



Contents lists available at ScienceDirect

International Journal of Surgery Case Reports

journal homepage: www.casereports.com

Giant gallbladder: A case report and review of literature

A.V. Kuznetsov^a, A.V. Borodach^{a,*}, E.N. Fedin^b, A.D. Khromova^c^a The Faculty of Surgery Clinic, The Novosibirsk State Medical University, Novosibirsk, Russian Federation^b The 1st Surgical Department, The 2nd Municipal Hospital, Novosibirsk, Russian Federation^c The Computer Tomography Department, Novosibirsk Regional Diagnostic Center, Novosibirsk, Russian Federation

ARTICLE INFO

Article history:

Received 31 July 2014

Accepted 5 August 2014

Available online 12 August 2014

Keywords:

Giant gallbladder

Gallbladder disease

Open cholecystectomy

Difficult diagnosis

ABSTRACT

INTRODUCTION: Reports of a giant gallbladder are rare.**PRESENTATION OF CASE:** A 77-year-old woman was admitted with complaints of dull pain in the right half of the abdomen and a palpable mass at the same place. A computerized tomography scan revealed an extremely enlarged gallbladder. Open cholecystectomy was performed. The volume of the removed organ was as much as 3.35 L.

Follow-up after 18 months showed that the patient was well. Examination revealed no significant acquired or congenital anomalies that might explain the excessive enlargement of the gallbladder.

DISCUSSION: We define a 'giant' gallbladder as an extreme enlargement of the organ with a volume exceeding 1.5 L, so that its weight is comparable to or even exceeds the mean (estimated) weight of the adult liver (1.5 kg). The first clinical presentation of such an enlargement is likely to differ from any other gallbladder disease, but rather to resemble a tumour or cyst of the abdominal cavity.**CONCLUSION:** A giant gallbladder is a special clinical and pathological entity in surgical practice, of unknown origin. It may develop in patients of any age, and mimics a large abdominal tumour or peritoneal cyst. Both the diagnostic process and surgical treatment demand non-routine approaches. Early and late follow-up results seem to be favourable.© 2014 The Authors. Published by Elsevier Ltd. on behalf of Surgical Associates Ltd. This is an open access article under the CC BY-NC-ND license (<http://creativecommons.org/licenses/by-nc-nd/3.0/>).

1. Introduction

The upper limit of the volume of a normal gallbladder in the adult is about 60 ml. Moderate enlargement of up to 200–300 ml is common in surgical practice due to various pathological conditions; in such cases the gallbladder fundus reaches the level of the anterior superior iliac spine. However, reports of a gallbladder of extreme size – with a weight exceeding that of the liver (1.5 kg) – are rare. In such cases, the gallbladder has lost its usual outlines and has acquired a balloon-shaped form. We could find only eight cases in the literature from the 18th century (Table 1). The pathogenesis of the development of a giant gallbladder remains obscure; some authors believe that it may have expanded this much due to a valve-like mechanism associated with three possible conditions: a stone(s), a tumour, or a “wandering gallbladder”,⁷ each of which could impair drainage and lead to almost unlimited enlargement. Giant gallbladders may present with remarkable weight loss.⁸

2. Case presentation

A 77-year-old woman was admitted to our hospital with a six-month history of dull pain in the right half of the abdomen that had become more severe over the previous several days; a palpable mass in the same place which the patient had not noticed before; and loss of about 15 kg in body weight. Examination revealed a slight asymmetry of the abdomen due to the right side being swollen, and a large mass on the right side of the abdomen extending from the hypochondrial region to the level of the right anterior superior iliac spine. A leucocytosis was found ($11 \times 10^9 \text{ ml}^{-1}$). An abdominal computerized axial tomography scan of the stomach and intestine was performed. The gallbladder was found to be extremely enlarged, approximately 172 mm × 161 mm × 240 mm, containing a partial septum separating its lumen into two unequal chambers. The proximal chamber included two floating stones of 12 mm and 14 mm in diameter. The posterior gallbladder wall displaced the right kidney dorsally and downwards, and its anterior wall was responsible for the distention of the right half of the anterior abdominal wall. The pericholecystic fat tissue was wiry and contained multiple enlarged lymph nodes (up to 10 mm in size) (Fig. 1).

At laparotomy, a giant roundish mass was discovered, coming from under the right lobe of the liver. It was covered by the greater omentum and adhered tightly to adjacent organs. It was

* Corresponding author at: The 2nd Municipal Hospital, Polzunova Street 21, Novosibirsk 630051, Russian Federation. Tel.: +7 913 941 79 65.

E-mail addresses: aborodach@gmail.com, borodach@ngmu.ru (A.V. Borodach).

Table 1
Case reports of giant gallbladders.

Publication	Sex	Age	Major co-morbidity	GB ^a size (cm)	GB volume	Patent cystic duct
Petit, before 1750 ¹	Female	27–28	–	?	'2 [Paris] pintes' (about 2 L) ^b	Probably
Van Swieten, 1754 ²	Mail	12	Very probable	?	'8 libras' (about 2.6 L) ^c	Yes
Collinson ^d	?	?	?	?	12.5 L	?
Neudörfer, 1911 ^d	Female	50	–	?	5.25 L	Yes
Kehr, 1913 ³	?	?	?	?	1.5 L	?
Borodach et al., 2005 ⁴	Female	67	–	20 × 12	1.5 L	Yes
Panaro et al., 2012 ⁵	?	17	PFIC-2 ^e	43 × 21	2.7 L	Yes
Liang Zong et al., 2013 ⁶	Female	55	–	30 × 18	4.0 L	Yes
This case	Female	77	–	24 × 17	3.3 L	Yes
Total: 9 cases	Female/male ratio: 5:1; not mentioned – 3	–	2	–	–	6 – yes 0 – no 1 – probably 2 – not mentioned

^a GB – gallbladder.

^b See the chapter "Tumeurs de la Vésicule de Fiel", pp. 445–9.

^c See the chapter "Hepatitis et Icterus Multiplex", pp. 107–43.

^d After Kehr, 1913, S6–7.³

^e Progressive Familial Intrahepatic Cholestasis, type 2.

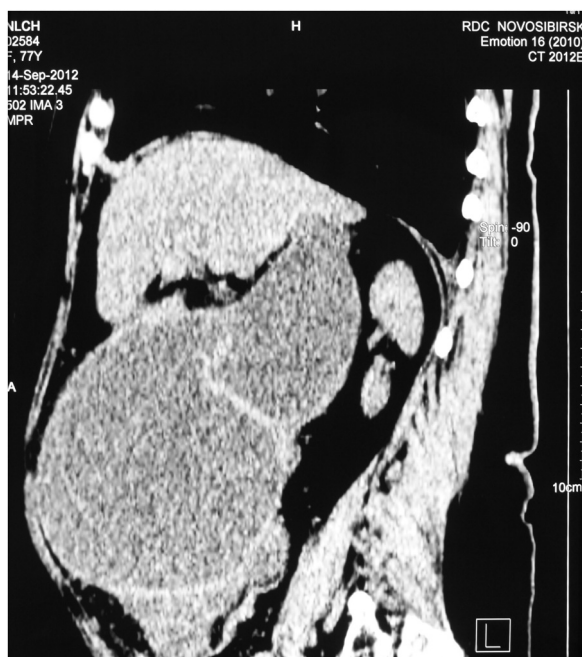

Fig. 1. A computerized axial tomography scan: the right parasagittal plane. A giant gallbladder displaces both the right kidney and the anterior abdominal wall.

decided to puncture and empty the sac with a trocar, which released about 3.35 L of its contents. The first portion of the fluid (about 3 L) looked whitish, cloudy, and viscous; the subsequent portion (about 350 ml) was a light-golden, transparent bile. The sac was cut open to facilitate its further dissection (Fig. 2), and a 3 mm cystic duct was discovered, emptying into the common bile duct, which had a normal outer width of 7 mm. The patient was discharged after an uneventful postoperative period of ten days.

The inner surface of the removed organ was covered in pink cellular mucosa, and the outer surface and the width of the wall both resembled those of the stomach. The gallbladder consisted of two unequal chambers divided by a high septum: the balloon-shaped larger one which contained mucus, and the proximal, smaller one in the form of a cone, which contained bile and two cholesterol 'mulberry' stones. The inner surface of the specimen was trabecular, similar to that of the urinary bladder. Microscopically, the picture was characteristic of chronic cholecystitis. The mucosal lining of the upper chamber (containing mucus) was flattened and

consistent with that of gallbladder hydrops. The mucosal lining of the lower chamber (containing bile) was tall prismatic. Both muscular bundles and connective tissue were hypertrophied markedly. A relatively limited growth of *Enterococcus faecalis* (100 CFU¹/ml) was found in the mucus; it was highly sensitive to all routine antibiotics.

At 18-month follow-up, the patient was well, sometimes working in her small garden. She did not have any symptomatic complaints. Computed tomography revealed that the outer width of the common bile duct was 8 mm. The pancreatico-biliary junction was found to be Y-shaped, forming on the level of the duodenal wall (Fig. 3). This disproved our working hypothesis that the development of a giant gallbladder may share a common mechanism with the development of congenital choledochal cysts, as suggested by Babbitt et al.⁹

3. Discussion

To the best of the authors' knowledge, no borders have ever been proposed to distinguish between simply enlarged and giant gallbladders. We define a gallbladder as 'giant' if the volume of the organ exceeds 1.5 L, so that its weight is comparable or even exceeds the mean (estimated) weight of the adult liver. The first clinical presentation of the entity will differ from any other gallbladder disease, but instead resembles a tumour or cyst of the abdominal cavity.

Alongside a valve-like mechanism making the gallbladder distend (for example, a stone), non-obstructive ways to alter the organ drainage may exist: nervous, hydraulic, or both. In younger patients, congenital anomalies may be considered, such as a local hypogangliosis in the gallbladder neck. We believe that, alongside a valve mechanism, there must be exclusively favourable conditions for a gallbladder to become extremely enlarged without either life-threatening complications, or even significant clinical manifestations: (1) low, if any, bacterial contamination of the bile in the gallbladder; (2) good vascularization; allowing (3) an appropriate regeneration of the gallbladder wall, allowing it to continue its distension at a steady rate. Perhaps, under conditions where the cystic duct is patent intermittently, an enlarged gallbladder itself might act as a kind of trap for the hepatic bile, allowing it to enter but not exit, and thereby creating a self-reinforcing expansionary process.

¹ Colony Forming Unit.

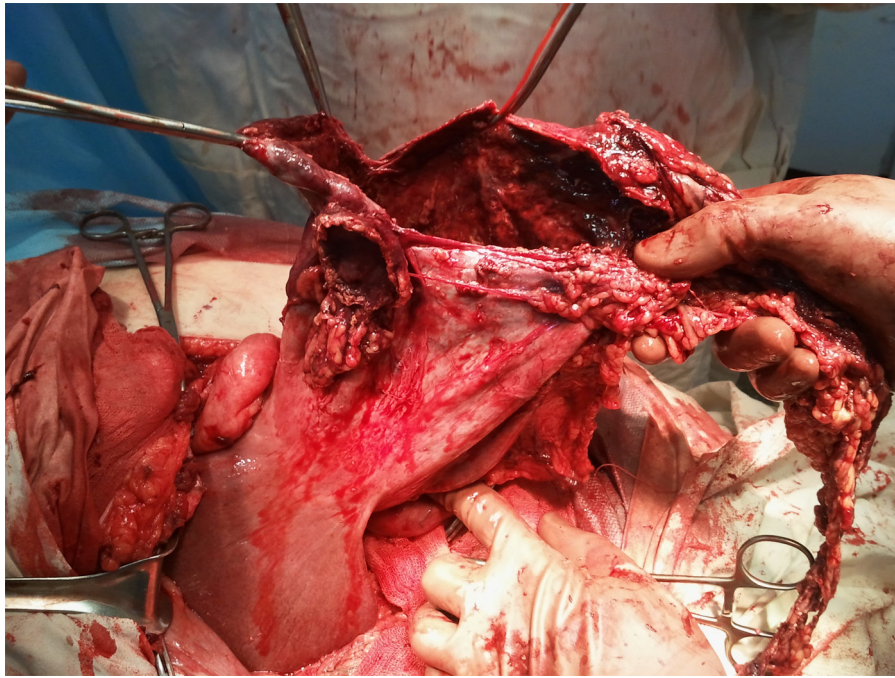


Fig. 2. During the operation: the gallbladder is cut open.

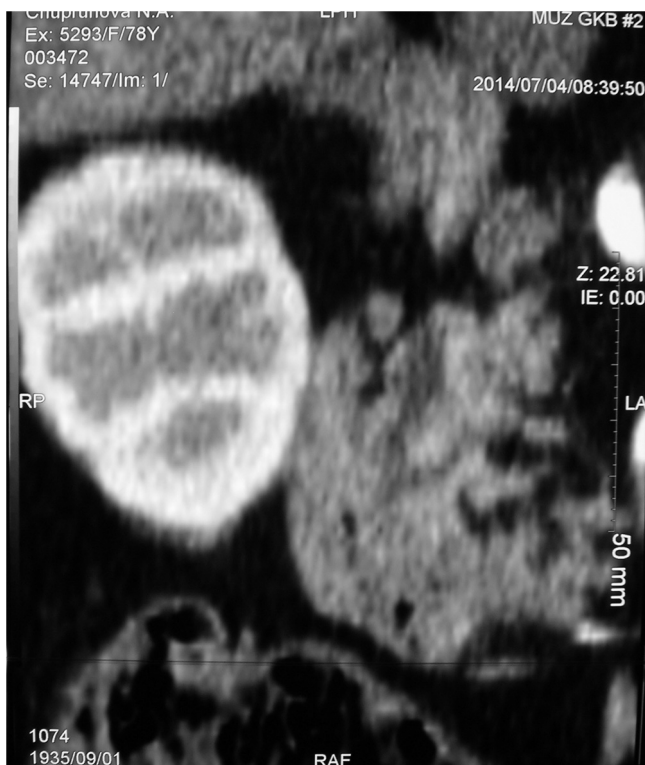

Fig. 3. A computerized axial tomography scan: the right parasagittal plane. A short common channel formed at the level of the duodenal wall is visible to the right.

4. Conclusion

The giant gallbladder is a special clinical and pathological entity of unknown origin that occurs occasionally in surgical practice. It may develop patients of any age, mimicking a gross abdominal tumour or peritoneal cyst. Both the diagnostic method and surgical treatment demand non-routine approaches; early and late

follow-up results seem to be favourable. Possible effects of gallbladder enlargement (with a patent cystic duct) on biliary hydrodynamics warrant further research on biliary system hydrodynamics which might shed light on this condition.

Conflicts of interest

None.

Funding

None.

Ethical approval

Written informed consent was obtained from the patient for publication of this case report and accompanying images. A copy of the written consent is available for review by the Editor-in-Chief of this journal on request.

Author contributions

Dr. Kuznetsov was an operator (a surgeon) in the case reported.

Prof. Borodach was asked to take part during the operation as a surgeon in the case reported; he has made a review of literature and translation from Russian into English as well; a contacting author.

Dr. Fedin was an operator-assistant and so called ‘a surgeon-curator’ in the case reported.

Dr. Khromova provided the CT diagnostics before the surgical treatment and in a remote follow-up examination in 1.5-year after the operation was performed.

Acknowledgements

The authors would like to express acknowledgements to Oxford Language Editing, Oxford University Press, UK, for both editing of this text and most kind attention; and to Dr. Lars Aanning, MD, FACS, a surgeon, Yankton SD 57078, USA, for discussion of the topic.

References

1. Petit JL. *Oeuvres complètes*. De Toutes de Librairies Médicales; 1837.
2. Van Swieten G. *Commentaria in Hermanni Boerhaave Aphorismos, de cognoscendis et curandis morbis*. T.3, Paris, 1754.
3. Kehr H. *Chirurgie der Gallenwege*. Stuttgart: Ferdinand Enke Verlag; 1913. p. 971S.
4. Borodach AV, Borodach VA, Kim AN. Gigantskaya vodyanka zhelchnogo puzyrya. Novosibirsk: Sibirskiy Universitet; 2005. p. 62–3.
5. Panaro F, Chastaing L, Navarro F. Hepatobiliary and pancreatic: Giant gallbladder associated with Byler's disease. *J Gastroenterol Hepatol* 2012;27, <http://dx.doi.org/10.1111/j.1440-1746.2012.07058.x>.
6. Zong L, Chen P, Wang L, He C, Wang G, Jiang J, et al. A case of congenital giant gallbladder with massive hydrops mimicking celiac cyst. *Oncol Lett* 2013;5: 226–8.
7. Taxonera Samsó C, García Albarrán J, Villacorta Patiño J, Díaz-Rubia García M. Vesícula gigante: Aportación de un caso y revisión de la literatura. *Rev Esp Enferm Apar Dig* 1983;64:141–4.
8. Maeda Y, Setoguchi T, Yoshida T, Katsuki T. A giant gallbladder. *Gastroenterol Jpn* 1979;14:621–4.
9. Jona JZ, Babbitt DP, Starshak RJ, LaPorta AJ, Glicklich M, Cohen RD. Anatomic observations and etiologic and surgical considerations in choledochal cyst. *J Pediatr Surg* 1979;14:315–20.

Open Access

This article is published Open Access at scimedirect.com. It is distributed under the [IJSCR Supplemental terms and conditions](#), which permits unrestricted non commercial use, distribution, and reproduction in any medium, provided the original authors and source are credited.