

# High-rate episodes with simultaneous atrial and ventricular activation in a patient with permanent pacemaker implantation for complete heart block



Saurabh Ajit Deshpande, MD, DNB, DM (Cardiology),\*  
Ameya Udyavar, MD, DM, DNB (Cardiology)<sup>†</sup>

From the \*Department of Cardiology, Jag Jivan Ram Western Railway Hospital, Mumbai, India, and  
<sup>†</sup>Department of Cardiology, P D Hinduja Hospital, Mumbai, India.

## Introduction

Tachycardias like atrial fibrillation and ventricular tachycardias are seen in patients who have undergone permanent pacemaker (PPM) implantations; however, supraventricular tachycardias in these patients are very rare.<sup>1,2</sup> A 20-year-old woman underwent PPM for repeated episodes of syncope owing to complete heart block in 2013. She underwent a dual-chamber PPM implantation and was 100% ventricular paced during regular follow-up. She presented with intermittent episodes of severe palpitations with a narrow QRS tachycardia with a heart rate of 160–180 beats per minute (bpm). Device interrogation showed multiple episodes of tachycardia with simultaneous atrial and ventricular activation during the tachycardia, suggestive of atrioventricular nodal re-entrant tachycardia (AVNRT). An electrophysiology (EP) study was done to study the tachycardia. The narrow QRS tachycardia with simultaneous atrial and ventricular activation in a patient with complete heart block is discussed herewith.

## Case report

A 20-year-old woman presented with 3 episodes of syncope in 2013. One of the episodes was occurred while driving a motorbike and she had sustained a hand injury as a result of the fall. Her electrocardiogram (ECG) on admission showed complete heart block. She was observed for a few days and secondary causes ruled out. A Holter study was done and showed an average heart rate of 57 bpm with minimum heart rate of 43 bpm and maximum heart rate of 75 bpm. The basal rhythm throughout the study was complete heart block. She underwent dual-chamber implantation (Adapta DDDR; Medtronic, Minneapolis, MN) in July 2013. The pacemaker

**KEYWORDS** Atrioventricular nodal reentrant tachycardia; Complete heart block; Electrophysiological study; High-rate episodes; Pacemaker (Heart Rhythm Case Reports 2020;6:67–71)

**Address reprint request and correspondence:** Dr Saurabh Ajit Deshpande, Department of CTVS (medicine), Jag Jivan Ram Western Railway Hospital, M Marg, RBI Staff Colony, Mumbai Central, Mumbai – 400008, Maharashtra state, India. E-mail address: saurabhmddm@gmail.com.

## KEY TEACHING POINTS

- Symptomatic narrow QRS tachycardia is rare in a patient with complete heart block and permanent pacemaker.
- If found, it should be meticulously evaluated to rule out sinus tachycardia.
- Simple measures such as increasing beta-blocker may take care of a patient's symptoms.

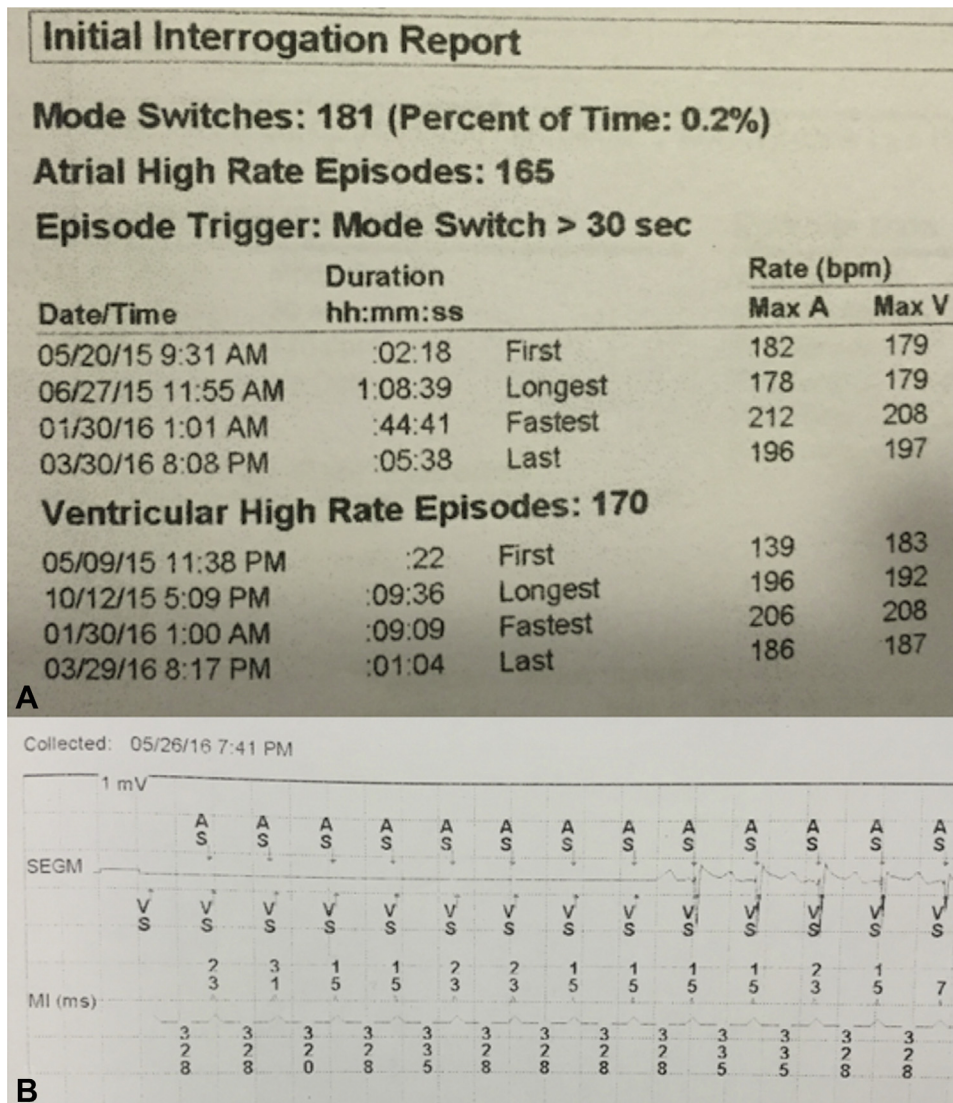
was programmed a lower rate of 60 bpm and an upper tracking rate of 140 bpm owing to her young age. She was symptomatically better, with no episodes of syncope.

However, in the last 1 year, she has been complaining of severe palpitations, which are triggered by exertion. ECG could not be recorded during these episodes.

The device was interrogated subsequently. Device interrogation showed multiple high-rate episodes lasting for a few seconds to an hour (Figure 1). These high-rate episodes were recorded in both the atrial and ventricular leads. There were almost 170 episodes of high atrial and ventricular rate lasting for a few minutes to as long as 1 hour. The rate varied from 160 to 188 bpm. The device also recorded 181 episodes of mode switch owing to these high-rate episodes.

Further interrogation of the device and the analysis of the marker channel suggested that there was simultaneous atrial and ventricular activation, similar to AVNRT. The ventricular-atrial interval was as low as 15 ms, ruling out pathway-related tachycardias. The interrogation suggested that these episodes could be AVNRT or junctional tachycardia. Though it is possible, AVNRT in a patient with impaired atrioventricular (AV) conduction system (complete heart block) and having 99% ventricular paced rhythm has not been reported.

An EP study was carried out in March 2016. A diagnostic decapolar catheter was positioned in the coronary sinus. Quadripolar catheters were placed in the His bundle and right



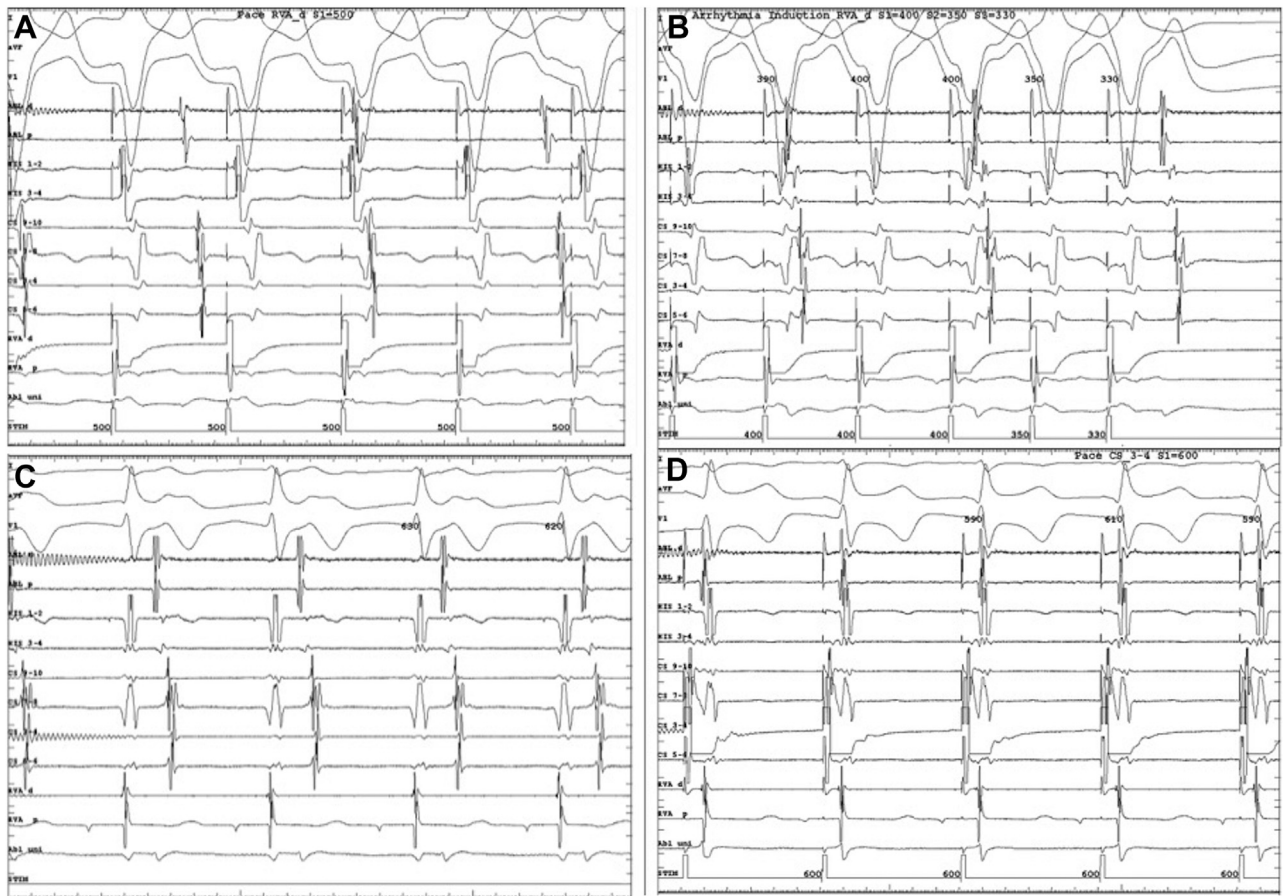
**Figure 1** Device interrogation. **A:** High-rate atrial and ventricular episodes detected by the pacemaker on interrogation. **B:** Pacemaker marker channel showed simultaneous A and V activation mimicking atrioventricular nodal re-entrant tachycardia. Atrial and ventricular sense electrograms are simultaneously seen with atrioventricular interval of 15–20 ms.

ventricle. A 4-mm-tip ablation catheter was positioned in the high right atrium. There was ventricular-atrial dissociation at baseline with pacing at 600 ms (Figure 2A), which did not improve with isoprenaline infusion (and ventricular pacing at 400 ms) (Figure 2B). Thus, it ruled out pathway-related tachycardias and AVNRT. After the pacemaker was programmed to DDI mode of 40 bpm, the native rhythm was analyzed. The patient had a prolonged AH interval of 470 ms with a basal sinus P-P interval of 630 ms (Figure 2C). During decremental atrial pacing the AV interval prolonged (Figure 2D). AV conduction was Wenckebach at 100 bpm.

With isoprenaline infusion, she developed sinus tachycardia of 160–180 bpm with a prolonged PR of 300–320

ms with 1:1 AV conduction. The ventricular electrogram was following on the next atrial electrogram owing to prolonged PR. This was recorded by the device as high-rate episodes owing to simultaneous A and V activation (mimicking AVNRT) (Figure 3A). A 12-lead ECG at this point of time also was very similar to AVNRT (Figure 3B). No junctional tachycardia or any other tachycardia could be induced.

Owing to the symptomatic status of the patient because of prolonged AV conduction, the upper tracking rate was then increased to 160 bpm with a short-paced PR interval. She was also started on beta-blockers to reduce her sinus tachycardia. The patient has been asymptomatic since then.



**Figure 2** The electrophysiology study findings with the following channels are displayed: first 3 channels of electrocardiogram, ablation distal and proximal (ABL d and p, positioned in the high right atrium), His bundle channels, coronary sinus channel, and right ventricle channel. **A:** Ventricular-atrial (VA) dissociation at baseline with pacing at 600 ms. **B:** VA dissociation persists with ventricular pacing at 400 ms with isoprenaline infusion. **C:** Basal sinus rhythm with P-P interval of 630 ms and prolonged AH interval of 470 ms. **D:** During decremental atrial pacing the AV interval prolonged.

## Discussion

Patients with PPM implantation for complete heart block rarely suffer any tachyarrhythmias during follow-up. The common tachycardias seen in patients with PPM are atrial fibrillation in elderly patients with sick sinus syndrome.<sup>2,3</sup> Pacemaker-mediated tachycardia is another tachycardia seen in patients with a dual-chamber pacemaker.<sup>4</sup> Nonsustained ventricular tachycardias are the least common among the tachycardias<sup>1</sup> and are not associated with increased mortality.<sup>5</sup>

Pathway-mediated tachycardias and AVNRT are uncommon in patients with congenital complete heart block, as 1 of the components (antegrade AV conduction) in these patients is impaired. AVNRT cases have been published with both AV block and atrial fibrillation. The circuit in these cases probably involves the inferior AVN extensions and so AVNRT is compatible in patients with infranodal block. However, pacemaker-mediated tachycardia is caused by AV conduction via the pacemaker and intrinsic ventriculoatrial conduction.<sup>4</sup>

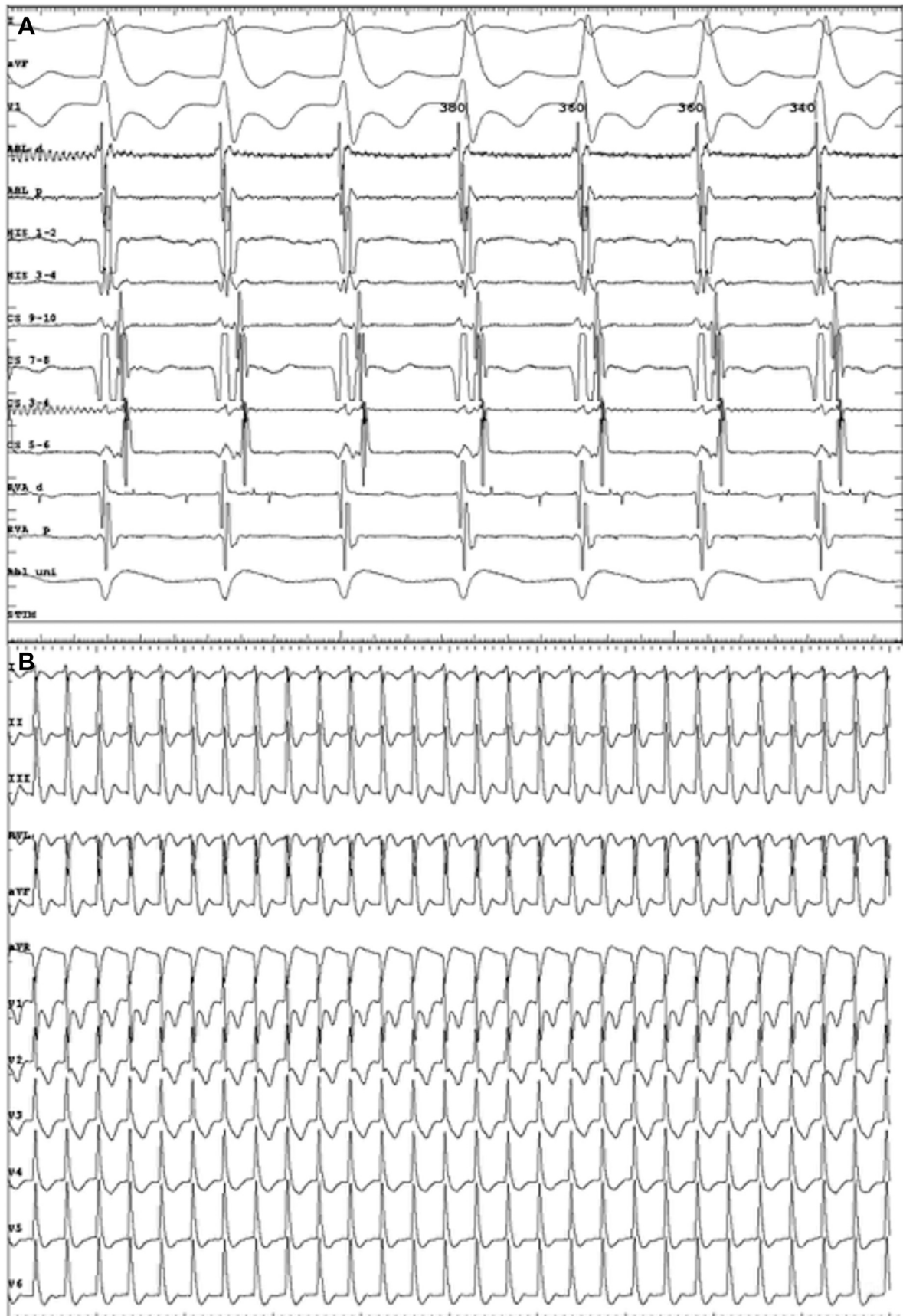
Our patient showed multiple high-rate episodes up to 180 bpm. Device interrogation suggested possibility of AVNRT owing to simultaneous atrial and ventricular activation. It was diagnosed as sinus tachycardia (up to 180 bpm), which was conducting to the ventricle with a very prolonged PR, causing the ventricle electrogram to fall on the next sinus atrial electrogram. This caused immense discomfort to the patient, probably owing to the diastolic mitral regurgitation caused by the very prolonged PR interval.<sup>6</sup>

The upper tracking rate was then increased to 160 bpm with a short PR interval. The patient has been asymptomatic since then.

## Conclusion

Narrow QRS tachycardias with 1:1 AV conduction are rare in patients with PPM for complete heart block. Our patient had sinus tachycardia of 180 bpm with a very prolonged PR, giving an impression of AVNRT (simultaneous atrial and ventricular activity) on device interrogation. Beta-blockers and





**Figure 3** Sinus tachycardia with prolonged PR causing simultaneous atrial and ventricular activation mimicking atrioventricular nodal re-entrant tachycardia. **A:** Intracardiac. **B:** Twelve-lead electrocardiogram.

increasing the upper tracking rate with shortened AV cured the patient of her symptoms.

## References

1. Gabriels J, Wu M, Rosen L, Patel A, Goldner B. Clinical significance of nonsustained ventricular tachycardia on stored electrograms in permanent pacemaker patients. *Pacing Clin Electrophysiol* 2016;39:1335–1339.
2. Swiryn S, Orlov MV, Benditt DG, et al. Clinical implications of brief device-detected atrial tachyarrhythmias in a cardiac rhythm management device population: results from the Registry of Atrial Tachycardia and Atrial Fibrillation Episodes. *Circulation* 2016;134:1130–1140.
3. Fernandez G, Maid GF, Arias AM, Maldonado S, Pizarro R, Belziti CA. Prevalence of atrial fibrillation and predictors of its occurrence in patients with dual-chamber pacemakers. *Arch Cardiol Mex* 2016;86:214–220.
4. Monteil B, Ploux S, Eschalier R, et al. Pacemaker-mediated tachycardia: manufacturer specifics and spectrum of cases. *Pacing Clin Electrophysiol* 2015;38:1489–1498.
5. Jamil HA, Mohammed SA, Gierula J, et al. Prognostic significance of incidental nonsustained ventricular tachycardia detected on pacemaker interrogation. *Am J Cardiol* 2019;123:409–413.
6. Panidis IP, Ross J, Munley B, Nestico P, Mintz GS. Diastolic mitral regurgitation in patients with atrioventricular conduction abnormalities: a common finding by Doppler echocardiography. *J Am Coll Cardiol* 1986;7:768–774.