

A rare and reversible cause of third-degree atrioventricular block: a case report

Gino Lee *, Patrick Badertscher, Christian Sticherling , and Stefan Osswald 

Department of Cardiology, University Hospital Basel, Petersgraben 4, 4031 Basel, Switzerland

For the podcast associated with this article, please visit <https://academic.oup.com/ehjcr/pages/podcast>

Received 14 January 2021; first decision 2 March 2021; accepted 14 September 2021; online publish-ahead-of-print 18 October 2021

Background

Cardiac involvement of Lyme disease (LD) typically results in atrioventricular (AV) conduction disturbance, mainly third-degree AV block.

Case summary

A 54-year-old patient presented to our emergency department due to recurrent syncope. Third-degree AV block with a ventricular escape rhythm (33 b.p.m.) was identified as the underlying rhythm. Transthoracic echocardiography (TTE) was normal. To rule out common reversible causes of complete AV block, a screening test for Lyme borreliosis was carried out. Elevated levels for borrelia IgG/IgM were found and confirmed by western blot analysis. Lyme carditis (LC) was postulated as the most likely cause of the third-degree AV block given the young age of the patient. Initiation of antibiotic therapy with ceftriaxone resulted in a gradual normalization of the AV conduction with stable first-degree AV block on Day 6 of therapy. The patient was changed on oral antibiotics (doxycycline) and discharged without a pacemaker. After 3 months, the AV conduction recovered to normal.

Discussion

Lyme carditis should always be considered, particularly in younger patients with new-onset AV block and without evidence of structural heart disease. Atrioventricular block recovers in the majority of cases after appropriate antibiotic treatment.

Keywords

Lyme carditis • Lyme disease • Third-degree atrioventricular block • Cardiac pacing • Borreliosis • Case report

Learning points

- Lyme carditis is a possible cause of third-degree atrioventricular (AV) block and early antibody screening in the serum should be considered if other reversible causes are absent or if there is a clinical suspicion for Lyme disease.
- Prognosis of Lyme carditis with third-degree AV block under antibiotic treatment is good and high-degree AV block usually resolves within 1 week.
- Permanent pacemaker implantation in Lyme carditis can often be avoided through early and correct administration of antibiotic therapy.

* Corresponding author. Tel: +41 79 794 5901, Email: gino.lee@usb.ch

Handling Editor: Tom De Potter

Peer-reviewers: Fabien Barbieri; Habib Rehman Khan

Compliance Editor: Brett Sydney Bernstein

Supplementary Material Editor: Fabienne Vervaat

© The Author(s) 2021. Published by Oxford University Press on behalf of the European Society of Cardiology.

This is an Open Access article distributed under the terms of the Creative Commons Attribution-NonCommercial License (<https://creativecommons.org/licenses/by-nc/4.0/>), which permits non-commercial re-use, distribution, and reproduction in any medium, provided the original work is properly cited. For commercial re-use, please contact journals.permissions@oup.com

Introduction

Symptomatic third-degree atrioventricular (AV) block is a critical condition, which usually mandates pacemaker implantation, if not reversible. Common reversible causes include medical therapy (e.g. beta blockers), myocardial ischaemia, cardiac procedures, and myocarditis. Lyme carditis (LC) is an overall rare cause, however, likely reversible with antibiotic treatment.¹

We report on the time course under antibiotic treatment of a 54-year-old patient with third-degree AV block caused by Lyme carditis.

Timeline

Time	Event
Day 1	Presentation to the emergency department due to recurrent syncope. Third-degree atrioventricular (AV) block with a ventricular escape rhythm (33 b.p.m.) was identified in the presenting electrocardiogram (ECG). Positive borrelia IgG/IgM titres were found. Begin of antibiotic treatment with ceftriaxone. Transfer to intensive care unit.
Day 2	Intermittent reversal of third-degree AV block with appearance of first- and second-degree AV block. Low-dose isoprenaline therapy (1–1.5 µg/min). Cardiac magnetic resonance imaging shows normal finding.
Day 3–4	Mainly first- and second-degree AV block with short periods of third-degree atrioventricular block. The patient is continuously haemodynamically stable.
Day 5	Cessation of isoprenaline therapy. There is mainly first-degree AV block (PQ interval 309 ms) with the last observed short appearance of complete heart block 9 h after cessation of isoprenaline therapy.
Day 6	Stable first-degree AV block with no observed PQ interval above 300 ms during 24 h. Antibiotic therapy is changed to an oral therapy with doxycycline.
Day 12	Discharge from the hospital. AV block I with PQ interval of 244 ms. Antibiotic therapy is prescribed for a total duration of 21 days.
Follow-up 3 months after the hospitalization	PQ interval is normalized (185 ms). Holter-ECG shows no higher-degree AV block. Patient is completely asymptomatic.

Case presentation

A 54-year-old otherwise healthy patient presented at our emergency ward after three syncope at home. He described very short

prodromal symptoms ('heat sensation' in the head) but denied concomitant chest pain or palpitations. The consecutive falls led to a head contusion with superficial lacerations.

Third-degree AV block with a ventricular escape rhythm (33 b.p.m.) was diagnosed as the cause of syncope (Figure 1). Upon arrival, the patient had a stable blood pressure of 114/71 mmHg, was afebrile and experienced no significant bradycardia symptoms at rest. A relevant brain injury was ruled out by computed tomography scanning. Transthoracic echocardiography ruled out structural heart disease and there were no signs for ischaemia as the underlying cause.

Since the patient was young, had no significant past medical history and lived in a risk area for borreliosis in Switzerland, we performed a screening test on admission with a chemoluminescence immunoassay. We found significantly elevated titres for borrelia IgG (73.62 AU/mL; reference value <10 AU/mL) and borrelia IgM (>180 AU/mL; reference value <18.0 AU/mL). The serologic findings were later confirmed by western blot analysis suggesting an ongoing Lyme borreliosis. After reassessing his detailed history, the patient remembered a scrotal rash after a long car drive several weeks before, which finally could be attributed to a tick bite.

Due to the serologic findings, we considered a Lyme carditis as possible cause of the third-degree AV block. Cardiac magnetic resonance imaging ruled out inflammatory or infiltrative processes. Since the patient was haemodynamically stable with a regular ventricular escape rhythm and no significant bradycardia symptoms at rest, we decided not to perform an immediate permanent pacemaker implantation but initiated intravenous antibiotic therapy with ceftriaxone (2 g daily). The patient was transferred to our intensive care unit with the possibility of immediate provisional pacemaker placement in case of haemodynamic instability.

On Day 2 of antibiotic treatment, there was already intermittent first-degree AV block with a PQ interval of 346 ms and second-degree AV block Type I and II. Due to intermittent short heart rate episodes below 30 b.p.m. on Day 2 of treatment, low-dose continuous isoprenaline therapy (1–1.5 µg/min) was initiated. On Day 5, isoprenaline therapy was stopped with a short episode of third-degree AV block 9 h after isoprenaline cessation. The electrocardiogram (ECG) then showed first-degree AV block with a PQ interval of 309 ms (Figure 2). One Day 6, there were no PQ intervals >300 ms during 24 h and the antibiotic therapy was changed to an oral regimen with doxycycline (100 mg twice daily).

Finally, the patient could be discharged from the hospital with a stable first-degree AV block (PQ interval 244 ms). The antibiotic therapy was prescribed for a total duration of 21 days.

At 3 months of follow-up, the patient denied any cardiac symptoms and the ECG revealed a normal PQ interval of 185 ms (Figure 2). There were no intermittent AV blocks in the Holter-ECG.

Discussion

Lyme disease is a tick-borne illness that is caused by gram-negative spirochete bacteria of the borrelia species and transmitted by the Ixodes tick.¹ Cardiac involvement is reported in 0.3–4% of patients. The most common clinical manifestation of Lyme carditis is AV conduction disturbance. A systematic review reported that third-degree AV block was present in 77% of patients with LC.²

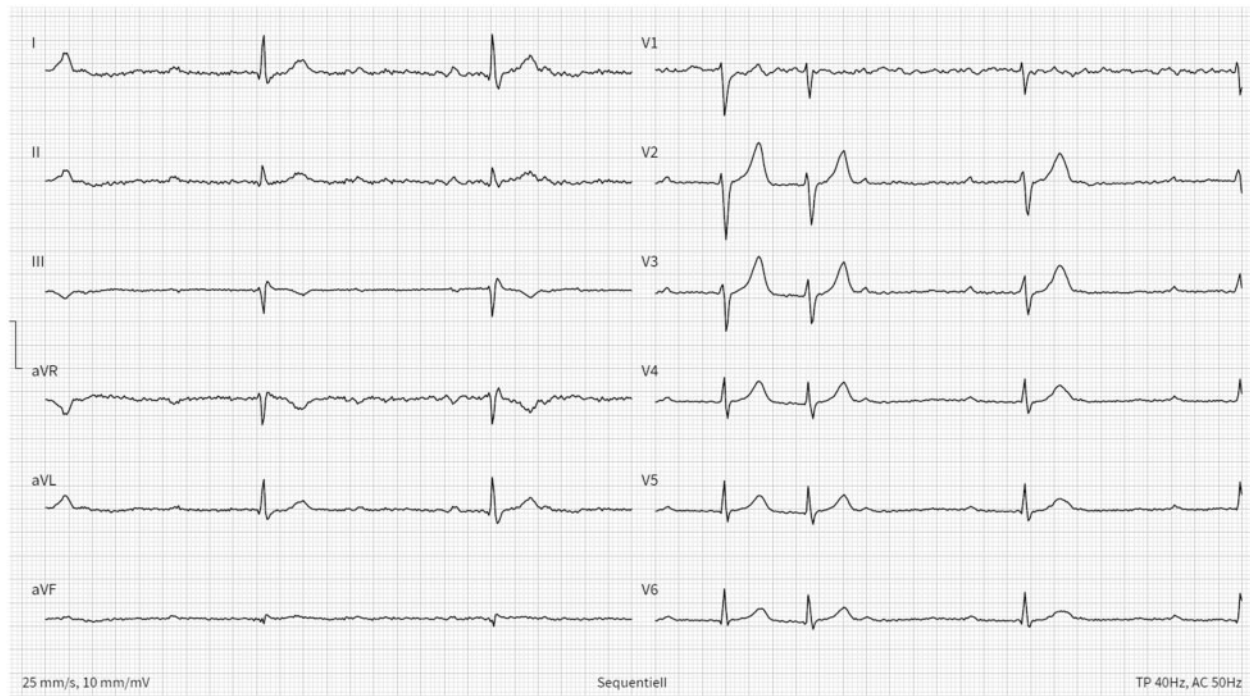


Figure 1 Presenting electrocardiogram in the emergency department.

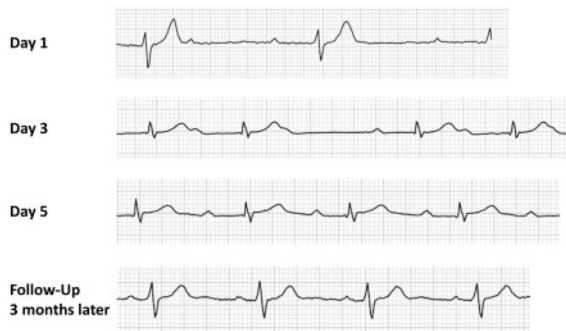

Figure 2 The electrocardiographic progression of a patient with Lyme carditis presenting with third-degree atrioventricular block under antibiotic treatment.

Serologic testing for Lyme disease consists of an initial borrelia antibody (IgG/IgM) screening test. Positive results must be confirmed by western blot assay. In addition, it is necessary to exclude a current Syphilis disease, because it can interfere with the borrelia antibody test.

The prognosis under antibiotic treatment is generally favourable and third-degree AV block typically resolves within 1 week. A review of 45 cases reported a median time until normal AV conduction or first-degree AV block of 6 days (range of 1–42 days).³ Another series of 88 cases showed a median time to resolution of high-degree AV block of 5 days (3–9 days).² Permanent pacemaker implantation can

therefore be avoided in the majority of cases, if correct antibiotic therapy is administered.

First-line therapy is intravenous administration of ceftriaxone followed by oral antibiotics (doxycycline or amoxicillin) for a total therapy duration of 14–21 days.⁴ Patients with LD and no conduction disturbances (defined as a PR interval <300 ms) can be initially treated with oral antibiotics for a duration of 21 days.⁵

The clinical course of our patient is in line with the reported cases and stable first-degree AV block was achieved on the 6th day of antibiotic therapy. Although the patient could not remember a recent tick bite, he noticed a transient right scrotal erythema and swelling several weeks prior to the hospital administration which was interpreted as an erythema migrans. Furthermore, he was a regular jogger and lived in a risk area for borreliosis in Switzerland. It is generally notable that only less than half of patients with Lyme carditis noticed erythema migrans before occurrence of cardiac symptoms.^{2,3} Recently, the Suspicious Index in Lyme Carditis (SILC) was proposed to evaluate the risk of underlying LD in patients presenting with high-degree AV block. Our patients had a SILC of 6 and was thus at intermediate risk for LD.

Our flowchart summarizes our systematic approach to the management of third-degree AV block (Figure 3).

In conclusion, this 54-year-old patient with Lyme carditis and third-degree AV block received appropriate antibiotic treatment with complete normalization of the AV conduction and therefore no need for permanent pacemaker implantation.

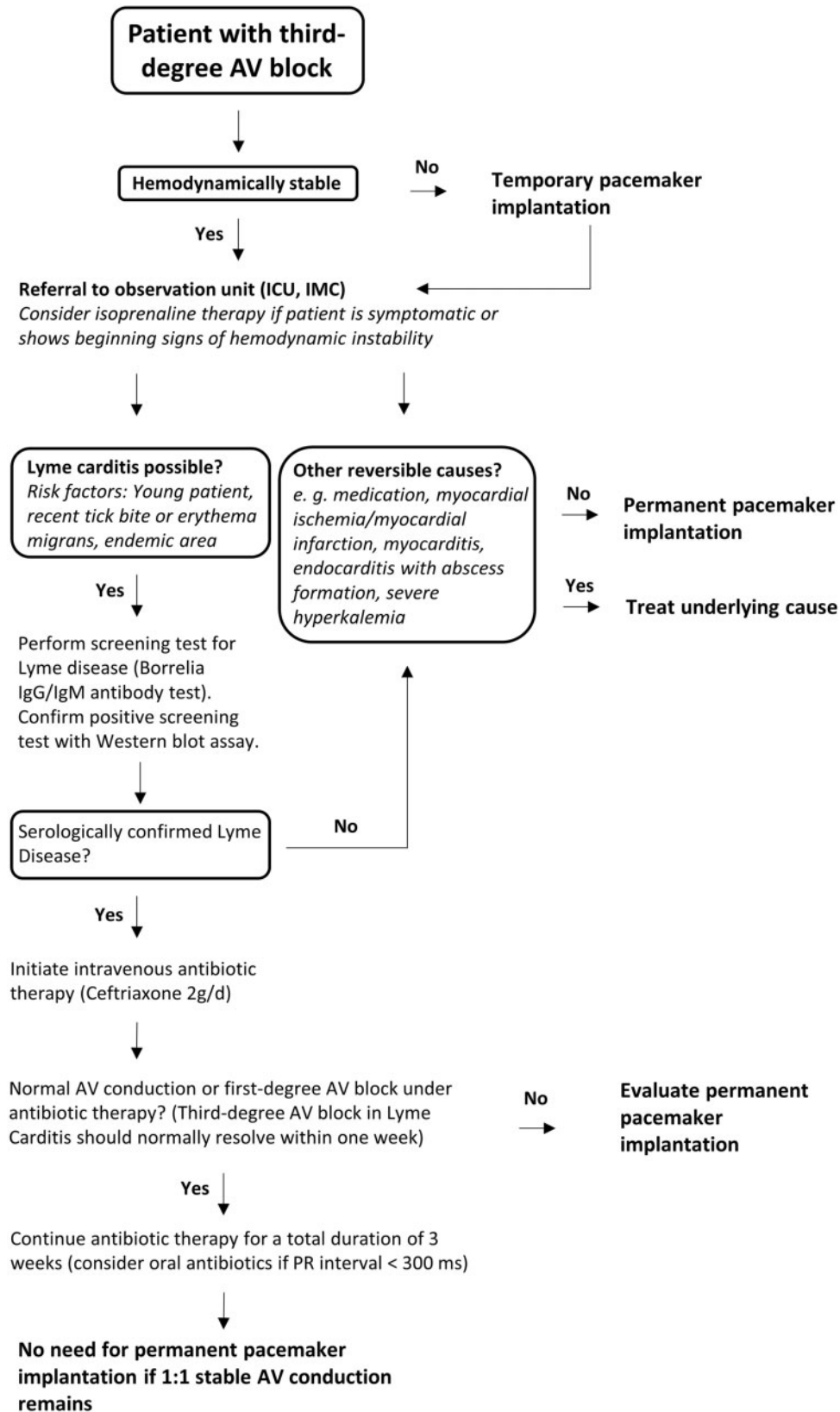


Figure 3 Systematic approach to the management of third-degree atrioventricular block with emphasis on geographical regions with high prevalence of Lyme borreliosis.

Lead author biography



Gino Lee is a senior physician for general cardiology at the University Hospital Basel in Switzerland.

Supplementary material

[Supplementary material](#) is available at *European Heart Journal - Case Reports* online.

Acknowledgements

The authors thank Prof. Nina Khanna und Dr Sabine Kuster from the Department for infectious diseases at the University Hospital Basel

for providing counsel that led to the successful treatment of this patient.

Slide sets: A fully edited slide set detailing this case and suitable for local presentation is available online as [Supplementary data](#).

Consent: The authors confirm that written consent for submission and publication of this case report including images and associated text has been obtained from the patient in line with COPE guidance.

Conflict of interest: None declared.

Funding: None declared.

References

1. Fish AE, Pride YB, Pinto DS. Lyme carditis. *Infect Dis Clin North Am* 2008;**22**: 275–288.
2. Besant G, Wan D, Yeung C, Blakely C, Branscombe P, Suarez-Fuster L et al. Suspicious index in Lyme carditis: systematic review and proposed new risk score. *Clin Cardiol* 2018;**41**:1611–1616.
3. Forrester JD, Mead P. Third-degree heart block associated with Lyme carditis: review of published cases. *Clin Infect Dis* 2014;**59**:996–1000.
4. Yeung C, Baranchuk A. Diagnosis and treatment of Lyme carditis. *J Am Coll Cardiol* 2019;**73**:717–726.
5. Wormser GP, Dattwyler RJ, Shapiro ED, Halperin JJ, Steere AC, Klemperer MS et al. The clinical assessment, treatment, and prevention of Lyme disease, human granulocytic anaplasmosis, and babesiosis: clinical practice guidelines by the Infectious Diseases Society of America. *Clin Infect Dis* 2006;**43**: 1089–1134.