



Review

A systematic review of gallstone sigmoid ileus management

Nicholas Farkas*, Vasha Kaur, Arun Shanmuganandan, John Black, Chantal Redon, Adam E. Frampton, Nicholas West

Epsom and St Helier University Hospitals, Wrythe Lane, Carshalton, Sutton, London, SM5 1AA, United Kingdom



ARTICLE INFO

Keywords:

Gallstone sigmoid ileus
Gallstone ileus
Large bowel
Obstruction
Cholelithiasis
Emergency surgery

ABSTRACT

Introduction: Gallstone sigmoid ileus is a rare although serious complication of cholelithiasis resulting in large bowel obstruction. The condition accounts for 4% of all gallstone ileus patients. There are no recognized management guidelines currently. Management strategies range from minimally invasive endoscopy and lithotripsy to substantial surgery. We aim to identify trends when managing patients with gallstone sigmoid ileus to help improve outcomes.

Methods: Literature searches of EMBASE, Medline and by hand were conducted. All English language papers published from 2000 to 2017(Oct) were included. The terms 'gallstone', 'sigmoid', 'colon', 'ileus', 'coelus' and 'large bowel obstruction' were used.

Results: 38 papers included, male:female ratio was 8:30. Average age was 81.11 (SD ± 7.59). Average length of preceding symptoms was 5.31days (+/-SD3.16). 20/38 (59%) had diverticulosis. 89% of patients had significant comorbidities documented. 34/38 patients underwent computerized tomography. 31 stones were located within sigmoid colon, 4 at rectosigmoid junction and 2 within descending colon. Average impacted gallstone size was 4.14 cm (2.3–7 cm range). 23/38 (61%) patients' initial management was conservative or with endoscopy ± lithotripsy. Conservative management successfully treated 26% of patients. 28/38 (74%) patients ultimately underwent surgical intervention. 5/38 patients died post-operatively. Patients treated non-operatively had shorter hospital stays (4:12.3days) although not significant (p-value = 0.0056).

Conclusions: There is no management consensus from the literature. Current evidence highlights endoscopy and lithotripsy as practical firstline strategies. However, surgical intervention should not be delayed if non-operative measures fail or in emergency. Given the complexity of such patients, less invasive timesaving surgery appears practical, avoiding bowel resection and associated complications.

1. Introduction

Sigmoid gallstone ileus is a rare complication of cholelithiasis leading to large bowel obstruction. Gallstone ileus, in general, arises in 0.3–0.5% of patients with cholelithiasis [1] and accounts for between 1 and 4% of patients with intestinal obstruction [2,3]. Many clinicians will have encountered patients with gallstone ileus resulting in small bowel obstruction. The condition most often affects elderly women with multiple co-morbidities. Gallstone ileus generally occurs as a result of a cholecystoenteric fistula between the gallbladder and small bowel, with most enteric fistulae occurring between the duodenum and gallbladder [4]. The commonest sites for stone impaction are the distal ileum and ileo-caecal valve, which together account for 60–85% of cases [3].

In contrast, sigmoid gallstone ileus arises as a result of either a cholecystocolonic fistula between the gallbladder and large bowel or a

stone traversing the ileocolic junction. If the gallstone is unable to pass distally, large bowel obstruction ensues. Gallstone sigmoid ileus accounts for 4% of all gallstone ileus patients [3]. This equates to between 12 and 15 patients per 100,000 of all patients with gallstone disease [1,3]. The same cohorts of patients are affected as those with gallstone ileus. Colonic pathology with the potential for luminal stricturing such as diverticular disease may increase the likelihood of a stone becoming impacted [5].

In general, gallbladder fistulae are uncommon. Such findings are identified in 0.9% of biliary tract surgery. Cholecystoduodenal fistulae account for 70% of these while cholecystocolic fistulae make up 10–20% and cholecystogastric fistulae account for the remainder [6].

At present, in view of its uncommon nature, there are no unified management guidelines to treat sigmoid gallstone ileus. Management strategies are individualized to the patient and managing team and can

* Corresponding author.

E-mail addresses: nickfarkas@doctors.org.uk (N. Farkas), vashakaur@yahoo.co.uk (V. Kaur), drsapsurg@doctors.org.uk (A. Shanmuganandan), jbjohnyblack126@gmail.com (J. Black), chantz24@hotmail.com (C. Redon), adam.frampton@doctors.org.uk (A.E. Frampton), nicholas.west@esth.nhs.uk (N. West).

<https://doi.org/10.1016/j.amsu.2018.01.004>

Received 13 October 2017; Received in revised form 7 January 2018; Accepted 21 January 2018

2049-0801/ © 2018 The Authors. Published by Elsevier Ltd on behalf of IJS Publishing Group Ltd. This is an open access article under the CC BY-NC-ND license (<http://creativecommons.org/licenses/by-nc-nd/4.0/>).

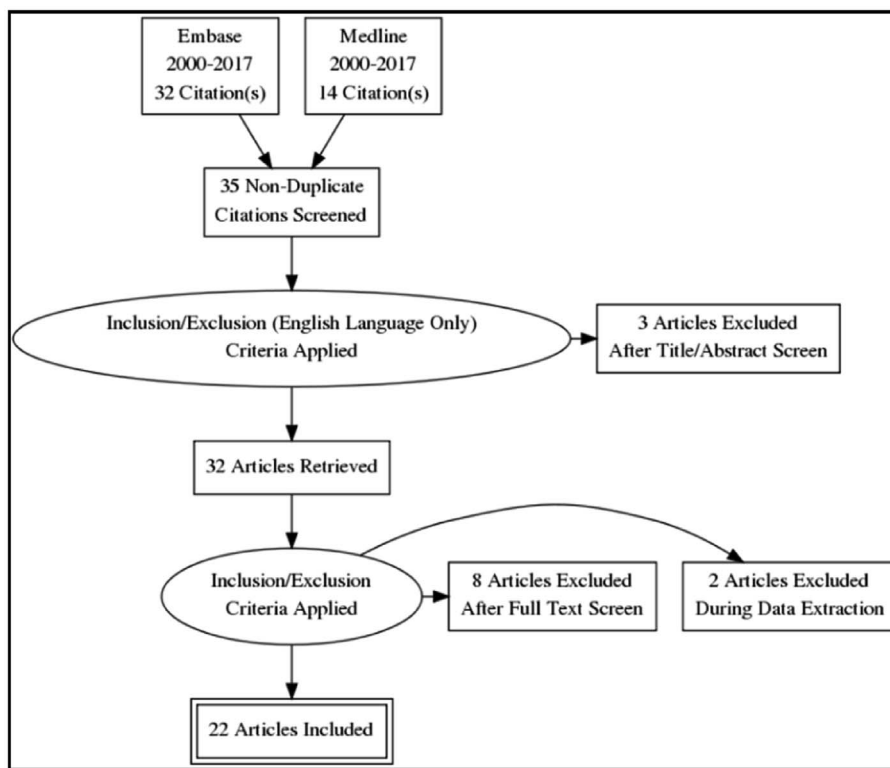


Fig. 1. Database literature search - PRISMA diagram.

range from minimally invasive endoscopy and lithotripsy to a variety of surgical procedures including significant bowel resection or stoma formation. As a result, patient outcomes vary significantly.

Following the successful treatment of an 89 year old female patient with a novel surgical approach after failed trial with endoscopy at our center [7] and two subsequent cases [8] we felt it of benefit to other clinicians and patients to conduct an up-to-date literature review. The aim of this paper is to identify potential trends when managing such patients to help improve patient outcomes.

2. Methods

A literature search of both EMBASE and Medline was conducted. All papers published in English from year January 2000–September 2017 were included to elucidate current practice. The terms ‘gallstone ileus,’ ‘sigmoid,’ ‘colon’ and ‘coelus’ were used. The results are demonstrated in Fig. 1. Hand searches of PubMed and Google Scholar were also included. The work was registered with the research registry (researchregistry3126) and reported in line with PRISMA guidelines [9].

The literature search generated:

The database search yielded 23 results, whilst hand searches revealed 15 additional papers. Thus, a total of 38 papers were included within our literature review (Table 1). All the papers generated from the search were case reports, 2 of which came from a case series (See Table 2). The cases reviewed were all published in English between the years 2000–2017. The reports originated from a range of countries including the UK, USA, Turkey, Greece, Belgium and Italy.

Different aspects relating to management were analysed, these

included; patient age, patient sex, journal, publication date, stone size, length of symptoms, presenting complaint, was computerized tomography undertaken, first line management, subsequent management, emergency/perforation, comorbidities, length of stay and complications. T-test was used to look for any statistical significance between the male and female cohorts where applicable.

Two authors independently reviewed the cases and fed the data into a spreadsheet. If discrepancies arose a 3rd author was utilised to determine the outcome used. Given that the data related to case reports there were no assumptions or simplifications that were required. Where data was not stated it was not included in our review. Reporter bias was considered, however given that the study relates to individual cases this was deemed an inevitable limitation.

3. Results

Patient demographics are presented in Table 3. There were nearly three times more female than male patients reported in the literature. Ages ranged from 65 to 94 years, with a mean age of 81.1 years. Duration of symptoms varied from less than a day to a fortnight. The average length of symptoms prior to presentation was 5.31 days and was not significantly different (*p*-value 0.81) between men and women.

All patients reported were found to have gallstones, with five having had recent episodes of cholecystitis or gallbladder empyema in the preceding months. Diverticulosis was the most commonly found comorbidity, seen in 59% of patients (where co-morbidities were reported). Other comorbidities within this cohort included cardiovascular disease (47%) and cancer (11%). One patient was found to have cholangiocarcinoma with liver metastases during their presentation [10]. Another had previously treated endometrial and breast cancer [11]. A third had endometrial cancer and inoperable oesophageal cancer [12] and another had treated uterine cancer [13]. Other co-morbid conditions are listed in Table 4.

Patients presented in a variety of manners as documented in Table 5. 74% of patients presented with symptoms of abdominal pain,

Table 1

Search results.

Database Searches	23
Hand Searches	15
Total	38

Table 2
Literature search results.

First Author	Year of Publication	Journal
Database Literature Search Results		
Anagnostopoulos	Jan-04	Journal of Postgraduate Medicine
Van Kerschaver	Jul-05	International Journal of Surgery
Versaci	Apr-08	ANZ Journal of Surgery
Valeri	Jul-08	
Osman	Jan-10	HPB Surgery
Zielinski	Mar-10	World Journal of Gastroenterology
Lujan	Aug-10	Surgical Laparoscopy, Endoscopy & Percutaneous Techniques
Ventham	Nov-10	BMJ Case Reports
Ranga	Jan-11	BMJ Case Reports
D'Hondt	Apr-11	Journal of gastrointestinal surgery
Zingales	Sep-11	Updates in Surgery
Patel	Oct-12	American Journal of Gastroenterology
Vaughan-Shaw	Mar-13	BMJ Case Reports
Ball	Nov-13	BMJ Case Reports
Halleran	Jan-14	International Journal of Surgery Case Reports
Ertem	Mar-14	Hepatology International
Mon-Martin	Jun-14	Revista Espanola De Enfermedades Digestivas
Heaney R.M.	Oct-14	BMJ Case Reports
Cargill	Jul-15	BMJ Case Reports
Carlsson	Dec-15	BMJ Case Reports
O'Brien	Mar-17	Case Reports Gastroenterology
Farkas	Sep-17	International Journal of Surgery Case Reports
Farkas	Sep-17	International Journal of Surgery Case Reports
Hand Searched Results		
Maltz	Jun-01	Gastrointestinal Endoscopy
Stewart	Jan-03	Journal of The American College of Surgeons
Ishikura	Sep-05	Surgery
Doddi	Feb-07	Grand Rounds Journal
Qureshi	Mar-09	BMJ Case Reports
Reiss	Apr-09	Clinical Gastroenterology and Hepatology
Schoofs	Jan-10	Journal of the Belgian Society of Radiology
Alkhusheh	Apr-11	International Journal of Case Reports and Images
Athwal	Jan-12	BMJ Case Reports
Muratori	Mar-12	Endoscopy
Salemans	Jul-13	Case Reports in Surgery
Waterland	Jan-14	BMJ Case Reports
Das	Jul-14	Journal of Surgical Case Reports
Balzarini	Mar-15	Case Reports in Gastrointestinal Medicine
Swarbrick	Nov-15	BMJ Case Reports

Table 3
Patient demographics.

	Number	Average Age (years)	Average length of preceding symptoms (days)
Male	8	82.00 (SD 9.89)	5.57 (SD 3.91)
Female	30	80.86 (SD 7.04)	5.25 (SD 3.03)
Overall	38	81.11 (SD 7.59)	5.31 (SD 3.16)
P value		0.71	0.81

whilst 93% of patients had other obstructive symptoms, namely constipation (61%), vomiting (50%) and abdominal distension (26%).

Computed tomography (CT) was the most commonly used modality of investigation and undertaken in all but 4 patients. The majority (n = 31) of stones were found impacted in the sigmoid colon, four were found at the rectosigmoid junction and two in the distal descending colon.

The obstructing gallstones ranged in size from 2.3 cm to 7 cm in their longest dimension. The mean was 4.14 cm, with average stone size

Table 4
Patient comorbidities.

Co-morbidity	Number
Cholelithiasis	38 (100%)
Not documented	4 (11%)
Documented	34 (89%)
●Diverticulosis	20 (59%)
●Cardiovascular disease	16 (47%)
●Cancer	4 (11%)
●Diabetes	3 (9%)
●COPD	1 (4%)
●DVT	1 (4%)
●Hypothyroidism	1 (4%)

Table 5
Presenting complaints.

Presenting Complaint	Number
Abdominal Pain	28 (74%)
Constipation	23 (61%)
Vomiting	19 (50%)
Abdominal Distension	10 (26%)

found in females the same as in males, demonstrating no statistically significant difference (p value = 0.99). In two cases, the stone size was not documented.

The site of the fistula was found to be cholecystocolonic in the majority of cases (87%) although 5 patients (13%) had a cholecysto-duodenal fistula.

Management strategies varied considerably across the papers as highlighted in Fig. 2 and Table 6. In 61% of cases conservative or non-operative management was attempted in the first instance. The latter included lithotripsy and endoscopic retrieval. In the single patient where conservative management was attempted, it was unsuccessful and the patient went on to have a sigmoid resection [12]. The team caring for this patient would have preferred to attempt a non-operative endoscopic approach prior to surgery but they did not have the expertise within their institution to do so.

Non-operative management successfully treated 10/38 (26%) patients. Lithotripsy was most efficacious in non-surgical management as it was successful in all 7 patients (100%) as either a first-line or second-line strategy.

Despite concerted attempts at non-operative management in many centers, 74% of patients required surgical intervention to manage their large bowel obstruction or the complications of sigmoid gallstone ileus.

Eight patients (21%) required emergency procedures as a result of either bowel ischaemia [35] or perforation [11,33,38,42,44]. One perforation was possibly iatrogenic post colonoscopy, although this was not confirmed by the authors [14]. A caecosotomy tube was utilised to decompress the colon (13 cm) prior to colotomy in one patient [42].

The patient reported by Zielinski whose large bowel obstruction resolved following lithotripsy required surgical management a day later, relating to concerns of concurrent biliary sepsis [30]. Salemans et al. highlight concurrent surgical procedures over two days having attempted to defunction the patient initially only for clinical deterioration to warrant further intervention [29].

Despite having the same pathophysiology, the surgical approach elected by the different teams varied considerably as evidenced by Fig. 3. All colonic perforations were managed surgically with a Hartmann's procedure (n = 6), caecosotomy tube was utilised to decompress an impending perforation [42]. The patient with a possible ischaemic segment underwent a transverse loop colostomy having had the stone milked retrograde from the sigmoid colon [35].

Seven patients were managed with a colostomy as urgent procedures. Two were sigmoid colostomies, one open [37] one laparoscopic

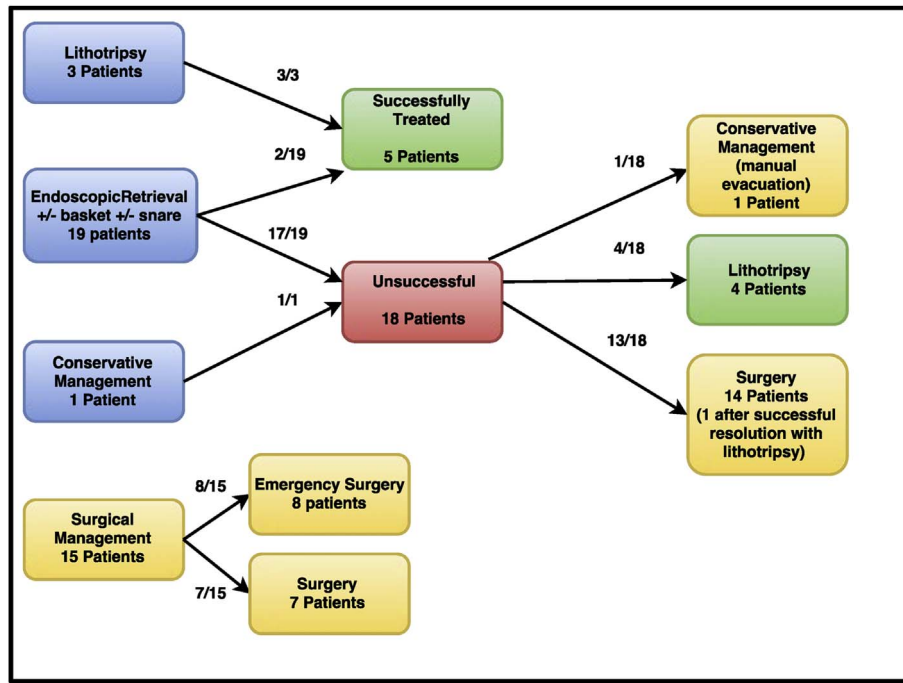


Fig. 2. Flow diagram of management strategies.

[41]. The other cases did not specify the colostomy site [13,17,21,27,28]. O'Brien highlights the use of on table flexible sigmoidoscopy and snare with local anaesthesia to perform an enterotomy and simultaneous trephine loop colostomy [28].

Of the patients managed with an enterolithotomy [7,10,15,19,22,28,39,41–43], two underwent laparoscopic mobilization of the sigmoid colon and enterotomy [16,41] Two were managed with mini-laparotomy and retrograde milking of the gallstone to the caecum with delivery via appendicectomy [7,22], a third via caecotomy [43].

Three patients underwent colonic resections of varying degrees. One had a sigmoid resection [12]. Valeri reports the patient undergoing a total colectomy, ileostomy formation and a contemporaneous cholecystectomy [40]. Patel documents an extended right hemicolectomy, primary anastomosis, proximal ileostomy and fistulectomy being undertaken [36]. Other documented surgery included the successful use of rectal examination with manual evacuation under anaesthesia [8]. Negative diagnostic laparotomy for gallstone ileus resulted in subsequent gallstone sigmoid ileus that eventually resolved spontaneously [8]. One surgical procedure was not specified [15].

On average patients remained in hospital for 10.8 days post-procedure. Patients who were managed non-operatively had shorter hospital stays than those managed surgically (4 days vs. 12.3 days) although this difference did not reach significance (p value = 0.056). There was a paucity of data to evaluate with only 17 papers stating their discharge timings.

No patients died intra-operatively with all obstructions successfully managed. However, five patients (13.1%) died post-procedure during

their admission. Four [10,29,33,36] died following surgical management and one patient after endoscopic lithotripsy [23].

Of these, one died 6 weeks post emergency Hartmann's procedure from a myocardial infarction after a difficult post-operative period [33]. Vaughan-Shaw et al. do not specify the postoperative timeframe to death. The patient had undergone multiple laparotomies for gallstone ileus and subsequent gallstone sigmoid ileus. Acute renal failure, pulmonary embolus, ongoing sepsis and newly diagnosed malignancy (cholangiocarcinoma) were highlighted [10]. The patient reported by Patel died after 17 days as a result of surgical complications (anastomotic break down and respiratory failure) [36]. The patient had undergone an extended right hemicolectomy with primary anastomosis, formation of ileostomy and repair of the cholecystocolonic fistula. Salemans reports a patient who died in the intensive care unit after 1 day following a second laparotomy in as many days. Faecal peritonitis and a necrotic descending colon were identified during the second surgery [29]. The patient managed non-surgically with lithotripsy, died 7 days later in the intensive care unit from pneumonia [23].

4. Discussion

Predictably, patient demographics for sigmoid gallstone ileus are similar to that of the more classical gallstone ileus with elderly women being those most commonly affected. This echoes the fact that the female gender has a compelling association with cholelithiasis, with stone formation twice as likely in women when compared to men [45].

The incidence of gallstone formation, and by extension its complications, increases with age and escalates markedly after the age of 40

Table 6
Conservative and surgical interventions.

Initial Management	Number	Success Rate	Papers	Subsequent Management	Number	Success Rate	Papers
Conservative	1	0/1 (0%)	[12]	Surgery	1		[12]
Endoscopic Retrieval ± basket ± snare	19	2/19 (10.5%)	[7,8,10,14–29]	Conservative	1	1/1 (100%)	[8]
				Lithotripsy ± basket	4	4/4 (100%)	[20,23,24,26]
				Surgery	13		[7,10,14–17,19,21,22,27–30]
Lithotripsy	3	3/3 (100%)	[30–32]				
Surgery	15		[8,11,13,33–44]				

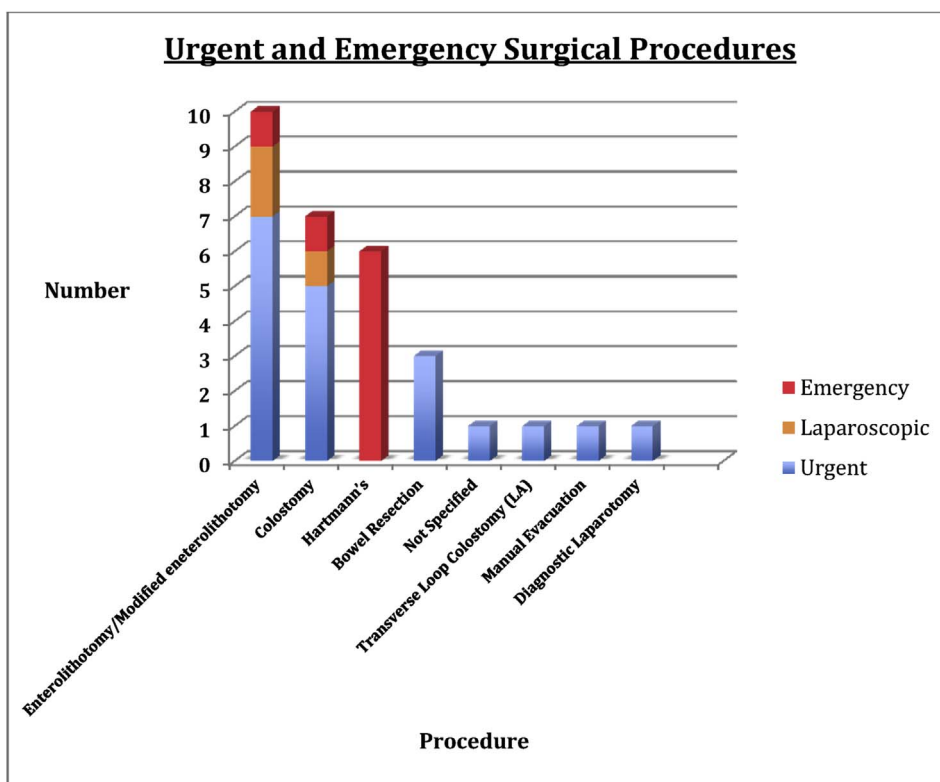


Fig. 3. Graph of urgent and emergency surgical procedures.

[46]. Despite that, it is of note that the youngest patient included in this review was 65 years old and the average age of patients with gallstone sigmoid ileus was 82 years. This is markedly older than the average patient with gallstone disease.

The proposed reason for this may relate to the pathophysiology of cholecystocolonic or cholecystoduodenal fistula formation [47]. They likely evolve sequentially following pericholecystic inflammation associated with cholecystitis leading to the development of adhesions between the gallbladder and the proximal colon or duodenum. Pressure necrosis by the gallstone on the biliary wall causes progressive erosion into the adjacent viscus and the resultant fistula formation. This process requires a significant inflammatory response over a significant duration of time, which may explain the older age at presentation.

The risk of co-morbidities increases as patients advance in age [48]. It is therefore somewhat predictable that a high proportion of the population affected by sigmoid gallstone ileus are affected by other comorbid conditions. Nearly half the cohort (47%) is affected by cardiovascular disease. In addition, it is well recognized that frailty is more prevalent in the older patient [49]. Unsurprisingly, a number of cases state that the care delivered was customized in view of the perceived frailty of the patient [7,21,22,28,43].

Colonic diverticulae were evident in nearly two-thirds (59%) of the patients studied which is expected given the prevalence of diverticulosis increase with age [50]. This is of particular relevance to both the aetiology and management of patients with sigmoid gallstone ileus. Stones may become lodged within a narrowed lumen as a result of diverticular scarring, hypertrophy and stricturing. It is reasonable to suggest that other stricturing or lumen-narrowing conditions such as Crohn's disease or colonic malignancy could also result in gallstone sigmoid ileus, although this was not evident in our review.

Previous episodes of diverticulitis can complicate both endoscopic [51] and surgical management [52] as a result of rigid hypertrophy and luminal stenosis in the former and dense adhesions in the latter. This can result in failed stone retrieval, longer procedure times, further interventions and prolonged duration of symptoms. Our review evidences

this as non-surgical management options failed in 74% of the patients where attempted. One of the most common reason cited was diverticular disease [7].

Evidently diverticulosis plays an important role in determining the most appropriate management. Two of the patients that required de-functioning colostomies following unsuccessful endoscopic attempts had severe diverticular disease [17,21]. Carlsson stated that an obstructing gallstone was left in situ because of patient comorbidities, specifically citing diverticular disease [21]. Two others were managed similarly without diverticulosis. One patient was defunctioned to protect the primary closure of the colostomy whilst the other was due to an irretrievable gallstone [9,29].

Stollman et al. state that 67% of the general population has diverticulosis [53]. Given that the average age of our cohort was 81.1 years with the documented presence of diverticulum being 59%, this potentially significant causative factor may be under reported in the case reports analysed.

Abdominal pain and constipation were the most common symptoms reported by patients (74% and 61% respectively) over 5.31 days on average. Duration of presenting symptoms was longer in this cohort when compared to cases of small bowel obstruction secondary to gallstones [44]. We postulate that this delay is a consequence of more intermittent pain in large bowel obstruction and later onset of distressing symptoms such as nausea and vomiting [54].

Multiple factors including older age, numerous co-morbidities, frailty, delayed presentation, diverticular disease, and the pathophysiology of large bowel obstruction all contributes to the complexities and challenges of managing patients with sigmoid gallstone ileus.

Computerized tomography plays a valuable diagnostic role in patients presenting with large bowel obstruction [1]. Only 4 patients were managed without utilizing CT [11,20,42,43]. CT scanning enables clinicians to diagnose underlying pathology and plan effectively pre-intervention. Given that CT is purely diagnostic, it is not a pre-requisite before surgery in the acutely unwell patient but is highly recommended.

The average size of obstructing gallstone was 4.14 cm. Our review failed to demonstrate a correlation between size of obstructing stone and the success of non-operative management. Success appears multifactorial with comorbidities; luminal narrowing, a centers expertise and a patient's clinical state all playing roles.

Conservative management of large bowel obstruction caused by a gallstone appears dubious as a successful management strategy. The finding that many of the patients had delayed presentations with no resolution of symptoms supports this. Only one case utilised a solely conservative (non-invasive) approach that proved successful [12]. Our cohort represents only reported cases; consequently determining the effectiveness of this strategy is difficult given the paucity of data of conservatively managed patients.

Non-surgical management proved a popular first-line strategy with endoscopic snare or basket retrieval and lithotripsy being utilised. Despite 62% of centers using this approach initially, an overall success rate of 23% highlights a discernible discrepancy in outcomes. Such procedures are not without their own risks as evidenced by one patient, who incurred a likely iatrogenic perforation secondary to colonoscopy [14].

High prevalence of diverticular disease, elderly age and the acute nature of these presentations all predispose patients to a greater risk of perforation [55]. However, where expertise and equipment are available, endoscopy and lithotripsy do appear useful adjuncts.

Operative management varied considerably between patients with no consensus in surgery demonstrated. Twenty-nine patients underwent surgical interventions in total.

The use of minimally invasive surgical approaches either as a primary procedure or following failed endoscopic efforts proved successful. Less invasive approaches infer a number of benefits including reduction in scarring, decreased post-operative pain and shorter hospital stays [56]. This group of patients made uneventful recoveries within our review.

Laparoscopic surgical management is reported as a successful treatment strategy in gallstone sigmoid ileus [16,41]. Although a common elective surgical modality in gallstone disease it appears less utilised when managing the cohort analysed. A number of factors may account for this. A quarter of surgical interventions were as acute emergencies requiring immediate intervention. Elderly patients are more likely to have had previous surgery, consequently adhesions may factor in pre-operative planning. In addition, surgical skillset, facilities and competency vary around the world. Given that some stones measured up to 7 cm in diameter, laparoscopic retrieval compared to modified laparotomy may only complicate and lengthen a potentially difficult operation.

Some centers opted for extensive surgery as first line management or during the acute presentation with varying results [12,29,36,40]. The extensive surgery reported by Patel offers an insight into some of the surgery being undertaken, the operation included an extended right hemicolectomy, takedown of the cholecystocolic fistula, cholecystectomy and primary anastomosis. This patient ultimately required a second laparotomy with end-colostomy formation following anastomotic breakdown, and subsequently died [36].

Vaughan-Shaw highlights the need to consider concurrent stones and whether early treatment of stones other than the obstructing one should be undertaken. Laparotomy and longitudinal enterolithotomy resulted in successful stone extraction initially. However, four months later the patient represented with bowel obstruction attributed to an incisional hernia. Despite hernia repair, symptoms failed to resolve. A second enterolithotomy (3rd operative intervention) followed, however the patient ultimately died [10].

In the acutely unwell patient following colonic perforation, Hartmann's procedure was performed for all patients [11,14,33,34,38,44]. Hartmann's procedure minimizes the risk of leakage and enables effective diversion of faecal matter in a time efficient manner.

Large bowel obstruction in the elderly is known to carry a high post-operative mortality [57]. Given the fragility of such patients, the associated complications of complex surgery and anaesthesia may push already low reserves to their limits. Authors highlighted this along with multiple comorbidities and anaesthetic concerns regarding lengthy operations as major reasons for not undertaking fistula repair or cholecystectomy in the majority of patients [7,8,10].

The patients who died after surgery either underwent multiple laparotomies or had significant bowel resection. Such procedures require long combined anaesthetic times which may have been a contributing factor in the patients' demises post procedure [58].

Although not statistically significant, patients successfully treated non-surgically returned home 8 days sooner than those who underwent surgery. This is unsurprising as one would expect non-surgical patients to have less pain, require less invasive monitoring and mobilise earlier than their counterparts.

Given that many patients had significant comorbidities and were known to have cholelithiasis, determining whether earlier cholecystectomy should have been undertaken is difficult. Undergoing cholecystectomy is not without risk and carries its own associated morbidities and mortality [59]. Girard et al. document a mortality rate of 2.5% and complication rate of 13.8% following elective open cholecystectomy in the over 70 years age group [60]. Nevertheless, there is growing evidence to support the use of laparoscopic cholecystectomy in the elderly [61].

There are a number of limitations to this study. Firstly, with 38 cases reported over the past 15 years around the world, we have a small sample size with inconsistent reporting of co-morbidities, length of hospital stay and outcomes. Given the nature of the publications assessed (case-reports) the weight of evidence is relatively weak. Additionally, over the timespan included in this review, advancements have been made both in surgical and non-surgical fields. Technique and equipment progression may impact on the outcomes reported.

Key Learning Points:

- Large bowel obstruction in the presence of known cholelithiasis and disease causing luminal narrowing e.g. diverticular disease should raise the possible diagnosis of gallstone sigmoid ileus to clinicians.
- Management of sigmoid gallstone ileus should focus on early stone removal and resolution of large bowel obstruction.
- CT scan plays a valuable role in diagnosis and pre-endoscopic/surgical planning and should be performed expeditiously.
- Current literature highlights endoscopy and lithotripsy as practical first-line non-operative strategies in stable patients.
- Stone size is not an indicator as to success of non-operative management.
- There should be a low threshold to proceed to surgery should endoscopy/lithotripsy fail.
- Minimally invasive timesaving surgery should be considered given the many co-morbidities and complexity of this patient cohort.
- Attempts to milk the stone distally or proximally should be considered to avoid or limit bowel resection and the associated complications where possible.
- Surgery should not be delayed in the emergency setting (i.e. perforation or ischaemia).
- In the case of multiple large gallstones (> 2 cm) being found within the bowel, efforts should be made to extract these to prevent future complications based on the documented cases

5. Conclusion

Sigmoid gallstone ileus is a rare potentially life-threatening condition, which often presents insidiously. Early diagnosis and resolution of the obstruction is paramount. There is no management consensus from the literature with regard to conservative or surgical intervention. Current evidence highlights endoscopy and lithotripsy as a practical

first-line strategy. However, surgical intervention should not be delayed should non-operative measures fail or in the emergency setting. Given the complexity of such patients, less invasive timesaving surgery appears a useful solution, avoiding bowel resection and associated complications.

This review highlights a condition seldom seen and provides an up-to-date insight into the management of gallstone sigmoid ileus from around the world. We are able to infer key learning points; however, given the small numbers assessed more definitive advice would be a step too far. Greater data, particularly with regard to overall outcome and follow up would enable the establishment of more conclusive proposals.

Ethical approval

Not required.

Sources of funding

No funding.

Author contribution

NF – data collection, writing paper.
 VK – writing paper, data analysis.
 AS – writing paper.
 JB – data collection.
 CR – data collection.
 AF – data analysis.
 NW – study concept.

Conflicts of interest

No conflicts of interest.

Registration of research studies

researchregistry3126.

Guarantor

Nicholas Farkas.

Consent

Not required.

References

- [1] F. Lassandro, S. Romano, A. Ragozzino, G. Rossi, T. Valente, I. Ferrara, et al., Role of helical CT in diagnosis of gallstone ileus and related conditions, *AJR Am. J. Roentgenol.* [Internet] 185 (2005) 1159–1165. Available from: <http://www.ncbi.nlm.nih.gov/pubmed/16247126>.
- [2] G.E. Gurvits, G. Lan, Enterolithiasis, *World J. Gastroenterol.* [Internet] 20 (2014) 17819–17829. Available from: <http://www.ncbi.nlm.nih.gov/pubmed/25548480>.
- [3] R.M. Reisner, J.R. Cohen, Gallstone ileus - a review of 1001 reported cases, *Am. Surg.* 60 (6) (1994 Jun) 441–446.
- [4] M. Van Hillo, J.A. Van der Vliet, T. Wiggers, H. Obertop, O.T. Terpstra, J.M. Greep, Gallstone obstruction of the intestine: an analysis of ten patients and a review of the literature, *Surgery* 101 (3) (1987) 273–276.
- [5] C. Brown, Colonic obstruction due to a gallstone, *Br. J. Clin. Pract.* 26 (4) (1972) 175.
- [6] P.R. Hession, J. Rawlinson, J.R. Hall, J.P. Keating, P.B. Guyer, The clinical and radiological features of cholecystocolic fistulae, *Br. J. Radiol.* 69 (825) (1996) 804–809.
- [7] A. Cargill, N. Farkas, J. Black, N. West, A novel surgical approach for treatment of sigmoid gallstone ileus, *BMJ Case Rep.* (2015), <http://dx.doi.org/10.1136/bcr-2014-209229> published online 6 July 2015.
- [8] N. Farkas, R. Karthigan, T. Lewis, J. Read, S. Farhat, A. Zaidi, et al., A single centre case series of gallstone sigmoid ileus management file:///Users/nickfarkas/Downloads/europepmc.ris.txt, *Int. J. Surg. Case Rep.* [Internet] 40 (2017 Sep 14) 58–62 Elsevier; Available from: <http://www.ncbi.nlm.nih.gov/pmc/articles/PMC5612792/>.
- [9] D. Moher, A. Liberati, J. Tetzlaff, D.G. Altman, Preferred reporting items for systematic reviews and meta-analyses: the PRISMA statement, *Int. J. Surg.* [Internet] 8 (5) (2018 Jan 6) 336–341, <http://dx.doi.org/10.1016/j.ijsu.2010.02.007> Elsevier; Available from:.
- [10] P.G. Vaughan-Shaw, A. Talwar, Gallstone ileus and fatal gallstone colesus: the importance of the second stone, *BMJ Case Rep.* [Internet] 2013 (2013 Mar 15) bcr2012008008. BMA House, Tavistock Square, London, WC1H 9JR: BMJ Publishing Group; Available from: <http://www.ncbi.nlm.nih.gov/pmc/articles/PMC3618741/>.
- [11] N.A. Qureshi, S. Dua, O. Leonard, F. Myint, Faecal peritonitis secondary to perforated recto sigmoid colon by a large gallstone: a case report, *BMJ Case Rep.* (2009), <http://dx.doi.org/10.1136/bcr.10.2008.1105> published online 17 March 2009.
- [12] F. Zingales, E. Pizzolato, M. Menegazzo, C. Da Re, R. Bardini, Gallstone ileus of the sigmoid colon: a rare complication of cholelithiasis, *Updates Surg.* [Internet] 63 (3) (2011) 219–221, <http://dx.doi.org/10.1007/s13304-011-0057-8> Springer Milan; Available from:.
- [13] H. Ishikura, A. Sakata, S. Kimura, H. Okitsu, M. Ishikawa, T. Ichimori, et al., Gallstone ileus of the colon, *Surgery* [Internet] 138 (3) (2017 Nov 21) 540–542, <http://dx.doi.org/10.1016/j.surg.2004.03.013> Elsevier; Available from:.
- [14] D.R. Halleran, D.R. Halleran, Colonic perforation by a large gallstone: a rare case report, *Int. J. Surg. Case Rep.* [Internet] 5 (12) (2014 Nov 21) 1295–1298 Elsevier; Available from: <http://www.ncbi.nlm.nih.gov/pmc/articles/PMC4276087/>.
- [15] I.S. Ertem, C. Yildiz, Ö.B. Binicier, Gallstone ileus in an elderly patient: a case report, *Hepatol. Int.* 8 (2014).
- [16] R.M. Heaney, Colonic gallstone ileus: the rolling stones [Internet], *BMJ Case Rep.* 2014 (2014) Available from: <http://casereports.bmj.com/content/2014/bcr-2014-204402.full.pdf+html?sid=62ce8480-f37a-4325-b177-74905a497a01%5Cnhttp://ovidsp.ovid.com/ovidweb.cgi?T=JS&PAGE=reference&D=emed12&NEWS=N&AN=2014907647>.
- [17] N. Ranga, Large bowel and small bowel obstruction due to gallstones in the same patient, *BMJ Case Rep.* 2011 (2011) BMJ Publishing Group Ltd; bcr0920103372.
- [18] G.K. Anagnostopoulos, G. Sakorafas, T. Kolettis, N. Kotsifopoulos, G. Kassaras, A case of gallstone ileus with an unusual impaction site and spontaneous evacuation, *J. Postgrad. Med.* 50 (1) (2004) 55 Medknow Publications.
- [19] N.T. Ventham, T. Eves, D. Raje, P. Willson, Sigmoid gallstone ileus: a rare cause of large bowel obstruction, *BMJ Case Rep.* [Internet] 2010 (2010 Nov 5) bcr0420102886. BMA House, Tavistock Square, London, WC1H 9JR: BMJ Publishing Group Available from: <http://www.ncbi.nlm.nih.gov/pmc/articles/PMC3029545/>.
- [20] C. Maltz, J.S. Zimmerman, D.B. Purow, Gallstone impaction in the colon as a result of a biliary-colonic fistula, *Gastrointest. Endosc.* [Internet] 53 (7) (2001 Jun) 776. Available from: <http://www.sciencedirect.com/science/article/pii/S0016510701679501>.
- [21] T. Carlsson, S. Gandhi, Gallstone ileus of the sigmoid colon: an extremely rare cause of large bowel obstruction detected by multiplanar CT, *BMJ Case Rep.* [Internet] 18 (2015 Dec) Available from: <http://casereports.bmj.com/content/2015/bcr-2015-209654.abstract>.
- [22] K. Swarbrick, B. Allin, T. Yeung, M. Sampson, Enterolithotomy for the treatment of large bowel obstruction secondary to gallstones, *BMJ Case Rep.* [Internet] 19 (2014 Nov) Available from: <http://casereports.bmj.com/content/2014/bcr-2014-208167.abstract>.
- [23] M. Alkhusheh, A.F. Tonsi, S. Reiss, E.R.T.C. Owen, K. Reddy, Endoscopic laser lithotripsy for gallstone large bowel obstruction, *Int. J. Case Rep. Images* 2 (4) (2011) 11–14.
- [24] G. Reiss, R. Gopi, S. Ramrakhiani, Unusual cause of colonic obstruction: gallstone impaction requiring mechanical lithotripsy, *Clin. Gastroenterol. Hepatol.* 7 (4) (2009) A20 WB Saunders.
- [25] S. Doddi, N.N. Basu, T. Kamal, T.W. Hennigan, P. Sinha, Large bowel obstruction due to gallstone: “gallstone colesus.”, *Gd. Rounds* 7 (2007) 36–38.
- [26] P. Waterland, F.S. Khan, D. Durkin, Large bowel obstruction due to gallstones: an endoscopic problem? *BMJ Publishing Group Ltd, BMJ Case Rep.* 2014 (2014) bcr2013201652.
- [27] N. Das, N.R. Plummer, H. Raja, A. Vashist, What to do with a non-rolling stone? Surgical on-table dilemma in large bowel obstruction due to an impacted gallstone, *J. Surg. Case Rep.* 2014 (7) (2014) rju042. The Oxford University Press.
- [28] J.W. O'Brien, L.A. Webb, L. Evans, C. Speakman, I. Shaikh, Gallstone Ileus Caused by Cholecystocolonic Fistula and Gallstone Impaction in the Sigmoid Colon: Review of the Literature and Novel Surgical Treatment with Trephine Loop Colostomy. *Case Rep. Gastroenterol.* [Internet]. Allschwilerstrasse 10, P.O. Box · Postfach · Case postale, CH-4009, Basel, Switzerland · Schweiz · Suisse, Phone: +41 61 306 11 11, Fax: +41 61 306 12 34, karger@karger.ch; S. Karger AG; 2017 Mar 3;11(1):95–102. Available from: <http://www.ncbi.nlm.nih.gov/pmc/articles/PMC5465712/>.
- [29] P.B. Salemans, G.F. Vles, S. Fransens, R. Vliegen, M.N. Sosef, Gallstone ileus of the colon: leave No stone unturned, *Case Rep. Surg.* [Internet] 2013 (2013 Jul 22) 359871Hindawi Publishing Corporation: Available from: <http://www.ncbi.nlm.nih.gov/pmc/articles/PMC3736546/>.
- [30] M.D. Zielinski, L.E. Ferreira, T.H. Baron, Successful endoscopic treatment of colonic gallstone ileus using electrohydraulic lithotripsy, *World J. Gastroenterol. WJG* 16 (12) (2010) 1533 WJG Press.
- [31] M. Balzarini, L. Broglia, G. Comi, C. Calcara, Large bowel obstruction due to a big gallstone successfully treated with endoscopic mechanical lithotripsy, *Case Rep. Gastrointest. Med.* 2015 (2015) Hindawi Publishing Corporation.
- [32] R. Muratori, V. Cennamo, M. Menna, P. Cecinato, L.H. Eusebi, G. Mazzella, et al.,

- Colonic gallstone ileus treated with radiologically guided extracorporeal shock wave lithotripsy followed by endoscopic extraction, *Endoscopy*. Germany 44 (Suppl 2) (2012) UCTN: E88-9.
- [33] C. Schoofs, R. Vanheste, L. Bladt, F. Claus, Cholecystocolonic fistula complicated by gallstone impaction and perforation of the sigmoid, *J. Belgian Soc. Radiol.* 93 (1) (2010) Ubiquity Press.
- [34] O. Van Kerschaver, V. Van Maele, L. Vereecken, M. Kint, Gallstone impacted in the rectosigmoid junction causing a biliary ileus and a sigmoid perforation, *Int. Surg.* 94 (1) (2008) 63–66.
- [35] W.R. Ball, M. Elshaieb, M.J. Hershman, Rectosigmoid gallstone colesus: a rare emergency presentation, *BMJ Case Rep.* [Internet] 2013 (2013) Available from: <http://www.ncbi.nlm.nih.gov/pubmed/24225733>.
- [36] P. Patel, T. Raiyani, D. Nunley-Gorman, Deadly gallstone!, *American Journal of Gastroenterology*, Nature Publishing Group, 75 Varick St, 9th Flr, New York, NY 10013-1917 USA, 2012p. S320–S320.
- [37] T.S. Athwal, N. Howard, J. Belfield, U. Gur, Large bowel obstruction due to impaction of a gallstone, *BMJ Case Rep.* [Internet] 2012 (2012 Feb 10) Available from: <http://casereports.bmj.com/content/2012/bcr.11.2011.5100.abstract>.
- [38] M. D'Hondt, A. D'Haeninck, F. Penninckx, Gallstone ileus causing perforation of the sigmoid colon, *J. Gastrointest. Surg.* [Internet] 15 (2011) 701–702. Available from: <http://www.ncbi.nlm.nih.gov/pubmed/21080096>.
- [39] N. Osman, D. Subar, M.-Y. Loh, A. Goscimski, Gallstone ileus of the sigmoid colon: an unusual cause of large-bowel obstruction, *HPB Surg.* 2010 (2010) 1–3.
- [40] S. Valeri, A. Garberini, R. Alloni, R. Coppola, Gallstone ileus: a rare cause of colon obstruction. Report of a case, *Chir. Ital.* [Internet] 60 (2008) 573–576. Available from: <http://www.ncbi.nlm.nih.gov/pubmed/18837260>.
- [41] H.J. Lujan, W.B. Bisland, Two-stage minimally invasive surgical management of colonic gallstone ileus, *Surg. Laparosc. Endosc. Percutan. Tech. United States* 20 (4) (2010 Aug) 269–272.
- [42] D.J. Stewart, D.N. Lobo, J.H. Scholefield, Colonic gallstone ileus, *J. Am. Coll. Surg.* [Internet] 196 (1) (2017 Nov 22) 154, [http://dx.doi.org/10.1016/S1072-7515\(02\)01601-0](http://dx.doi.org/10.1016/S1072-7515(02)01601-0) Elsevier; Available from:.
- [43] A. Versaci, A. Macr, V. Pacil, G. Sfuncia, L.G. Angi, C. Famulari, Gallstone ileus of the colon: a rare surgical emergency, *ANZ J. Surg.* [Internet] 78 (4) (2008 Apr 1) 321–322, <http://dx.doi.org/10.1111/j.1445-2197.2008.04453.x> Blackwell Publishing Asia; Available from:.
- [44] F. Mon-Martín, A. Morales-Hernández, L.J. Delgado-Plasencia, A. Alarcó-Hernández, Gallstone ileus and intestinal perforation secondary to sigmoid diverticulum, *Rev. Esp. Enferm. Dig.* [Internet] 106 (6) (2014) 431–433. Available from: <http://europemc.org/abstract/MED/25361459>.
- [45] H.H. Wang, M. Liu, D.J. Clegg, P. Portincasa, D.Q.-H. Wang, New insights into the molecular mechanisms underlying effects of estrogen on cholesterol gallstone formation, *Biochim. Biophys. Acta* [Internet] 1791 (11) (2009 Nov 6) 1037–1047. Available from: <http://www.ncbi.nlm.nih.gov/pmc/articles/PMC2756670/>.
- [46] E.A. Shaffer, Epidemiology and risk factors for gallstone disease: has the paradigm changed in the 21st century? *Curr. Gastroenterol. Rep.* 7 (2) (2005) 132–140 Springer.
- [47] R. Costi, B. Randone, V. Violi, O. Scatton, L. Sarli, O. Soubrane, et al., Cholecystocolonic fistula: facts and myths. A review of the 231 published cases, *J. Hepatobiliary Pancreat. Surg.* 16 (1) (2009) 8–18 Wiley Online Library.
- [48] E. Ickowicz, Guiding principles for the care of older adults with multimorbidity: an approach for clinicians, *J. Am. Geriatr. Soc.* 60 (10) (2012) E1–E25 WILEY-BLACKWELL 111 RIVER ST, HOBOKEN 07030-5774, NJ USA.
- [49] A. Clegg, J. Young, S. Iliffe, M.O. Rikkert, K. Rockwood, Frailty in elderly people, *Lancet* 381 (9868) (2013) 752–762 Elsevier.
- [50] E.J. McConnell, D.J. Tessier, B.G. Wolff, Population-based incidence of complicated diverticular disease of the sigmoid colon based on gender and age, *Dis. Colon Rectum* 46 (8) (2003) 1110–1114 Springer.
- [51] T.N. Witte, R. Enns, The difficult colonoscopy, *Can. J. Gastroenterol.* 21 (8) (2007) 487 Pulsus Group.
- [52] S.Q. Nguyen, C.M. Divino, A. Vine, M. Reiner, L.B. Katz, B. Salky, Laparoscopic surgery for diverticular disease complicated by fistulae, *JSLJ J. Soc. Laparoendosc. Surg.* 10 (2) (2006) 166 Society of Laparoendoscopic Surgeons.
- [53] N. Stollman, J.B. Raskin, Diverticular disease of the colon, *Lancet* 363 (9409) (2004) 631–639 Elsevier.
- [54] A.A. Ayantunde, A. Agrawal, Gallstone ileus: diagnosis and management, *World J. Surg.* [Internet] 31 (6) (2007) 1294–1299, <http://dx.doi.org/10.1007/s00268-007-9011-9> Available from:.
- [55] V. Lohsiriwat, Colonoscopic perforation: incidence, risk factors, management and outcome, *World J. Gastroenterol.* [Internet] 16 (4) (2010 Jan 28) 425–430. The WJG Press and Baishideng; Available from: <http://www.ncbi.nlm.nih.gov/pmc/articles/PMC2811793/>.
- [56] R.E. Glasgow, K.A. Adamson, S.J. Mulvihill, The benefits of a dedicated minimally invasive surgery program to academic general surgery practice, *J. Gastrointest. Surg.* 8 (7) (2004) 869–873 Springer.
- [57] S. Biondo, D. Parés, R. Frago, J. Martí-Ragué, E. Kreisler, J. De Oca, et al., Large bowel obstruction: predictive factors for postoperative mortality, *Dis. Colon Rectum* 47 (11) (2004) 1889–1897 Springer.
- [58] C. Strøm, L.S. Rasmussen, F.E. Sieber, Should general anaesthesia be avoided in the elderly? *Anaesthesia* 69 (s1) (2014) 35–44 Wiley Online Library.
- [59] D. Hazzan, N. Geron, D. Golijanin, P. Reissman, E. Shiloni, Laparoscopic cholecystectomy in octogenarians, *Surg. Endosc. Other Interv. Tech.* 17 (5) (2003) 773–776 Springer.
- [60] R.M. Girard, M. Morin, Open cholecystectomy: its morbidity and mortality as a reference standard, *Can. J. Surg.* 36 (1) (1993) 75–80.
- [61] R. Dennis, R. Guy, F. Bajwa, Laparoscopic cholecystectomy in patients over 80 years is feasible and safe: analysis of 68 consecutive cases, *World J. Surg.* 23 (2) (2009) 22–25.