

Review Article

Open Access

Valentina Giudice, Rosa Rosamilio, Bianca Serio, Rosa Maria Di Crescenzo, Francesca Rossi, Amato De Paulis, Vincenzo Pilone, Carmine Selleri*

Role of Laparoscopic Splenectomy in Elderly Immune Thrombocytopenia

DOI 10.1515/med-2016-0066

received August 10, 2016; accepted August 19, 2016

Abstract: The management of older patients with chronic primary immune thrombocytopenia (ITP) is still very challenging because of the fragility of older patients who frequently have severe comorbidities and/or disabilities. Corticosteroid-based first-line therapies fail in most of the cases and patients require a second-line treatment, choosing between rituximab, thrombopoietin-receptor agonists and splenectomy. The choice of the best treatment in elderly patients is a compromise between effectiveness and safety and laparoscopic splenectomy may be a good option with a complete remission rate of 67% at 60 months. But relapse and complication rates remain higher than in younger splenectomized ITP patients because elderly patients undergo splenectomy with unfavorable conditions (age >60 year-old, presence of comorbidities, or multiple previous treatments) which negatively influence the outcome, regardless the hematological response. For these reasons, a good management of concomitant diseases and the option to not use the splenectomy as the last possible treatment could improve the outcome of old splenectomized patients.

Keywords: Immune thrombocytopenia; Splenectomy; Laparoscopy; Elderly

*Corresponding author: Carmine Selleri, Hematology and Transplant Center, Department of Medicine and Surgery, University of Salerno, Salerno, 84131, Italy, Tel.: +39 089673150, mobile: 3356166591, E-mail: cselleri@unisa.it

Valentina Giudice, Rosa Rosamilio, Bianca Serio, Vincenzo Pilone, Department of Medicine and Surgery, University of Salerno, Baronissi, Italy

Rosa Maria Di Crescenzo, Division of Pathology Second University of Naples, Naples, Italy

Amato De Paulis, Francesca Rossi, Department of Translational Medical Sciences, University of Naples Federico II, Naples, Italy

1 Introduction

Primary immune thrombocytopenia (ITP) is an acquired hematologic disorder characterized by isolated peripheral thrombocytopenia (platelet count <100 x 10⁹/L) in the absence of any other underlying disease [1-5]. Mostly, ITP is caused by the production of autoantibodies against platelet surface markers, leading to the increase of phagocytosis by the reticuloendothelial system, mainly present in the red pulp of the spleen [4,6]. The incidence of ITP is around 4 per 100,000 people per year [7] with a peak of 9 per 100,000 yearly in people over 60 years old. The yearly risk of fatal bleeding increases with age at a rate of 13% per annum for patients over 60 years old [3,7-8]. For these reasons, the correct diagnosis and the choice of the best treatment are important for a good management of these patients. Though the criteria are simple, the diagnosis of ITP is still very challenging, especially in older patients, because of the absence of specific recommendations and the priority to exclude other diseases which can mimic ITP in the elderly, such as myelodysplastic syndromes or drug-induced ITP (Table 1) [3].

In absence of bleeding symptoms and a platelet count $\geq 50 \times 10^9/L$, observation alone can be preferred, while a treatment is required when platelets are less than $30 \times 10^9/L$. ITP patients with platelet count from 30 to $50 \times 10^9/L$ are considered for treatment in the following circumstances: 1) if older than 65 year-old, 2) in the presence of bleeding symptoms or history of bleeding, 3) presence of severe comorbidities such as hypertension which may cause intracranial hemorrhage, 4) poor health-related quality of life, 5) concomitant anticoagulation therapy with antiplatelet agents, or 6) if the patient requires a surgical procedure [1,3-5,7,9-12]. In all of these cases, a short-course of corticosteroids is recommended with a response rate of 70-80% [3-4,7]. The most used drug is prednisone at 1-2 mg/Kg/day for 4 weeks, but side effects such as gastritis, hyperglycemia, psychosis, hypertension and infections are commonly reported and underestimated [3-5,9,13-15]. To minimize the corticosteroid-related complications,

Table 1: Criteria for diagnosis of ITP [4-5]

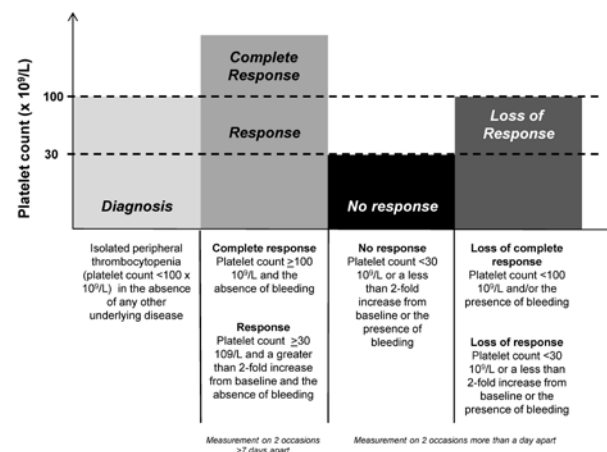
<p>Platelet count < 100 x 10⁹/L Presence of circulating antiplatelet antibodies Plasma TPO level normal or minimally elevated</p>
<p>Bleeding symptoms:</p> <ul style="list-style-type: none"> – Absent in 40% of cases, especially in younger and with platelets > 50 x 10⁹/L – Mucocutaneous bleeding, as widespread petechiae or ecchymosis, gum bleeding, or blood blisters in mouth – Menorrhagia in women – Major bleeding as intracranial hemorrhage, more frequent in elderly with co-morbidities and/or platelets < 30 x 10⁹/L [7]
<p>Absence of:</p> <p>Constitutional symptoms, as significant weight loss, bone pain, or night sweats Hepatosplenomegaly Lymphadenopathy Stigmata of congenital disorders</p>
<p>Exclusion of underlying diseases:</p> <p>HCV, HIV, <i>H. pylori</i>, CMV, or VZV infections Liver disease Myelodysplastic syndromes Lymphoproliferative disorders Autoimmune diseases, as systemic erythematosus lupus, antiphospholipid syndrome or Evans syndrome Drug-induced, as acetaminophen or amiodarone (for a more detailed list of drugs, see Mahévas <i>et al.</i> [3])</p>

Abbreviations. TPO: thrombopoietin; HCV: hepatitis C virus; HIV: human immunodeficiency virus; *H. pylori*: *Helicobacter pylori*; CMV: cytomegalovirus; VZV: varicella-zoster virus.

dexamethasone at 40 mg/day for 4 days has been used with a response rate of 50% [3,5,16-17]. In cases of very low platelet count and severe bleeding, the administration of intravenous immunoglobulin can be added at lower doses (0.4 – 0.5 g/Kg for 4-5 days) with pre- and post- infusion hydration to reduce the risk of thrombosis, pulmonary edema and acute renal failure [3,12,18-22].

After treatment, patients could achieve a complete response (CR) or response (R), according to the criteria proposed by the International Working Group and the 2011 American Society of Hematology (ASH) guidelines, or they could experience no response (NR), or a loss of CR or R when corticosteroids are tapered or stopped (Figure 1) [5]. In these cases, a second-line therapy, such as splenectomy, rituximab and thrombopoietin receptor agonists (TPO-RAs), may be considered to maintain a safe level of platelet count and a low risk of bleeding [4-5,23-26]. Several studies have also shown the efficacy of danazol as a good alternative in older women with a response rate of 57-67% [3,27-28].

In this review, we focused on the role of splenectomy as second-line therapy in ITP patients and, in particular, on the effectiveness of laparoscopic splenectomy in the management of chronic ITP in older subjects.

**Figure 1:** 2011 ASH criteria for ITP treatment response.

2 Literature analysis

2.1 Search strategy and inclusion and exclusion criteria

Relevant literature was searched in PubMed database, from 1946 to July 2016. The key words for searches were “Splenectomy” and “Primary immune thrombocytopenia”. Limiting factors were “elderly” or “adult”, and

“English language”. Two investigators independently scanned, reviewed and chose from reference list all the potentially eligible abstracts and full text of articles for the review. Next, the eligible articles were reviewed independently for inclusion into the final analysis. Studies were included when they met the following criteria: (1) the date of publication was not earlier than 2000; (2) the article reported data collected since 1980.

From selected articles, data was collected into a standardized form for basic characteristics including publication year, source and time of cohort enrollment, study design, age, sex, number of enrolled patients divided by age and type of surgery, first-line therapies, time to splenectomy, platelet count before splenectomy, and vaccinations (Table 2 and 3). For the outcome the following parameters were considered: overall response rate (ORR, defined as CR+R) and relapse, the number of postoperative days, early and late complications, surgery-related mortality, red blood cell (RBC) transfusions and follow-up time.

2.2 Statistical Analysis

All data was collected from a computerized database and chart review and was analyzed using GraphPad Prism version 6.

Table 2: Baseline characteristics of included studies

Author and year	Study design	Multicenter (number of centers)	Source	Number of splenectomies (Male/Female)	Patient age (years, range)	Date of cohort
Gonzales-Porras J.R. et al., 2013 [30]	Retrospective	Yes (12)	Spain	57 (27/30)	>65	1982 – 2011
Park Y.H. et al., 2016 [29]	Retrospective	Yes (5)	Korea	52 (11/41)	66, 60 -77	1998 – 2013

Table 3: Preoperative characteristics

	Gonzales-Porras et al.	Park et al.
Median time to splenectomy	13 months (3-54.5)	58 months (0-146)
Number of prior treatments	2 (1-3)	2 (1- ≥3)
Operative technique		
Open	31 (54%)	5 (9.6%)
Laparoscopy	26 (46%)	47 (90.4%)
Platelet count (x10 ⁹ /L)	43 (16-82)	60 (2-347)
Vaccinations		
<i>Pneumococcus</i>	52 (91%)	46 (88.5%)
Platelet transfusion	n.r.	9.5

3 Results

3.1 Study selection

A total of 2136 articles were screened and 50 of these were identified as eligible for review. We excluded 28 articles because they did not meet the selection criteria. Of the remaining 22 articles, 7 were chosen for relevance and for the use of “Laparoscopic” as limiting factor. Five articles were excluded because the median age of the cohort was less than 60 year-old or the results were not divided according to the age. Figure 2 shows the flow diagram for the selection process. A total of 2 articles were finally included in the analysis [29-30].

3.2 Pre-operative characteristics

From 1982 to 2013, a total of 109 splenectomies in older ITP patients (male/female, 38/71; age ≥ 60 year-old) were described in selected retrospective studies (Table 2), performed with open technique in 33% of cases (n=36) and laparoscopic procedure in 67% of subjects (n=73) (Table 3). The comorbidities were described differently in each study: as median Charlson index of 4.1 as in Gonzales-Porras et al. or as 84.6% of patients with underlying

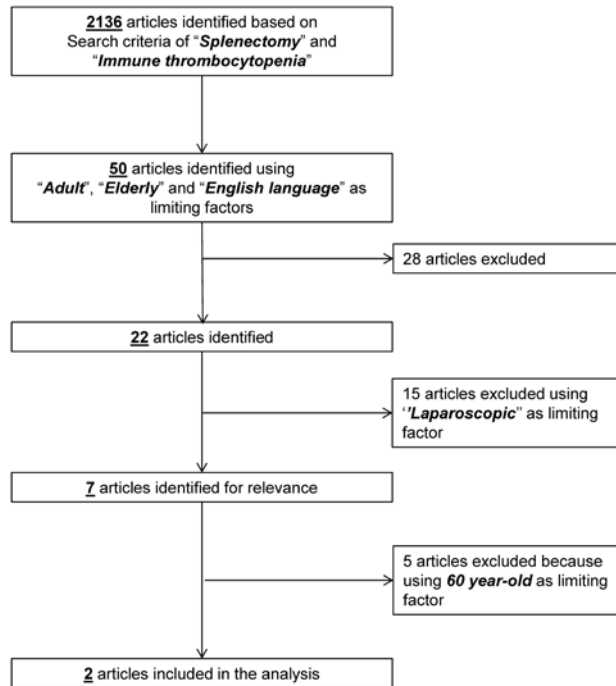

Figure 2: Flow diagram of search strategy

diseases (mostly cardiovascular diseases or diabetes) as in Park *et al.* Patients underwent splenectomy after a median time from diagnosis of 35.5 months (varying from 0 to 146 months) and a median number of prior treatments of 2 (range, 1 to more than 3). Pneumococcal vaccination was performed in 89.9% of patients ($n=98$) at least two weeks before surgery. The median preoperative platelet count was $51.5 \times 10^9/L$ (range, 2 – $347 \times 10^9/L$).

3.3 Surgical procedure

Laparoscopic splenectomy could be performed using a lateral or anterior approach, preferred for very large spleens. The operation starts with safe laparoscopic abdominal access using open or closed technique with a Verres needle (contraindicated in patients with massive splenomegaly and severe thrombocytopenia). Once the peritoneal cavity is accessed, 4-5 trocars are positioned: the first (5 or 12 mm port) in the midclavicular line at 2-6 cm below the costal margin; the second medial trocar in the midline subxiphoid region in the left subcostal position; the third in the anterior axillary line in the left subcostal region; the fourth laterally off the tip of the 11th rib. The port with the best angle for hilar ligation could be used as a 12 mm port for the endoscopic stapler and for the extraction of the spleen. Preliminary to the proce-

dure, accessory spleens have to be looked for in the hilum, omentum, mesocolon or mesentery. Dissection starts from the inferior pole of the spleen with the section of the splenocolic, splenorenal and gastrosplenic ligaments. After this, the splenic hilum is accessible and the splenic artery can be controlled, proximal to the splenic hilum (1-2 cm), along the superior border of the pancreas; otherwise the splenophrenic ligament can be divided superiorly. Then the hilum is carefully dissected from the tail of pancreas and splenopancreatic ligament. Now, the splenic vasculature can be ligated and divided and the spleen can be grasped from the splenocolic ligament left on the inferior border and flipped with the hilum facing up. The spleen is ready to be placed in a retrievable sac and morcellated, unless the spleen must be removed intact for pathologic analysis. During the morcellation phase, it is important to not break the bag and spill the splenic tissue into the peritoneal cavity. When the morcellation cannot be performed, the spleen could be removed through a Pfannenstiel suprapubic access. After removal, hemostasis must be evaluated; suction drains are placed, the abdomen is reinsufflated and the skin incisions are closed [31-38].

3.4 Outcome and complication rate

Splenectomized patients experienced a median postoperative stay of 8 days (range, 4–52 days). The median follow-up was 60 months (range, 0–146 months). Using the 2011 ASH criteria for ITP treatment response, 73 patients (67%) achieved a complete response (CR) after splenectomy and 14 subjects (13%) a response (R), for an overall response rate (ORR) of 80%. Nineteen percent of patients ($n=21$) did not respond to treatment, and 39% ($n=43$) relapsed after surgery (Table 4).

Table 4: Response after splenectomy

	Gonzales-Porras <i>et al.</i>	Park <i>et al.</i>
Postoperative days	8 (6-14)	9.5 (4-52)
CR (%)	41 (71.9)	32 (61.5)
R (%)	4 (7)	10 (19.2)
ORR (%)	45 (78.9)	42 (80.7)
NR (%)	12 (7.5)	9 (17.3)
Relapse (%)	24 (42.9)	19 (45.2)
Follow-up (months)	62 (27-113)	58 (0-146)
PFS (months)	>42	3

Abbreviations. CR: complete response; R: response; ORR: overall response rate; NR: no response; PFS: progression-free survival.

Operative mortality was assessed at 2% (n=2), but one death was related to an intracranial hemorrhage 5 days post- splenectomy. The complication rate was 48% (n=52) and early or late bleeding was the most frequent complication (48% of all postoperative events, n=25). Other frequent complications were infections (29%, n=15), late thrombotic events (13%, n=7), and subphrenic abscess (8%, n=4). Cardiovascular events were reported at very low frequency (2%, n=1 as paroxysmal atrial fibrillation).

Red blood cell transfusions were performed in a median of 16 splenectomized patients (0-16) (Table 5 and Figure 3).

4 Discussion

Diagnosis and management of ITP are still very challenging in older patients because of the lack of guidelines [3,39-41]. Treatment is required for patients older than 65 years with a platelet count less than 50 x 10⁹/L, and/

or when bleeding symptoms, severe comorbidities, severe disabilities or anticoagulation therapy are reported [3]. First-line therapies include short-course corticosteroids with or without low-dose intravenous immunoglobulins (IVIg), but are not effective for a sustained response, since most patients relapse after tapering off or stopping therapy [4-5,23-26,39-41]. For this reason, adult, especially elderly, ITP patients develop chronic ITP with a very-high yearly risk of fatal bleeding [3,7-8]. International guidelines equally suggest the use of splenectomy, rituximab and TPO-RAs as second-line therapy, with the option to switch from one to another in case the previous treatment should fail [4-5,23-26,39-45].

Given the increasingly frequent use of less invasive techniques, such as the fine-needle aspiration biopsy, splenectomy is less and less used in malignant hematological disorders for diagnostic purposes [46-51], but is still used for palliation or to facilitate drug therapy [43-45]. Conversely, splenectomy so far is a key treatment option in hematological benign disorders such as ITP, autoimmune hemolytic anemia, hereditary spherocytosis and some types of hemoglobinopathies and thalassemia [45]. Among the benign hematological disorders, one of the most frequent indications for splenectomy is definitely ITP [42,45]. In children, the 2011 ASH guidelines recommend delaying splenectomy until the chronic phase (>12 months), unless severe disease is unresponsive to other treatments or causes a poor quality of life [4,5]. Together with the higher postoperative complication rate and mortality of major surgery in adults due to comorbidities, splenectomy is usually the third choice in elderly patients and is delayed for longer than the recommended 12 months (median, 35.5 months), as we highlighted in the two selected studies [29,30].

Several reviews reported a complete remission rate (CRr) after splenectomy of 66% at 28 months (range, 1 – 153 months) in children and adults, or of 64% at 7.25 years (range, 5 – 12.75 years) only in adults, or of 72% at 5 years only in patients who received laparoscopic splenectomy. Two limitations of this data set are the definition of “adult” which contains a wide range of patients up to 18 years old and the combination of data from children and adults [42]. The two studies included in our series focused on small cohorts of patients older than 60 years but CRr and ORR were similar to the general splenectomized population (67% at 60 months and 80% vs 88% of all splenectomies, respectively). Gonzales-Porras et al. and Park et al. described a relapse rate in elderly patients of 39%, 2.5-fold higher than the general splenectomized population (15%; range, 0 – 51%) [29,30]. Therefore, these findings suggest that splenectomies in elderly patients could not be used

Table 5: Postoperative complications

	Gonzales-Porras et al.	Park et al.
Any complications	31	21
Bleeding	16	9
Infections	11	4
Cardiovascular events	0	1
Subphrenic abscess	3	1
Thrombotic events	1	6
RBC transfusion	16	0 (0-10)
Operative mortality	1	1

Abbreviations. RBC: red blood cells.

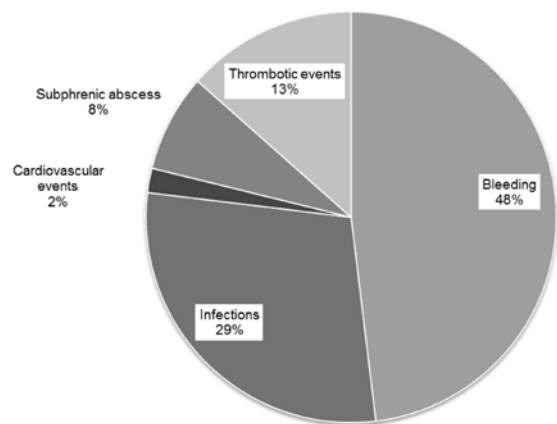


Figure 3: Complication rate in elderly splenectomized ITP patients.

a “definitive” treatment as it is in younger patients [42]. On the other hand, the authors suggested that the higher relapse rate is negatively influenced by the older age (≥ 65 year-old) and lack of response to prior treatments [29,30]. Indeed, several studies showed that an age of < 50 years old and the response to previous therapies are favorable predictive factors for hematological remission after splenectomy [6,42]. Gonzales-Porras *et al.* confirmed these reports because the highest relapse rate was found in older patients who received several treatments before splenectomy. The 30-day mortality in laparoscopic and open splenectomy was assessed at 0.2% and 1% respectively in the general ITP population, similar to the rate observed in our series of older patients (1%), and is not related to the type of surgery [42].

Due to their comorbidities, mostly diabetes and cardiovascular diseases, older patients more frequently experience postoperative complications, which may negatively affect the outcome regardless of the underlying disease [3,52-54]. The complication rate in all splenectomies was assessed at 9.6% for laparoscopy and 12.9% for laparotomy, 10- and 4-fold lower respectively than the reported older cohorts [42]. Early and late bleedings are the most frequent complications in younger, adult and older patients, and the risk was not related to the use of anti-aggregation agents [3,42]. Interestingly, in older ITP patients, the infection rate was 13.8%, higher than the 3-10% of all splenectomies, even if 89.9% of patients received at least pneumococcal immunization prior to surgery [3,55]. These findings support the hypothesis that splenectomy deregulates the immune system which becomes less efficient at removing encapsulated bacteria or other pathogenic particles in peripheral blood, increasing the frequency of recurrent bacterial and viral infections and the risk of overwhelming sepsis [54]. This susceptibility may be highlighted in elderly patients because of their comorbidities and older age, explaining the higher infection rate reported in this population after splenectomy. Thromboembolic events represent the most frequent late complications: up to 70% of splenectomized patients experienced a portal vein thrombosis of unknown clinical significance, because in most cases therapy was not necessary [2,56]. Major events were documented in 10% of all cases, as well as in elderly cases (6%) [42].

As favorable predictive factors for response to splenectomy, several studies suggest the use of preoperative platelet count, though Gonzales-Porras *et al.* did not report a significant correlation between higher preoperative platelet count and complete remission after splenectomy [6,29-30]; instead a higher postoperative platelet

count may better predict the hematological response after surgery [29].

5 Conclusion

The management of older patients with chronic ITP is still challenging because of the presence of severe comorbidities and/or disabilities that influence the choice of the best treatment, which becomes a compromise between effectiveness and safety. As second-line therapy, laparoscopic or open splenectomy could be chosen as “curative” strategy in younger patients and women who contemplate pregnancy with higher complete response rates and low complication frequencies. Older patients undergoing splenectomy already have unfavorable conditions (age > 60 year-old, presence of comorbidities, or multiple previous treatments) which negatively influence the outcome, increasing the relapse and complication rates. For these reasons, a good management of concomitant diseases and the option not to use splenectomy as the last possible chance could improve the outcome of older splenectomized patients who, nevertheless, show a response rate similar to general ITP population after surgery. However, these results require further validation in prospective or randomized larger studies.

Funding: This research did not receive any specific grant from funding agencies in the public, commercial, or not-for-profit sectors.

Conflict of interest statement: Authors state no conflict of interest.

References

- [1] Rodeghiero F., Stasi R., Gernsheimer T., Michel M., Provan D., Arnold D.M., *et al.*, Standardization of terminology, definitions and outcome criteria in immune thrombocytopenic purpura of adults and children: report from an international working group, *Blood.*, 2009, 113, 2386-2393
- [2] Ghanima W., Godeau B., Cines D.B., Bussel J.B., How I treat immune thrombocytopenia: the choice between splenectomy or a medical therapy as a second-line treatment, *Blood.*, 2012, 120, 960-969
- [3] Mahévas M., Michel M., Godeau B., How we manage immune thrombocytopenia in the elderly, *Br J Haematol.*, 2016, 173, 844-856
- [4] Neunert C.E., Current management of immune thrombocytopenia, *Hematology Am Soc of Hematol Educ Program.*, 2013, 276-282

- [5] Neunert C., Lim W., Crowther M., Cohen A., Solberg L., Crowther M.A., The American Society of Hematology 2011 evidence-based practice guideline for immune thrombocytopenia, *Blood.*, 2011, 117, 4190-4207.
- [6] Duperier T., Brody F., Felsher J., Walsh R.M., Rosen M., Ponsky J., Predictive factors for successful laparoscopic splenectomy in patients with immune thrombocytopenic purpura, *Arch Surg.*, 2004, 139, 61-66
- [7] Provan D., Stasi R., Newland A.C., Blanchette V.S., Bolton-Maggs P., Bussel J.B., et al., International consensus report on the investigation and management of primary immune thrombocytopenia, *Blood.*, 2010, 115, 168-186
- [8] Moulis G., Palmaro A., Montastruc J.L., Godeau B., Lapeyre-Mestre M., Sailler L., Epidemiology of incident immune thrombocytopenia: a nationwide population-based study in France, *Blood.*, 2014, 124: 3308-3315
- [9] Cortelazzo S., Finazzi G., Buelli M., Molteni A., Viero P., Barbui T., High risk of severe bleeding in aged patients with chronic idiopathic thrombocytopenic purpura, *Blood.*, 1991, 77, 31-33
- [10] Portielje J.E., Westendorp R.G., Kluijn-Nelemans H.C., Brand A., Morbidity and mortality in adults with idiopathic thrombocytopenic purpura, *Blood.*, 2001, 97, 2549-2554
- [11] Bourgeois E., Caulier M.T., Delarozee C., Brouillard M., Bauters F., Fenaux P., Long-term follow-up of chronic autoimmune thrombocytopenic purpura refractory to splenectomy: a prospective analysis, *Br J Haematol.*, 2003, 120, 1079-1088
- [12] Michel M., Rauzy O.B., Thoraval F.R., Languille L., Khellaf M., Bierling P., et al., Characteristics and outcome of immune thrombocytopenia in elderly: results from a single center case-controlled study, *Am J Hematol.*, 2011, 86, 980-984
- [13] Gentile M., Zirikli K., Ciolli S., Mauro F.R., Di Renzo N., Mastrullo L., et al., Combination of bendamustine and rituximab as front-line therapy for patients with chronic lymphocytic leukaemia: multicenter, retrospective clinical practice experience with 279 cases outside of controlled clinical trials, *Eur J Cancer.*, 2016, 60, 154-165
- [14] Daou S., Federici L., Zimmer J., Maloisel F., Serraj K., Andrès E., Idiopathic thrombocytopenic purpura in elderly patients: a study of 47 cases from a single reference center, *Eur J Intern Med.*, 2008, 19, 447-451
- [15] Tamez-Pérez H.E., Quintanilla-Flores D.L., Rodríguez-Gutiérrez R., González-González J.G., Tamez-Peña A.L., Steroid hyperglycemia: Prevalence, early detection and therapeutic recommendations: A narrative review, *World J Diabetes.*, 2015, 6, 1073-1081
- [16] Cheng Y., Wong R.S., Soo Y.O., Chui C.H., Lau F.Y., Chan N.P., et al., Initial treatment of immune thrombocytopenic purpura with high-dose dexamethasone, *N Engl J Med.*, 2003, 349, 831-836
- [17] Mazzucconi M.G., Fazi P., Bernasconi S., De Rossi G., Leone G., Gugliotta L., et al., Therapy with high-dose dexamethasone (HD-DXM) in previously untreated patients affected by idiopathic thrombocytopenic purpura: a GIMEMA experience, *Blood.*, 2007, 109, 1401-1407
- [18] Ahsan N., Intravenous immunoglobulin induced-nephropathy: a complication of IVIG therapy, *J Nephrol.*, 1998, 11, 157-161
- [19] Carbone J., Adverse reactions and pathogen safety of intravenous immunoglobulin, *Curr Drug Saf.*, 2007, 2, 9-18
- [20] Khellaf M., Michel M., Schaeffer A., Bierling P., Godeau B., Assessment of a therapeutic strategy for adults with severe autoimmune thrombocytopenic purpura based on a bleeding score rather than platelet count, *Haematologica.*, 2005, 90, 829-832
- [21] Godeau B., Chevret S., Varet B., Lefrère F., Zini J.M., Bassompierre F., et al., Intravenous immunoglobulin or high-dose methylprednisolone, with or without oral prednisone, for adults with untreated severe autoimmune thrombocytopenic purpura: a randomised, multicentre trial, *Lancet.*, 2002, 359, 23-29
- [22] Fiorelli A., Petrillo M., Vicidomini G., Di Crescenzo V.G., Frongillo E., De Felice A., et al., Quantitative assessment of emphysematous parenchyma using multidetector-row computed tomography in patients scheduled for endobronchial treatment with one-way valves, *Interact Cardiovasc Thorac Surg.*, 2014, 19, 246-255
- [23] Mahevas M., Gerfaud-Valentin M., Moulis G., Terriou L., Audia S., Guenin S., et al., A Multicenter, Case-Control Study Evaluating the Characteristics and Outcome of ITP Patients Refractory to, Rituximab, Splenectomy and Both TPO Receptor Agonists, *Blood.*, 2015, 126
- [24] Khellaf M., Michel M., Quittet P., Viillard J.F., Alexis M., Roudot-Thoraval F., et al., Romiplostim safety and efficacy for immune thrombocytopenia in clinical practice: 2-year results of 72 adults in a romiplostim compassionate-use program, *Blood.*, 2011, 118, 4338-4345
- [25] Godeau B., Porcher R., Fain O., Lefrère F., Fenaux P., Cheze S., et al., Rituximab efficacy and safety in adult splenectomy candidates with chronic immune thrombocytopenic purpura: results of a prospective multicenter phase 2 study, *Blood.*, 2008, 112, 999-1004
- [26] Ghanima W., Bussel J.B., Thrombopoietic agents in immune thrombocytopenia, *Semin Hematol.*, 2010, 47, 258-265
- [27] Ahn Y.S., Efficacy of danazol in hematologic disorders, *Acta Haematol.*, 1990, 84, 122-129
- [28] Maloisel F., Andrès E., Zimmer J., Noel E., Zamfir A., Koumariou A., et al., Danazol therapy in patients with chronic idiopathic thrombocytopenic purpura: long-term results, *Am J Med.*, 2004, 116, 590-594
- [29] Park Y.H., Yi H.G., Kim C.S., Hong J., Park J., Lee J.H., et al., Clinical Outcome and Predictive Factors in the Response to Splenectomy in Elderly Patients with Primary Immune Thrombocytopenia: A Multicenter Retrospective Study, *Acta Haematol.*, 2016, 135, 162-171
- [30] Gonzalez-Porras J.R., Escalante F., Pardo E., Sierra M., Garcia-Frade L.J., Redondo S., et al., Safety and efficacy of splenectomy in over 65-yrs-old patients with immune thrombocytopenia, *Eur J Haematol.*, 2013, 91, 236-241
- [31] Habermalz B., Sauerland S., Decker G., Delaitre B., Gigot J.F., Leandros E., et al., Laparoscopic splenectomy: the clinical practice guidelines of the European Association for Endoscopic Surgery (EAES), *Surg Endosc.*, 2008, 22, 821-848
- [32] Somasundaram S.K., Massey L., Gooch D., Reed J., Menzies D., Laparoscopic splenectomy is emerging 'gold standard' treatment even for massive spleens, *Ann. R. Coll. Surg. Engl.*, 2015, 1-4
- [33] Uranues S., Alimoglu O., Laparoscopic surgery of the spleen, *Surg Clin North Am.*, 2005, 85, 75-90
- [34] Park A.E., Birgisson G., Mastrangelo M.J., Marcaccio M.J., Witzke D.B., Laparoscopic splenectomy: outcomes and lessons learned from over 200 cases, *Surgery.*, 2000, 128, 660-667

- [35] Pace D.E., Chiasson P.M., Schlachta C.M., Mamazza J., Poulin E.C., Laparoscopic splenectomy for idiopathic thrombocytopenic purpura (ITP), *Surg Endosc.*, 2003, 17, 95-98
- [36] Wang K.X., Hu S.Y., Zhang G.Y., Chen B., Zhang H.F., Hand-assisted laparoscopic splenectomy for splenomegaly: a comparative study with conventional laparoscopic splenectomy, *Chin Med J. (Engl)*, 2007, 120, 41-45
- [37] Barbaros U., Aksakal N., Tukenmez M., Agcaoglu O., Bostan M.S., Kilic B., et al., Comparison of single port and three port laparoscopic splenectomy in patients with immune thrombocytopenic purpura: Clinical comparative study, *J Minim Access Surg.*, 2015, 11, 172-176
- [38] Santini M., Fiorelli A., Messina G., Laperuta P., Mazzella A., Accardo M., Use of the LigaSure device and the Stapler for closure of the small bowel: a comparative ex vivo study, *Surg Today.*, 2013, 43, 787-793
- [39] Mahévas M., Gerfaud-Valentin M., Moulis G., Terriou L., Audia S., Guenin S., et al., Characteristics, outcome and response to therapy of multirefractory chronic immune thrombocytopenia, *Blood.*, 2016
- [40] Michel M., Suzan F., Adoue D., Bordessoule D., Marolleau J.P., Viallard J.F., et al., Management of immune thrombocytopenia in adults: a population-based analysis of the French hospital discharge database from 2009 to 2012, *Br J Haematol.*, 2015, 170, 218-222
- [41] Kojouri K., George J.N., Recent advances in the treatment of chronic refractory immune thrombocytopenic purpura, *Int J Hematol.*, 2005, 81, 119-125
- [42] Kojouri K., Vesely S.K., Terrell D.R., George J.N., Splenectomy for adult patients with idiopathic thrombocytopenic purpura: a systematic review to assess long-term platelet count responses, prediction of response, and surgical complications, *Blood.*, 2004, 104, 2623-2634
- [43] Heniford B.T., Matthews B.D., Answini G.A., Walsh R.M., Laparoscopic splenectomy for malignant diseases, *Semin Laparosc Surg.*, 2000, 7, 93-100
- [44] Walsh R.M., Brody F., Brown N., Laparoscopic splenectomy for lymphoproliferative disease, *Surg Endosc.*, 2004, 18, 272-275
- [45] Silecchia G., Boru C.E., Fantini A., Raparelli L., Greco F., Rizzello M., et al., Laparoscopic splenectomy in the management of benign and malignant hematologic diseases, *JLS.* 2006, 10, 199-205
- [46] Cozzolino I., Varone V., Picardi M., Baldi C., Memoli D., Ciancia G., et al., CD10, BCL6, and MUM1 expression in diffuse large B-cell lymphoma on FNA samples, *Cancer Cytopathol.*, 2016, 124, 135-143
- [47] Cozzolino I., Vigliar E., Todaro P., Peluso A.L., Picardi M., Sosa Fernandez L.V., et al., Fine needle aspiration cytology of lymphoproliferative lesions of the oral cavity, *Cytopathology.*, 2014, 25, 241-249
- [48] Vigliar E., Cozzolino I., Picardi M., Peluso A.L., Fernandez L.V., Vetrani A., et al., Lymph node fine needle cytology in the staging and follow-up of cutaneous lymphomas, *BMC Cancer.*, 2014, 14, 8
- [49] Zeppa P., Sosa Fernandez L.V., Cozzolino I., Ronga V., Genesio R., Salatiello M., et al., Immunoglobulin heavy-chain fluorescence in situ hybridization-chromogenic in situ hybridization DNA probe split signal in the clonality assessment of lymphoproliferative processes on cytological samples, *Cancer Cytopathol.*, 2012, 120, 390-400.
- [50] Peluso A.L., Cascone A.M., Lucchese L., Cozzolino I., Ieni A., Mignogna C., et al., Use of FTA cards for the storage of breast carcinoma nucleic acid on fine-needle aspiration samples, *Cancer Cytopathol.*, 2015, 123, 582-592
- [51] Zeppa P., Barra E., Napolitano V., Cozzolino I., Troncone G., Picardi M., et al., Impact of endoscopic ultrasound-guided fine needle aspiration (EUS-FNA) in lymph nodal and mediastinal lesions: a multicenter experience, *Diagn Cytopathol.*, 2011, 39, 723-729
- [52] Di Crescenzo V., Laperuta P., Napolitano F., Carlomagno C., Danzi M., Amato B., et al., Unusual case of exacerbation of sub-acute descending necrotizing mediastinitis, *BMC Surg.*, 2013, 13 Suppl 2, S31
- [53] Di Crescenzo V., Laperuta P., Napolitano F., Carlomagno C., Garzi A., Vitale M., Pulmonary sequestration presented as massive left hemothorax and associated with primary lung sarcoma, *BMC Surg.*, 2013, 13 Suppl 2, S34
- [54] Di Crescenzo V., Vitale M., Valvano L., Napolitano F., Vatrella A., Zeppa P., et al., Surgical management of cervico-mediastinal goiters: Our experience and review of the literature, *Int J Surg.*, 2016, 28 Suppl 1, S47-53
- [55] Serio B., Pezzullo L., Giudice V., Fontana R., Annunziata S., Ferrara I., et al., OPSI threat in hematological patients, *Transl Med UniSa.*, 2013, 6, 2-10
- [56] Romano F., Caprotti R., Conti M., Piacentini M.G., Uggeri F., Motta V., et al., Thrombosis of the splenoportal axis after splenectomy, *Langenbecks. Arch Surg.*, 2006, 391, 483-488