

Case Report

Perforating head injury with iron rod and its miraculous escape: Case report and review of literature

Batuk Diyora^{a,*}, Nitin Kotecha^a, Mazhar Mulla^a, Shailendra Dethe^b,
Bhagyashree Bhende^a, Swapnil Patil^a

^a Department of Neurosurgery, Second floor, College building, LTMG Hospital, Sion, Mumbai 22, India

^b Department of Anaesthesia, College building, LTMG Hospital, Sion, Mumbai 22, India

ARTICLE INFO

Keywords:

Head injury
Penetrating injury
Iron rod

ABSTRACT

Civilian perforating head injury is rare. Because rarity of this injury, there is no standard management protocol. We report a case of perforating head injury with iron rod, review the literature on the subject and discuss the challenges in the management of such case. We have not found similar case in the literature. Civilian perforating head injury is rare. A 25-year-male brought to the emergency department with approximately two feet perforating iron rod in the head, entering via frontal region, left side of midline and coming out of the occipital region. He developed right sided hemiplegia and global aphasia. He underwent series of imaging for the evaluation of the course of the iron rod and injury sustained because of it. Under strict aseptic precaution, iron rod removed in the operation theater. His clinical condition improved over a period of three weeks. At one year follow up- he had almost normal speech and language functions and was able to walk without support. This case illustrates the possibility of bizarre type of such injury in the presence of protective helmet and challenges in the management. Preoperative planning on the basis of images, prophylactic antibiotics and anticonvulsant medications, cleaning of the objects with antiseptic solutions, anterograde extraction after adequate exposure around entry and exit points resulted in good clinical outcome after successful removal of the rod.

Introduction

Penetrating and perforating head injuries are serious brain injuries and associated with significant morbidity and mortality. Penetrating craniocerebral injuries are commonly seen in war related situations, mainly caused by missiles [1,2,3]. Civilian Non-missile intracranial injuries caused by foreign bodies are quite rare [1,2]. The vast majority of deaths from penetrating trauma are due to unintentional accidents while a significant minority follow suicides and homicides [2,3,4,5]. Civilian Perforating head injury is extremely uncommon. Literature search we found only three cases of perforating head injury [6,7,8]. We present a case of accidental perforating head injury with iron rod and its miraculous escape, review the literature on the subject and discuss the challenges in management of such case.

Case Presentation

A 27-year-male presented to our emergency department with altered sensorium with right sided hemiparesis and global aphasia.

* Corresponding author.

E-mail addresses: bddiyora@gmail.com, batuk73@yahoo.co.in (B. Diyora).

<https://doi.org/10.1016/j.tcr.2018.01.001>

Accepted 22 January 2018

Available online 02 February 2018

2352-6440/ © 2018 Published by Elsevier Ltd. This is an open access article under the CC BY-NC-ND license (<http://creativecommons.org/licenses/by-nc-nd/4.0/>).

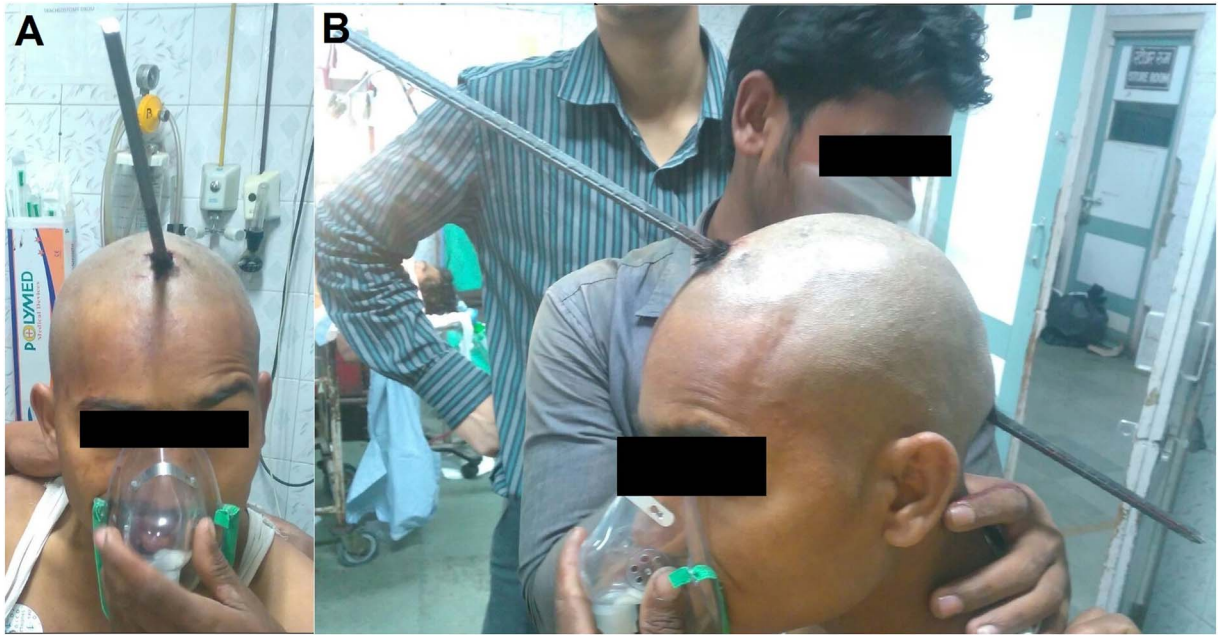

Fig. 1. Iron rod passing through head; from frontal to occipital region. (A) Antero-posterior view, (B) Lateral view.

He was conscious but drowsy and his Glasgow coma scale was 10/15(E3M6VI). His pupils were bilaterally 3 mm reacting to light. He had iron rod in the head perforating through left side of midline and was coming out of left occipital region about 4 cm from the midline (Fig. 1 A, B).

Mechanism of injury: Earlier as a construction site worker, he was working on the ground with protective helmet very close to a building under construction. Of the same building, on the 4th floor a person standing close to parapet was passing bunch [2,3] of iron rods (about 8–10 ft) to a person standing on the 5th floor. Suddenly one of the rod got slipped and fell down. Listening to the shout to clear the ground, person working just below tried to look up and got the iron rod through his head; of course through his helmet. Following the injury he was conscious and well awake but fell down on the ground. With the help of the rod cutter, part of the iron rod on the frontal site was cut at the construction site and he was taken to the private hospital in conscious status. He has received primary treatment in the form of tetanus prophylaxis, intravenous broad spectrum antibiotics and anti-convulsive medication. Within next two hours he developed weakness and difficulty in speech and he was brought to our institute.

Position in the bed:

On arrival, he was conscious but drowsy. He was aphasic and had right hemiplegia. He was kept in supine position, head tilted in such a way that rod remains almost parallel to the bed. He underwent computed tomography (CT) scan and similar precaution taken in the CT room.

Imaging

Head CT scan revealed metallic foreign body entering in the frontal region and coming out of the occipital region with metal artifact. Also few specks of haemorrhage noticed along the tract. The extent of brain injury could not be ascertained on the CT images as a consequence of severe metallic artifacts (Fig. 2A, B). CT bone window revealed iron rod penetrating through the frontal bone almost close to the midline on the left side and coming out of the occipital bone about 3–4 cm from the midline just above the left transverse sinus (Fig. 3A, B,C,D). Brain CT angiography revealed no abnormality. CT venography revealed close relation of iron rod to the superior sagittal sinus and coming out just above the left transverse sinus (Fig. 4 A, B).

Preparation for surgery

He was prophylactically intubated and kept on ventilator. Under general anesthesia, his head was fixed with the mayfield clamp in such a way that if require, left sided frontal, parietal or occipital craniotomy can be performed without any difficulty and rod can be pulled easily from the occipital region (Fig. 5A,B). Iron rod was thoroughly washed with saline, hydrogen peroxide and betadine solution for 15 min. Painting and draping of the operative site done. Scalp flap marked and cut opened across the sinus over the frontal region and craniotomy performed (Fig. 6A). Similarly, occipital region via 'Z' shaped incision, scalp flaps retracted and occipital craniectomy performed around iron rod (Fig. 6B). Iron rod became relatively loose. Dura opened around the rod in cruciate manner over the frontal region. Loosened iron rod held firmly and via gentle progressive very very minimal rotatory movements pulled out at the occipital end without any difficulty (Fig. 6C). Minor ooze at both the ends stop spontaneously. Both wound sites

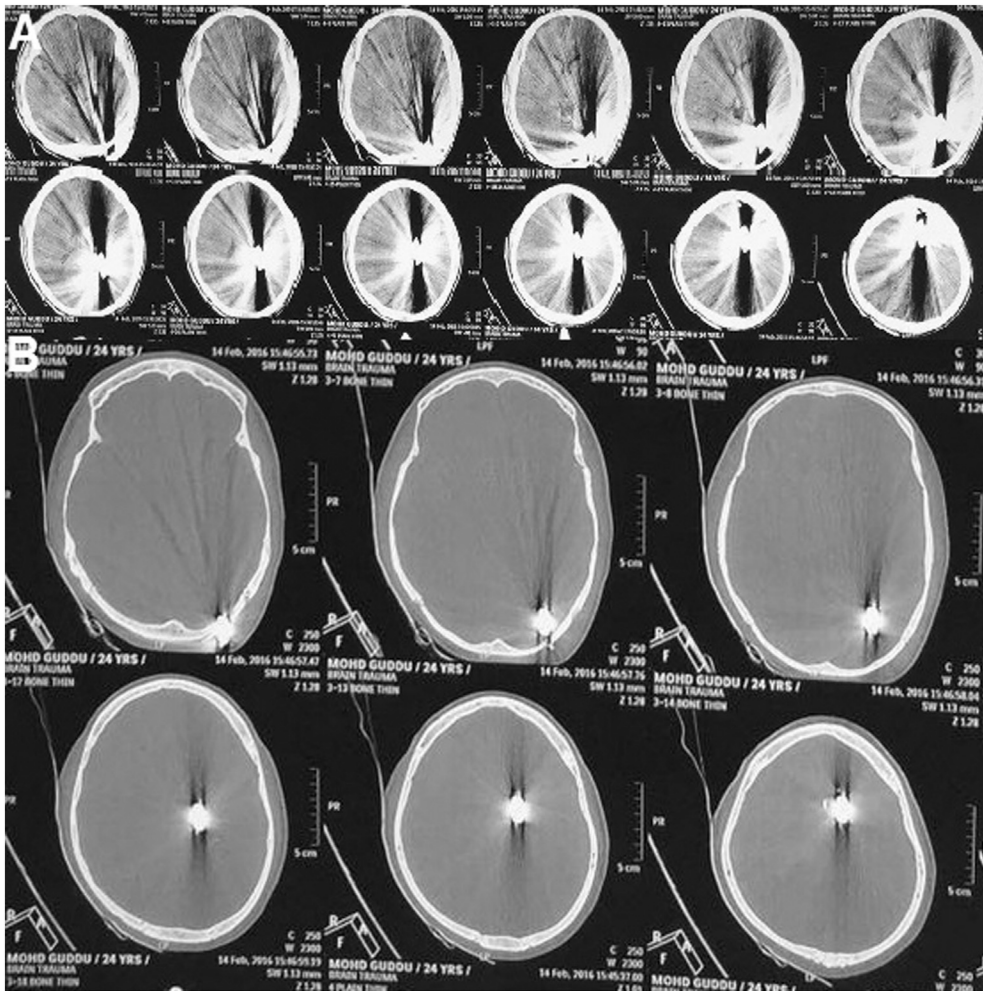


Fig. 2. Computed tomography(CT) scan head showing foreign body passing from frontal to occipital region with metallic artifacts;(A) Parenchymal window and (B) bone window.

thoroughly washed with the saline and antiseptic solutions. Dural defect closed with galeal patch. Both wounds again thoroughly washed with the antiseptic solutions. Frontal bone flap kept and fixed. Both wounds closed in layers after putting negative suction drain.

Immediately following surgery, CT scan brain was performed which revealed minor haemorrhage along the tract without any new changes (Fig. 7). Patient was shifted to ICU and ventilated till next day morning. He was weaned from the ventilator and extubated at the end of 48 h. He was afebrile and Glasgow coma scale was 13/15 at the end of fourth day.

He underwent digital subtraction angiography(DSA) of brain vessels on 7th post-operative day which reveals normal venous sinuses and no evidence of pseudoaneurysm or dural arteriovenous fistula (Fig. 8A,B)). He also underwent Magnetic Resonance Image (MRI) of the brain that revealed hyper intensity along the course of rod on T2-weighted images. There was no evidence of subdural infection or brain abscess. Magnetic resonance tractography revealed impairment of corticospinal tract on the left side. He was discharged from the ward at two weeks with oral antibiotics for 4 weeks and anticonvulsive treatment for two years and shifted to neurorehabilitation centre.

At 6 weeks follow up, his neurological examination revealed almost normal speech and grade 4/5 in right sided limbs. He never complained about vision impairment in either of his eyes, however his computerized perimetry revealed left homonymous hemianopia with left eye superiorquadrantanopia (Fig. 9A,B). He progressively improved in his neurology and we have follow up of one and half years. He had no seizures. He was fully conscious well awake and well oriented to time place and person. His speech and language function were normal. He had normal power in left side limbs, while grade 4/5 power in right lower limb and grade 5/5 power in right upper limb. His neuropsychological assessment revealed no abnormality. He has no changes in his follow up computerized perimetry study.

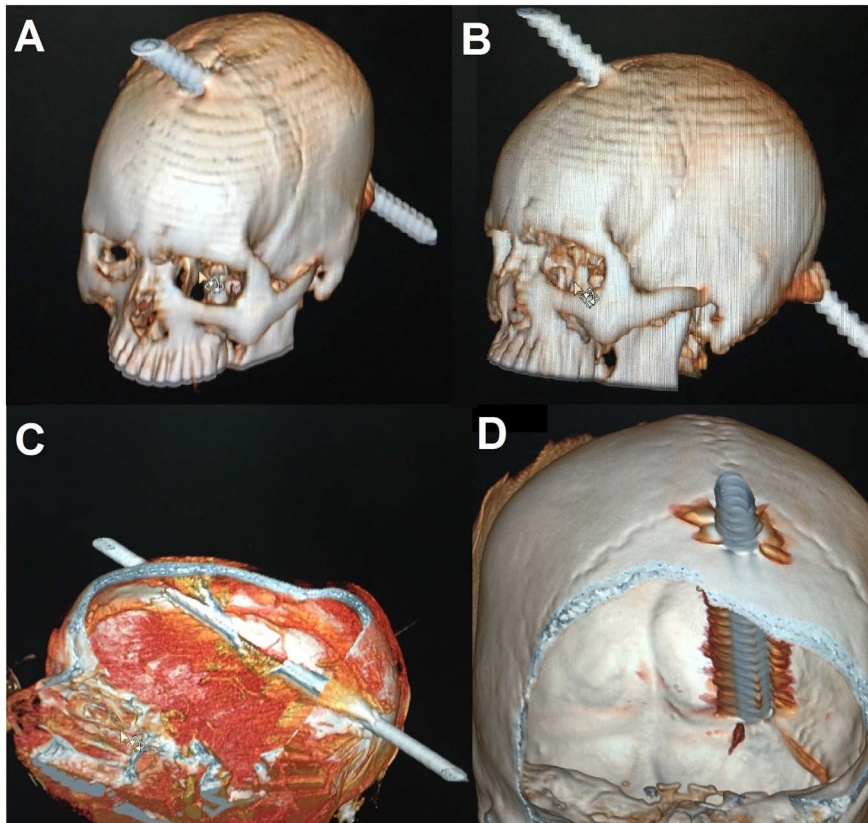


Fig. 3. 3-Dimensional CT head showing iron road entering from left frontal bone and coming out from left occipital region;(A) Antero-posterior view, (B) left lateral oblique. 3-Dimension CT head also showing iron rod passing through the skull and its relation with (C) superior sagittal sinus and (D)left transvers sinus.

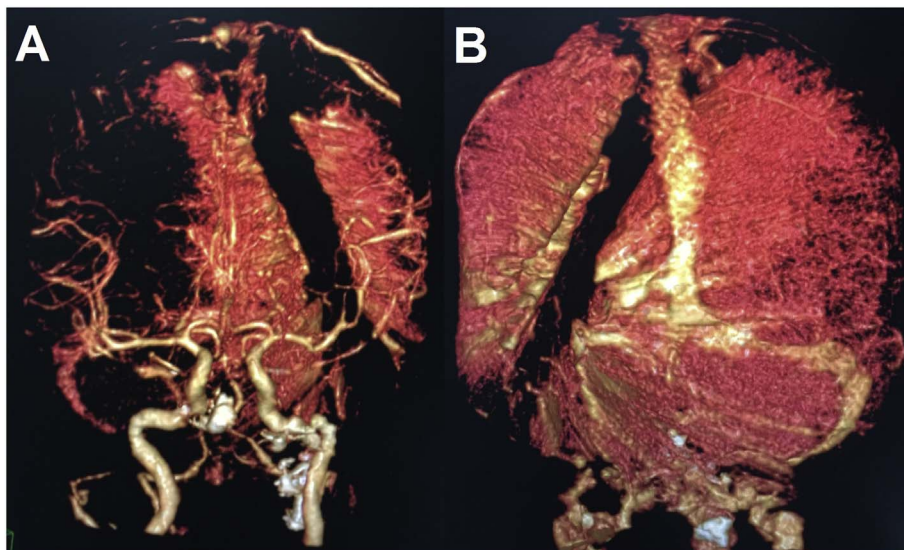


Fig. 4. CT angiography(A) and CT venography(B) showing relation of the iron rod to major arterial system and venous sinuses respectively.

Discussion

In 1868 Dr. Harlow describe first ever reported case of perforating brain injury [6]. Importance of this case in the history of neuroscience and role of left frontal cortex as an eloquent area are being elegantly described [9]. Though many cases of penetrating injury being reported in the literature, we have found only two additional cases of perforating head injury till date. (Table 1) As there

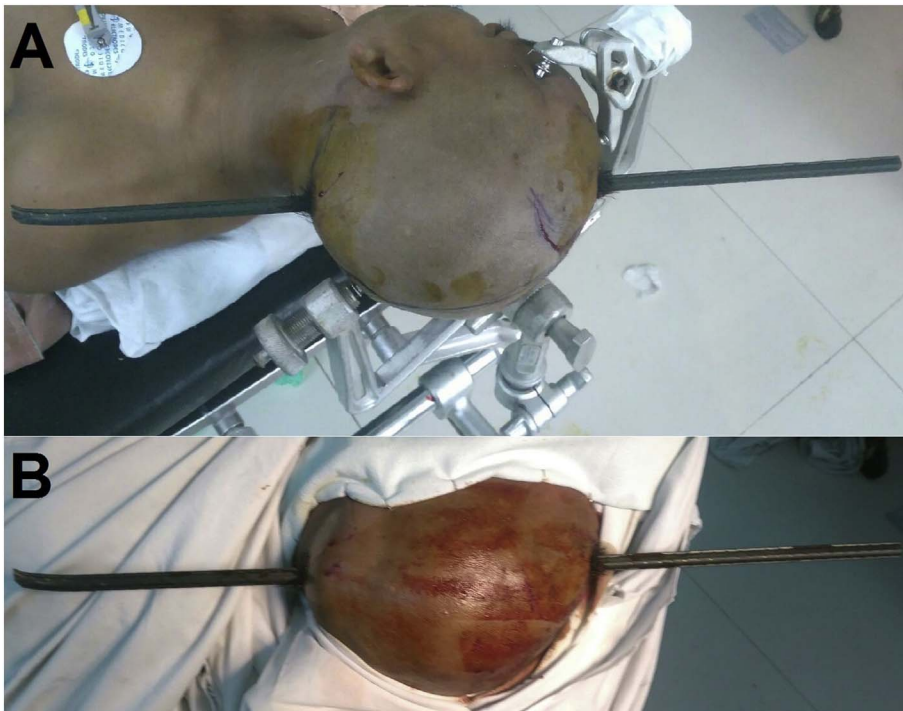

Fig. 5. (A)View of iron rod in relation to the head clamp, (B) view after putting surgical drap.

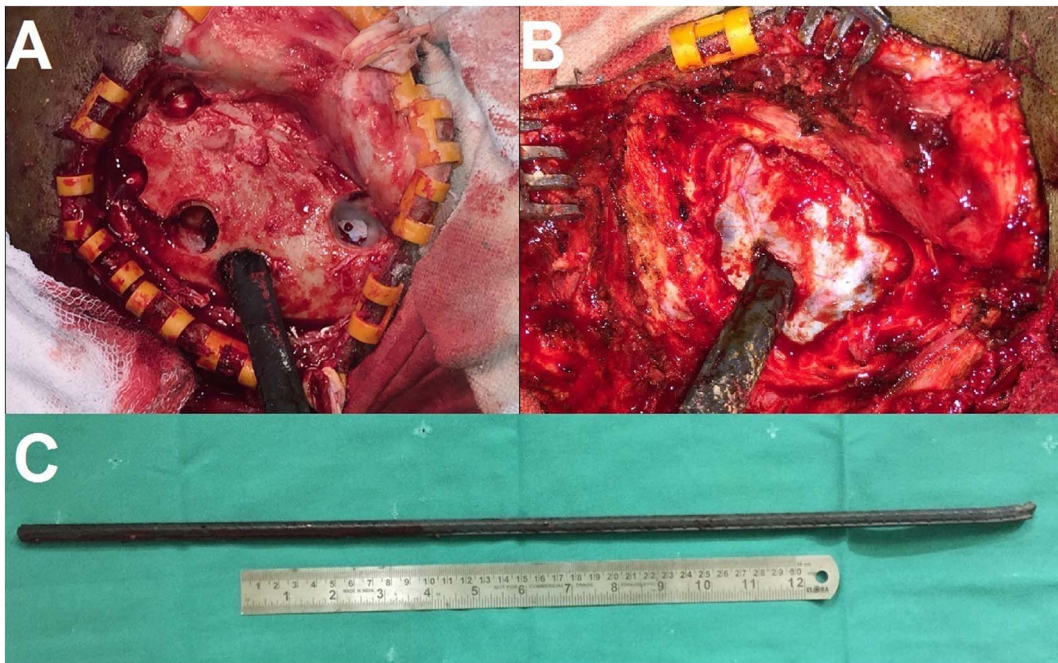


Fig. 6. Intraoperative photograph showing(A) right frontal craniotomy, (B) left occipital craniectomy and (C) successfully removed iron rod.

are not many cases in the literature, there are no standard management guidelines. We share our experience and put forwards the challenges in the management.

Transferring the patient with 8 ft iron rod in the head through the helmet was practically a big challenge. Cutting the rod and helmet with the iron cutter was a wise decision made by local engineer and patient was shifted to nearby hospital. Some authors have advised against the cutting the rod with the hacksaws to prevent transmission of vibration to the brain [10]. While other reported safe cutting of arrow with cold saw by a specialist [8]. In our case we have not further attempted to cut short road as it was enough size to

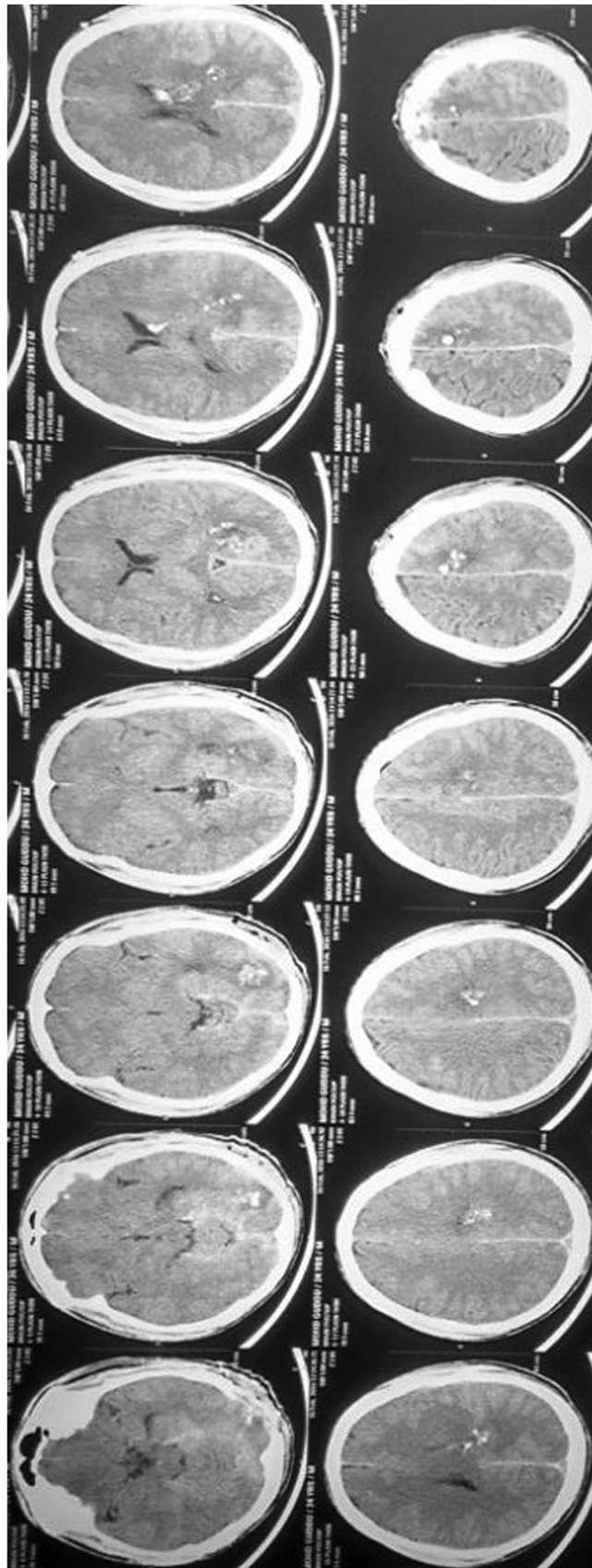


Fig. 7. Immediate post-operative CT scan plain study showing very minimal haemorrhage around the tract traverse by iron rod.

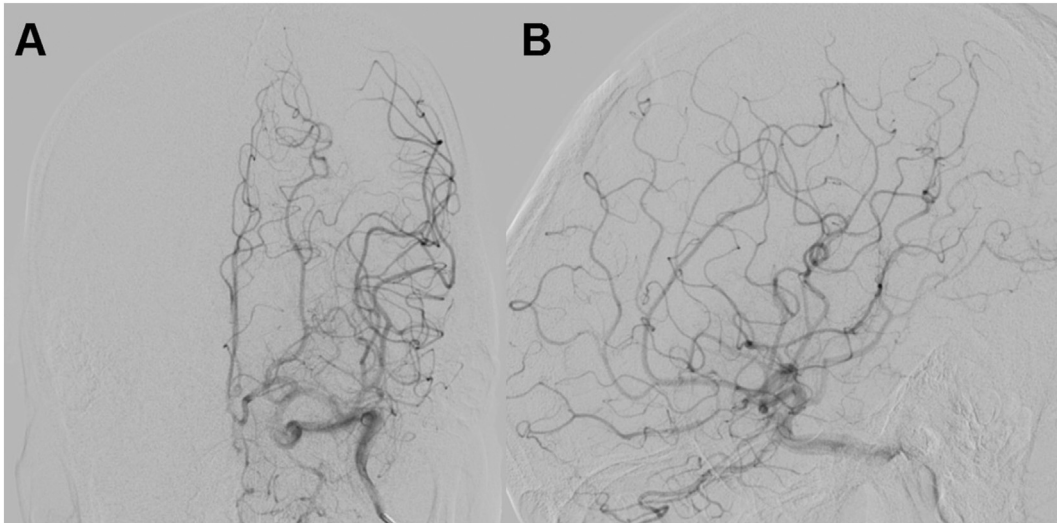


Fig. 8. Digital subtraction angiography: Left internal carotid artery injection (A) antero posterior view and (B) lateral view showing no evidence of pseudo-aneurysm or fistula.

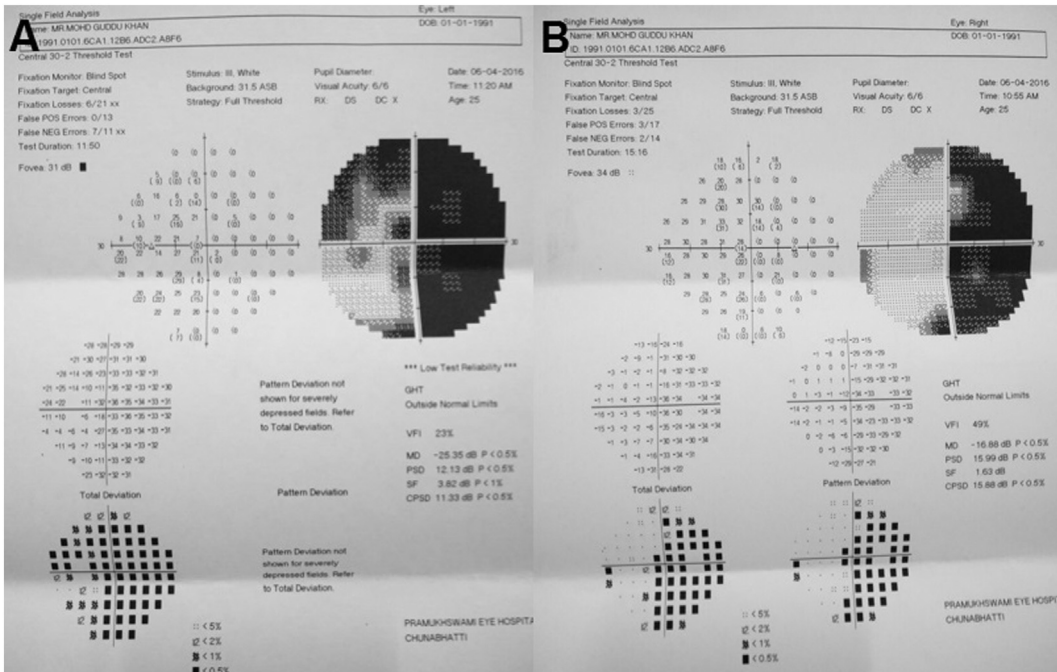


Fig. 9. Computerized perimetry (A) left eye, (B) right eye showing left sided homonymous hemianopia and left eye superior quadrantanopia.

keep patients head in CT scan gantry in lateral position. Patient was taken to the local hospital in sitting position as there was difficulty in keeping him straight. As he became drowsy he was kept in supine position with head turned towards the right so rod can remain parallel to stretcher or bed. Even during the transferring and performing the CT scan his head was kept in lateral position. Like in the previous reported cases we also performed prophylactic intubation in view of deteriorating neurology and fear of probable convulsion if he can have [10]. Intubation was difficult and anaesthetist literally bent towards right side to perform successful intubation.

In general patient with the penetrating head injury requires prompt medical attention and penetrating object has to be removed within 12 h [11,12], but patient with the penetrating foreign body with active bleeding should be taken for intervention as early as possible [12,13]. However, in case like this with no active haemorrhage from the penetrating site; with hemodynamically stable patient enough time between injury and surgical intervention should be invested in thorough and necessary investigation for understanding the nature, severity of the injury and preoperative planning.

Table 1
Summary of cases of perforating head injury and their outcome.

Study	Year	Type of foreign body	Type of injury	Age sex	Presentation neurodeficit	Foreign body removed	Complications	Outcome
Harlow J [6]	1848	Tamping iron rod	Accidental	25/M	Conscious no deficit	Spontaneous ejection	seizures	Survived for 12 years Died due to seizures
Abaraca J et al. [8]	2011	Spear gun arrow	Suicidal	34/M	Conscious No deficit	Operation theater	nil	Good
Williams J et al. [7]	2014		Suicidal	55/M	Glasgow coma scale 3Ton chemical sedation	Operation theater	Low grade fever, cerebritis	Died after 33 days
Present case	2016	Iron rod	Accidental	29/M	Drowsy right sided weakness aphasia	Operation theater	nil	Good

There is direct correlation between severity of injury and increased risk of seizure. In all cases of penetrating brain injury, 30–50% of patients reported seizures, however, Prophylactic antiepileptic treatment is controversial [1,2,6,]. We routinely administer antiepileptic medicine in penetrating brain injury cases.

As in the cases of penetrating head injury with gunshot wounds, CT scan head is the imaging modality of choice. CT scan will not only locate penetrating objects and its fragments but also give detail information about injury to the underlying brain. As most of the penetrating objects are metallic, they generate CT artefact that obscures anatomy crucial to planning surgical approaches. When available, DECT (Dual-energy computed tomography) scanning with 3-D reconstruction may be helpful [14,15]. MRI can be used to screen the patient with non-metallic injury. As the CT scan with 3-dimension reconstruction with volumetric images revealed close relation of the entry and exist point of the rod to venous sinuses and relatively long course of the rod, it was decided to do CT venography and CT angiography respectively. Imaging played a very crucial role in the operative planning to bring out the rod safely.

Advanced planning about the direction of extraction is also utmost important. For this not only the imaging tests but also detail information about characteristics of object is essential [16]. As nearly half foot rod was outside the skull on both the sides, it was inevitable to pull the rod at either end to remove it. But on the detail examination, slight bend noticed at the occipital end of the rod so decision was taken to pull it anterograde towards the occipital end to prevent further parenchymal injury during removal.

When portion of the perforating object remain partially outside of the cranial vault, extra measures will be necessary to minimize further inoculation of brain tissue with toxic microorganisms via manipulation of the penetrating object or the need to push initially external projectile material through brain parenchyma in order to remove the entire missile in an anterograde fashion. Bringing the unsterile part of the rod through the brain was concern. Rod was thoroughly cleaned with the antiseptic solution for 15 min especially at the frontal end.

Position of the head during the surgery was a challenge. Head was fixed with the Mayfield's clamp in such a way that left frontal parietal and occipital area remain accessible. Best operative techniques, Craniotomy Vs Craniectomy still remains controversial for such injury. No statistical significance difference was observed between these two procedure by Rish et al. [17] We have performed frontal craniotomy and occipital craniectomy in our case. It was clear from the CT images about possible involvement of the superior sagittal sinus and so the decision was made about frontal craniotomy. Though the plan was to perform small frontal craniotomy and occipital craniectomy only, large area was prepared for emergency wide craniotomy if inadvertent excessive bleeding happened during or after removal of the rod. Constant fear of possible haemorrhage ended with the successful removal of the rod without bleeding.

Post-operative wound infection was a big concern in view of extensive deep penetration of the rod. No standard of infection management has emerged from penetrating brain injury study due to variation in the infection control practice among different departments and institute. Uncertainties remain regarding timing of antibiotic use, length of antibiotic regimen, and whether the early or prophylactic use of antibiotics produces more resistant strains of bacteria. Literature is very contradictory for the type and duration of antibiotics; some are recommending prophylactic use of antibiotics while are others advice use of antibiotics when specific colony identify [12,18]. We have given intravenous antibiotics for two weeks and oral antibiotics for 4 weeks.

Vascular complication are frequent following penetrating head injury and ranges from 5 to 40% [19,20]. these includes true and pseudo aneurysm, arteriovenous malformation and subarachnoid haemorrhage. Earlier guideline of management of penetrating injury suggested pre-operative digital subtraction angiography study in cases suspected with vascular injury [12,18,21,22,23]. However, recent data from middle east conflicts suggest that more than one third patient with penetrating injury develop vascular injury [24,25]. Thus warrants pre-operative CT angiography in all patients with penetrating brain injury. Postoperatively, non-vascular short term complications like wound infection, subdural collection and long term problems like brain abscess, are always concern. Digital subtraction angiography will help in the diagnosis of vascular complications. Imaging with contrast CT/MRI play vital role in diagnosis of these conditions. At one and half year follow up, our patient had neither of these problems.

Conclusion

We present the first case of accidental brain injury caused by an iron rod. This case illustrate the possibility of bizarre type of such injury in the presence of protective helmet and challenges in the management. Preoperative planning on the basis of CT scan with 3D

reconstruction, CT angiography and CT venography helped in successful removal of the rod. Prophylactic antibiotics and anticonvulsant medications, cleaning of the objects with antiseptic solutions, anterograde extraction after adequate craniotomy around entry and exit points resulted in good clinical outcome.

References

- [1] B. Cemil, K. Tun, O. Yigenoglu, E. Kaptanoglu, Attempted suicide with screw penetration into the cranium, *Ulus. Travma Acil Cerrahi Derg.* 15 (2009) 624–627.
- [2] S. Chibbaro, L. Tacconi, Orbito-cranial injuries caused by penetrating non-missile foreign bodies. Experience with eighteen patients, *Acta Neurochir.* 148 (2006) 937–941 discussion 41–2.
- [3] J.M. Pascual, M. Navas, R. Carrasco, Penetrating ballistic-like frontal brain injury caused by metallic rod, *Acta Neurochir.* 151 (2009) 689–691.
- [4] M.R. Farhadi, M. Becker, C. Stippich, A.W. Unterberg, K.L. Kiening, Transorbital penetrating head injury by a toilet brush handle, *Acta Neurochir.* 151 (2009) 685–687.
- [5] D. Mitilian, B. Charon, F. Brunelle, F. Di Rocco, Removal of a chopstick out of the cavernous sinus, pons, and cerebellar vermis through the superior orbital fissure, *Acta Neurochir.* 151 (2009) 1295–1297.
- [6] J.M. Harlow, Passage of an iron rod through the head, *Boston Med. Surg. J.* 39 (1848) 389–393.
- [7] J.R. Williams, D.M. Aghion, C.E. Doberstein, G.R. Cosgrove, W.F. Asaad, Penetrating brain injury after suicide attempt with spear gun: case study and review of literature, *Front. Neurol.* 5 (2014) 113.
- [8] J. Abarca-Olivas, L.A. Concepcion-Aramendia, E. Baño-Ruiz, M.A. Caminero-Canas, J.A. Navarro-Moncho, C. Botella-Asunción, Perforating brain injury from a spear gun. A case report, *Neurocirugía (Astur.)* 22 (2011) 271–275.
- [9] A. García-Molina, Phineas gage and the enigma of the prefrontal cortex, *Neurología* 27 (2012) 370–375.
- [10] R. Fernández-Melo, A.F. Morán, G. López-Flores, W. Bouza-Molina, I. García-Maeso, J. Benavides-Barbosas, Penetrating head injury from harpoon. Case report, *Neurocirugía* 13 (2002) 397–400.
- [11] S.F. Kazim, M.S. Shamim, M.Z. Tahir, S.A. Enam, S. Waheed, Management of penetrating brain injury, *J. Emerg. Trauma Shock* 4 (2011) 395–402.
- [12] T.S. Helling, McNabney Wk, C.K. Whittaker, C.C. Shultz, Watkins M. The role of early surgical intervention in civilian gunshot wounds to head, *J. Trauma* 32 (1992) 398–400.
- [13] O. Hubschmann, K. Shapiro, M. Baden, K. Shulman, Craniocerebral gunshot injuries in civilian practice: prognostic criteria and surgical management experiences with 82 cases, *J. Trauma* 19 (1979) 6–12.
- [14] L. Yu, A.N. Primak, X. Liu, C.H. McCollough, Image quality optimization and evaluation of linearly mixed images in dual-source, dual-energy CT, *Med. Phys.* 36 (2009) 1019–1024.
- [15] E.G. Hoeffner, I. Case, R. Jain, S.K. Guiar, G.V. Shah, J.P. Deveikis, et al., Cerebral perfusion CT: technique and clinical applications, *Radiology* 231 (2004) 632–644.
- [16] G. Mouzopoulos, M. Tzurbakis, Unusual cervical spine injury by fishing harpoon, *Eur J Emerg Med* 16 (2009) 209–211.
- [17] Rish BL, Dillon JD, Caviness WF, Mohr JP, Kistler JP, Weiss GH. Evolution of craniotomy as a debridement technique for penetrating craniocerebral injuries. *J. Neurosurg.* 53:772–775.
- [18] D.P. Esposito, J.B. Walker, Contemporary management of penetrating brain injury, *Neurosurg. Q.* 19 (2009) 249–254.
- [19] M.L. Levy, A. Rezai, L.S. Masri, S.N. Litofsky, S.L. Giannotta, M.L. Apuzzo, et al., The significance of subarachnoid hemorrhage after penetrating craniocerebral injury: correlation with angiography and outcome in a civilian population, *Neurosurgery* 32 (1993) 532–540.
- [20] N. Nathoo, H. Boodhoo, S.R. Naidoo, E. Gouws, Transcranial brain-stem stab injuries; a retrospective analysis of 17 patients, *Neurosurgery* 47 (2000) 1117–1122.
- [21] A.G. Taylor, J.C. Peter, Patients with retain transcranial knife blades: a high risk group, *J. Neurosurg.* 87 (1997) 512–515.
- [22] J.D. Carrillo-Ruiz, *Stab Wounds of the Brain and Skull*, Vol. 23 Elsevier, Amsterdam, 1975.
- [23] J.C. de Villiers, D. Sevel, Intracranial complications of transorbital stab wounds, *Br. J. Ophthalmol.* 59 (1975) 52–56.
- [24] R.S. Bell, R.D. Ecker, M.A. Severson III, J.E. Wanebo, B. Crandall, R.A. Armonda, The evolution of the treatment of traumatic cerebrovascular injury during war time, *Neurosurg. Focus.* 28 (2010) E5.
- [25] J.E. Cohen, J.M. Gomori, R. Segal, A. Spivak, E. Margolin, G. Sviri, et al., Results of endovascular treatment of traumatic intracranial aneurysms, *Neurosurgery* 63 (2008) 476–486.