



Contents lists available at ScienceDirect

# Asia-Pacific Journal of Sports Medicine, Arthroscopy, Rehabilitation and Technology

journal homepage: [www.ap-smart.com](http://www.ap-smart.com)

## Original Article

## Second-look arthroscopy after double-bundle posterior cruciate ligament reconstruction: Effect of patient age

Yuta Tachibana <sup>a,\*</sup>, Yoshinari Tanaka <sup>a</sup>, Kinugasa Kazutaka <sup>a</sup>, Shuji Horibe <sup>b</sup><sup>a</sup> Department of Sports Orthopaedics, Osaka Rosai Hospital, Sakai, Japan<sup>b</sup> Faculty of Comprehensive Rehabilitation, Osaka Prefecture University, Habikino, Japan

## ARTICLE INFO

## Article history:

Received 26 March 2021

Received in revised form

6 August 2021

Accepted 4 October 2021

## Keywords:

Double-bundle posterior cruciate ligament reconstruction

Second-look arthroscopy

Patient age

Posteromedial graft

Graft morphology

Chondral damage

## ABSTRACT

**Purpose:** Second-look arthroscopy is invasive but still one of the most useful postoperative evaluation methods since graft morphology including graft tension, graft tear, and synovial coverage can be directly evaluated. However, only a few studies have evaluated transplanted posterior cruciate ligament (PCL) grafts. This study aimed to clarify the PCL graft morphology and chondral damages at second-look arthroscopy after double-bundle PCL reconstruction (PCLR) and to investigate the effects of patient age on these arthroscopic findings.

**Methods:** This study retrospectively included 26 patients who underwent second-look arthroscopy at the time of hardware removal 14 months after double-bundle PCLR for isolated PCL injury from January 2007 to December 2020. The patients were divided into two groups: group A, 39 years or younger ( $n = 14$ ); and group B, 40 years or older ( $n = 12$ ). At second-look arthroscopy, the grafts were evaluated based on tension (taut, graft tension as tense as a normal PCL; lax, graft tension looser than a normal PCL, unclassified, completely torn graft), tear (one or more tendon strands torn), and synovial coverage (good, synovial coverage greater than 80% around the graft; fair, synovial coverage greater than 50%; and poor, synovial coverage less than 50%). The chondral damages were evaluated using the Outerbridge classification system. Radiographic posterior tibial translation with gravity sag view as well as clinical outcomes were also evaluated.

**Results:** Anterolateral (AL) graft tension was lax in 8% of the patients, whereas posteromedial (PM) graft tension was lax or unclassified in 24% ( $p = 0.043$ ). Graft tear was observed only in the PM graft of 19% patients ( $p = 0.022$ ). Synovial coverage of AL grafts was good or fair in all cases, whereas that of PM grafts was poor in 28% cases ( $p < 0.001$ ). Regarding the effect of patient age, the synovial coverage of PM grafts was significantly poorer in group B ( $p = 0.033$ ), but no statistical difference in graft tension or tear was found. The chondral damages were significantly advanced in group B ( $p \leq 0.01$ ), except for the trochlear groove and lateral femoral condyle. No patients had residual subjective posterior instability, knee swelling, or loss of extension exceeding  $5^\circ$  or flexion exceeding  $10^\circ$ . All patients had improved from grade II or III preoperatively to grade I or grade II in the posterior drawer test. The posterior tibial translation significantly improved from  $10.0 \pm 3.6$  mm preoperatively to  $3.6 \pm 2.1$  mm at second-look arthroscopy. No significant differences in the postoperative clinical outcomes were observed between the two groups.

**Conclusion:** The morphology of the PM grafts at second-look arthroscopy after double-bundle PCLR was poorer than that of the AL grafts. Patient age negatively affected the postoperative graft synovial coverage and chondral status but did not affect the clinical outcomes.

© 2021 Asia Pacific Knee, Arthroscopy and Sports Medicine Society. Published by Elsevier (Singapore) Pte Ltd. This is an open access article under the CC BY-NC-ND license (<http://creativecommons.org/licenses/by-nc-nd/4.0/>).

\* Corresponding author. Department of Sports Orthopaedics, Osaka Rosai Hospital, 1179-3 Nagasone-cho, Kita-ku, Sakai, Osaka, 591-8025, Japan.

E-mail address: [yuta-tachibana@osakah.johas.go.jp](mailto:yuta-tachibana@osakah.johas.go.jp) (Y. Tachibana).

### 1. Introduction

Posterior cruciate ligament (PCL) reconstruction (PCLR) is performed to improve the subjective knee instability and restore the normal knee laxity. Several methods exist for evaluating the transplanted PCL graft. Posterior tibial translation and clinical

outcomes have been widely used as biomechanical and functional evaluations, and some studies have reported good outcomes after PCLR.<sup>1,2</sup> Magnetic resonance imaging (MRI) is a noninvasive evaluation method and has been used to qualitatively and morphologically evaluate injury to the transplanted PCL graft in some investigations.<sup>3,4</sup> However, the diagnostic accuracy of MRI using a standard orthogonal view for evaluating PCL graft tears was less than 80% compared with that of arthroscopic assessment.<sup>4</sup> Thus, comprehensive evaluation of the transplanted PCL graft using imaging modalities has not yet been established. Second-look arthroscopy is invasive but still one of the most useful postoperative evaluation methods since graft morphology including graft tension, graft tear, and synovial coverage can be directly evaluated. Several studies have investigated the morphology of transplanted grafts after multiple-bundle anterior cruciate ligament (ACL) reconstruction (ACLR) using second-look arthroscopy and shown that arthroscopic findings of the posterolateral bundle were inferior to the anteromedial bundle.<sup>5–7</sup> However, only a few studies have evaluated transplanted PCL grafts.<sup>8,9</sup> Moreover, only one study has investigated the morphology of grafts after double-bundle PCLR and reported that posteromedial (PM) grafts were torn in 30% of patients; however, that study included combined PCL injury.<sup>8</sup> Thus, information about the morphology of transplanted grafts after double-bundle PCLR for isolated PCL injury is limited. In the past two decades, more people aged 40 years or older has participated in physical fitness programs and sports,<sup>10</sup> and more middle-aged athletes have activity demands similar to those of young ones.<sup>11</sup> As a result, the number of reconstructive surgeries for cruciate ligament injuries in patients aged 40 years or older has been increasing.<sup>12</sup> A recent systematic review and meta-analysis have shown no significant differences in the postoperative outcomes after ACLR between middle-aged patients and young patients in terms of clinical scores, complication, and arthrometric anterior knee laxity.<sup>13–15</sup> Regarding the morphology of transplanted grafts at second-look arthroscopy, synovial coverage of ACL grafts was significantly inferior in elderly patients, but clinical outcomes were not affected.<sup>16</sup> However, no study has investigated the effects of patient age on the morphology of PCL grafts. Therefore, this study aimed to investigate the PCL graft morphology of PCL grafts and chondral damages using second-look arthroscopy after double-bundle PCLR and to evaluate the effects of patient age on these arthroscopic findings. We hypothesized that (1) morphology differed between anterolateral (AL) and PM grafts and that (2) patient age negatively affected the morphology of PCL grafts and chondral status.

## 2. Materials and methods

### 2.1. Patients

This retrospective study protocol was approved by our institutional review board. Between January 2006 and December 2019, 83 patients with unilateral isolated grade II or III PCL injuries<sup>17</sup> underwent double-bundle PCLR using autogenous hamstring tendon grafts. All patients experienced persistent posterior instability or pain during daily or sporting activities despite receiving more than three months of conservative treatment at our institution or another clinic. Among them, 26 (24 men and two women), who underwent second-look arthroscopy 14 months (range, 12–22 months) after PCLR from January 2007 to December 2020, were included in this study. The reason for undergoing second-look arthroscopy was the patients' hope of hardware removal and/or irritation. The mean patient age at the time of surgery was 36 years (range, 17–49 years), and the reasons for surgery included sports-related injuries ( $n = 12$ ), work-related injuries ( $n = 5$ ), and traffic

accidents ( $n = 9$ ). Based on previous studies,<sup>13–15</sup> the patients were divided into two groups according to their age: group A consisted of patients aged 39 years or younger, and group B consisted of patients aged 40 years or older.

### 2.2. Surgical techniques

All surgical procedures were performed by two orthopedic surgeons (S.H. and Yo.T.) at the same institution. Nineteen patients were subjected to bi-socket double-bundle PCLR with two femoral tunnels and one tibial tunnel, whereas seven patients were subjected to double-bundle PCLR with two femoral/tibial tunnels. Each patient was placed in the supine position, and an arthroscopic diagnosis was made via standard anteromedial and anterolateral portals. For femoral tunnel creation, we cleared the soft tissues, including the remnants of the torn PCL, using a mechanical shaver and visualized the anatomical landmarks for the PCL femoral footprint.<sup>18</sup> Two 2.4-mm Kirschner wires were separately inserted into the center of the AL and PM bundles of the PCL footprints in an inside–out manner with the knee flexed at 100°–110°. Matching the graft diameter, two 15–20-mm sockets were created by over-drilling the Kirschner wires, with diameters of 6.0–9.0 mm for the AL tunnel and 5.0–7.0 mm for the PM tunnel. To create tibial tunnels, we cleared the remnants of the torn PCL using a mechanical shaver through the posteromedial portal and clearly visualized the anatomical landmarks for the PCL tibial footprint.<sup>19</sup> Viewing through the posteromedial portal, one 2.4-mm Kirschner wire in the bi-socket procedure or two 2.4-mm Kirschner wires in the double-bundle procedure were inserted using an outside–inside manner from the medial tibial cortex to the center of the footprint using a tibial tip aimer (Smith & Nephew Endoscopy, Andover, MA, USA). After checking the location of the tips of wires using frontal/lateral radiographs, the wires were over-drilled, matching the graft diameter. The tibial tunnel diameter was 9.0–11.0 mm in the bi-socket procedure, whereas the tibial tunnel diameter was 6.5–8.0 mm for the AL tunnel and 5.5–7.0 mm for the PM tunnel in the double-bundle procedure. The autogenous semitendinosus and gracilis tendons were harvested and made into 80–85-mm-long tripled grafts. The semitendinosus tendon was used for the AL grafts, and the gracilis tendon was used for the PM grafts. Both ends of the grafts were unified using two no. 2 polyethylene sutures. After the passage of the grafts, two Endobuttons® (Smith & Nephew Endoscopy, Andover, MA, USA) were set on the cortex of the medial femoral condyle and unified using sutures. Subsequently, the graft sutures for the tibial side were connected with two Double-Spike Plates® (MEIRA Corp., Nagoya, Japan), and the creep of the construct was removed by repetitive manual pulling. Finally, these grafts were fixed to the tibia under a total initial tension of 10 N (5 N and 5 N for the AL and PM grafts, respectively) at 0° of flexion.<sup>20</sup> Graft tensions were applied and monitored using tensioners via the tensioning sutures distally connected to the Double-Spike Plates.

### 2.3. Postoperative rehabilitation

For postoperative management, the knees were immobilized in extension using braces for three weeks to reduce the acute inflammatory responses, such as pain and swelling in the early postoperative term. Range-of-motion exercises and partial weight-bearing activities were started at three weeks postoperatively, and full weight-bearing activities were allowed at five weeks postoperatively. Jogging and running were allowed at four and seven months postoperatively, respectively. The patients were allowed to return to their previous activity levels approximately 10 months postoperatively.

#### 2.4. Evaluation using second-look arthroscopy

Each patient was placed in the supine position, and an arthroscopic diagnosis was made via standard anteromedial and anterolateral portals. At second-look arthroscopy, the PCL in each graft (i.e., AL and PM grafts), including graft tension, graft tear, and synovial coverage, was evaluated. The graft tension of ALB was evaluated at 90° while that of PMB was at 20°. The graft tears were evaluated by probing at 20°–90° of knee flexion.<sup>16,22</sup> Then, graft tension was categorized into taut, lax, or unclassified. Grafts as tense as a normal PCL were considered taut, whereas grafts showing tension loss compared to a normal PCL were defined as lax. If the graft was completely torn, it was categorized as unclassified. Graft tear was defined when a tear of one or more tendon strands was observed. Synovial coverage over the grafts was classified into the following three categories: good, synovial coverage greater than 80% around the graft; fair, synovial coverage greater than 50%; and poor, synovial coverage less than 50% (Fig. 1).<sup>16</sup> The area where the graft was torn was considered uncovered by the synovium. The chondral damages on the patella, trochlear groove (TG), lateral/medial femoral condyle (LFC/MFC), and lateral/medial tibial plateau (LTP/MTP) were evaluated using the Outerbridge classification system<sup>23</sup> and compared with those at the primary PCLR.<sup>24,25</sup> All arthroscopic findings in the medical record, intraoperative images, or movies were re-confirmed among three orthopedic surgeons (Yu.T., Yo.T., and K.K.).

#### 2.5. Clinical evaluations

Before the second-look arthroscopic surgery, subjective posterior instability and physical examinations were evaluated: knee swelling, loss of extension/flexion, and the posterior drawer test. We evaluated the loss of extension/flexion comparing the contralateral intact knee because the absolute value of maximum extension/flexion angle can vary among the individuals. For the radiographic evaluation of the posterior tibial translation (PTT), lateral radiographs with gravity sag views<sup>26</sup> were collected. The patients were placed in the supine position along a long axis of the table with both hips flexed at 45° and both knees kept upright at 90° of flexion. First, the posterior tibial axis was defined as a line parallel to the posterior cortex that had started passing through a point 15 cm away from the joint line on the posterior cortex.<sup>27</sup> Second, the tibial line was defined as a line parallel to the posterior tibial axis and across the anterior border of the tibial plateau, whereas the femoral line was defined as a line parallel to the

posterior tibial axis and across the middle point between the distal borders of the lateral and medial condyles. The tibia–femur step-off was measured as the interval between the tibial and femoral lines. Then, the PTT was defined as the side-to-side difference of the tibia–femur step-off (Fig. 2). Plain radiographs were taken bilaterally to adjust the tibial rotation and knee flexion angles, which potentially affected the tibia–femur step-off value. The PTT was measured before PCLR and second-look arthroscopy. According to a previous study,<sup>28</sup> the intraobserver intraclass correlation coefficient (ICC) was 0.975, while the interobserver ICC was 0.874.

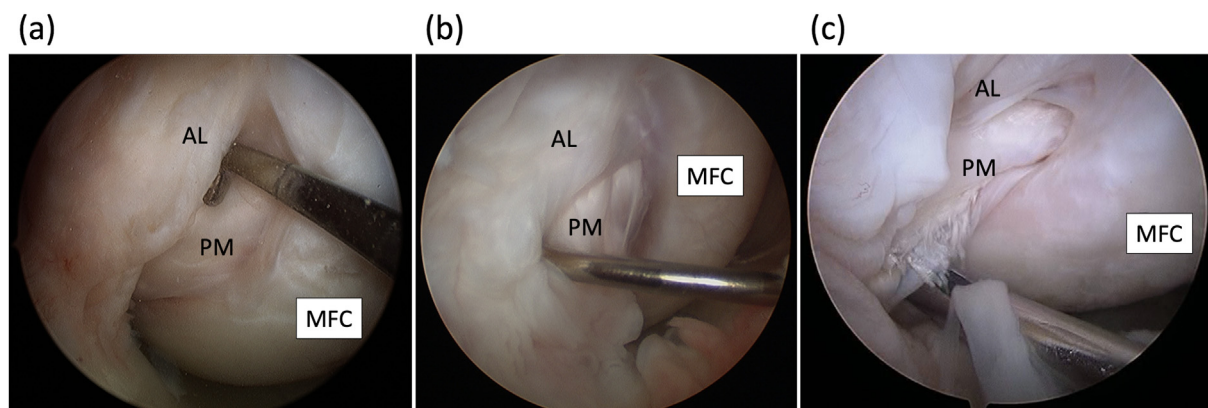
#### 2.6. Statistical analysis

All statistical analyses were conducted using JMP Pro (version 15.1.0; SAS Institute, Cary, NC, USA). The Wilcoxon signed-rank test was used to compare the graft morphology between AL and PM grafts among the same patients. In the comparison between the two subgroups of patient age, Fisher's exact test was used for nominal scales, such as sex, meniscal injury, and surgical procedure. The Wilcoxon rank sum test was used for continuous scales, such as age, interval between injury and surgery, PTT, and graft cross-sectional areas (CSAs). Nominal scales regarding graft morphology were converted to numeral parameters as follows: graft tension, taut = 1, lax/unclassified due to tear = 0; graft tear, no = 1, yes = 0; and synovial coverage, good = 2, fair = 1, and poor = 0. Ordinal scales including PCL injury grades and chondral damages were regarded as numeral parameters. Furthermore, these parameters were analyzed using the Wilcoxon rank sum test. *P* values of less than 0.05 were used to denote statistical significance.

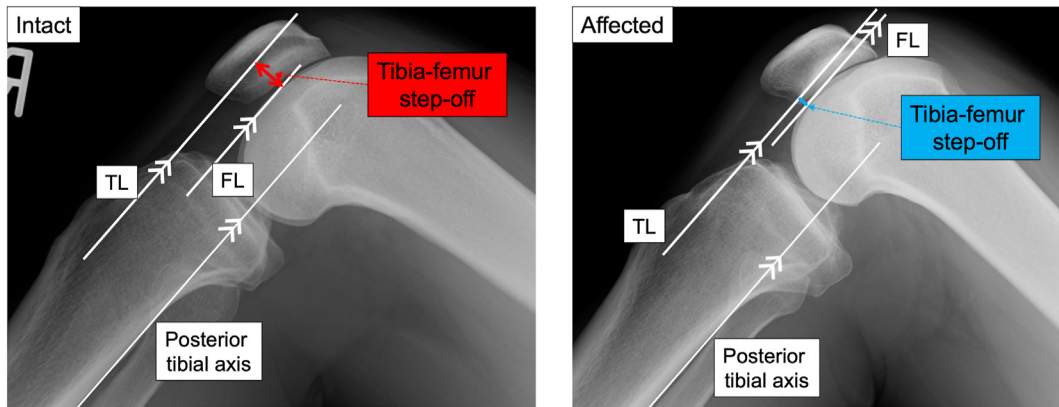
### 3. Results

#### 3.1. Graft morphology

Overall, the tension in the AL grafts was lax in two patients (8%), whereas that in the PM grafts was lax in four patients (15%) and unclassified due to graft tear in two patients (8%). The incidence rate of graft tension classified as lax/unclassified was significantly greater in the PM grafts with a significant difference ( $p = 0.043$ ). No tear was observed in the AL grafts, whereas five patients (19%) had tears in the PM grafts ( $p = 0.022$ ). The synovial coverage of the AL grafts was good in 23 patients (88%) and fair in three patients (12%), whereas no patients were categorized as poor. Meanwhile, the synovial coverage of the PM grafts was significantly poorer



**Fig. 1.** Arthroscopic classification of transplanted grafts based on synovial coverage. These figures were the evaluation of the posteromedial grafts. (A) Good: synovial coverage greater than 80% over the graft. (B) Fair: synovial coverage greater than 50% over the graft. (C) Poor: synovial coverage less than 50% around the graft. MFC, medial femoral condyle; AL, anterolateral; PM, posteromedial.



**Fig. 2.** Evaluation of the gravity sag view on lateral radiographs. The side-to-side difference of the tibia–femur step-off, which was the interval between the tibial and femoral lines, was defined as the posterior tibial translation. TL, tibial line; FL, femoral line.

( $p < 0.001$ ): fair in six patients (23%) and poor in seven patients (27%) (Fig. 3). Tear in the PM grafts were observed in one of the six patients showing fair synovial coverage and in four of the seven patients showing poor synovial coverage.

### 3.2. Chondral damage

To focus only on the effects of the PCLR on postoperative chondral status, three lesions simultaneously treated with drilling and osteochondral autograft transplantation in PCLR were excluded from the comparison in the second-look arthroscopic evaluation. Chondral damages on the LFC and LTP were significantly worsened postoperatively from PCLR to second-look arthroscopy ( $p = 0.029$  and  $p = 0.029$ ), whereas no significant changes in other compartments were observed (Fig. 4). The postoperative worsening of the chondral damages on the LFC and LTP significantly correlated with the intraoperative presence of lateral meniscal tears at the primary PCLR ( $p = 0.015$  and  $p = 0.024$ ), whereas no significant relationships were detected between chondral damages and graft morphology or postoperative PTT.

### 3.3. Clinical outcomes

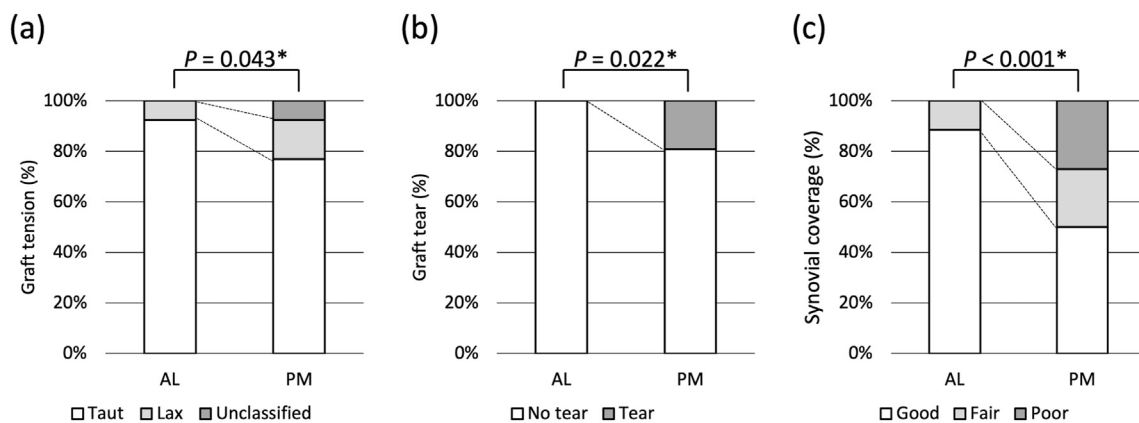
No patients had residual subjective posterior instability, knee

swelling, or loss of extension exceeding  $5^\circ$  or flexion exceeding  $10^\circ$ . All patients had improved from grade II or III preoperatively to grade I or grade II in the posterior drawer test. The PTT significantly improved from  $10.0 \pm 3.6$  mm (95% confidence interval (CI), 8.4–11.5) preoperatively to  $3.6 \pm 2.1$  mm (95% CI, 2.7–4.5) at second-look arthroscopy ( $p < 0.001$ ). No significant correlation was detected between the postoperative PTT and lax tension in the AL grafts ( $p = 0.345$ ). Likewise, no significant correlation was detected between the postoperative PTT and the morphology of the PM grafts: graft tear ( $p = 0.850$ ), graft tension classified as lax/unclassified ( $P = 0.541$ ), and poor synovial coverage ( $P = 0.828$ ).

### 3.4. Effects of patient age

Demographic data of the two patient groups were shown in Table 1. Chondral status in the LTP and MTP in group B was significantly worse than that in group A; however, no significant differences in other parameters were observed between the two groups.

The comparison of graft morphology, chondral damage, and the PTT at the second-look arthroscopy between the two patient groups were shown in Table 2. The synovial coverage of the PM grafts in group B was significantly poorer than that in group A ( $p = 0.033$ ); however, no significant differences in the other

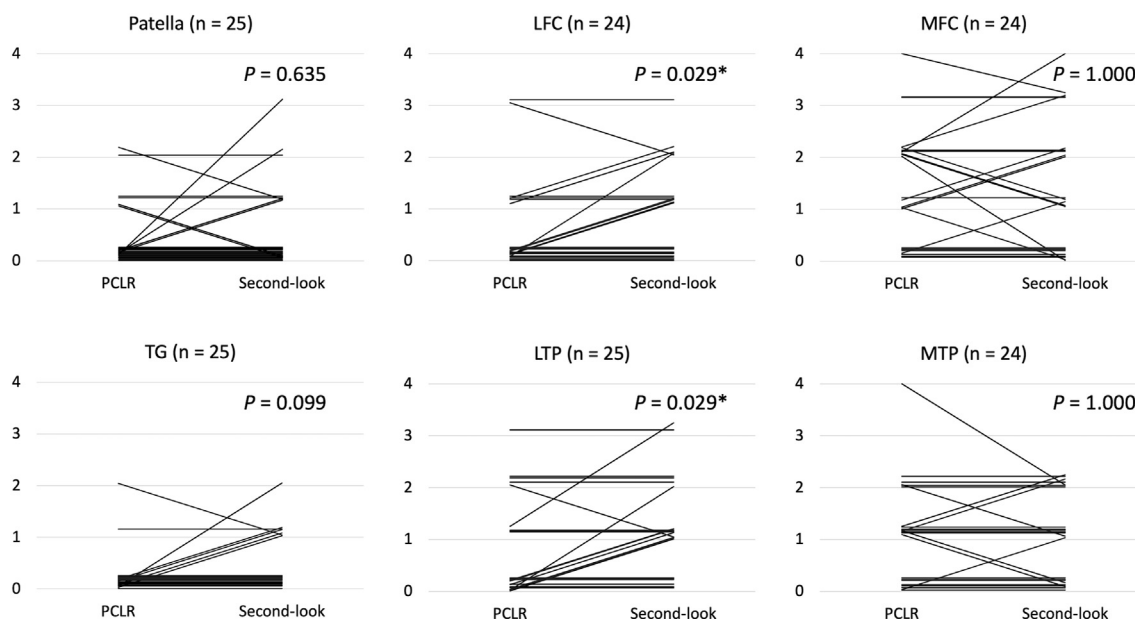


**Fig. 3.** Comparison of graft morphology between AL and PM grafts. (a) Graft tension: taut (white), lax (gray), and unclassified due to graft rupture (dark gray). (b) Graft tear: no tear (white) and tear (gray). (c) Synovial coverage over grafts: good (white), fair (gray), and poor (dark gray).

[AL, anterolateral; PM, posteromedial.

\*Statistically significant difference ( $p < 0.05$ ).





**Fig. 4.** Changes in chondral damages from primary PCLR to second-look arthroscopy. Patients whose operative/arthroscopic records were unavailable or who were simultaneously treated with osteochondral autograft transplantation or microfracture were excluded. PCLR, posterior cruciate ligament reconstruction; TG, trochlea groove; MFC, medial femoral condyle; LFC, lateral femoral condyle; MTP, medial tibial plateau; LTP, lateral tibial plateau. \*Statistically significant difference ( $p < 0.05$ ).

**Table 1**  
Comparison of demographic data of the two patient groups.

	Group A (n = 14)	Group B (n = 12)	P value
Sex (male/female)	14/0	10/2	0.203
Age (range) (years)	26.5 ± 6.8 (17–39)	45.3 ± 2.9 (40–49)	<0.001
Height (range) (cm)	170.8 ± 8.4 (157.0–186.5)	171.9 ± 8.7 (153.0–184.0)	0.699
Weight (range) (kg)	75.1 ± 19.0 (47.0–128.0)	78.6 ± 14.6 (46.0–96.0)	0.280
Body mass index (range) (kg/m <sup>2</sup> )	25.5 ± 5.3 (19.1–41.8)	26.4 ± 3.9 (19.7–33.5)	0.328
Time from injury to surgery (range) (months)	18.6 ± 13.4 (3–45)	113.4 ± 148.9 (3–388)	0.625
Time from PCLR to second-look arthroscopy (range) (months)	13.8 ± 3.4 (12–23)	15.0 ± 3.5 (12–20)	0.837
Injury mechanism (sports/other)	8/6	4/8	0.947
MM injury	1 (7%)	5 (42%)	0.065
LM injury	2 (14%)	3 (25%)	0.635
Chondral damage			
Patella (0/I/II/III/IV/N.A.)	11/2/0/0/0/1	8/2/2/0/0/0	0.244
TG (0/I/II/III/IV/N.A.)	13/0/0/0/0/1	9/1/1/0/1/0	0.060
LFC (0/I/II/III/IV/N.A.)	10/1/0/1/0/2	7/4/0/1/0/0	0.232
<b>LTP (0/I/II/III/IV/N.A.)</b>	<b>11/1/0/1/0/1</b>	<b>3/4/4/0/1/0</b>	<b>0.006*</b>
MFC (0/I/II/III/IV/N.A.)	7/1/4/1/1/0	1/4/4/1/2/0	0.123
<b>MTP (0/I/II/III/IV/N.A.)</b>	<b>8/4/1/1/0/0</b>	<b>0/7/4/0/1/0</b>	<b>0.006*</b>
Preoperative grade (I/II/III)	0/8/6	0/5/7	0.428
Preoperative PTT (mm)	9.6 ± 3.8 (5.1–18.3)	10.3 ± 3.7 (5.1–16.2)	0.661
Surgical procedure			
Bi-socket/Double-bundle	12/2	7/5	0.190
Femoral AL tunnel diameter (mm)	7.4 ± 0.6 (6.0–8.0)	7.3 ± 0.9 (6.5–9.0)	0.604
Femoral PM tunnel diameter (mm)	5.9 ± 0.4 (5.5–7.0)	5.8 ± 0.4 (5.0–7.0)	0.679
Tibial tunnel diameter (mm)			
Bi-socket	9.8 ± 0.6 (9.0–11.0)	9.7 ± 0.8 (9.0–11.0)	0.631
AL graft (double-bundle)	7.0 ± 1.4 (6.0–8.0)	7.5 ± 0.7 (6.5–8.0)	N.A. <sup>†</sup>
PM graft (double-bundle)	5.9 ± 0.2 (5.5–6.0)	6.8 ± 0.4 (6.5–7.0)	N.A. <sup>†</sup>
AL graft CSA (mm <sup>2</sup> )	29.3 ± 4.9 (21.7–37.5)	33.8 ± 6.5 (22.2–46.3)	0.093
PM graft CSA (mm <sup>2</sup> )	19.8 ± 2.2 (16.7–24.9)	17.9 ± 4.0 (10.4–24.0)	0.211

MM, medial meniscus; LM, lateral meniscus; TG, trochlea groove; MFC, medial femoral condyle; LFC, lateral femoral condyle; MTP, medial tibial plateau; LTP, lateral tibial plateau; N.A., not available; AL, anterolateral; PM, posteromedial; CSA, cross-sectional area; PTT, posterior tibial translation.

Note that statistical comparison could not be performed in the lines indicating <sup>†</sup> because there were only two patients in Group A.

\*Statistically significant difference ( $p < 0.05$ ).

parameters were detected between both groups. The chondral damages in group B were significantly advanced compared with those in group A, except for the chondral damages on the TG and

LFC. However, no significant difference in the clinical outcomes was perceived between the two groups.

**Table 2**  
Postoperative outcomes of two patient groups at second-look arthroscopy.

	Group A (n = 14)	Group B (n = 12)	P value
Graft morphology			
Tension			
AL (taut/lax/unclassified)	13/1/0	11/1/0	1.000
PM (taut/lax/unclassified)	11/3/0	9/1/2	0.635
Tear			
AL	0 (0%)	0 (0%)	1.000
PM	2 (14%)	3 (25%)	0.216
Synovial coverage			
AL (good/fair/poor)	13/1/0	10/2/0	0.580
<b>PM (good/fair/poor)</b>	<b>8/5/1</b>	<b>5/1/6</b>	<b>0.033*</b>
Chondral damage			
<b>Patella (0/I/II/III/IV/N.A./Tx.)</b>	<b>13/1/0/0/0/0/0</b>	<b>6/4/2/0/0/0/0</b>	<b>0.007*</b>
TG (0/I/II/III/IV/N.A./Tx.)	12/2/0/0/0/0/0	6/4/1/0/0/0/1 <sup>a</sup>	0.101
LFC (0/I/II/III/IV/N.A./Tx.)	10/1/2/1/0/0/0	4/6/2/0/0/0/0	0.258
<b>LTP (0/I/II/III/IV/N.A./Tx.)</b>	<b>8/4/1/1/0/0/0</b>	<b>0/7/3/1/1/0/0</b>	<b>0.010*</b>
<b>MFC (0/I/II/III/IV/N.A./Tx.)</b>	<b>9/2/1/1/1/0/1<sup>a</sup></b>	<b>0/3/5/1/1/0/1<sup>b</sup></b>	<b>0.002*</b>
<b>MTP (0/I/II/III/IV/N.A./Tx.)</b>	<b>9/4/1/0/0/1/0</b>	<b>0/5/7/0/0/0/0</b>	<b>&lt; 0.001*</b>
Subjective posterior instability	0 (0%)	0 (0%)	1.000
Knee swelling	0 (0%)	0 (0%)	1.000
Loss of extension >5°/flexion >10°	0 (0%)/0 (0%)	0 (0%)/0 (0%)	1.000/1.000
Postoperative grade (I/II/III)	11/3/0	12/2/0	1.000
Postoperative PTT (mm)	4.0 ± 2.0 (1.4–8.4)	2.9 ± 2.3 (–1.0–5.6)	0.471

TG, trochlea groove; MFC, medial femoral condyle; LFC, lateral femoral condyle; MTP, medial tibial plateau; LTP, lateral tibial plateau; N.A., not available; Tx., simultaneously treated for chondral damage; PTT, posterior tibial translation.

\*Statistically significant difference (*p* < 0.05).

<sup>a</sup> Simultaneously treated with osteochondral autograft transplantation for concomitant severe chondral damage.

<sup>b</sup> Simultaneously treated with bone marrow stimulation for concomitant severe chondral damage. Those cases indicating<sup>a</sup> or<sup>b</sup> were excluded from the comparison between the two groups.

#### 4. Discussion

The major findings in this study can be summed up as follows: (1) the morphology of the PM grafts at second-look arthroscopy was poorer than that of the AL grafts, and (2) a poorer synovial coverage over the PM grafts and more advanced chondral damages were observed in group B; however, clinical outcomes were not affected.

This was the first study to compare the morphology between AL and PM grafts after double-bundle PCLR for isolated PCL injury, and show that lax graft tension, graft tear, and poor synovial coverage were significantly observed more in the PM grafts than the AL grafts. Furthermore, a similar investigation has reported that graft rupture and graft loosening were observed in 30% and 10% cases among PL grafts after double-bundle PCLR, whereas no such findings were observed among AL grafts.<sup>8</sup> The AL bundle covers a larger area and are stiffer than the PM bundle.<sup>21,29</sup> Clinically, when using autogenous hamstring tendon grafts, that with a larger CSA is used for the AL graft, whereas that with a smaller CSA is used for the PM graft (e.g., the semitendinosus tendon for the AL graft and the gracilis tendon for the PM graft). Moreover, Harner et al. have shown that the *in situ* force of the PM graft was higher than the corresponding force of the AL graft under a posterior tibial load.<sup>30</sup> Consequently, PM grafts could be susceptible to higher mechanical stress than AL grafts, leading to poor PM graft morphology at second-look arthroscopy. Although it is not easily available in our country, the usage of a large-sized allograft including the Achilles's tendon allograft,<sup>1,2</sup> may not only cover the wide PCL attachment area but also reduce the graft laxity or tear. No significant correlation was perceived between the poor arthroscopic findings of the transplanted grafts and the increased posterior PTT in this study, whereas a previous study has reported that a larger postoperative PTT was observed in patients with ruptured PM grafts.<sup>8</sup> However, that study included patients with combined ligamentous injuries, and the healing status of the concomitant ligaments could affect their results. Additionally, when the PTT was evaluated at 90° of

knee flexion, the AL bundle significantly contributes to the posterior knee stability rather than the PM bundle.<sup>21</sup> In our case series, the AL graft tension was lax in only two patients, but no tear was observed, which potentially led to no significant difference between the graft morphology and postoperative PTT. This study demonstrated that no progression was observed in the patellofemoral or medial tibiofemoral compartment from primary PCLR to second-look arthroscopy at 14 months. Biomechanically, PCL insufficiency causes not only increased PTT but also elevated contact pressures of the patellofemoral and medial tibiofemoral compartments.<sup>31</sup> In addition, arthroscopic studies have reported that chondral damages in those compartments were frequently observed in patients with acute PCL injury<sup>32</sup> and the incidence of chondral damages in those compartments increased over time after PCL injury.<sup>33</sup> The results of this study indicated that our PCLR could prevent serial chondral worsening in those compartments due to PCL deficiency during the short term. However, a further follow-up investigation would be warranted, since recent studies have compared the chondral degeneration using MRI at least five years after PCLR and one year later and reported that PCLR-reconstructed knees displayed progression of cartilage degeneration in the medial tibiofemoral and patellofemoral compartments compared with uninjured controls.<sup>34,35</sup> Meanwhile, chondral worsening was observed in the lateral tibiofemoral compartment and was correlated with concomitant lateral meniscal tears. In our case series, lateral meniscectomy was performed in three patients, whereas lateral meniscal repair was performed in two patients: the repaired meniscus was completely healed in one patient and unhealed in the other at the second-look arthroscopy. In a recent investigation, Gwinner et al. have shown that concomitant meniscal surgery was one of the potential risk factors for worse whole-organ MRI score five years after PCLR.<sup>35</sup> Thus, the incidence of concomitant meniscal tears with PCL injury could lead to secondary osteoarthritis change, similar to those with ACL injury.<sup>36,37</sup>

This study firstly demonstrated that poorer synovial coverage over PM grafts and more advanced chondral damages were

observed in the patient group aged 40 years or over, whereas no differences in clinical outcomes were detected. In the reviews comparing the clinical results after ACLR between patients aged  $\geq 40$  years and those aged  $< 40$  years, no significant differences in the anterior knee laxity, complications, or clinical scores were reported.<sup>13,14</sup> However, Kinugasa et al. have investigated the morphology of grafts at second-look arthroscopy after anatomic double-bundle ACLR and reported that the synovial coverage was significantly poor, and the incidence of tears tended to be larger in patients aged  $\geq 50$  years.<sup>16</sup> Asano et al. have reported that patient age  $\geq 30$  years was a risk factor for more advanced chondral damages at second-look arthroscopy after ACLR.<sup>24</sup> Although the cut-off value of patient age varied among studies, these findings indicated that aging could delay the remodeling of the grafts and increase the vulnerability of the cartilage to damage. Some basic investigations have indicated that the tissue healing potential declines with aging.<sup>38,39</sup> For cartilages, accumulation of advanced glycation end-products with aging causes non-enzymatic collagen crosslinking, directly altering the mechanical properties of the extracellular matrix.<sup>40,41</sup> There were 3 patients with chronic PCL deficiency more than 5 years in the group B and the average and standard deviation of time from injury to surgery in the group B was consequently increased. In this study, the non-parametric analysis did not detect any significant difference of time from injury to surgery. However, this non-significant difference might potentially contribute the chondral status, since a previous study reported that severer chondral damages were observed more frequently in cases with chronic PCL deficiency more than 5 years.<sup>33</sup> Thus, this study indicated that the postoperative arthroscopic findings can be inferior in middle-aged patients even though the clinical outcomes are comparable to those in young patients. The clinical implication in this study was that although patient age did not negatively affect the clinical outcomes in a short term, those inferior arthroscopic findings could worsen clinical outcomes in a long-term observation.

Concerning the surgical procedure, the cases treated with the bi-socket PCLR and the ones with the double-bundle PCLR were combined in this case series of surgically-treated isolated PCL injury with a relatively limited number. Several authors regarded the bi-socket procedure with two femoral tunnels and one tibial tunnel as 'double-bundle procedure'.<sup>1,2</sup> In the present study, no significant difference was detected between the two procedures in terms of the graft morphology at second-look arthroscopy or the postoperative posterior tibial translation. Although two femoral tunnels were created in both procedures and the graft morphology around the femoral tunnel aperture was evaluated via standard anteromedial and anterolateral portals, the one around the tibial tunnel aperture was not evaluated via the posteromedial portal. Thus, there might be some unaddressed differences of the graft morphology around the tibial tunnel between the two procedures with one or two tibial tunnels.

Although the posterior tibial translation was significantly improved through PCLR, the preoperative value was approximately 10 mm in both groups. All the patients in this series were treated as an isolated PCL injury, based on the negative findings on the varus, valgus, and dial tests, and no other concomitant ligamentous injuries (posterolateral/posteromedial corner injuries) on magnetic resonance images. There was no case with a high-energy trauma, which could cause multiple ligament injuries or knee dislocation, although it was difficult to quantitatively measure the size of trauma in each case. However, a cadaveric study has demonstrated that the large posterior tibial translation  $\geq 10$  mm could be combined with collateral ligamentous or capsular injuries.<sup>42</sup> Pacheco et al. warned that the correct diagnosis of posterolateral corner injury via magnetic resonance images was approximately 25% if the examination was performed more than 12 weeks after the injury.<sup>43</sup>

Thus, unaddressed or unrecognized disruptions of secondary posterior restraints, including minor posteromedial/posterolateral capsular injuries/stretching, might be included in some patients.

This study has several limitations. In some patients, data on chondral damages at primary PCLR and second-look arthroscopy were unavailable. Graft morphology around the tibial tunnel was not evaluated via the posteromedial portal at the second-look arthroscopy. Since only 26 cases underwent second-look arthroscopy out of 83 cases after PCL reconstruction, the result in this study could not be simply applied to the whole study population. We did not evaluate the histological remodeling process of the grafts but evaluated the maturation of the surface of the grafts, since the biopsy specimens could not be obtained from an ethical perspective. Power analysis was not conducted due to the small sample size. The mean interval between the primary PCLR and second-look arthroscopy was only 14 months, and the morphology of both AL graft and PM graft and the chondral status might be worsened over time with a long-term observation. Finally, the cases treated with the bi-socket PCLR and the ones with the double-bundle PCLR were combined. The graft morphology around the femoral tunnel aperture was evaluated in both procedures with two femoral tunnels in this series. However, there might be unaddressed differences of that around the tibial tunnel aperture due to the different number of tibial tunnel.

## 5. Conclusions

The morphology of the PM grafts at second-look arthroscopy after double-bundle PCLR was poorer than that of the AL grafts. Patient age negatively affected the postoperative graft synovial coverage and chondral status but did not affect the clinical outcomes.

## Authorship statement

Y. Tachibana: Conception and design of study, acquisition of data, analysis and/or interpretation of data, Drafting the manuscript, Conception and design of study, analysis and/or interpretation of data, revising the manuscript critically for important intellectual content, Approval of the version of the manuscript to be published.

S. Horibe: revising the manuscript critically for important intellectual content, Conception and design of study, Approval of the version of the manuscript to be published.

K. Kinugasa: analysis and/or interpretation of data, Approval of the version of the manuscript to be published.

## Conflicts of interest

The authors declare that they have no conflicts of interest associated with the present study.

## Acknowledgements

This manuscript was proofread by a native English speaker of Enago (<https://www.enago.jp>).

## References

1. Chahla J, Moatshe G, Cinque ME, et al. Single-bundle and double-bundle posterior cruciate ligament reconstructions: a systematic review and meta-analysis of 441 patients at a minimum 2 years' follow-up. *Arthroscopy*. 2017;33:2066–2080.
2. LaPrade RF, Cinque ME, Dornan GJ, et al. Double-bundle posterior cruciate ligament reconstruction in 100 patients at a mean 3 years' follow-up: outcomes were comparable to anterior cruciate ligament reconstructions. *Am J*

- Sports Med.* 2018;46:1809–1818.
3. Alcalá-Galiano A, Baeva M, Ismael M, Argüeso MJ. Imaging of posterior cruciate ligament (PCL) reconstruction: normal postsurgical appearance and complications. *Skeletal Radiol.* 2014;43:1659–1668.
  4. Park HJ, Lee SY, Hong HP, et al. Usefulness of oblique coronal magnetic resonance images of the knee after posterior cruciate ligament reconstruction. *Br J Radiol.* 2016;89:20160373.
  5. Otsubo H, Shino K, Nakamura N, Nakata K, Nakagawa S, Koyanagi M. Arthroscopic evaluation of ACL grafts reconstructed with the anatomical two-bundle technique using hamstring tendon autograft. *Knee Surg Sports Traumatol Arthrosc.* 2007;15:720–728.
  6. Tanaka Y, Shino K, Horibe S, et al. Triple-bundle ACL grafts evaluated by second-look arthroscopy. *Knee Surg Sports Traumatol Arthrosc.* 2012;20:95–101.
  7. Mae T, Shino K, Nakagawa S, et al. Second-look arthroscopy after anatomic anterior cruciate ligament reconstruction: bone-patellar tendon-bone versus hamstring tendon graft. *J Orthop Sci.* 2019;24:488–493.
  8. Hatayama K, Higuchi H, Kimura M, Kobayashi Y, Asagumo H, Takagishi K. A comparison of arthroscopic single- and double-bundle posterior cruciate ligament reconstruction: review of 20 cases. *Am J Orthoped.* 2006;35:568–571.
  9. Yang JH, Yoon JR, Jeong HI, et al. Second-look arthroscopic assessment of arthroscopic single-bundle posterior cruciate ligament reconstruction: comparison of mixed graft versus Achilles tendon allograft. *Am J Sports Med.* 2012;40:2052–2060.
  10. Stiefel M, Knechtel B, Lepers R. Master triathletes have not reached limits in their Ironman triathlon performance. *Scand J Med Sci Sports.* 2014;24:89–97.
  11. Jokl P, Sethi PM, Cooper AJ. Master's performance in the New York city marathon 1983-1999. *Br J Sports Med.* 2004;38:408–412.
  12. Sanders TL, Maradit Kremers H, Bryan AJ, et al. Incidence of anterior cruciate ligament tears and reconstruction: a 21-year population-based study. *Am J Sports Med.* 2016;44:1502–1507.
  13. Corona K, Ronga M, Morris BJ, et al. Comparable clinical and functional outcomes after anterior cruciate ligament reconstruction over and under 40 years of age. *Knee Surg Sports Traumatol Arthrosc.* 2020;28:1932–1945.
  14. Kim KT, Kim HJ, Lee HI, et al. A comparison of results after anterior cruciate ligament reconstruction in over 40 and under 40 years of age: a meta-analysis. *Knee Surg Relat Res.* 2018;30:95–106.
  15. Yoon KH, Lee HW, Park JY, Kim SJ, Kim SG. Clinical outcomes and the failure rate of revision anterior cruciate ligament reconstruction were comparable between patients younger than 40 years and patients older than 40 years: a minimum 2-year follow-up study. *Arthroscopy.* 2020;36:2513–2522.
  16. Kinugasa K, Mae T, Matsumoto N, Nakagawa S, Yoneda M, Shino K. Effect of patient age on morphology of anterior cruciate ligament grafts at second-look arthroscopy. *Arthroscopy.* 2011;27:38–45.
  17. Hughston JC, Andrews JR, Cross MJ, Moschi A. Classification of knee ligament instabilities. Part I. The medial compartment and cruciate ligaments. *J Bone Joint Surg Am.* 1976;58(2):159–172.
  18. Costa LAV, Mestriner MB, Amaral TAD, Barbosa BDS, Kaleka CC, Cury RPL. Histological study of the posterior cruciate ligament femoral insertion. *Rev Bras Ortop.* 2018;53:415–420.
  19. Anderson CJ, Ziegler CG, Wijdicks CA, Engebretsen L, LaPrade RF. Arthroscopically pertinent anatomy of the anterolateral and posteromedial bundles of the posterior cruciate ligament. *J Bone Joint Surg Am.* 2012;94:1936–1945.
  20. Jung YB, Tae SK, Lee YS, Jung HJ, Nam CH, Park SJ. Active non-operative treatment of acute isolated posterior cruciate ligament injury with cylinder cast immobilization. *Knee Surg Sports Traumatol Arthrosc.* 2008;16:729–733.
  21. Race A, Amis AA. Loading of the two bundles of the posterior cruciate ligament: an analysis of bundle function in a P drawer. *J Biomech.* 1996;29:873–879.
  22. Toritsuka Y, Shino K, Horibe S, et al. Second-look arthroscopy of anterior cruciate ligament grafts with multistranded hamstring tendons. *Arthroscopy.* 2004;20:287–293.
  23. Outerbridge RE. The aetiology of chondromalacia patellae. *J Bone Joint Surg Br.* 1961;43:752–757.
  24. Asano H, Muneta T, Ikeda H, Yagishita K, Kurihara Y, Sekiya I. Arthroscopic evaluation of the articular cartilage after anterior cruciate ligament reconstruction: a short-term prospective study of 105 patients. *Arthroscopy.* 2004;20:474–481.
  25. Nakamura N, Horibe S, Toritsuka Y, et al. The location-specific healing response of damaged articular cartilage after ACL reconstruction: short-term follow-up. *Knee Surg Sports Traumatol Arthrosc.* 2008;16(9):843–848.
  26. Shino K, Mitsuoka T, Horibe S, Hamada M, Nakata K, Nakamura N. The gravity sag view: a simple radiographic technique to show posterior laxity of the knee. *Arthroscopy.* 2000;16:670–672.
  27. Jackman T, LaPrade RF, Pontinen T, Lender PA. Intraobserver and interobserver reliability of the kneeling technique of stress radiography for the evaluation of posterior knee laxity. *Am J Sports Med.* 2008;36:1571–1576.
  28. Tachibana Y, Tanaka Y, Kinugasa K, Mae T, Horibe S. Tunnel enlargement correlates with postoperative posterior laxity after double-bundle posterior cruciate ligament reconstruction. *Orthop J Sports Med.* 2021;19(1):9. <https://doi.org/10.1177/2325967120977834>.
  29. Race A, Amis AA. The mechanical properties of the two bundles of the human posterior cruciate ligament. *J Biomech.* 1994;27:13–24.
  30. Harner CD, Janaushek MA, Ma CB, Kanamori A, Vogrin TM, Woo SL. The effect of knee flexion angle and application of an anterior tibial load at the time of graft fixation on the biomechanics of a posterior cruciate ligament-reconstructed knee. *Am J Sports Med.* 2000;28:460–465.
  31. Van de Velde SK, Bingham JT, Gill TJ, Li G. Analysis of tibiofemoral cartilage deformation in the posterior cruciate ligament-deficient knee. *J Bone Joint Surg Am.* 2009;91:167–175.
  32. Hamada M, Shino K, Mitsuoka T, Toritsuka Y, Natsu-Ume T, Horibe S. Chondral injury associated with acute isolated posterior cruciate ligament injury. *Arthroscopy.* 2000;16:59–63.
  33. Strobel MJ, Weiler A, Schulz MS, Russe K, Eichhorn HJ. Arthroscopic evaluation of articular cartilage lesions in posterior-cruciate-ligament-deficient knees. *Arthroscopy.* 2003;19:262–268.
  34. Culvenor AG, Wirth W, Boeth H, Duda GN, Eckstein F. Longitudinal changes in location-specific cartilage thickness and T2 relaxation-times after posterior cruciate ligament reconstruction for isolated and multiligament injury. *Clin Biomech.* 2020;79:104935.
  35. Gwinner C, Weiler A, Denecke T, Rogasch JMM, Boeth H, Jung TM. Degenerative changes after posterior cruciate ligament reconstruction are irrespective of posterior knee stability: MRI-based long-term results. *Arch Orthop Trauma Surg.* 2018;138:377–385.
  36. Hiranaka T, Furumatsu T, Kamatsuki Y, et al. Early chondral damage following meniscus repairs with anterior cruciate ligament reconstruction. *Asia Pac J Sports Med Arthrosc Rehabil Technol.* 2020;20:1–5.
  37. Tsujii A, Yonetani Y, Kinugasa K, et al. Outcomes more than 2 years after meniscal repair for radial/flap tears of the posterior lateral meniscus combined with anterior cruciate ligament reconstruction. *Am J Sports Med.* 2019;47:2888–2894.
  38. Gosain A, DiPietro LA. Aging and wound healing. *World J Surg.* 2004;28:321–326.
  39. Stolzing A, Jones E, McGonagle D, Scutt A. Age-related changes in human bone marrow-derived mesenchymal stem cells: consequences for cell therapies. *Mech Ageing Dev.* 2008;129:163–173.
  40. Bank RA, Bayliss MT, Lafeber FP, Maroudas A, Tekoppele JM. Ageing and zonal variation in posttranslational modification of collagen in normal human articular cartilage. The age-related increase in non-enzymatic glycation affects biomechanical properties of cartilage. *Biochem J.* 1998;330:345–351.
  41. Verzijl N, DeGroot J, Ben ZC, et al. Crosslinking by advanced glycation end products increases the stiffness of the collagen network in human articular cartilage: a possible mechanism through which age is a risk factor for osteoarthritis. *Arthritis Rheum.* 2002;46(1):114–123.
  42. Sekiya JK, Whiddon DR, Zehms CT, Miller MD. A clinically relevant assessment of posterior cruciate ligament and posterolateral corner injuries. Evaluation of isolated and combined deficiency. *J Bone Joint Surg Am.* 2008;90(8):1621–1627.
  43. Pacheco RJ, Ayre CA, Bollen SR. Posterolateral corner injuries of the knee: a serious injury commonly missed. *J Bone Joint Surg Br.* 2011 Feb;93(2):194–197.