



Oncology

Paraurethral Leiomyoma in a 20 Year-old Woman: A Case Report

Emily Adams-Piper^{a,*}, Stephanie Jacobs^a, Gamal M. Ghoniem^b^a Department of Obstetrics/Gynecology, Division of Urogynecology, University of California, Irvine, Orange, CA, United States^b Department of Urology, University of California, Irvine, Orange, CA, United States

ARTICLE INFO

Article history:

Received 11 October 2015

Accepted 20 October 2015

Keywords:

Paraurethral leiomyoma

Vaginal mass

ABSTRACT

We present the case of a 20 year-old woman with a vulvar mass, found to be a paraurethral leiomyoma. She subsequently underwent supermedial-approach paraurethral mass excision, distal urethral reconstruction and cystourethroscopy. Paraurethral leiomyoma make up approximately five percent of urethral tumors. This case depicts the presentation and treatment of a paraurethral leiomyoma in one of the youngest women reported in the literature.

© 2016 The Authors. Published by Elsevier Inc. This is an open access article under the CC BY-NC-ND license (<http://creativecommons.org/licenses/by-nc-nd/4.0/>).

Introduction

The differential diagnosis for paraurethral mass includes an extensive list of pathologies arising from structures of both of urologic and gynecologic origin. Such masses have a wide variety of symptomatology, which range from asymptomatic to a severely impacted quality of life. Examples of benign causes include urethral diverticuli, vaginal wall cysts (including Skene's gland cysts), urethral prolapse/caruncles, and urethral leiomyoma. When symptoms warrant treatment, surgical excision of the mass is typically undertaken, with the procedure performed dictated by the pathology.

We describe an unusual case of an incidentally found paraurethral leiomyoma in an adolescent woman, who lacked typical risk factors for development of leiomyoma.

Case report

A 20 year-old virginal woman, without history of prior surgery, was referred to urogynecology clinic for a vulvar mass found during a pelvic examination for menometrorrhagia. Prior to specialist referral, she underwent a transabdominal pelvic ultrasound, which was reported as normal.

In urogynecology clinic, the patient denied lower urinary tract symptoms, including urgency, frequency, incontinence, incomplete voiding or nocturia. She denied pelvic pain or pressure. She did report a change in urine stream months earlier with intermittent spraying of urine. Examination noted a 5 cm by 3 cm firm, ovoid

mass protruding from the vaginal introitus. The mass was tender to palpation and remaining examination (including identification of the urethral opening) was limited by patient discomfort.

Pelvic MRI was obtained. It demonstrated a circumscribed, solid mass "arising from the inferior third of the vagina protruding through the introitus or arising from the urethra superficial to the urogenital diaphragm" with a normal cervix, uterus, tubes and ovaries (Fig. 1).

The patient was scheduled for pelvic examination under anesthesia, cystourethroscopy and biopsy of vaginal mass. Examination revealed the urethral orifice posterior to the mass (Fig. 2). Cystourethroscopy was normal, with an intact urethral sphincter noted. Four biopsies were obtained and pathology returned as benign leiomyoma.

The patient was subsequently referred to a reconstructive female urologist for definitive resection. Findings at the time of surgery included a 5 cm mass with a 2.5 cm stalk, attached from the superior aspect of the urethral meatus to the posterior aspect of the pubic symphysis. The mass was excised intact. Periurethral tissues were reapproximated in multiple layers to the fascial attachments posterior to the pubic bone and the suspensory ligament of the clitoris. After urethral support was reconstructed, there was noted to be a significant excess of posterior urethral mucosa. Excess mucosa was excised and subsequent examination confirmed adequate support of the periurethral tissues (see Fig. 3). A urethral catheter was left in place for 8 days to prevent formation of distal urethral stricture.

Pathology of the excised specimen was consistent with pathology of prior biopsies. It demonstrated complete resection of a benign, submucous leiomyoma. Pathology of the urethral mucosa showed chronic inflammation but was without concerning features.

Following surgery, the patient did well and passed a voiding trial at the time of removal of the urethral catheter. She had no urinary

* Corresponding author. UC Irvine Medical Center, 101 The City Drive South, Orange, CA 92868, United States.

E-mail address: eadamspi@uci.edu (E. Adams-Piper).

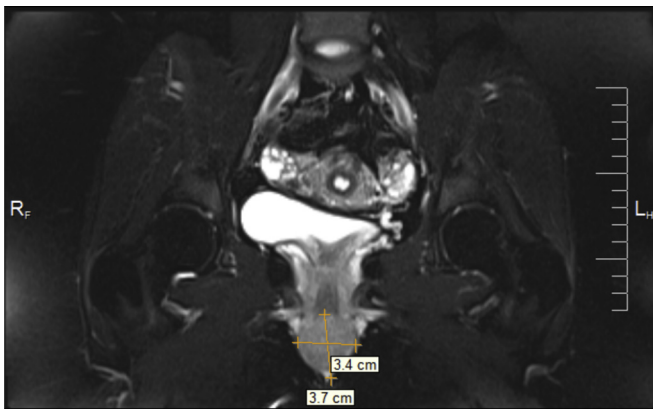


Figure 1. MRI showing size and location of paraurethral leiomyoma.

incontinence or difficulty urinating following surgery but did report increased urinary frequency and occasional urgency. Postoperative pelvic examinations showed appropriate healing without complication. Work up of urinary frequency and urgency was deferred until 3 months after surgery.

Discussion

Paraurethral leiomyomas are a rare cause of periurethral masses and often grouped in studies with other smooth muscle tumors of the lower urinary tract. While the etiology of bladder, urethral and paraurethral leiomyoma is unknown, the relatively elevated incidence in reproductive age women (compared to younger and older women or men), has led to speculation that leiomyoma growth is enhanced by circulating female hormones.¹ The majority of women treated for such tumors are in their thirties and forties, with a mean age of 40–44 years old.^{1–3} This case describes the second youngest patient reported in the literature treated for a paraurethral leiomyoma.⁴

Periurethral masses are themselves uncommon, with a retrospective case series finding that they comprise less than 5% of patients being seen at a tertiary, referral urogynecology practice. Urethral and paraurethral leiomyoma make up just 5–7% of periurethral masses.⁵ Urethral diverticulum comprise the vast majority of periurethral masses and vaginal cysts are a similar percentage of periurethral masses as urethral leiomyoma.^{3,5}

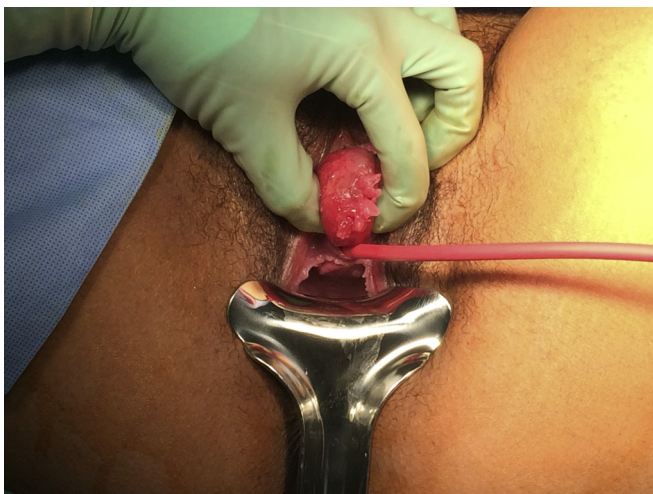

Figure 2. Demonstration of paraurethral mass at time of examination under anesthesia.

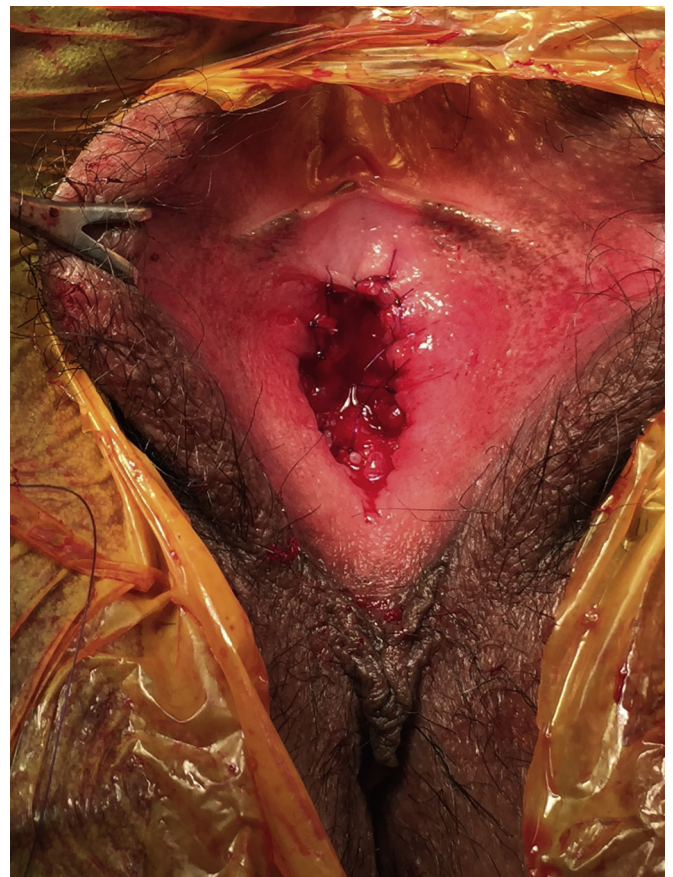

Figure 3. Urethral orifice immediately following resection and reconstruction.

Work-up for periurethral masses includes a detailed history and examination, and if the diagnosis is not clear or is concerning for more complicated pathology, imaging and cystoscopy may be employed. MRI provides superior resolution of the lower urinary tract including diverticuli. Although pelvic ultrasound (trans-abdominal or transvaginal) has limited utility and may overlook distal masses (as occurred in this case), perineal/translabial ultrasound may be useful, with lower cost and faster access. The likelihood of malignancy in any periurethral masses is low, but in the case of solid masses, biopsy may provide additional information to enable appropriate preoperative planning.

Surgical resection of paraurethral leiomyoma requires detailed knowledge of the location of the mass and the anatomy of the female urethra to facilitate reconstruction. In this case, cystoscopy and MRI were able to confirm that the mass was at the level to the distal urethra, there was a normal urethral lumen and the mass did not abut the internal urethral sphincter. Although often confused by providers and in the literature,¹ preoperative distinction between urethral and paraurethral fibroids aids in surgical planning and patient counseling regarding postoperative management and outcomes.

This patient's major continence mechanism was not disrupted, but resection of the mass required severing the distal urethral supports. Reconstruction required careful reapproximation of the urethral adventitia to the tissue at the pubic symphysis and the remaining anterior urethropelvic ligament in order to prevent urethral hypermobility. Excess urethral mucosa was excised and the urethral orifice reconstructed to prevent urethral prolapse.

Given location and symptoms, particularly hematuria or obstruction,² bladder leiomyoma in women are often treated by

urologists. In contrast, typical presentation of urethral/paraurethral leiomyoma (palpable pelvic mass, dysfunctional voiding, urinary tract infection and pain) often leads patients to gynecologists or urogynecologists. It is important that all specialists in female pelvic medicine be familiar with the broad differential of paraurethral masses in order to streamline the patient experience and facilitate favorable patient outcomes.

Conflict of interest

The authors declare they have no conflicts of interest.

References

1. Özel Begüm, Ballard Charles. Urethral and paraurethral leiomyomas in the female patient. *Int Urogynecol J.* 2006;17(1):93–95.
2. Cornella JL, Larson TR, Lee RA, et al. Leiomyoma of the female urethra and bladder: report of twenty-three patients and review of the literature. *Am J Obstet Gynecol.* 1997;176(6):1278–1285.
3. Tunitsky Elena, Goldman Howard B, Ridgeway Beri. Periurethral mass: a rare and puzzling entity. *Obstet Gynecol.* 2012;120(6):1459–1464.
4. Kuramoto T, Nishizawa S, Mori T, et al. Giant paraurethral leiomyoma in the female: a case report. *Hinyokika Kyo.* 2008;54(10):677–680.
5. Blaivas JG, Flisser AJ, Bleustein CB, Panagopoulos G. Periurethral masses: etiology and diagnosis in a large series of women. *Obstet Gynecol.* 2004;103(5, Part 1): 842–847.