

Original article:

HEPATOPROTECTIVE ACTIVITY OF CINNAMON ETHANOLIC EXTRACT AGAINST CCL₄-INDUCED LIVER INJURY IN RATS

Akram Eidi^{1*}, Pejman Mortazavi², Maryam Bazargan¹, Jalal Zaringhalam³

¹ Department of Biology, Science and Research Branch, Islamic Azad University, Tehran, Iran

² Department of Pathology, Faculty of Specialized Veterinary Sciences, Science and Research Branch, Islamic Azad University, Tehran, Iran

³ Department of Physiology, Shahid Beheshti University of Medical Sciences, Tehran, Iran

* corresponding author: Department of Biology, Science and Research Branch, Islamic Azad University, P.O. Box 16535-446, Tehran, Iran, E-mail: ehidi@srbiau.ac.ir, akram_eidi@yahoo.com, Tel: +98 9123380064, Fax: +9821 44865939

ABSTRACT

The inner bark of cinnamon (*Cinnamomum zeylanicum* L.) is commonly used as a spice and has also been widely employed in the treatment and prevention of disease. The aim of the present study is to evaluate the protective effect of cinnamon bark extract against carbon tetrachloride (CCl₄)-induced liver damage in male Wistar rats. Administration with cinnamon extracts (0.01, 0.05 and 0.1 g/kg) for 28 days significantly reduced the impact of CCl₄ toxicity on the serum markers of liver damage, aspartate aminotransferase, alanine aminotransferase and alkaline phosphatase. In addition, treatment of cinnamon extract resulted in markedly increased the levels of superoxide dismutase and catalase enzymes in rats. The histopathological studies in the liver of rats also supported that cinnamon extract markedly reduced the toxicity of CCl₄ and preserved the histoarchitecture of the liver tissue to near normal. Thus, the results suggest that cinnamon extract acts as a potent hepatoprotective agent against CCl₄ induced hepatotoxicity in rats.

Keywords: Carbon tetrachloride, *Cinnamomum zeylanicum* L., cinnamon, hepatoprotective, rat

INTRODUCTION

The liver as a vital organ in the body is primarily responsible for the metabolism of endogenous and exogenous agents. It plays an important role in drug elimination and detoxification and liver damage may be caused by xenobiotics, alcohol consumption, malnutrition, infection, anaemia and medications (Mroueh et al., 2004). Hepatotoxicity is defined as injury to the liver that is associated with impaired liver function caused by exposure to a drug or another non-infectious agent (Navarro and Senior, 2006). Hepatotoxic agents can react with the basic cellular components and consequently induce almost all types of liver le-

sions. Toxins and drugs are among the basic etiopathogenetic agents of acute liver failure in Western countries (Grattagliano et al., 2009). Nevertheless, chemical toxins (including acetaminophen, carbon tetrachloride, galactosamine and thioacetamide) are often used as the model substances causing experimental hepatocyte injury in both in vivo and in vitro conditions (Domenicali et al., 2009; Kucera et al., 2006; Ledda-Columbano et al., 1991; Rousar et al., 2009). Despite the fact that hepatic problems are responsible for a significant number of liver transplantations and deaths recorded worldwide, available pharmacotherapeutic options for liver diseases are very

limited and there is a great demand for the development of new effective drugs. A number of studies have shown that the plant extracts having antioxidant activity protect against CCl₄ hepatotoxicity by inhibiting lipid peroxidation and enhancing antioxidant enzyme activity (Shahjahan et al., 2004; Sheweita et al., 2001).

Cinnamon (*Cinnamomum zeylanicum* L., Lauraceae) is a tropical evergreen tree and grows wild in Sri Lanka, Madagascar, India and Indochina. The inner bark of the tree has been used in ethno-medicine and flavoring for foods (Bakkali et al., 2008; Baytop, 1999). In addition to its culinary uses, cinnamon has been employed in traditional herbal medicine to treat a variety of health conditions (Gruenwald et al., 2010). Some studies showed that extracts and its constituents from cinnamon also possess antimicrobial (Carmo et al., 2008; Chao et al., 2000; Dusan et al., 2006; Ranasinghe et al., 2002; Shahverdi et al., 2007), insecticidal (Yang et al. 2005), acaricidal (Fichi et al., 2007), antityrosinase (Marongiu et al., 2007), antioxidant and antimutagenic (Jayaprakasha et al., 2007) activities. In addition, other evidence suggests that cinnamon may be effective in the treatment of cancer (Hyeon et al., 2003; Nishida et al., 2003) and infectious diseases (Hayashi et al., 2007; Premanathan et al., 2000), and that it also shows anti-inflammatory (Hong et al., 2002; Tung et al., 2008), antioxidant (Su et al., 2007; Murcia et al., 2004; Okawa et al., 2001), hypotensive (Preuss et al., 2006), and cholesterol-lowering effects (Khan et al., 2003; Subash Babu et al., 2007). The present study investigates the hepatoprotective potential of cinnamon ethanolic extract treatment against CCl₄-induced liver toxicity in rats.

MATERIALS AND METHODS

Chemicals

CCl₄ was obtained from Merck, Germany. Assay kits for alanine aminotransferase (ALT), aspartate aminotransferase (AST), alkaline phosphatase (ALP), total protein, superoxide dismutase (SOD) and catalase

(CAT) were purchased from Parsazmoon Company of Iran. All other reagents used in the experiment were of analytical grade.

Preparation of the plant powder and extraction

The plant materials were obtained from the local market. Shade dried cinnamon bark was milled and extracted using ethanol 80 % in Soxhlet apparatus for 8 h. Then, the extract was evaporated to dryness and the final dry extract was stored in dark at -20 °C until used for the experiments. The percentage yield of extract was 17.7 % (w/w) of the initial raw material.

Phytochemical analysis

The qualitative phytochemical analysis of the crude extract of *Cinnamomum zeylanicum* L. bark was carried out to determine the active phytochemical constituents which were responsible for the hepatoprotective activity. Some of these methods were as follows:

20 mg extract was dissolved in 10 ml ethanol and filtered. 0.5 ml conc. HCl and magnesium ribbon were added to 2 ml filtrate. Development of pink-tomato red color indicated the presence of flavonoids (Parekh et al., 2006). 20 mg extract was dissolved in 2 ml distilled water and filtered. 2 ml FeCl₃ was added to the filtrate, blue-black precipitate indicated the presence of tannins (Parekh et al., 2006). To 0.5 ml of the filtrate obtained in alkaloids test 5 ml distilled water was added. Frothing persistence indicated the presence of saponins (Parekh et al., 2006). 20 mg extract was dissolved in 2 ml distilled water and filtered. To the filtrate, 2-4 drops of 1 % HCl was added and steam was passed through it. To the 1 ml of this solution 6 drops of Wagner's reagent was added. Brownish-red precipitate indicated the presence of alkaloids (Finar, 2003). Salkovski test was performed using a small amount of extract solution. To this solution 5 drops of conc. H₂SO₄ and 1 ml chloroform were added. Change of yellow color into red indicated the presence of terpenoids (Finar, 2003). A

small amount of material was extracted in ethanol and evaporated to dryness. Residue was dissolved in distilled water and 0.5 ml Folin-ciocalteu reagent was added followed by 2 ml 20 % Na₂CO₃ solution. Development of bluish color indicated the presence of phenols (Sadasivam and Manickam, 1996).

Animals

Adult male Wistar rats weighing 200-230 g were used in the study. The animals were maintained in an air conditioned animal house at a temperature of 22 ± 2 °C, relative humidity of 57 ± 2 % and photocycle of 12:12 h light and dark. The animals were provided with standardized pelleted feed and drinking water ad libitum. All the experimental procedures were carried out in accordance with the guidelines of the Institutional Animal Ethics Committee. The animals were observed daily for any signs of toxicity. Body weight was recorded at regular intervals throughout the experimental period.

Experimental groupings

After acclimatization a period of one week, the animals were randomly divided into seven groups each consisting of nine rats. Group I served as the normal control and was given olive oil (i.p. 0.5 ml/kg b.w.) as vehicle twice a week intraperitoneally for a period of four weeks. Group II served as the cinnamon extract control and was given cinnamon extract dissolved in distilled water orally at a dose level of 0.05 g/kg b.w. daily for a period of four weeks. For inducing hepatotoxicity, animals of Groups III, IV, V, VI, and VII were intraperitoneally administered 0.5 ml/kg body weight of carbon tetrachloride (50 % CCl₄ in olive oil) twice a week for a period of four weeks. After CCl₄ intoxication, Group III served as the CCl₄ control. Groups IV-VII were orally administered cinnamon extract dissolved in distilled water at doses of 0.005, 0.01, 0.05 and 0.1 g/kg, respectively, daily for a period of four weeks.

Biochemical evaluation

At the end of the treatment period all animals were fasted for 12 h, then blood samples were collected by cardiac puncture using sterile disposable syringes under diethyl ether anesthesia. Sera were separated out by centrifugation at 3000 rpm for 15 min and stored at -20 °C until analysis. After the collections of blood samples, animals were killed and samples of the liver of each animal were dissected, weighed and homogenized for the determination of SOD and CAT activities. Liver damage was assessed by the estimation of serum activities of ALT, AST, and ALP using commercially available test kits. The results were expressed as units/liter (IU/L). In addition, the serum levels of total protein were estimated in the experimental animals by using commercial kit.

Measurement of SOD and CAT in liver homogenate

Liver homogenates were prepared in cold Tris-HCl (5 mmol/L, containing 2 mmol/L EDTA, pH 7.4) using a homogenizer. The unbroken cells and cell debris were removed by centrifugation at 10,000 g for 10 min at 4 °C. The activities of SOD (Kakkar et al., 1984) and CAT (Sinha, 1972) were assayed in the liver. SOD was assayed by the inhibition of the formation of NADH-phenazine methosulphate nitroblue tetrazolium formazan which was measured at 520 nm. One unit of SOD activity is defined as the enzyme concentration required inhibiting the chromogen production by 50 % in 1 min under the assay conditions. CAT activity was determined by measuring the amount of hydrogen peroxide (H₂O₂) consumed in the reaction. The remaining H₂O₂ was reacted with dichromate-acetic acid reagent and monitored spectrophotometrically at 590 nm. Activity was expressed in µmol H₂O₂ consumed/min/mg protein.

Histopathological techniques

A fresh piece of the liver (right distal lobe) from each rat, previously trimmed to

approximately 2 mm thickness, was rapidly fixed in 10 % neutral formalin. The fixed tissues were then embedded in paraffin, sectioned (5 μ m) with a rotary microtome and stained with haematoxylin and eosine (H&E). The liver sections were evaluated histologically with a camera attached to a light microscope (Nikon E400). The extent of CCl₄-induced liver damage was evaluated based on pathologic lesions in liver sections stained with H&E method. Score system was used for histopathological examinations. Hepatocyte necrosis, fatty change, hyaline degeneration, ballooning degeneration, and infiltration of inflammatory cells were prominent in the histological findings (Valeer, 2003). The liver pathology was scored as described by French et al. 2000 as follows:

- Score 0 = no visible cell damage
- Score 1 = focal hepatocyte damage on less than 25 % of the tissue
- Score 2 = focal hepatocyte damage on 25-50 % of the tissue
- Score 3 = extensive, but focal, hepatocyte lesions
- Score 4 = global hepatocyte necrosis.

The morphology of any lesions observed was classified and registered (Gray, 1958).

Statistical analysis

Statistical analysis was performed using the SPSS for Windows statistical package, version 10.0 (SPSS Inc. Chicago, IL, USA). Data were expressed as means \pm S.E.M. The effects of drug treatments were evaluated statistically using the one-way analysis of variance (one-way ANOVA) followed by the Dunnett post-hoc test to correct for multiple comparison treatments. Statistical significance was set at the $p < 0.05$ level.

RESULTS

Phytochemical analysis

Phytochemical analysis of *Cinnamomum zeylanicum* L. bark extract demonstrates the presence of flavonoids, tannins, saponins, alkaloids, terpenoids and phenols.

Body weight and weight of liver

No animals died during CCl₄ administration period. The administration of CCl₄

caused a significant decrease in the body weight of rats as compared with the control rats (Table 1). The animals co-treated with cinnamon extract (0.01, 0.05 and 0.1 g/kg b.w.) for four weeks also gained weight during the experimental period. Liver weights and liver index (the ratio of liver weight to body weight) were higher in CCl₄-treated animals than in control animals. Co-treatment with cinnamon extract (0.01, 0.05 and 0.1 g/kg b.w.) resulted in both liver weights and liver index that were significantly reduced compared to those of CCl₄-treated rats. There was no significant alteration in control rats treated solely with cinnamon extract (0.05 g/kg b.w.).

Biochemical analysis

CCl₄ is activated by phase-II detoxifying enzymes in liver cell endoplasmic reticulum to form trichloromethyl and peroxytrichloromethyl free radicals. These can react covalently with several biomolecules such as protein, nucleic acid and lipid, resulting in cellular membrane degeneration, increased permeability, and leakage of cytoplasmic ALT, AST and ALP. Serum levels of ALT, AST and ALP should serve as hepatotoxicity indexes. Indeed, CCl₄ administration produced significant elevations of serum ALT and AST compared to the normal control group. However, pretreatment of rats with 0.01, 0.05 and 0.1 g/kg b.w. cinnamon extract significantly decreased these serum biochemical indices as compared with the CCl₄ treatment group. Hepatic SOD and CAT activities in the CCl₄ treatment group were reduced compared to the normal control group. These antioxidant enzyme activities were all statistically significantly greater in the group treated with cinnamon extract (0.01, 0.05 and 0.1 g/kg b.w.) compared with the CCl₄ treatment group. There was no significant alteration in control rats treated solely with cinnamon extract (Table 2).

Table 1: Body weight, liver weight and liver index of acute CCl₄ (50% CCl₄/olive oil)-treated rats with or without cinnamon ethanolic extract

Parameters	Control	Cinnamon extract (0.05 g/kg b.w.)	CCl ₄	CCl ₄ + Cinnamon extract (g/kg b.w.)			
				0.005	0.01	0.05	0.1
Initial body weight (g)	224 ± 10.4	216 ± 9.8	223 ± 13.2	219 ± 12.5	221 ± 11.2	218 ± 8.9	220 ± 11.4
Final body weight (g)	256 ± 15.3	249 ± 17.2	226 ± 10.5 +++	232 ± 8.5	239 ± 13.6	240 ± 17.4 *	245 ± 15.2 **
Weight gain (g)	32 ± 4.9	33 ± 3.7	3 ± 0.7 +++	13 ± 3.4	18 ± 6.3 *	22 ± 5.9 *	25 ± 4.1 **
Liver weight (g)	5.3 ± 0.34	5.2 ± 0.41	8.5 ± 1.2 +++	6.9 ± 0.64	6.5 ± 0.71 **	6.3 ± 0.57 **	5.9 ± 0.83 ***
Liver index	2.07 ± 0.04	2.09 ± 0.03	3.76 ± 0.07 +++	2.97 ± 0.05	2.72 ± 0.04 **	2.63 ± 0.03 **	2.41 ± 0.03 ***

Values are mean ± S.E.M. (n = 9 rats per each group). The liver index was calculated as liver weight / body weight × 100, * p < 0.05, ** p < 0.01, ***, p < 0.001 significantly different from the group treated with CCl₄. +++ p < 0.001 significantly different from the control

Table 2: Effects of cinnamon ethanolic extract on serum and liver biochemical indices in CCl₄-induced hepatotoxicity in rats

Parameters	Control	Cinnamon extract (0.05 g/kg b.w.)	CCl ₄	CCl ₄ + Cinnamon extract (g/kg b.w.)			
				0.005	0.01	0.05	0.1
ALT (IU/L)	44.81 ± 3.28	54.00 ± 4.71	595.33 ± 18.04 +++	449.28 ± 67.45	266.00 ± 14.91 ***	358.66 ± 28.83 ***	417.40 ± 44.28 *
AST (IU/L)	125.81 ± 10.28	197.25 ± 5.20	671.80 ± 19.63 +++	572.71 ± 30.34	331.66 ± 20.60 ***	335.83 ± 38.10 ***	512.00 ± 23.15 **
ALP (IU/L)	280.45 ± 13.44	270.75 ± 15.28	559.00 ± 17.17 +++	593.00 ± 22.89	384.16 ± 25.36 ***	420.00 ± 26.35 ***	401.71 ± 10.37 ***
SOD (U/mg protein)	9.4 ± 1.7	9.1 ± 2.1	5.8 ± 1.3 +++	6.4 ± 0.9	6.9 ± 1.5 *	7.6 ± 1.3 **	8.3 ± 1.1 ***
CAT (U/mg protein)	4.05 ± 0.05	3.75 ± 0.05	0.61 ± 0.01 +++	3.15 ± 0.05	2.45 ± 0.05 ***	2.55 ± 0.05 ***	0.95 ± 0.15 ***
Total protein (g/dL)	62.66 ± 2.6	57.66 ± 3.57	26.27 ± 0.81 +++	35.50 ± 1.84	41.52 ± 1.83 ***	43.07 ± 3.38 ***	45.01 ± 4.52 ***

Values are mean ± S.E.M. (n = 9 rats per each group). * p < 0.05, ** p < 0.01, *** p < 0.001 significantly different from the group treated with CCl₄. +++ p < 0.001 significantly different from the control

Histopathological findings

The central vein, hepatocyte and portal space were observed to be normal in the control group (Figure 1 A-G). CCl₄ is a hepatotoxicant known to produce a characteristic centrilobular pattern of degeneration and necrosis. In the present study, CCl₄ application constituted histopathological changes in the liver. Severe hyperemia was observed in the area surrounding the central veins. Wide vacuolar degeneration of hepatocytes and lymphocyte infiltration were observed. Derangement of the hepatocyte cord and necrosis at the periphery of central vein were also determined in CCl₄ group (Table 3). The histological appearance of the cinnamon extract-treated groups was quite similar to that of the control group, and tissue damage and necrosis were of less extent in this group than the CCl₄ group. Minimal tissue degeneration was observed at the periphery of the central vein. No derangement was observed at hepatocyte cords. Lymphocyte infiltration was not detected in the cinnamon extract-treated group. Hydropic and vacuolar degeneration were found only at the periphery of the central vein. Moderate degenerative changes, vacuolar degeneration of hepatocytes, and lymphocyte infiltration at the periphery of the central vein were determined in this group.

DISCUSSION

The present study demonstrates the hepatoprotective, curative and antioxidant effects of cinnamon ethanolic extract against CCl₄-induced liver injury in rats. The liver is one of the vital organs in our body responsible for detoxification of toxic chemicals and drugs. Thus it is the target organ for all toxic chemicals. Numerous studies noted that CCl₄ is widely used to induce liver damage because it is metabolized in hepatocytes by cytochrome P₄₅₀, generating a highly reactive carbon-centered trichloromethyl radical, leading to initiating a chain of lipid peroxidation and thereby causing liver fibrosis (Fang et al., 2008; Weber et al., 2003; Ashok et al., 2001; Bahceioglu et al., 1990; Aleynik et al., 1997; Halliwell and Gutteridge, 1998). CCl₄ not only initiates lipid peroxidation but also reduces tissue CAT and SOD activities, and this depletion may result from oxidative modification of these proteins (Augustyniak et al., 2005). Our results showed that administration of cinnamon extract effectively protected against the loss of these antioxidant activities after CCl₄ administration, and it is well known to serve diverse biological functions, including protection of cells from oxidative damage by ROS and free radicals (Nakamura et al., 2001; Gabele et al., 2009). Phytochemicals have also been shown to stimulate synthesis of anti-

Table 3: Histological injury score of liver under different doses of cinnamon extract in rats treated with CCl₄

Group	Injury of score ^a			
	Fatty Degeneration	Necrosis	Cell swelling	Inflammation
Control	0	0	0	0
Cinnamon extract (0.05 g/kg b.w.)	0	0	0	0
CCl ₄	4	3	3	3
Cinnamon extract 0.005 g/kg b.w. + CCl ₄	2	1	2	1
0.01 g/kg b.w. + CCl ₄	0	0	0	1
0.05 g/kg b.w. + CCl ₄	3	2	2	2
0.1 g/kg b.w. + CCl ₄	2	2	2	2

^a Livers were scored for hepatic injury via light microscopy with score 0 = no visible cell damage; score 1 = focal hepatocyte damage on less than 25 % of the tissue; score 2 = focal hepatocyte damage on 25-50 % of the tissue; score 3 = extensive, but focal, hepatocyte lesions; score 4 = global hepatocyte necrosis.

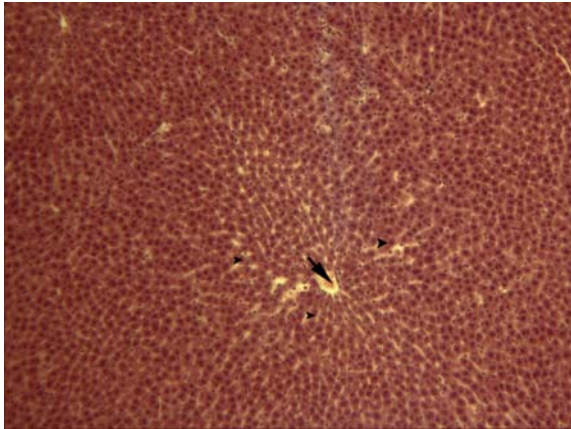


Figure 1A: Liver section of normal control showing normal central vein (arrow) and radiating hepatocytes (arrowhead) (H&E*16)

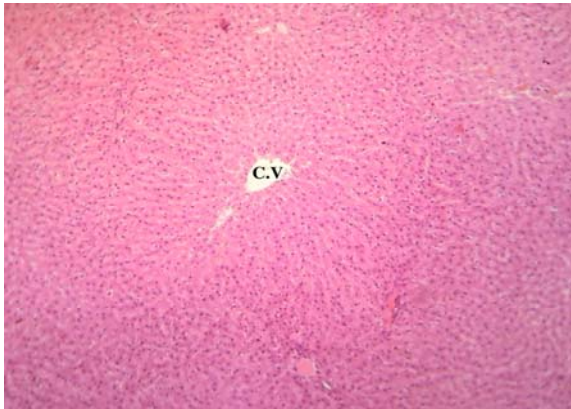


Figure 1B: Liver section from cinnamon extract treated animals shows normal central vein (C.V.) and hepatocyte (H&E*16)

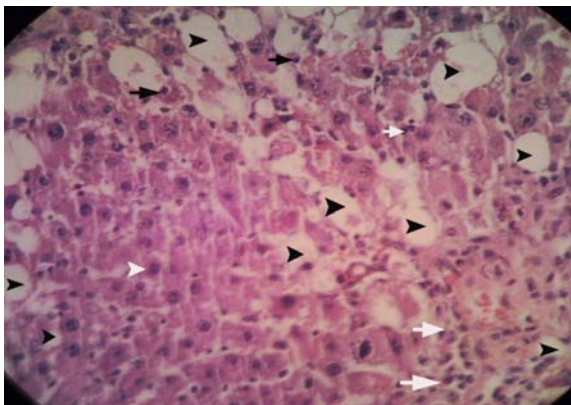


Figure 1C: Liver section of CCl₄-treated rats revealing fatty degeneration (black arrowhead), hepatocyte necrosis (black arrow), inflammatory cells infiltration (white arrow) and normal hepatocyte (white arrowhead) (H&E*640)

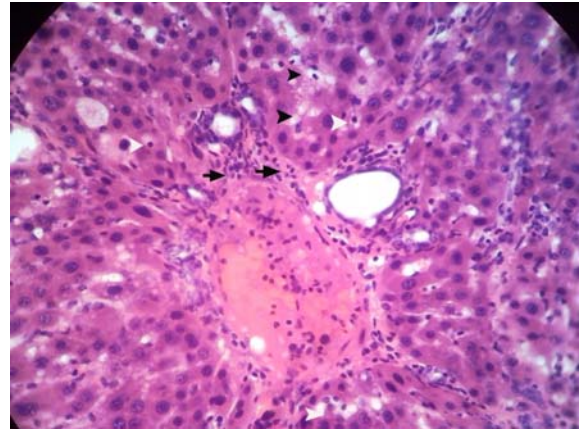


Figure 1D: Liver section from rat treated with 0.005 g/kg b.w. + CCl₄ shows fatty degeneration (arrowhead), necrosis and infiltration of inflammatory cells (arrow) (H&E*640)

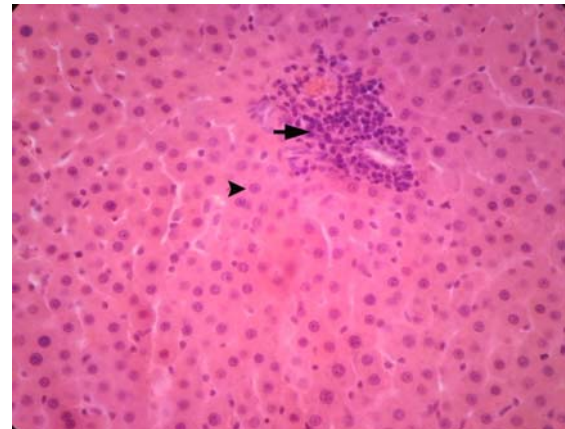


Figure 1E: Liver section from rat treated with 0.01 g/kg b.w. + CCl₄ shows infiltration of inflammatory cells (arrow) with normal hepatocyte (arrow head) (H&E*160)

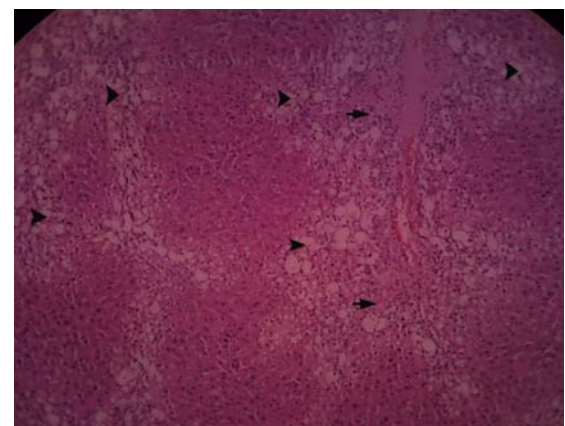


Figure 1F: Liver section from rat treated with 0.05 g/kg b.w. + CCl₄ shows fatty degeneration (arrowhead), infiltration of inflammatory cells (arrow) (H&E*160)

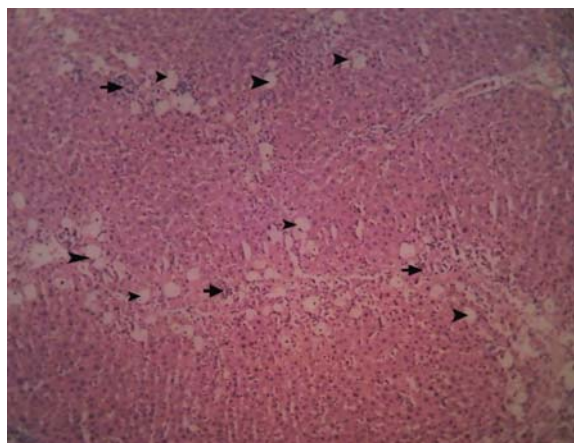


Figure 1G: Liver section from rat treated with 0.1 g/kg b.w. + CCl₄ shows fatty degeneration (arrowhead), infiltration of inflammatory cells (arrow) (H&E*160)

Figure 1: Histopathological changes of liver tissue

oxidant enzymes and detoxification systems at the transcriptional level, through antioxidant response elements (Masella et al., 2005), and to increase γ -glutamylcysteine synthesis (Kim et al., 2007).

Increased levels of ALT, AST and ALP in serum of the CCl₄-treated animals indicate liver damage as these enzymes leak out from liver into the blood at the instance of tissue damage, which is always associated with hepatonecrosis (Naik and Panda, 2008; Ree and Spector, 1961). With the treatment of cinnamon extract, the levels of these marker enzymes were near normal or only slightly elevated, indicating protection against liver damage. ALP activity is related to the functioning of hepatocytes. Suppression of increased ALP activity suggests the stability of biliary dysfunction in rat liver during chronic hepatic injury with CCl₄. Diminution of total protein and albumin induced by CCl₄ is a further indication of liver damage (Navarro and Senior, 2006). Cinnamon extract has increased the levels of serum total protein towards the respective normal value, which indicates hepatoprotective activity. Stimulation of protein synthesis has been advanced as a contributory hepatoprotective mechanism which

accelerates the regeneration process and the production of liver cells (Rip et al., 1985; Tadeusz et al., 2001).

Additionally, we observed histopathological changes indicating liver damage after CCl₄ administration. It has been reported by previous findings that CCl₄ causes necrosis (Sun et al., 2001; Zalatnai et al., 1991), fibrosis (Mackinnon et al., 1995; Natsume et al., 1999; Zalatnai et al., 1991), mononuclear cell infiltration (Natsume et al., 1999), steatosis and degeneration of hepatocytes, increase in mitotic activity (Teocharis et al., 2001) and cirrhosis (Zalatnai et al., 1991) in liver. It has also been reported that CCl₄ causes apoptosis in liver (Shi et al., 1998; Sun et al., 2001). Therefore, histopathological findings in the liver due to CCl₄ administration are in agreement with previous studies. Pretreatment with cinnamon extract significantly improved the structure of hepatic cells. We therefore suggest that pretreatment with the cinnamon extract markedly reversed hepatotoxicity caused by the CCl₄.

Phytochemical screening of cinnamon bark has revealed the presence of flavonoids, glycosides, coumarins, alkaloids, anthraquinone, steroids, tannins and terpenoids (Shihabudeen et al., 2011). Phytoconstituents like the flavonoids (Baek et al., 1996), triterpenoids (Xiong et al., 2003), saponins (Tran et al., 2001) and alkaloids (Vijayan et al., 2003) are known to possess hepatoprotective activity. The presence of flavanoids in our extract may be responsible for its antioxidant and thus hepatoprotective activity. Numerous studies have suggested that flavonoids commonly function as antioxidants and may protect plants against oxidative stress caused by suboptimal environmental conditions (Bohnert and Jensen, 1996; Rice-Evans et al., 1997; Tattini et al., 2004; Gould and Lister, 2006). The antioxidant capacity of flavones is attributed to the high reactivity of the hydroxyl substituent, with the number of hydroxyl groups on the B-ring being correlated with ROS scavenging capability (Sekher et al., 2001; Burda and Oleszek, 2001; Heim et al., 2002).

In conclusion, the results of this study demonstrate that cinnamon extract was effective for the prevention of CCl₄-induced hepatic damage in rats. Our results show that the hepatoprotective effects of cinnamon extract may be due to both an increase in the activity of the antioxidant-defense system and an inhibition of lipid peroxidation. However, the protective, curative and antioxidant qualities of cinnamon need to be confirmed by characterizing the active ingredient(s) of this plant as well as its mechanism(s) of action.

ACKNOWLEDGMENTS

We would like to thank Deputy Research, Science and Research Branch, Islamic Azad University, for financial support of the project.

REFERENCES

- Aleynik IS, Leo AM, Ma X, Aleynik KM, Lieber SC. Polyenyl phosphatidylcholine prevents carbon tetrachloride-induced lipid peroxidation while it attenuates liver fibrosis. *J Hepatol* 1997;7:554-61.
- Ashok SK, Somayaji SN, Bairy AKL. Hepatoprotective effect of *Ginkgo biloba* against carbon tetrachloride induced hepatic injury in rats. *Indian J Pharmacol* 2001;33:260-6.
- Augustyniak A, Wazkilwicz E, Skrzydlewaka E. Preventive action of green tea from changes in the liver antioxidant abilities of different aged rats intoxicated with ethanol. *Nutrition* 2005;21:925-32.
- Baek NL, Kim YS, Kyung JS, Park KH. Isolation of anti-hepatotoxic agents from the roots of *Astragalus membranaceus*. *Korean J Pharmacog* 1996;27:111-6.
- Bahcecioglu IH, Ustundag B, Ozercan I, Erceci E, Bayolas G, Akdere T. Protective effect of *Ginkgo biloba* extract on CCl₄-induced liver damage. *Hepatol Res* 1990;15:215-24.
- Bakkali F, Averbeck S, Averbeck D. Biological effects of essential oils - a review. *Food Chem Toxicol* 2008;46:446-75.
- Baytop T. Türkiye’de Bitkiler ile Tedavi (Treatment with Plants in Turkey). Istanbul, Turkey: Istanbul University Publications; 1999. No 3255/40.
- Bohnert HJ, Jensen RG. Strategies for engineering water stress tolerance in plants. *Trends Biotechnol* 1996;14:89-97.
- Burda S, Oleszek W. Antioxidant and anti-radical activities of flavonoids. *J Agric Food Chem* 2001;49:2774-9.
- Carmo ES, Lima ED, de Souza EL, de Sousa FB. Effect of *Cinnamomum zeylanicum* blume essential oil on the growth and morphogenesis of some potentially pathogenic *Aspergillus* species. *Braz J Microbiol* 2008;39:91-7.
- Chao SC, Young DG, Oberg CJ. Screening for inhibitory activity of essential oils on selected bacteria, fungi and viruses. *J Essent Oil Res* 2000;12:639-49.
- Domenicali M, Caraceni P, Giannone F, Baldassarre M, Lucchetti G, Quarta C et al. A novel model of CCl₄-induced cirrhosis with ascites in the mouse. *J Hepatol* 2009;51:991-9.
- Dusan F, Marian S, Katarina D, Dobroslava B. Essential oils-their antimicrobial activity against *Escherichia coli* and effect on intestinal cell viability. *Toxicol In Vitro* 2006;20:1435-45.
- Fang HL, Lai JT, Lin WC. Inhibitory effect of olive oil on fibrosis induced by carbon tetrachloride in rat liver. *Clin Nutr* 2008;27:900-7.
- Fichi G, Flamini G, Zaralli LJ, Perrucci S. Efficacy of an essential oil of *Cinnamomum zeylanicum* against *Psoroptes cuniculi*. *Phytotherapy* 2007;14:227-31.

- Finar IL. Organic chemistry. Vol 2: Stereochemistry and the chemistry of natural products. 5th ed. (pp 769-71). Delhi: Pearson Education, 2003.
- French SW, Miyamoto K, Ohta Y, Geofrion Y. Pathogenesis of experimental alcoholic liver disease in the rat. *Methods Achiev Exp Pathol* 2000;13:181-207.
- Gabele E, Fron M, Aeteel GE, Uesugi T, Hellerbrand C, Scholmerich J. TNFalpha is required for cholestasis-induced liver fibrosis in the mouse. *Biochem Biophys Res Commun* 2009;378:348-53.
- Gould KS, Lister C. Flavonoid functions in plants. In: Andersen OM, Markham KR (eds.): *Flavonoids: chemistry, biochemistry and applications* (pp 397-440). London: CRC Press, 2006.
- Grattagliano I, Bonfrate L, Catia VD, Wang HH, Wang DQH, Portincasa P. Biochemical mechanisms in drug-induced liver injury. *World J Gastroenterol* 2009;15:4865-76.
- Gray P. *Handbook of basic microtechnique*. 3rd ed. (pp 45-85). New York: McGraw-Hill, 1958.
- Gruenwald J, Freder J, Armbruster N. Cinnamon and health. *Crit Rev Food Sci Nutr* 2010;50:822-34.
- Halliwell B, Gutteridge JMC. *Free radicals in biology and medicine* (pp 27-30). New York: Oxford University Press, 1998.
- Hayashi K, Imanishi N, Kashiwayama Y, Kawano A, Terasawa K, Shimada Y et al. Inhibitory effect of cinnamaldehyde, derived from cinnamomi cortex, on the growth of influenza A/PR/8 virus in vitro and in vivo. *Antiviral Res* 2007;74:1-8.
- Heim KE, Tagliaferro AR, Bobilya DJ. Flavonoid antioxidants: chemistry, metabolism and structure–activity relationships. *J Nutr Biochem* 2002;10:572-84.
- Hong CH, Hur SK, Oh OJ, Kim SS, Nam KA, Lee SK. Evaluation of natural products on inhibition of inducible cyclooxygenase (COX-2) and nitric oxide synthase (iNOS) in cultured mouse macrophage cells. *J Ethnopharmacol* 2002;83:153-9.
- Hyeon K, Hee-Juhn P, Hyun-Ju J, Jong-Won C, Kyu-Seok C, Joohun H et al. Cinnamaldehyde induces apoptosis by ROS mediated mitochondrial permeability transition in human promyelocytic leukemia HL-60 cells. *Cancer Lett* 2003;196:143-52.
- Jayaprakasha GK, Negi PS, Jena BS, Jagan Mohan Rao L. Antioxidant and antimutagenic activities of *Cinnamomum zeylanicum* fruit extracts. *J Food Compos Anal* 2007;20:330-6.
- Kakkar P, Das B, Viswanathan PN. A modified spectrophotometric assay of superoxide dismutase. *Indian J Biochem Biophys* 1984;21:130-2.
- Khan A, Safdar M, Ali Khan MM, Khattak KN, Anderson RA. Cinnamon improves glucose and lipids of people with type 2 diabetes. *Diabetes Care* 2003;26:3215-8.
- Kim MK, Lee HS, Kim ET, Won NH, Chi YM, Kim BC. Protective effect of aqueous extract of *Perilla frutescens* on tert-butyl hydroperoxide induced oxidative hepatotoxicity in rats. *Food Chem Toxicol* 2007;45:1738-44.
- Kucera O, Cervinkova Z, Lotkova H, Krivakova P, Rousar T, Muzakova V et al. Protective effect of Sadenosylmethionine against galactosamine-induced injury of rat hepatocytes in primary culture. *Physiol Res* 2006;55:551-60.
- Ledda-Columbano GM, Coni P, Curto M, Giacomini L, Faa G, Oliverio S et al. Induction of two different modes of cell death, apoptosis and necrosis, in rat liver after a single dose of thioacetamide. *Am J Pathol* 1991;139:1099-109.

- Mackinnon M, Clayton C, Plummer J, Ahern M, Cmielewski P, Isley A. Iron overload facilitates hepatic fibrosis in the rat alcohol/low-dose carbon tetrachloride model. *Hepatology* 1995;21:1083-8.
- Marongiu B, Piras A, Porcedda S, Tuveri E, Sanjust E, Meli M et al. Supercritical CO₂ extract of *Cinnamomum zeylanicum*: chemical characterization and antityrosinase activity. *J Agr Food Chem* 2007;55:10022-7.
- Masella R, Benedetto RD, Vari R, Filesi C, Govannini C. Novel mechanisms of natural antioxidant compounds in biological systems: involvement of glutathione and glutathione-related enzymes. *J Nutr Biochem* 2005;16:577-86.
- Mroueh M, Saab Y, Rizkallah R. Hepatoprotective activity of *Centaurium erythraea* on acetaminophen-induced hepatotoxicity in rats. *Phytother Res* 2004;18:431-3.
- Murcia MA, Egea I, Romojaro F, Parras P, Jiménez AM, Martínez-Tomé M. Antioxidant evaluation in dessert spices compared with common food additives. Influence of irradiation procedure. *Am Chem Soc* 2004; 52:1872-81.
- Naik SR, Panda VS. Hepatoprotective effect of Ginkgoselect Phytosome in rifampicin induced liver injury in rats: evidence of antioxidant activity. *Fitoterapia* 2008;79: 439-45.
- Nakamura Y, Torikai K, Ohigashi H. Toxic dose of a simple phenolic antioxidant, protocatechuic acid, attenuates the glutathione level in ICR mouse liver and kidney. *J Agr Food Chem* 2001;3:5674-8.
- Natsume M, Tsuji H, Harada A, Akiyama M, Yano T, Ishikura H et al. Attenuated liver fibrosis and depressed serum albumin levels in carbon tetrachloride-treated IL-6-deficient mice. *J Leukoc Biol* 1999;66:601-8.
- Navarro VJ, Senior JR. Drug-related hepatotoxicity. *N Engl J Med* 2006;354:731-9.
- Nishida S, Kikuichi S, Yoshioka S, Tsubaki M, Fujii Y, Matsuda H et al. Induction of apoptosis in HL-60 cells treated with medicinal herbs. *Am J Chin Med* 2003;31:551-62.
- Okawa M, Kinjo J, Nohara T, Ono M. DPPH (1,1-diphenyl-2-picrylhydrazyl) radical scavenging activity of flavonoids obtained from some medicinal plants. *Biol Pharm Bull* 2001;24:1202-5.
- Parekh J, Karathia N, Chanda S. Antibacterial activity of *Bauhinia variegata*. *J Biomed Res* 2006;9:53-6.
- Premanathan M, Rajendran S, Ramanathan T, Kathiresan K, Nakashima H, Yamamoto N. A survey of some Indian medicinal plants for anti-human immunodeficiency virus (HIV) activity. *Indian J Med Res* 2000;112:73-7.
- Preuss HG, Echard B, Polansky MM, Anderson R. Whole cinnamon and aqueous extracts ameliorate sucrose-induced blood pressure elevations in spontaneously hypertensive rats. *J Am Coll Nutr* 2006;25:144-50.
- Ranasinghe L, Jayawardena B, Abeywickrama K. Fungicidal activity of essential oils of *Cinnamomum zeylanicum* (L.) and *Syzygium aromaticum* (L.) Merr et L.M. Perry against crown rot and anthracnose pathogens isolated from banana. *Lett Appl Microbiol* 2002;35:208-21.
- Ree KR, Spector WG. Reversible nature of liver cell damage due to carbon tetrachloride as demonstrated by the use of phenergan. *Nature* 1961;190:821-2.
- Rice-Evans CA, Miller NJ, Papanga G. Antioxidant properties of phenolic compounds. *Trends Plant Sci* 1997;2:152-9.

- Rip JW, Rupar CA, Ravi K, Carroll KK. Distribution, metabolism and function of dolichol and polyprenols. *Prog Lipid Res* 1985;24:269-309.
- Rousar T, Kucera O, Krivakova P, Lotkova H, Kandar R, Muzakova V, et al. Evaluation of oxidative status in acetaminophen treated rat hepatocytes in culture. *Physiol Res* 2009;58:239-46.
- Sadasivam S, Manickam A. *Biochemical methods*. 2nd ed. (pp 192-3). New Delhi: New Age International Ltd, 1996.
- Sekher A, Pannala-Chan TS, O'Brien PJ, Rice-Evans CA. Flavonoid B-ring chemistry and antioxidant activity: fast reaction kinetics. *Biochem Biophys Res Commun* 2001;282:1161-8.
- Shahjahan M, Sabitha KE, Jainu M, Devi CSS. Effect of *Solanum trilobatum* against carbon tetrachloride induced hepatic damage in albino rats. *Indian J Med Res* 2004;120:194-8.
- Shahverdi AR, Monsef-Esfahani HR, Tavassoli F, Zaheri A, Mirjani R. Trans-cinnamaldehyde from *Cinnamomum zeylanicum* bark essential oil reduces the clindamycin resistance of *Clostridium difficile* in vitro. *J Food Sci* 2007;72:55-8.
- Sheweita SA, El-Gabar MA, Bastawy M. Carbon tetrachloride-induced changes in the activity of phase II drug-metabolizing enzyme in the liver of male rats: role of antioxidants. *Toxicology* 2001;165:217-24.
- Shi J, Aisaka K, Ikawa Y, Wake K. Evidence of hepatocyte apoptosis in rat liver after the administration of carbon tetrachloride. *Am J Pathol* 1998;153:515-25.
- Shihabudeen MS, Priscilla H, Thirumurgan K. Cinnamon extract inhibits α -glucosidase activity and dampens postprandial glucose excursion in diabetic rats. *Nutr Metab* 2011;8:1-11.
- Sinha AK. Colorimetric assay of catalase. *Anal Biochem* 1972;47:389-94.
- Su L, Yin J-J, Charles D, Zhou K, Moore J, Yu L. Total phenolic contents, chelating capacities, and radical-scavenging properties of black peppercorn, nutmeg, rosehip, cinnamon and oregano leaf. *Food Chem* 2007;100:990-7.
- Subash Babu P, Prabuseenivasan S, Ignacimuthu S. Cinnamaldehyde-a potential antidiabetic agent. *Phytomedicine* 2007;14:15-22.
- Sun F, Hamagawa E, Tsutsui C, Ono Y, Ogiri Y, Kojo S. Evaluation of oxidative stress during apoptosis and necrosis caused by carbon tetrachloride in rat liver. *Biochem Biophys Acta* 2001;1535:186-91.
- Tadeusz J, Teresa J, Krzysztof N. The role of polyprenol in modulation of physical properties of model membranes. *Curr Top Biophys* 2001;25:33-8.
- Tattini M, Galardi C, Pinelli P, Massai R, Remorini D, Agati G. Differential accumulation of flavonoids and hydroxycinnamates in leaves of *Ligustrum vulgare* under excess light and drought stress. *New Phytol* 2004;163:547-61.
- Teocharis SE, Margeli AP, Skaltsas SD, Spiliopoulou CA, Koutselini AS. Induction of metallothionein in the liver of carbon tetrachloride intoxicated rats: an immunohistochemical study. *Toxicology* 2001;161:129-38.
- Tran QI, Adnyana IK, Tezuka Y, Nagaoka T, Tran QK, Kadota S. Triterpene saponins from *Vietnamese ginseng* (*Panax vietnamensis*) and their hepatocyte protective activity. *J Nat Prod* 2001;64:456-61.

Tung YT, Chua MT, Wang SY, Chang ST. Antiinflammation activities of essential oil and its constituents from indigenous cinnamon (*Cinnamomum osmophloeum*) twigs. *Bioresour Technol* 2008;99:3908-13.

Valeer JD. Liver tissue examination. *J Hepatol* 2003;39:S43-9.

Vijayan P, Prashanth HC, Dhanraj SA, Badami S, Suresh B. Hepatoprotective effect of total alkaloid fraction of *Solanum pseudocapsicum* leaves. *Pharmaceut Biol* 2003;41:443-8.

Weber LW, Boll M, Stampfl A. Hepatotoxicity and mechanism of action of haloalkanes: carbon tetrachlorides as a toxicological model. *Crit Rev Toxicol* 2003;33:105-36.

Xiong X, Chen W, Cui J, Yi S, Zhang Z, Li K. Effects of ursolic acid on liver protection and bile secretion. *Zhong Yao Cai* 2003;26:578-81.

Yang YC, Lee HS, Lee SH, Clark JM, Ahn YJ. Ovicidal and adulticidal activities of *Cinnamomum zeylanicum* bark essential oil compounds and related compounds against *Pediculus humanus capitis* (Anoplura: Pediculidae). *Int J Parasitol* 2005;35:1595-600.

Zalatnai A, Sarosi I, Rot A, Lapis K. Inhibitory and promoting effects of carbon tetrachloride-induced liver cirrhosis on the diethylnitrosamine hepatocarcinogenesis in rats. *Cancer Lett* 1991;57:67-73.