

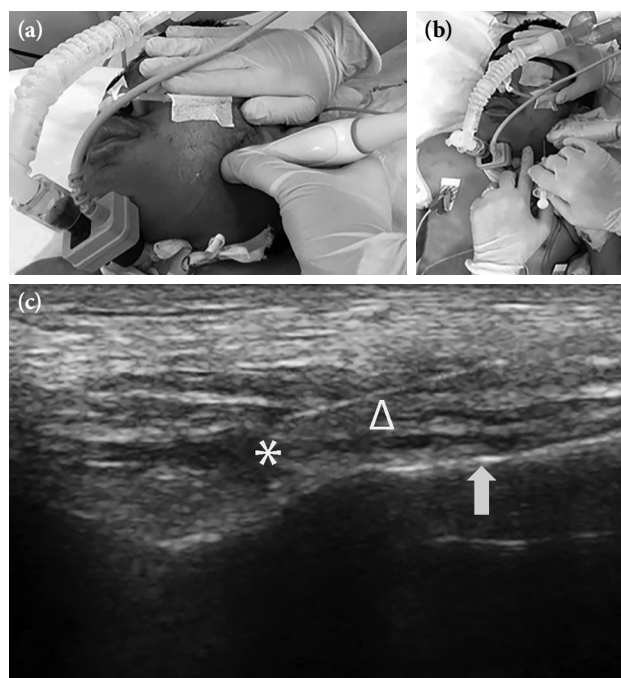
## The value of physiatrists in pediatric intensive care unit: A case report of botulinum toxin injection into masseter muscle for the treatment of trismus

Esra Giray , Kardelen Gencer-Atalay , Evrim Karadağ-Saygı , İlker Yağcı 

Department of Physical Medicine and Rehabilitation, Marmara University School of Medicine, Istanbul, Turkey

Received: October 20, 2019 Accepted: January 01, 2020 Published online: March 04, 2020

A 15-year-old boy with mucopolysaccharidosis type IV suffered from cardiopulmonary arrest after cervical stenosis surgery and was resuscitated. The patient demonstrated bilateral and progressively worsening trismus associated with hypoxic-ischemic encephalopathy and underwent partial amputation of tongue after injury due to a bitten tongue. He was given rocuronium infusion due to unresolved worsening trismus and consulted for botulinum toxin injection into the masseter muscle. The marker on the ultrasound probe was located on the mandibular ramus. The masseter muscle was identified as lying adjacent to echogenic band of the mandibula.<sup>[1]</sup> A total of 20 IU of onabotulinum toxin A (BoNT-A) injection per each masseter muscle was performed under the guidance of electromyography, electrical stimulation, and ultrasound (Figure 1). Three days after the injection, the treating physicians and nurses who were responsible with the care of the patient reported an increased mouth opening distance, easier care of oral cavity, and no more need for rocuronium infusion. At three months, however, all these improvements became less prominent and swallowing of saliva was impaired due to hypoxic-ischemic encephalopathy-related trismus. Subsequently, the patient developed aspiration pneumonia possibly due to posterior drooling and the nurses were complaining spillage of



**Figure 1.** An ultrasonographic image of masseter muscle during injection and probe position. (a) The position of probe during demonstration of masseter muscle via ultrasound. (b) The position of probe during injection. (c) An ultrasonographic image of masseter muscle during injection: mandibular rim (arrow), masseter muscle (asterisk), and needle (arrowhead).

**Corresponding author:** Esra Giray, MD. Marmara Üniversitesi Pendik Eğitim ve Araştırma Hastanesi, Fiziksel Tıp ve Rehabilitasyon Kliniği, 34899 Pendik, İstanbul, Türkiye.

e-mail: esra.giray@marmara.edu.tr

*Cite this article as:*

Giray E, Gencer-Atalay K, Karadağ-Saygı E, Yağcı İ. The value of physiatrists in pediatric intensive care unit: A case report of botulinum toxin injection into masseter muscle for the treatment of trismus. Turk J Phys Med Rehab 2020;66(4):495-496.

saliva over his neck due to anterior drooling. Three months after the first injection, botulinum toxin injection into the masseter (25 IU per masseter muscle) was repeated. Also, 15 IU of BoNT-A injection per temporalis muscle and 20 IU of BoNT-A injection per parotid gland were applied. The physicians and nurses who were responsible with the care of the patient reported ease of providing oral care and tracheostomy care as well as an increased mouth opening distance. No side effects were observed after injections.

Trismus is caused by diffuse hypoxic brain injury due to disrupted central inhibition leading to an increased tone in bilateral masseter and other muscles.<sup>[2]</sup> Difficulty in feeding, swallowing of the saliva, and mouth hygiene may occur as a result of trismus. These impairments pose a risk for respiratory problems and aspiration bronchopneumonia which is a frequent life-threatening complication. Muscle relaxants other than curare may show limited benefit in the management of trismus.<sup>[3]</sup> The aim was to produce a long lasting curare-like, localized effect on the masseter and temporalis muscles which are responsible for closing the mouth and can be easily imagined externally via ultrasound to avoid difficulty in weaning from the ventilator patients who have chronically received neuromuscular blocking drugs in the intensive care unit. Also, this effect was expected to be higher in this patient due to hepatic impairment related to mucopolysaccharidosis, since rocuronium has a longer elimination half-life and may result in a longer duration of action in patients with liver disease.<sup>[4]</sup> Previously, mandibular nerve block has been defined for the management of trismus. The mandibular nerve is situated in the pterygomandibular space which is surrounded by bony structures limiting the ease of ultrasound imaging. Mandibular nerve is situated in the neighborhood of important anatomical structures in the pterygomandibular space which may be related to certain complications. This makes

botulinum toxin injection with ultrasound guidance safer than mandibular nerve block. The effect of mandibular nerve block starts immediately, while the effect of botulinum toxin starts after 72 hours. Therefore, it can be preferred when immediate relief of trismus is required.

In conclusion, botulinum toxin injection into the masseter and temporalis muscles via ultrasound and electromyography and electrical stimulation guidance seems to be a safe and effective treatment in patients with trismus associated with hypoxic-ischemic encephalopathy. Improved patient care as well as improved trismus can be achieved in these patients with the help of physical medicine and rehabilitation specialists who is qualified in applying ultrasound- and electromyography and electrical stimulation-guided botulinum toxin injections for the management of hypertonia.

#### **Declaration of conflicting interests**

The authors declared no conflicts of interest with respect to the authorship and/or publication of this article.

#### **Funding**

The authors received no financial support for the research and/or authorship of this article.

#### **REFERENCES**

1. Serra MD, Duarte Gavião MB, dos Santos Uchôa MN. The use of ultrasound in the investigation of the muscles of mastication. *Ultrasound Med Biol* 2008;34:1875-84.
2. Takemura H, Masuda Y, Yatsushiro R, Yamamoto N, Hosoyamada A. Mandibular nerve block treatment for trismus associated with hypoxic-ischemic encephalopathy. *Reg Anesth Pain Med* 2002;27:313-5.
3. Andrade LA, Brucki SM. Botulinum toxin A for trismus in cephalic tetanus. *Arq Neuropsiquiatr* 1994;52:410-3.
4. Magorian T, Wood P, Caldwell J, Fisher D, Segredo V, Szenohradszky J, et al. The pharmacokinetics and neuromuscular effects of rocuronium bromide in patients with liver disease. *Anesth Analg* 1995;80:754-9.