



# Anatomical Study of the Accessory Tendon of the Extensor Hallucis Longus Muscle and Its Clinical Application

Yue Li, MD, Jing-Ying Zhang, MD\*, Xin-Yue Zhao, MD<sup>†</sup>, Li-Ya Pan, MD<sup>†</sup>, De-Hao Jin, MD<sup>†</sup>, He-Xing Xu, PhD<sup>§</sup>, Hu-Zhe Cui, MD<sup>†</sup>, Yan-Qun Liu, PhD<sup>||</sup>, Xiang-Zheng Qin, PhD<sup>¶</sup>, Qingyuan Li, PhD<sup>§</sup>

*Class of 2016, Clinical Medicine, Yanbian University Clinical College, Yanji,*

*\*Jilin Provincial Center for Disease Control and Prevention, Changchun,*

*†Class of 2015, Clinical Medicine, Yanbian University Clinical College, Yanji,*

*‡Department of Radiology, Yanbian Hospital, Yanji,,*

*§Department of Hand and Foot Surgery, Yanbian Hospital, Yanji,*

*||Department of Orthopaedic, Yanbian Hospital, Yanji,*

*¶Department of Anatomy, Yanbian University Medical College, Yanji, China*

**Background:** The accessory tendon of the extensor hallucis longus (ATEHL) muscle is a common abnormal structure, and its clinical significance remains debatable. In this study, we provide the incidence of the ATEHL and characterize its morphological types in Asian cadavers and investigate its clinical applications.

**Methods:** The tendons from 50 adult cadaveric feet, fixed in 10% formalin, were analyzed. We measured the length and width of both the ATEHL and the extensor hallucis brevis (EHB).

**Results:** All dissected specimens had an ATEHL. The first metatarsophalangeal joint was surrounded by an accessory tendon that inserted onto the joint capsule and the dorsal base of the proximal phalanx. We classified the ATEHL into 3 types based on their directions. Differences in ATEHL type based on sex were not statistically significant.

**Conclusions:** We found an ATEHL in all cadaveric specimens in this study. We surmise that the ATEHL acts as an antagonist with the EHB when the toe is extending, which might help prevent the occurrence of hallux valgus deformity.

**Keywords:** Accessory tendon, Extensor hallucis longus, Proximal phalanx, Anatomy, Extensor hallucis brevis muscle

The anatomy and function of the extensor hallucis longus (EHL) muscle has been well described. The EHL develops from the deep surface of the primitive tendon plate and may subdivide during embryonic development, giving

origin to an accessory tendon (AT).<sup>1)</sup> Supernumerary tendinous slips attached to the hallux proximal phalanx or the first metatarsophalangeal (MTP) joint capsule appear in the majority of lower limb specimens.<sup>1-3)</sup> However, studies disagree on the incidence of ATs. Thus, we aimed to determine the rate of occurrence of the AT of the EHL (ATEHL) and classify it based on its morphology. Despite the high frequency of the ATEHL, its clinical importance is relatively minor, and its possible association with hallux valgus (HV) deformity is disputed.<sup>4-6)</sup>

The relationship between the ATEHL and development of HV deformity is still unclear. In an anatomical study of 60 adult human cadavers, Al-Saggaf<sup>5)</sup> found that the ATEHL increased susceptibility to the development of HV deformity secondary to an imbalance during exten-

Received March 12, 2020; Revised August 30, 2020;

Accepted August 30, 2020

Correspondence to: Xiang-Zheng Qin, PhD

Department of Anatomy, Yanbian University Medical College, Yanji 133002, Jilin Province, China

Tel: +86-433-2436152, Fax: +86-433-2435007, E-mail: qinxzh@ybu.edu.cn

Co-Correspondence to: Qing-Yuan Li, PhD

Department of Hand and Foot Surgery, Yanbian Hospital, Yanji 133000, Jilin Province, China

Tel: +86-433-2660806, Fax: +86-433-2513610, E-mail: 18643398829@163.com

Copyright © 2021 by The Korean Orthopaedic Association

This is an Open Access article distributed under the terms of the Creative Commons Attribution Non-Commercial License (<http://creativecommons.org/licenses/by-nc/4.0>) which permits unrestricted non-commercial use, distribution, and reproduction in any medium, provided the original work is properly cited.

Clinics in Orthopedic Surgery • pISSN 2005-291X eISSN 2005-4408

sion of the first MTP joint in the first toe. According to his theory, the extension force of the ATEHL on the medial side of the proximal phalanx of the first MTP joint may play a role in countering the EHL at the distal aspect of the distal phalanx, leading to HV deformity. However, this hypothesis is not based on any biomechanical or functional anatomical research on the ATEHL. On the contrary, we believe that the ATEHL acts contrary to the axis of the deformity force, and thus the AT might prevent the occurrence of HV deformity rather than reinforce it.

We hypothesized that a study of ATEHL structure may provide preliminary data for novel treatments for HV deformity. Therefore, we provide information on the structure and function of the ATEHL and suggestions for novel treatments for HV deformity.

## METHODS

### Materials

The Institutional Review Board of Yanbian University reviewed and approved the study. Our study used 50 legs from 25 Asian cadavers (mean age,  $82.2 \pm 8$  years; 10 feet from women and 40 feet from men). All specimens had been sterilized with alcohol and preserved in 10% formalin and had no history of trauma or surgery. All individuals had donated their bodies to medical education and research. Surgical instruments for dissection, surgical microinstruments, vernier calipers with 0.02 mm accuracy, and a digital camera (5D MARK III; Canon, Tokyo, Japan) were used.

### Dissection

The skin, superficial fascia, deep fascia, and muscle above the region of the EHL were removed in sequential order. Then we harvested and dissected the tendon sheath of the EHL and found the origin of the ATEHL on the main tendon, followed by dissection of the EHL hood and identification of the ATEHL insertion. Next, we measured the length and width of the ATEHL and extensor hallucis brevis (EHB) at the proximal end of the first MTP joint.

**Table 1.** Length and Width of the EHB and ATEHL

Variable	EHB	ATEHL
Width (mm)	$2.16 \pm 0.06$	$1.43 \pm 0.05^*$
Length (cm)	$6.51 \pm 0.17$	$5.89 \pm 0.14^*$

Values are presented as mean  $\pm$  standard deviation. EHB: extensor hallucis brevis, ATEHL: accessory tendon of the extensor hallucis longus.

\* $p < 0.05$ , compared with the EHB.

### Statistical Analysis

We performed statistical analyses using Prism 4.0 (Microsoft, Redmond, WA, USA). Data were analyzed with *t*-tests, and the results are expressed in the form of mean and standard deviation.

## RESULTS

The length and width of the ATEHL and EHB ( $n = 50$ ) are shown in Table 1. The EHB was significantly wider and longer than the ATEHL. Differences in the ATEHL based on sex were not statistically significant (Table 2).

### Morphological Observations

The ATEHL originated from the main tendon of the EHL and ran along the medial side of the EHL. The AT surrounded the first MTP joint, inserted onto the dorsal base of the proximal phalanx, and had a tight junction with the dorsal fibrous layer of the joint capsule. After dissection and observation, we classified the ATEHLs into 3 types (Table 3). Type I (96%) had 1 AT along the medial side of the EHL inserted into the dorsal base of the proximal phalanx. The EHL inserted onto the hallux at the dorsal distal phalanx surface (Fig. 1). In type II (2%), the AT also ran along the medial side of the EHL and inserted onto the dorsal aspect of the distal phalanx (Fig. 2). Type III (2%) had 2 ATs that ran on the both medial and lateral sides of the EHL (Fig. 3). The insertion of the medial AT was the same as the former types, and the lateral AT inserted onto the EHB.

**Table 2.** Comparison of the Tendons of Feet between Male and Female

Variable	Male ( $n = 40$ )	Female ( $n = 10$ )
Length of the ATEHL (cm)	$5.97 \pm 0.15$	$5.60 \pm 0.30$
Width of the ATEHL (mm)	$1.48 \pm 0.06$	$1.25 \pm 0.07$
Length of EHB (cm)	$6.52 \pm 0.20$	$6.47 \pm 0.37$
Width of EHB (mm)	$2.25 \pm 0.07^*$	$1.81 \pm 0.06$

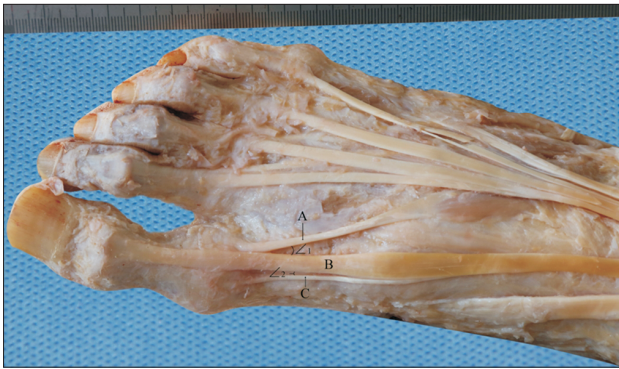Values are presented as mean  $\pm$  standard deviation. ATEHL: accessory tendon of the extensor hallucis longus, EHB: extensor hallucis brevis.

\* $p < 0.05$ , compared with the width of EHB of female.

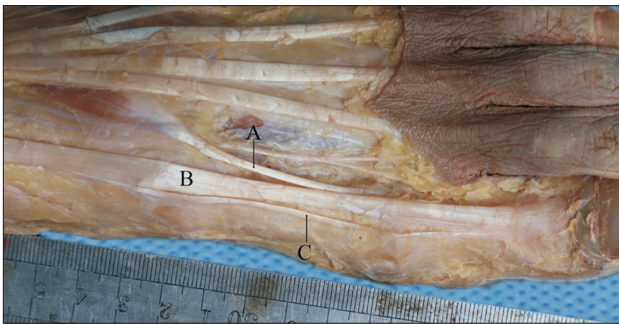
**Table 3.** Types of ATEHL and the Ratio of Each Type

Variable	Type I	Type II	Type III
Number of cases	48	1	1
Per centum (%)	96	2	2

ATEHL: accessory tendon of the extensor hallucis longus.



**Fig. 1.** Morphological structure of type I accessory tendon (AT) of the extensor hallucis longus (EHL). The AT runs on the medial side of the main tendon and inserts onto the dorsal base of the proximal aspect of the proximal phalanx. A: extensor hallucis brevis, B: EHL, C: AT of the EHL.

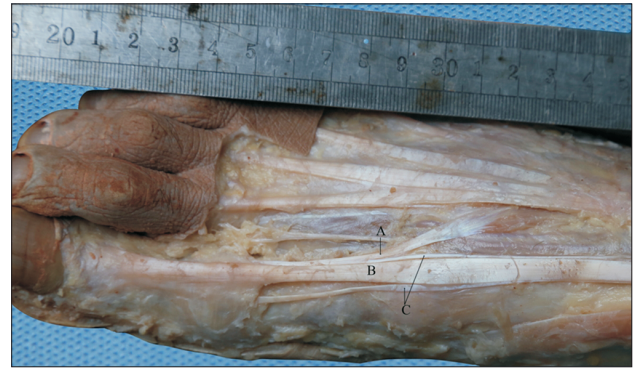

**Fig. 2.** Morphological structure of type II accessory tendon (AT) of the extensor hallucis longus (EHL). The AT accompanies the main tendon until the end of the distal phalanx. A: extensor hallucis brevis, B: EHL, C: AT of the EHL.

## DISCUSSION

Bardeen's seminal study of human embryonic lower extremity development described the EHL tendon as generating from the deep surface of the primitive tendon plate, which is variously subdivided during embryonic development.<sup>7)</sup> Several anatomic variations according to its different directions and various attachments have been described; the EHL tendon divides into 2 or 3 independent slips and inserts separately. Moore described how programmed cell death plays an important role during development by influencing the separation of digital rays.<sup>8)</sup> Variability within these developmental processes may contribute to anomalies in leg musculature such as ATs or the duplication or complete absence of muscles.<sup>9)</sup> The findings of the present study show that the ATEHL can be classified into 3 types according to its morphology.

The existence and attachment of the ATEHL has been described in previous studies. In 1871, Macalister de-



**Fig. 3.** Morphological structure of type III accessory tendon (AT) of the extensor hallucis longus (EHL). Two ATs run on the medial side and lateral side each. A: extensor hallucis brevis, B: EHL, C: AT of the EHL.

scribed the ATEHL, which was attached to the base of the proximal phalanx.<sup>10)</sup> More recent studies have investigated anatomical variation in AT attachments. Al-Saggaf<sup>5)</sup> described how the ATEHL attaches at the dorsal base of the proximal phalanx of hallux and the first MTP joint capsule. The findings of the present study are similar to those findings in that the ATEHL either inserted onto the dorsal base of the proximal phalanx of hallux and first MTP joint capsule or combined with the EHL and inserted onto the dorsal distal aspect of the distal phalanx and first MTP joint capsule.

It has been implied that the ATEHL may be associated with HV deformity.<sup>4)</sup> There are usually multiple causes of HV deformity, including patient factors (e.g., genetic predisposition, wearing uncomfortable shoes, and poor compliance with postoperative instructions) and surgical factors (e.g., type of procedure and surgeon's technical skills).<sup>11)</sup> The imbalance of the tension force between the abductor and adductor muscles of the hallux is also an important factor in the development of HV deformity.<sup>12,13)</sup>

In the current study, we found most ATEHLs (96%) were type I, running along the medial side of the EHL tendon and inserting onto the dorsal base of the proximal phalanx. When the ATEHL is in this position, it can exert antagonistic effects on the EHB to maintain the normal form of the hallux. Our hypothesis, therefore, was that the ATEHL acts as an antagonist to the deformity force of the EHB in a varus rather than valgus direction, and thus the anatomy of the ATEHL might provide evidence for the prevention and clinical treatment of HV deformity.

In addition, if the ATEHL bears prolonged pressure on the medial side of the toe, produced by factors such as wearing tight, narrow shoes or high heels, the insertion side of AT will move laterally as a result. This will cause

the force between the ATEHL and EHB to become imbalanced and put the big toe at risk for HV deformity. If the external pressure is not relieved, the angle between the AT and main tendon will continue to decrease, and the pull of the AT and EHB will move laterally. When the hallux valgus angle between the first metatarsal and proximal phalanx reaches 15° or greater, it is considered HV deformity.

We conclude that as the EHL, AT, and EHB all aid in extending the first toe, their function needs to be discussed together, which is in accordance with the study by Al-Saggaf.<sup>5)</sup> Type I ATEHL specimens can be subdivided into two groups. In one group, the AT and the fibers of the EHB insert onto the middle of the dorsal base of the proximal phalanx; with this structure, the tension of the AT has no effect on the EHL. In the other group that has a large percentage of cases, the AT inserts onto the medial side of the base of the proximal phalanx; in this configuration, the AT has antagonistic effects on the EHB. Based on our results, we surmise that the position and morphology of the ATEHL have a corrective effect on HV deformity; we also conjecture that because in most cases the ATEHL is of type I, it exerts an antagonistic effect on the EHB to maintain the normal angle of the hallux.

In a previous study, Bayer et al.<sup>1)</sup> concluded that the function of the ATEHL is to provide preloading on the joint capsule to prevent shock when the hallux is dorsiflexed. According to our study, this inference is rational. The dorsal traction from the AT to the joint capsule can lessen the shock to plantar structures when the first MTP joint is dorsiflexed. Denk et al.<sup>2)</sup> also regarded the distal division of the EHL to be an adaptive change related to bipedalism. Bibbo et al.<sup>14)</sup> also hypothesized that the existence of the AT was an adaptive change for human beings to be able to stand and walk as bipeds. They noted that the AT is a structure unique to human beings that has not been found in other quadrupeds. During our dissections, we observed that all of our specimens had an ATEHL. Based on our study and the theoretical evidence from the literature, we deduced a surgical treatment method in which the deviated end of the ATEHL is transferred to the medial side of the first MTP joint capsule to restore bal-

ance between the ATEHL and EHB.

This study has several limitations. First, there was no statistically significant association between sex and HV deformity or the presence of an ATEHL; however, this study only included 5 females (10 feet). Second, there was only 1 type II and 1 type III case identified during dissection, so we cannot draw conclusions on the meaning of these types of ATEHL. Third, the present study was focused on the morphological characteristics of the ATEHL, and no biomechanical functional investigation was performed.

## CONFLICT OF INTEREST

No potential conflict of interest relevant to this article was reported.

## ACKNOWLEDGEMENTS

This study was supported by the Natural Science Foundation of China (31860294), the Natural Science Research Foundation of Jilin Province for the Department of Education (grant no. JJKH20180907KJ).

The authors appreciate those individuals who donated their bodies generously and the comprehensive support provided by Yanbian University College of Medicine, which provided an excellent study environment.

## ORCID

Yue Li	<a href="https://orcid.org/0000-0002-1225-5989">https://orcid.org/0000-0002-1225-5989</a>
Jing-Ying Zhang	<a href="https://orcid.org/0000-0002-0830-5832">https://orcid.org/0000-0002-0830-5832</a>
Xin-Yue Zhao	<a href="https://orcid.org/0000-0002-4259-8894">https://orcid.org/0000-0002-4259-8894</a>
Li-Ya Pan	<a href="https://orcid.org/0000-0002-7996-3023">https://orcid.org/0000-0002-7996-3023</a>
De-Hao Jin	<a href="https://orcid.org/0000-0003-0841-5932">https://orcid.org/0000-0003-0841-5932</a>
He-Xing Xu	<a href="https://orcid.org/0000-0002-4941-6707">https://orcid.org/0000-0002-4941-6707</a>
Hu-Zhe Cui	<a href="https://orcid.org/0000-0001-7196-5983">https://orcid.org/0000-0001-7196-5983</a>
Yan-Qun Liu	<a href="https://orcid.org/0000-0002-4350-1521">https://orcid.org/0000-0002-4350-1521</a>
Xiang-Zheng Qin	<a href="https://orcid.org/0000-0002-9744-5756">https://orcid.org/0000-0002-9744-5756</a>
Qingyuan Li	<a href="https://orcid.org/0000-0002-6998-0524">https://orcid.org/0000-0002-6998-0524</a>

## REFERENCES

1. Bayer T, Kolodziejski N, Flueckiger G. The extensor hallucis capsularis tendon: a prospective study of its occurrence and function. *Foot Ankle Surg.* 2014;20(3):192-4.
2. Denk CC, Oznur A, Surucu HS. Double tendons at the distal attachment of the extensor hallucis longus muscle. *Surg Radiol Anat.* 2002;24(1):50-2.
3. Tate R, Pachnik RL. The accessory tendon of extensor hallucis longus: its occurrence and function. *J Am Podiatry Assoc.* 1976;66(12):899-907.
4. Lundeen RO, Latva D, Yant J. The secondary tendinous slip

- of the extensor hallucis longus (extensor ossis metatarsi hallucis). *J Foot Surg.* 1983;22(2):142-4.
5. Al-saggaf S. Variations in the insertion of the extensor hallucis longus muscle. *Folia Morphol (Warsz).* 2003;62(2):147-55.
  6. Natsis K, Konstantinidis GA, Symeonidis PD, Totlis T, Anastasopoulos N, Stavrou P. The accessory tendon of extensor hallucis longus muscle and its correlation to hallux valgus deformity: a cadaveric study. *Surg Radiol Anat.* 2017;39(12):1343-7.
  7. Bardeen CR. Development and variation of the nerves and the musculature of the inferior extremity and of the neighboring regions of the trunk in man. *Am J Anat* 1906;6(1):259-390.
  8. Moore KL. Before we are born: essentials of embryology and birth defects. 5th ed. Philadelphia: Saunders; 1998. 242-52.
  9. Hill RV, Gerges L. Unusual accessory tendon connecting the hallucal extensors. *Anat Sci Int.* 2008;83(4):298-300.
  10. Macalister A. XLIV: On some points in the myology of the chimpanzee and others of the primates. *Nat Hist.* 1871;7(41):341-51.
  11. Duan X, Kadakia AR. Salvage of recurrence after failed surgical treatment of hallux valgus. *Arch Orthop Trauma Surg.* 2012;132(4):477-85.
  12. Hoffmeyer P, Cox JN, Blanc Y, Meyer JM, Taillard W. Muscle in hallux valgus. *Clin Orthop Relat Res.* 1988;(232):112-8.
  13. Iida M, Basmajian JV. Electromyography of hallux valgus. *Clin Orthop Relat Res.* 1974;(101):220-4.
  14. Bibbo C, Arangio G, Patel DV. The accessory extensor tendon of the first metatarsophalangeal joint. *Foot Ankle Int.* 2004;25(6):387-90.