

Ventricular fibrillation in congenitally corrected transposition of great arteries treated with pacing: a case report

Lei Zhang^{1†}, Hongyang Liu ^{1†}, Qilin Wan¹, and Xinqiang Han ^{1,2*}

¹Department of Cardiology, Huaihe Hospital, Henan University College of Medicine, Kaifeng, Henan 475000, China; and ²Cardiovascular Division, Reid Health, Indiana University School of Medicine, 1100 Reid Parkway, Richmond, IN 47374, USA

Received 17 April 2019; first decision 28 June 2019; accepted 9 October 2019; online publish-ahead-of-print 30 October 2019

Background

Congenitally corrected transposition of the great arteries (CCTGA) is a rare form of congenital heart disease which may present with sudden death from malignant arrhythmias including complete heart block and ventricular tachyarrhythmias as late complications. Only few cases about ventricular tachyarrhythmias, usually in those with markedly depressed systemic ventricular function, have been reported.

Case summary

A 26-year-old woman with a known history of CCTGA presented to the emergency department with palpitations and breathlessness for 3–4 weeks and worsening symptoms for 8 h. She had a history of ventricular septal defect repair 14 years ago. Her initial presentation electrocardiogram demonstrated high degree atrioventricular block with a ventricular rate of 44 b.p.m. She had two episodes of complete syncope during this hospitalization, both required external defibrillation due to documented bradycardia-dependent ventricular fibrillations. Her two-dimensional echocardiography study confirmed the diagnosis of CCTGA with preserved systolic ventricular function. She underwent urgent temporal pacing wire placement with a paced ventricular rate at 90 b.p.m. Having thoroughly reviewed the arrhythmia events and discussed with the patient about the option of defibrillator vs. pacemaker therapy a decision was made upon her request for dual-chamber pacemaker implantation. She was discharged home uneventfully 3 days after hospital presentation and has been physically active at 3-, 6-, and 9-month follow-ups.

Discussion

Our case illustrates the individualized clinical decision making in choosing device therapy for a rare congenital heart disease presented with malignant arrhythmia. Careful history taking, open communication, and closely planned long-term follow-up will be essential in caring for such patients.

Keywords

Congenitally corrected transposition of the great arteries • Ventricular fibrillation • Complete heart block • Pacemaker implantation • Case report

† The first two authors contributed equally to this work.

† The first two authors contributed equally to this work.

* Corresponding author. Tel: +1 765 983 3000, Email: hanxx057@umn.edu

† The first two authors contributed equally to this work.

Handling Editor: Tom de Potter

Peer-reviewers: Konstantinos Iliodromitis and Habib Khan

Compliance Editor: Rahul Mukherjee

Supplementary Material Editor: Deepti Ranganathan

© The Author(s) 2019. Published by Oxford University Press on behalf of the European Society of Cardiology.

This is an Open Access article distributed under the terms of the Creative Commons Attribution Non-Commercial License (<http://creativecommons.org/licenses/by-nc/4.0/>), which permits non-commercial re-use, distribution, and reproduction in any medium, provided the original work is properly cited. For commercial re-use, please contact journals.permissions@oup.com

Learning points

- Congenitally corrected transposition of the great arteries (CCTGA) is a rare form of congenital heart disease which may present with sudden death from ventricular fibrillation.
- Pacing therapy to prevent bradycardia-dependent ventricular fibrillation may be reasonable in CCTGA who presented with high degree atrioventricular block.
- Careful history and clear arrhythmia documentation are essential in clinical decision-making; Imaging study should aid in defining complex cardiac anatomy and facilitate pacing lead implantation in for such patients.

Introduction

Congenitally corrected transposition of the great arteries (CCTGA), also known as L-transposition of the great arteries or ventricular inversion, is a rare and intricate form of congenital heart diseases.^{1–3} Although the etiology of CCTGA remains unclear, the disease is characterized by atrioventricular (AV) and ventriculoarterial discordance resulting from abnormal looping of the embryonic cardiac tube.^{1,2} Most patients may be accompanied by one or more anomalies such as ventricular septal defect (VSD), pulmonary stenosis, and abnormalities of the systemic AV (tricuspid) valve.³ Patients with CCTGA, especially those without other associated defects, may remain undiagnosed until adult life.^{4,5} Both bradyarrhythmias (1st, 2nd, and 3rd degree AV blocks; sinus node dysfunction) and supra-ventricular tachycardias (WPW syndrome, focal atrial tachycardia, atypical AV nodal re-entry, atrial fibrillation, and atrial flutter) have been reported.^{3,6–8} Very few cases about ventricular tachyarrhythmias, usually in those with markedly depressed systemic ventricular function, also have been reported.^{7–9} Here, we report an adult patient with CCTGA and a history of VSD repair who presented with high degree AV block and bradycardia-dependent ventricular fibrillation being successfully treated with pacemaker implantation.

Timeline

Timeline	Clinical events	Investigations
12 years old	Ventricular septal defect repair	Echocardiography: congenitally corrected transposition of the great arteries (CCTGA)
19 years old	Uneventful pregnancy Healthy delivery	
22 years old	Syncopal event	Electrocardiogram (ECG): sinus rhythm with intraventricular conduction delay, QRS 120 ms Holter: no significant tachy- or bradyarrhythmias Oesophageal electrophysiology: normal sinus node function and atrioventricular (AV) node conduction; no ventricular arrhythmia induction
26 years old	Shortness of breath Witnessed syncope	ECG: high degree AV block Cardiac monitor: ventricular fibrillation

Case presentation

The patient was a 26-year-old woman who presented to the emergency department with palpitations and breathlessness for 3–4 weeks and worsening for 8 h. She had a history of VSD repair which was performed 14 years earlier after she was diagnosed with CCTGA. Seven years after the operation one healthy child was born after uneventful pregnancy. She also reported a 'syncopal event' 10 years after VSD repair although no further detail regarding the event could be elucidated. Holter's study at that time only demonstrated no significant tachy- or bradyarrhythmias. Her transoesophageal atrial and ventricular pacing study demonstrated normal sinus node function and AV conduction without inducible ventricular tachycardia (VT). Multiple follow-up electrocardiograms (ECGs) 11 and 13 years after open-heart surgery only showed mild first-degree AV block and intraventricular conduction delay, with one ECG illustrated in [Figure 1A](#). On this admission, her ECG showed high degree AV block ([Figure 1B](#)) with a ventricular rate of 44 b.p.m. A fusion beat could be seen (the 3rd QRS). Her blood pressure was 102/57 mmHg. Respiratory rate was 25/min and oxygen saturation was 98% on room air. The remainder of the examination was unremarkable. Her B-type natriuretic peptide was mildly elevated at 1623 pg/mL (normal 0–450 pg/mL). Other relevant biochemical and haematologic parameters were within normal limits. Her weakness and shortness of breath further worsened shortly after admission and she 'passed out' twice, both required electric defibrillation. Her ECG rhythm strip at

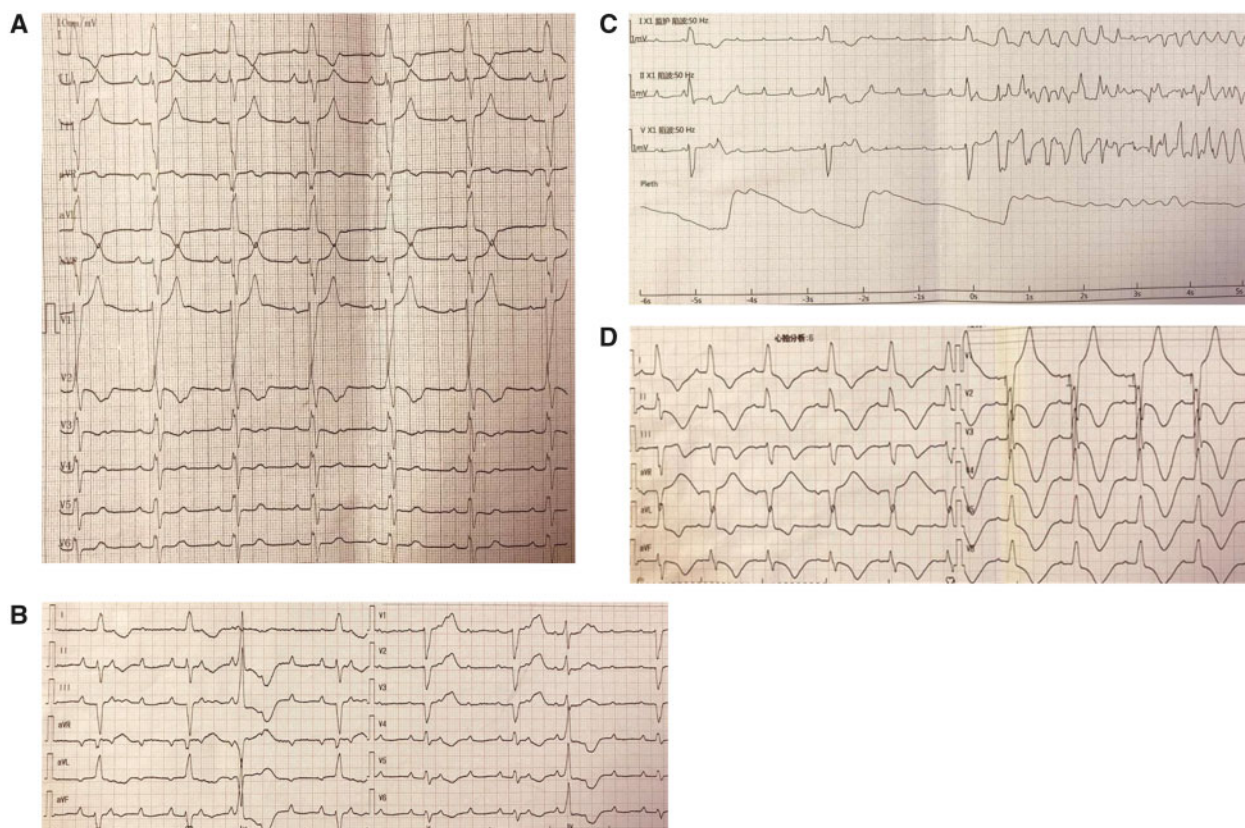


Figure 1 Baseline electrocardiogram with 1st-degree atrioventricular block plus interventricular conduction delay and the presentation electrocardiogram are shown in A and B, respectively. Rhythm strip from the first captured syncope event requiring defibrillation is shown in C. Electrocardiogram after pacemaker implantation is shown in D.

one such event was shown in [Figure 1C](#). After a bedside Echo study confirming CCTGA [right ventricle (RV) is the systolic ventricle] and preserved right ventricular systolic function [ejection fraction (EF) 55–60%] the patient was taken to the EP lab with implantation of a temporary pacemaker. She was ventricularly paced at 90 b.p.m. and remained completely haemodynamically stable overnight. She received a dual-chamber pacemaker (XL DR 5826, St. Jude Medical, USA), the next day after a thorough discussion with patient and her family members regarding various treatment options including single-chamber, dual-chamber, and resynchronization pacemaker or defibrillator. The atrial and ventricular leads were fixed in the right atrium and high interventricular septum, respectively. Her paced ECG was shown in [Figure 1D](#), with QRS morphology being consistent with high septal pacing. The Echo study with four-chamber views, the chest X-rays before and after pacemaker implantation were shown in [Figure 2A–C](#), respectively. The ventricular lead was intentionally implanted in the mid- to high septum so that the paced QRS duration was similar to the native QRS prior to pacemaker implantation. This was achieved with careful mapping. The high resolution computed tomography (CT) reconstruct of three-dimensional imaging for the patient's CCTGA anatomy after pacemaker implantation was shown in [Figure 3A and B](#). The CT study also confirmed the high septal ventricular lead location. Patient was discharged home in clinically stable

condition. She has been physically active at 3, 6, and 9-month follow-ups. Repeat Echo study at a 6-month follow-up showed systolic ventricular function at 57%. Her pacemaker interrogation demonstrated atrial sensing and ventricular pacing rhythm without ventricular tachyarrhythmia. Atrial sensing was 4.4 mV, threshold was 0.5 V at 0.5 ms, and impedance was 538 ohms. Ventricular sensing was 6.8 mV, threshold was 0.5 V at 0.5 ms, and impedance was 326 ohms. Atrial pacing was 19% and ventricular pacing was >99% being in complete AV block. Those parameters were essentially unchanged from previous interrogation at hospital discharge.

Discussion

Congenitally corrected transposition of the great arteries is a rare congenital heart disease accounting for <1% of all congenital anomalies.^{1–3} Of the coexisting malformations, VSD is among the most frequent and usually occurs peri-membranous. If there are no associated defects, which are relatively uncommon, the patient will typically be asymptomatic early in life. Accurate diagnosis can usually be made by means of ECG, chest radiograph, and echocardiography in addition to a careful history and physical examination. The natural history of CCTGA is usually defined by the associated malformations,

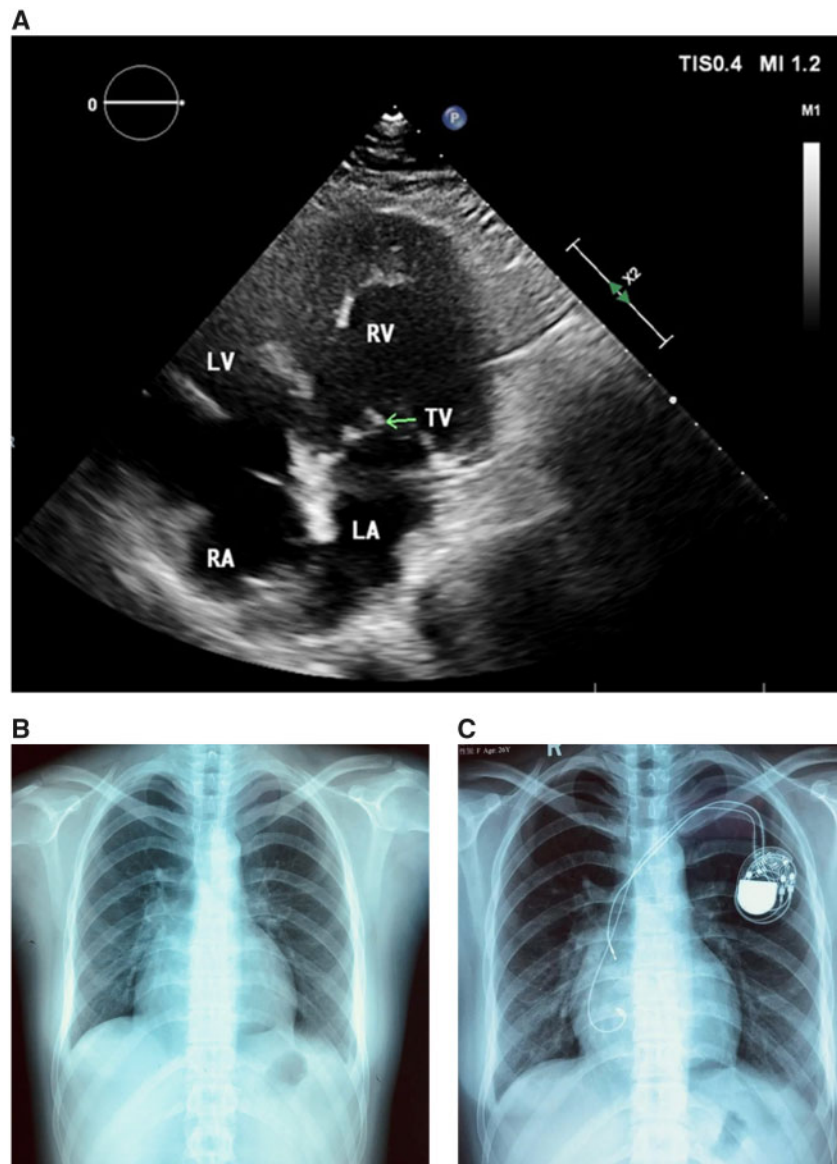


Figure 2 Echo study with apical four-chamber view of the heart illustrating reversal insertion of the ventricles (A). The order of connection was as follows: right atrium—mitral valve—morphology left ventricle—pulmonary artery; left atrium—tricuspid valve—morphology right ventricle—aorta. Pacemaker lead was visible in right atrium and left ventricle. Anterior and posterior views of chest X-rays before (B) and after (C) pacemaker implantation. Ventricular lead was implanted in high septum.

and also by the time and approach to surgical repair.¹⁰ This patient was diagnosed with peri-membranous VSD because of her cyanosis in late childhood and had VSD repair at 12 years old. She had uneventful pregnancy and delivery at the age of 19 years old.

Congenitally corrected transposition of the great arteries is known to have increased risk of AV block. Some studies have shown that the AV blocks can be present before birth and acquired at a rate of 2% per year.^{2,11} Nonetheless, VT has rarely been described in the natural history of CCTGA.^{7–9} The mechanisms of VT is generally assumed to be scar-related re-entry or enhanced abnormal automaticity such as those commonly occurring during progressive left ventricular failure. However, it remains unknown if the mechanism of VT in CCTGA (in

which the RV is the systemic pumping chamber) is similar to those patients whose left ventricle is the systemic pump. Some CCTGA patients with systemic ventricular dysfunction and ventricular arrhythmias appropriately underwent implantable cardioverter-defibrillator (ICD) implantation for secondary prevention.^{8,9,12} However, in this patient no documented VT or ventricular fibrillation occurred before admission or at least 9 months after hospital discharge. The ventricular fibrillation was seen during marked bradycardia from high degree AV block, with premature ventricular contraction clearly occurring on top of the previous T (Figure 1C). While the patient's refusal of ICD being a factor considered in the management, pacemaker implantation to prevent both bradycardia

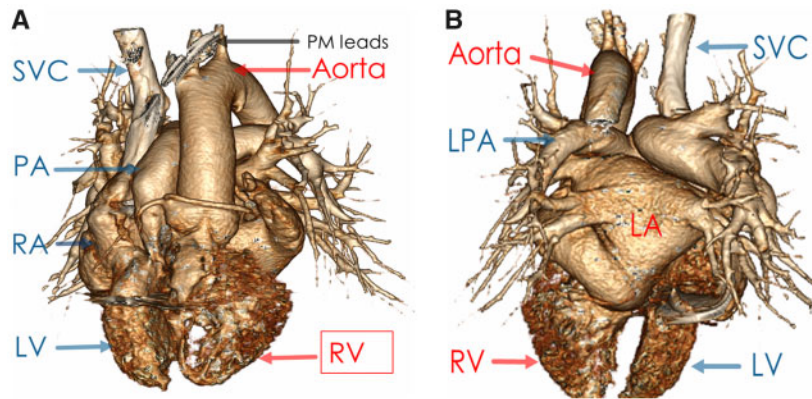



Figure 3 Three-dimensional reconstruct of patient's congenitally corrected transposition of the great arteries anatomy by high resolution computed tomography with anterior (A) and posterior (B) views. LPA, left pulmonary artery; PA, pulmonary artery; PM, pacemaker; SVC, superior vena cava.

and bradycardia-dependent torsades de pointes remains an acceptable alternative in this clinical situation. A recent study¹³ reported no sudden death with a ventricular arrhythmia of 3% (2 out of 73 patients) at a follow-up of 7.2 years in CCTGA with systolic ventricular EF >35%. Nonetheless, pacemaker implantation sometimes can be challenging in patients with CCTGA owing to the complex anomalies and related surgical repairs. Information about detailed anatomy and coexisting malformation sometimes can be obtained by contrast-enhanced CT or magnetic resonance imaging before the procedure. Biventricular function should be periodically monitored during follow-up given that the majority of patients with CCTGA develop progressive congestive cardiac failure.

Conclusion

Pacing therapy can be reasonable and effective in preventing bradycardia-dependent ventricular tachyarrhythmia in patients with CCTGA who develop high degree AV block.

Lead author biography



Dr Lei Zhang graduated from a 7-year MD/MSc programme in May 2019 from Henan University College of Medicine. She was awarded the first-class Scholarship every year during her medical school training and has a special interest in Interventional Cardiology. Currently, she is a Junior Physician at Huaihe Hospital (a major teaching affiliate with more than 2700 patient beds) of Henan

University College of Medicine, China.

Supplementary material

Supplementary material is available at *European Heart Journal - Case Reports* online.

Acknowledgements

The authors would like to thank Drs Ying Chen, Yanming Li, Ruili He, Xiaoming Zhong, Guanchang Cheng, Yan Hong, Xiaohong Zhang, and Peng Nie, all from Huaihe Hospital, Henan University College of Medicine, for their contributions in stimulating discussion and cardiac imaging preparation.

Slide sets: A fully edited slide set detailing this case and suitable for local presentation is available online as [Supplementary data](#).

Consent: The author/s confirm that written consent for submission and publication of this case report including image(s) and associated text has been obtained from the patient in line with COPE guidance.

Conflict of interest: none declared.

References

1. Van Praagh R. What is congenitally corrected transposition? *N Engl J Med* 1970; **282**:1097–1098.
2. Wallis GA, Debich-Spicer D, Anderson RH. Congenitally corrected transposition. *Orphanet J Rare Dis* 2011; **6**:22.
3. Warnes CA. Transposition of the great arteries. *Circulation* 2006; **114**:2699–2709.
4. Presbitero P, Somerville J, Rabajoli F, Stone S, Conte MR. Corrected transposition of the great arteries without associated defects in adult patients: clinical profile and follow up. *Br Heart J* 1995; **74**:57–59.
5. Bullock-Palmer RP, Rohen A. Congenitally corrected transposition of the great arteries (CCTGA) initially presenting in the sixth decade. *Echocardiography* 2009; **26**:1118–1120.
6. Kodliwadmath A. Congenitally corrected transposition of great vessels with infundibular pulmonary stenosis with ventricular septal defect, presenting with atypical atrioventricular nodal reentrant tachycardia: a rare association. *Int Med Case Rep J* 2017; **10**:319–322.
7. Kasar T, Ayyildiz P, Tunca Sahin G, Ozturk E, Gokalp S, Haydin S, Guzelas A, Ergul Y. Rhythm disturbances and treatment strategies in children with

- congenitally corrected transposition of the great arteries. *Congenit Heart Dis* 2018;**13**:450–457.
8. McCombe A, Touma F, Jackson D, Canniffe C, Choudhary P, Pressley L, Tanous D, Robinson PJ, Celermajer D. Sudden cardiac death in adults with congenitally corrected transposition of the great arteries. *Open Heart* 2016;**3**: e000407.
 9. Kayrak M, Kaya Z, Gul EE, Ulgen MS, Yazici M, Gumus S, Paksoy Y. Congenitally corrected transposition of great arteries with severe rhythm disturbances. *Indian Pacing Electrophysiol J* 2010;**10**:179–183.
 10. Kutty S, Danford DA, Diller GP, Tutarel O. Contemporary management and outcomes in congenitally corrected transposition of the great arteries. *Heart* 2018;**104**:1148–1155.
 11. Paladini D, Volpe P, Marasini M, Russo MG, Vassallo M, Gentile M, Calabrò R. Diagnosis, characterization and outcome of congenitally corrected transposition of the great arteries in the fetus: a multicenter series of 30 cases. *Ultrasound Obstet Gynecol* 2006;**27**:281–285.
 12. Hohmann S, Duncker D, König T, Horke A, Westhoff-Bleck M, Veltmann C. Implantable cardioverter defibrillator therapy in grown-up patients with transposition of the great arteries-role of anti-tachycardia pacing. *J Thorac Dis* 2018;**10**(Suppl 15):S1769–S1776.
 13. Kapa S, Vaidya V, Hodge DO, McLeod CJ, Connolly HM, Warnes CA, Asirvatham SJ. Right ventricular dysfunction in congenitally corrected transposition of the great arteries and risk of ventricular tachyarrhythmia and sudden death. *Int J Cardiol* 2018;**258**:83–89.