



Sagittal balance: from theory to clinical practice

Juan I. Cirillo Toterá^{1,2}

José G. Fleiderman Valenzuela^{1,2}

Jorge A. Garrido Arancibia¹

Samuel T. Pantoja Contreras¹⁻³

Lyonel Beaulieu Lalanne¹

Facundo L. Alvarez-Lemos⁴

- Adequate sagittal balance (SB) is essential to maintain an upright, efficient, and painless posture. It has been shown that sagittal profile alterations affect quality of life of patients with a similar or even greater impact than chronic disease.
- Evaluation of the SB has gained much relevance in recent years, with recognition of its importance in the evaluation of spinal pathology.
- This review summarizes the basic principles of SB, aiming to obtain a practical, simple and understandable evaluation of the sagittal profile of a patient.
- SB is a dynamic process that involves a varying degree of energy expenditure. Distinguishing between a balanced, compensated imbalance or decompensated imbalance patient, is relevant to diagnosis and therapeutic decision-making.

Keywords: lumbar lordosis; pelvic incidence; radiographic parameters; sagittal balance; sagittal imbalance; vertebral column

Cite this article: *EFORT Open Rev* 2021;6:1193-1202.

DOI: 10.1302/2058-5241.6.210062

Introduction

One function of the vertebral column (VC), is to maintain an upright posture, allowing standing (exclusive to humans). This is achieved through the harmonic development of curves in the sagittal plane that make up the sagittal balance (SB), where the forces exerted are evenly distributed. Sagittal alteration or imbalance (SI) of these curves conditions the requirement of additional forces to counteract this imbalance in order to maintain an upright posture. This can be represented through Dubousset's¹ concept of the 'cone of economy', where the body is inside an inverted cone of small diameter, the 'cone of balance'. Positioning outside of this cone will require greater muscle activation to maintain posture (Fig. 1).

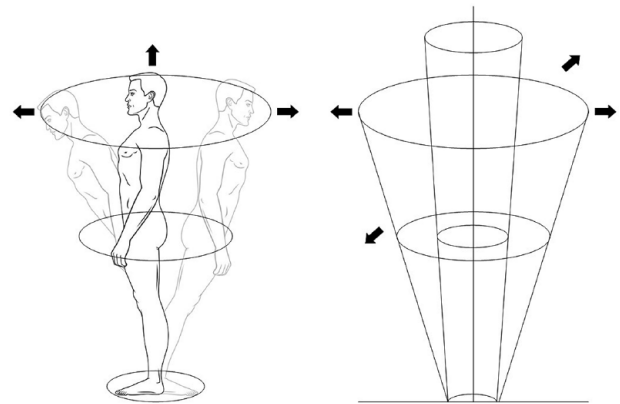


Fig. 1 Economy cone scheme according to Dubousset.¹

Sagittal profile alterations have been shown to affect quality of life of patients with a similar or even greater impact than pathologies such as chronic lung disease, visual disturbances, osteoarthritis, rheumatoid arthritis, etc.² This may explain its growing interest on the part of specialists, with an increase in registered publications in recent years (Fig. 2).

Method

A non-systematic review was carried out in PubMed of articles published between January 2000 and December 2020, with the terms "sagittal alignment", "sagittal balance", "sagittal imbalance", "pelvic incidence" and "lumbar lordosis". The inclusion criteria were articles, clinical guidelines, systematic reviews and randomized controlled trials (RCTs) published in indexed journals, with full-text availability. In addition, the references of these articles were checked for significant studies that were outside our chronological range. From this review, the relevant publications were selected to determine the main radiographic

RESULTS BY YEAR

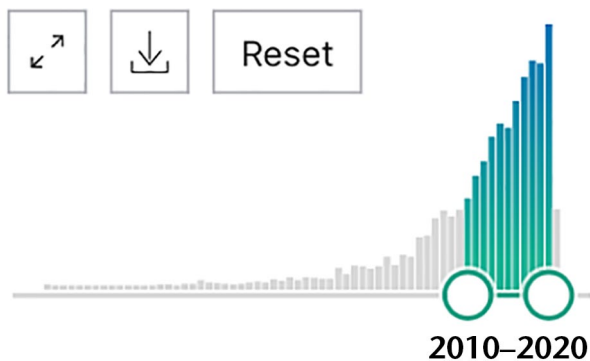


Fig. 2 Publications registered in PubMed. From 1990 to 2010, 915 publications were registered, while from 2010 onwards the number increased to 2262.

parameters (RP); both regional (cervical lordosis, thoracic kyphosis, lumbar lordosis, pelvic incidence, pelvic tilt and sacral slope) and global (SVA [sacral vertical axis] and T1-pelvis angle), the relationship between them, the implication of physiological ageing of the VC on these RP and with its clinical repercussions and finally, to propose in a practical way what we consider an adequate analysis of the sagittal profile, encompassing the aforementioned concepts.

Studies in basic sciences, animal or cadaveric studies and populations under the age of 18 years were excluded.

Radiographic parameters

Spinal balance can be appropriately measured by conventional radiology. Correct radiological technique is crucial; measurements must be made in lateral plane X-ray, including the entire VC (from the external auricle to the femoral heads),³ with the patient in a relaxed position, without support from the upper extremities, without extension of the knees or hips and with the hands placed on the clavicles ('clavicle position', Fig. 3).⁴ This is the position that allows visualization of the anatomical points of reference necessary for the measurement of the different RP that guide us in the spatial location of the VC in the sagittal plane, with minimal impact on the natural posture of the patient.⁵ The radiological parameters that can be measured are multiple, and can be divided into regional and global. The most used in daily practice are mentioned below.

Regional

The regional curvatures of the VC are quantified using the Cobb method,⁶ through the angle formed by the upper and lower endplates of the most proximal and caudal vertebra, respectively, of the spine region.⁷



Fig. 3 Clavicle position.

Cervical lordosis (CL) – angle between lower endplate of C2 and C7. In the upper cervical region, the angulation between level C0-C2 (C0-2), measured between the McRae line and the lower endplate C2, can also be considered.

Thoracic kyphosis (TK) – angle between upper endplate of T1 and inferior of T12. Many measurements are made at the level of the upper endplate of T4 due to the frequent poor visualization of T1 (due to the interposition of the shoulders). According to Le Huec and Hasegawa's study, the average kyphosis between T1 and T4 is equal to 8° and 10°.⁵ *Lumbar lordosis* (LL) – angle between the upper endplates of L1 and S1 (Fig. 4).

Lumbopelvic

Work of Duval-Beaupere.^{6,7} The study of SB should include the pelvis, which conceptually is the first vertebra of the VC, which it is closely related to it.¹

Pelvic incidence (PI) – angle between a perpendicular line to the midpoint of the upper endplate of S1 and the line that runs from this same point to the centre of both femoral heads (if they do not coincide, the midpoint of a line joining the centre of these two has to be utilized).

Sacral slope (SS) – angle formed between the tangent to the top endplate of S1 and a line parallel to the horizon.

Pelvic tilt (PT) – angle formed between a vertical line to the centre of the femoral heads and another line to the centre of the upper endplate of S1 (Fig. 5).

Global

C7 plumb line (C7PL) – line from the centre of the C7 body, perpendicular to the horizon.

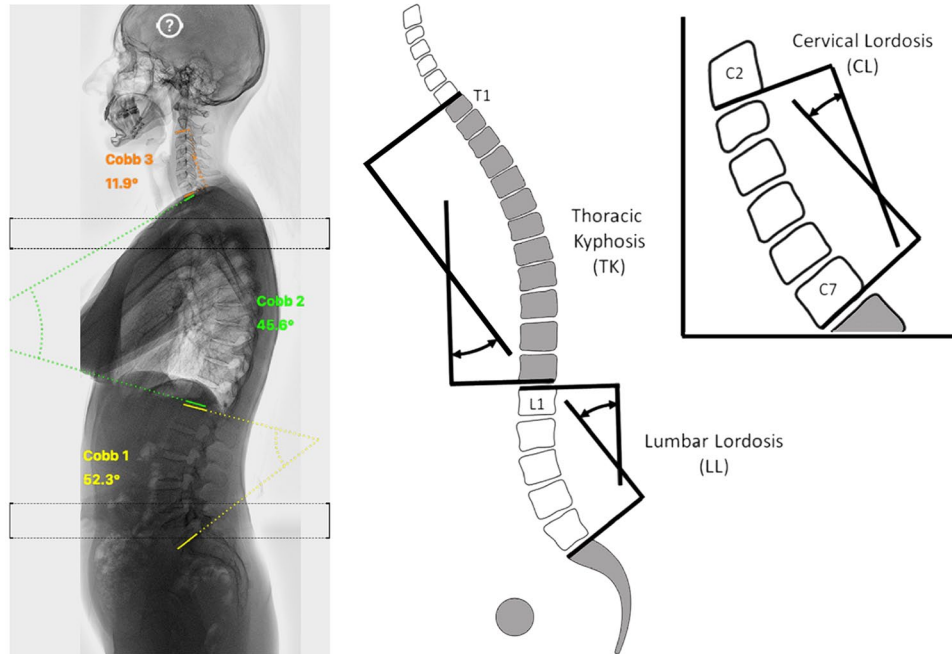


Fig. 4 Cervical lordosis, thoracic kyphosis and lumbar lordosis measurement scheme.

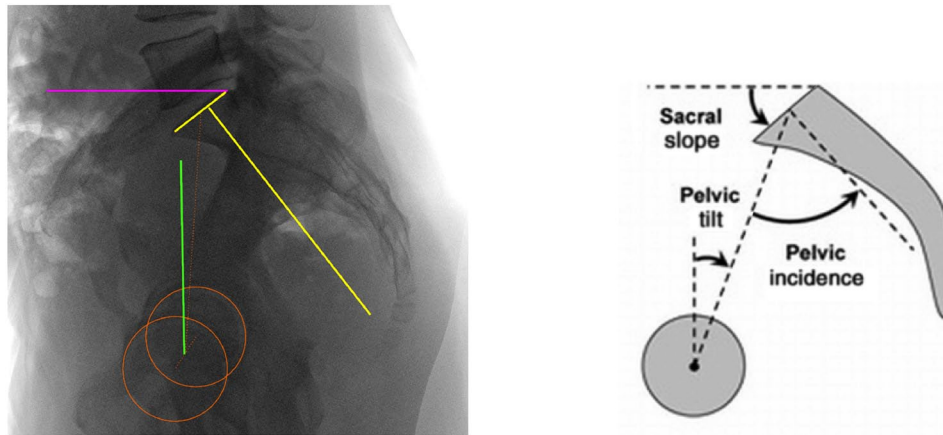


Fig. 5 Measurement of pelvic incidence, pelvic tilt and sacral slope.

Sacral vertical axis (SVA) – distance between the posterior superior margin of S1 and the C7PL. An SVA ahead of, within, or behind the acceptable range (5 cm) classifies the alignment as positive, neutral, or negative, respectively. In general, an adequate overall balance is considered when this line falls behind the hips.

T1-pelvic angle (TPA); angle formed by the union of a line from the centre of the T1 to the centre of the femoral heads and from this, to the centre of the upper endplate S1 (Fig. 6).

In theory, each parameter or curve should ideally remain within a respective normal range. It should be

considered, however, that within a healthy and asymptomatic population there is a wide range of values that can be considered as ‘normal’ (Table 1).^{8–12} Additionally, it must be considered that these values change with the physiological ageing of the VC, resulting in older, asymptomatic individuals, with values that could be considered ‘abnormal’ for a younger population. For this reason, Schwab et al and Lafage et al established age-adjusted values (Table 2), from a linear regression analysis of different RP in relation to age and quality of life, reinforcing that the ideal sagittal alignment should consider age, where younger patients require a more rigorous alignment than those of older age.^{13,14}

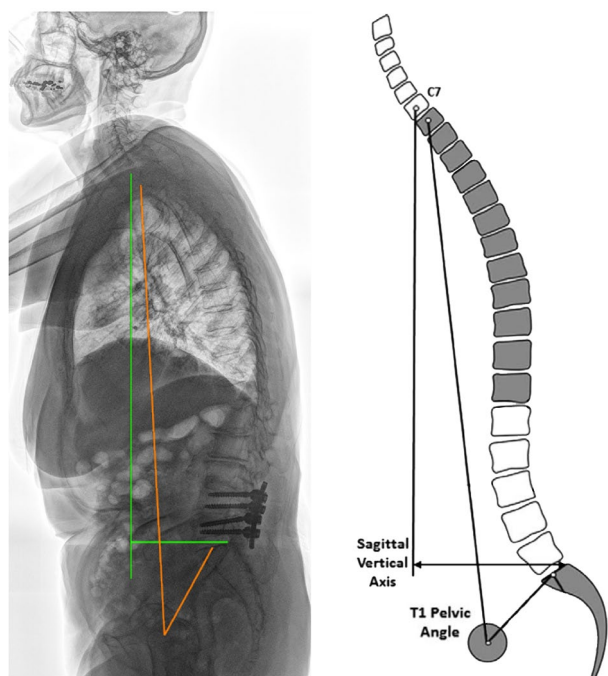


Fig. 6 Measurement of C7 plumb line, sacral vertical axis and T1-pelvic angle.

Concepts to consider

Unlike SS and PT, which vary according to the patient’s posture, the PI is constant, recognized as a morphological parameter (fixed) because the mobility of the sacroiliac joints is negligible during adult life. In its essence, the PI is a reflection of the anteroposterior diameter of the pelvis, distinguishing individuals with a ‘wide’, ‘normal’ or ‘narrow’ pelvis.

The SS indicates the inclination of the sacrum (low SS = vertical sacrum, high SS = horizontal sacrum), which sets

the stage for the lumbar curve, while the PT translates the degree of pelvic version (anteversion or retroversion).

The PI represents the pelvic version’s potential (low PI = narrow pelvis with little retroversion power, high PI = wide pelvis with great retroversion capacity). This relationship between lumbopelvic parameters is mathematically corroborated through the formula $PI = PT + SS$ (Fig. 7).¹⁵

There is a close relationship between PI and LL,⁴ allowing estimation of a harmony between the pelvic morphology and the lumbar curve, called ‘match’. In a pragmatic way, this relationship should be $\leq 10^\circ$ ($PI-LL \geq \pm 10^\circ$), identifying this value as a target for spinopelvic alignment. Outside this range, there will be a spinopelvic ‘mismatch’.¹²

However, the balance must consider the thoracic shape. For this reason, Schwab et al propose an adjusted formula, $LL = (PI + TK) / 2 + 10$, that relates different RP, representing a more faithful image of the sagittal alignment.¹⁶

In clinical practice, because of its simplicity, SVA measurement is frequently used. Thus, those patients who present a normal or neutral SVA will be considered as balanced and those who exceed the limit, positive SVA, unbalanced. However, a more detailed evaluation may reveal that in some cases, this normality ($SVA < 5$ cm) has been achieved through postural compensation mechanisms,¹⁵ determined by the particular anatomy of each individual.

Furthermore, SVA is subject to postural variations, where altered values may be the consequence of an antalgic posture and not the result of real misalignment.¹⁷ Because of this, the TPA, like the ‘global tilt’ (GT) angle formed by the union of a line drawn from the centre of C7 to the centre of the sacral endplate and, from this, to the centre of the femoral heads, represent two global RP, independent of the patient’s posture, which can aid in differentiating between a true SI and one caused by posture.¹⁸

Table 1. Average normal values of radiographic parameters based on studies carried out on healthy and asymptomatic adult population

Parameter	Average normal value	Reference				
		Schwab 2006 ⁵¹	Boulay 2006 ⁵²	Roussouly 2006 ⁵³	Berthonnaud 2005 ⁵⁴	Vialle 2005 ⁸
CL	10–40	–	–	–	23.9 ± 3.9 (9.5–44.5)	–
TK (T4–T12)	20–50	41 ± 12	53.8 ± 10.1	46.3 ± 9.5 (23–65.9)	47.5 ± 4.8 (22.5–70.3)	40.6 ± 10 (0–69)
LL (L5–S1)	30–85	60 ± 12	66.4 ± 9.5 (44.8–87.2)	50.6 ± 10.2 (39.9–83.7)	42.7 ± 5.4 (16–71.9)	60.2 ± 10.3 (30–89)
PI	33–83	52 ± 10	53.1 ± 9 (33.7–77.5)	50.6 ± 10.2 (27.9–82.8)	51 ± 5.3 (33.7–83.7)	54.7 ± 10.6 (33–82)
SS	20–65	30 ± 9	41.2 ± 7 (0.6–19.7)	39.6 ± 7.6 (17.5–63.4)	39.7 ± 4.1 (21.2–65.9)	41.2 ± 8.4 (17–63)
PT	–2–27	15 ± 7	12 ± 6.4 (–2–30)	11 ± 5.9 (–2.8–23.7)	12.1 ± 3.2 (–5.1–30.5)	13.2 ± 6.1 (–4.5–27)
SVA	< 5 mm	–20 ± 30	–	35 ± 19.4	–	–
TPA	< 14° ⁵⁵	–	–	–	–	–
Mismatch (PI-LL)	< ±10° ¹²	–	–	–	–	–

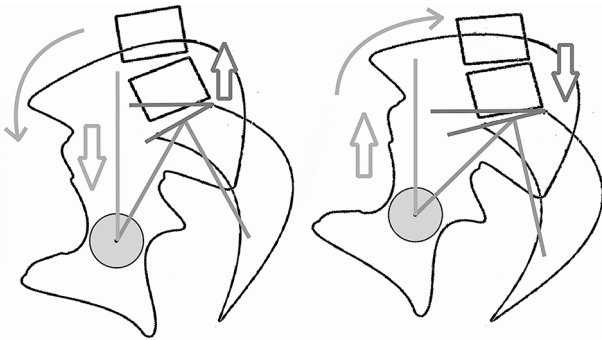
Notes. CL, cervical lordosis; TK, thoracic kyphosis; LL, lumbar lordosis; PI, SS, sacral slope; PT, pelvic tilt; SVA, sacral vertical axis; TPA, T1-pelvic angle.

Table 2. Radiographic parameter values according to age in relation to quality of life (ODI)

Age	Radiographic thresholds in relation to age and Oswestry Disability Index (ODI)									
	Moderate disability (ODI = 20)					Severe disability (ODI = 40)				
	PT	PI-LL	LL-TK	SVA	TPA	PT	PI-LL	LL-TK	SVA	TPA
< 35	11.3	-6.8	27.6	-17.4	6.2	13.2	1.8	24.5	5.0	9.8
35-44	15.1	-2.7	20.7	5.2	11.5	17.0	5.9	17.6	27.6	15.0
45-54	17.8	0.2	15.7	21.6	15.3	19.7	8.8	12.6	44.0	18.8
55-64	20.2	2.9	11.3	36.1	18.7	22.2	11.5	8.2	58.5	22.2
65-74	22.6	5.5	6.9	50.4	22.0	24.6	14.1	3.8	72.8	25.5
> 75	25.2	8.3	2.1	65.8	25.6	27.1	16.9	-1.0	88.2	29.1

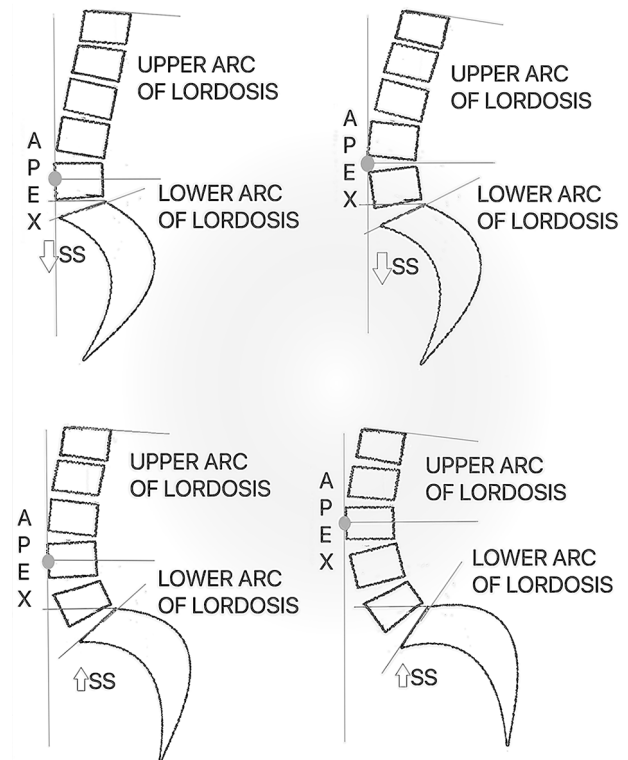
Note. PI, pelvic incidence; TK, thoracic kyphosis; LL, lumbar lordosis; PT, pelvic tilt; SVA, sacral vertical axis; TPA, T1-pelvic angle.

Source: Taken from Lafage R, Schwab F, Challier V, et al. Defining spinopelvic alignment thresholds: should operative goals in adult spinal deformity surgery account for age? *SPINE* 2016;41:62-68.

**Fig. 7** Relationship of lumbopelvic parameters.

For Roussouly¹⁹ the concept of LL, based only on anatomical limits, is erroneous; the distribution of LL must also be considered, with two thirds of the LL located in the last two segments (L4-S1) with more proximal levels sometimes kyphotic, postulating that the true LL originates from the sacrum to the point of inflection, where it passes from a lordotic to a kyphotic spine (regardless of whether this occurs at the lumbar or dorsal level). According to this turning point and the relationship established between LL and PI, not all patients have the same sagittal profile. Thus, he classifies them into four types (Fig. 8),²⁰ which are predisposed to different degenerative changes:^{21,22}

- Type I: low PI (< 45°), low SS (< 35°), short LL (apex at L5 level) and thoracolumbar kyphosis; Low lumbar hyperlordosis, with greater biomechanical stress on the posterior structures and at the thoracolumbar transition level, with little capacity for pelvic retroversion, predisposing to isthmic spondylolisthesis at the level of L5-S1 ‘nutcracker-type’ and thoracolumbar discopathy.
- Type II: low PI (< 45°), low SS (< 35°), LL plus harmonic (apex at disk level L4-L5); Flat back, with horizontal

**Fig. 8** Morphological types of sagittal profile according to Roussouly²⁰.

discs (slightly lordotic), with higher axial stress from L4-L5 and L5-S1 discs.

- Type III: high PI (45-60°), average SS (35-45°), better distribution of lordosis (apex at L4 level); More harmonic SB, without predisposition to degenerative pathology.
- Type IV: high PI (> 60°), high SS (> 45°), long LL (apex at L3 level) and short kyphosis; similar to type I, they present greater stress on the posterior structures of the lower lumbar segments, but due to a ‘shear-type’ mechanism.

Similarly, Pesenti et al²³ demonstrated an association between proximal (L1-L4) lordosis with pelvic anatomy, with larger PI accompanying larger proximal lordosis. With increasing PI values, a greater recruitment of lordotic levels is generated, producing a proximal migration of the lordosis apex, increasing proximal (L1-L4), but not affecting distal (L4-S1) lordosis. Their findings suggest that lordosis is not homogeneously distributed across the different lumbar levels, with the L4-S1 segment responsible for roughly 2/3 and the proximal, L1-L4, segment accounting for about 1/3 of total lordosis. Also, distal L4-S1 lordosis was nearly constant and independent of PI. The proximal part of the lumbar spine had the most variability across individuals and appeared to accommodate to

pelvic morphology (incidence). They suggested that this may serve as a therapeutic guide for the restoration of a specific lumbar shape based on pelvic morphology rather than a global lordosis that matches the PI. The distribution of the segmental LL should be considered when planning realignment surgery, rather than just the global lordosis.

Pathophysiology of ageing, impact on spinal balance and clinical implications

SB is a dynamic phenomenon that is altered by the degenerative phenomena that normally occur with aging, mainly at the level of the disc,²⁴ where, together with the atrophy of the paraspinal extensor musculature, they generate a loss of LL (main driver of spinopelvic imbalance). This will affect the rest of the VC, producing ‘reciprocal changes’²⁵ to prevent the trunk from moving forward; that is, by triggering compensatory mechanisms.

In the first instance, the lumbar spine tries to compensate for this loss of lordosis by generating hyperextension of one or more segments, segmental lordosis greater than 15° (Fig. 9), with a consequent increase in stress on the posterior structures (articular facets),²⁶ while at the same time, an attempt is made to flatten the TK²⁷ at the expense of a muscular effort, in order to move the head to the centre of the body and maintain a horizontal gaze.

The second compensatory mechanism occurs in the pelvis, which rotates in a posterior direction around the femoral heads (pelvic retroversion), generating an increase in PT and a decrease in SS, a product of contracture of the gluteal muscles and secondary extension of the hips. This retroversion capacity is conditioned by its anteroposterior diameter (PI), being more limited for smaller PIs.^{28,29} Once maximum pelvic retroversion has been reached, other more distal mechanisms are activated, producing flexion of the knees and subsequent dorsal flexion of the ankles (Fig. 10).^{26,30,31}

The activation of these mechanisms in response to a SI (column ‘unbalanced but compensated’) is individual to each person and, in the same way, presents a particular

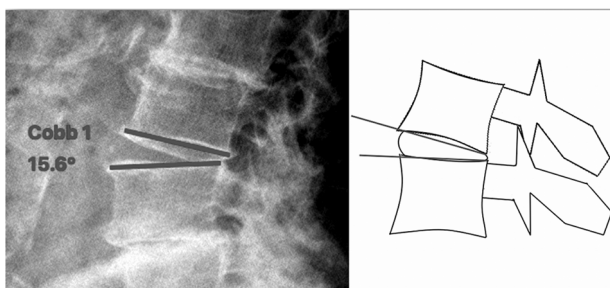


Fig. 9 Segmental hyperextension as a regional compensatory mechanism.

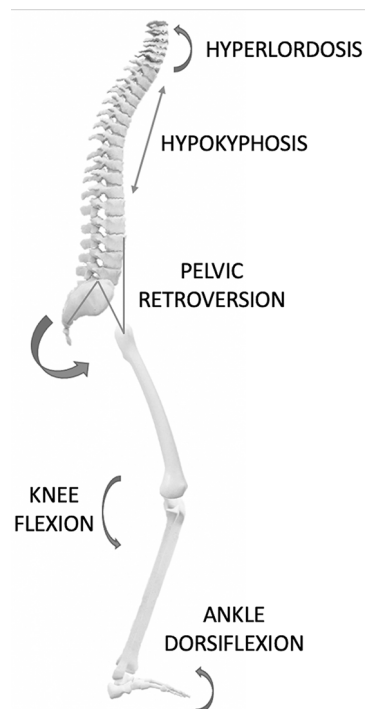


Fig. 10 Global vision of compensatory mechanisms.

physiological limit of each individual. When these limits are overcome, we speak of a column ‘unbalanced and decompensated’.³²

The relationship between a SI and altered quality of life, disability and pain has been widely demonstrated in the literature.^{12,33,34} In 2005, Glassman³⁵ demonstrated greater pain and a decrease in the quality of life in patients who presented an increase in SVA. Lazennec et al³⁶ showed that patients with elevated PT, compared to their preoperative values, presented greater postoperative pain. Similarly, Lafage et al³² associated elevated PT and SVA values with pain and worse health-related quality of life (HRQOL) outcomes. Subsequently, Schwab et al,³⁷ supporting the relationship between PT and SVA and adding the relationship between PI and LL (mismatch), established cut-off points in relation to high disability values (Oswestry Disability Index - ODI > 40);

- SVA > 45.9 mm
- PT > 22, 1°
- PI-LL > ±11, 4°

Based on these values, they created the ‘SRS-Schwab’ classification for adult deformities (Table 3).³³

The association between pain and SI is explained through the understanding of degenerative processes and the associated compensatory mechanisms. Recent studies have questioned this presumed relationship between SI

Table 3. SRS-Schwab classification for adult deformities³⁶

Type of coronal curve	Sagittal modifier
T thoracic curve With lumbar curve $<30^\circ$	PI - LL 0: $< 10^\circ$ +: 10 a 20° ++: >20
L thoracolumbar or lumbar curve With thoracic curve $<30^\circ$	Global alignment 0: SVA < 4 cm +: SVA 4–9.5 cm ++: SVA > 9.5 cm
D Double curve T and L curves, both $>$ at 30°	Pelvic tilt (PT) 0: PT $< 20^\circ$ +: PT 20– 30° ++: PT $> 30^\circ$
N no coronal curve All the curves $< 30^\circ$	

Note. PI, pelvic incidence; LL, lumbar lordosis; SVA, sacral vertical axis.

and the negative impact on health status.^{38,39} Only weak correlations have been found between SVA and PT with the different HRQOL and ODI scores,⁴⁰ also implying that the clinical impact of sagittal malalignment only explains a small portion of the variance of ODI,⁴¹ while demographic variables, such as age, sex, body mass index (BMI), etc., seemed to explain up to 40.1% of this.⁴²

The relevance of the RP should not be minimized, but it seems that its main importance does not lie in a direct negative correlation with the patient's HRQOL, but rather in understanding the SI of a patient, which should be assessed and quantified whenever we face spinal pathologies and considered within surgical planning in long fixations with associated osteotomies, but also for less extensive surgeries such as focal decompressions. Here RP will provide a context with respect to the potential risk of mechanical failure attributable to increased loads that are likely to present after surgery.

From theory to practice

Sagittal profile analysis

A patient presenting global parameters within adequate values (a neutral SVA and a TPA $< 14^\circ$), with lumbopelvic harmony (LL appropriate for his PI) is balanced, without requiring compensatory mechanisms to maintain this situation, those that are objectified by a low PT and an SS in value according to their PI (Fig. 11).

Similarly, a patient may present a neutral SVA, but with a mismatch between his PI and LL due to a flattening of the latter, where the pelvis will try to compensate through pelvic retroversion and verticalization of the sacrum (increased PT and decrease in SS) to maintain an upright posture, to the physiological point that his/her PI allows. In this situation the patient has a compensated imbalance (Fig. 12). Faced with the imbalance between the PI and LL and reaching the physiological limits of the different compensatory mechanisms, the progressive

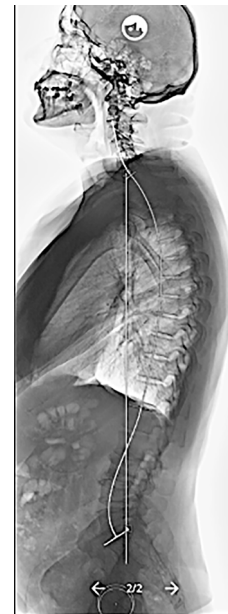

Fig. 11 Balanced patient: PI of 35° and LL of 44° , with an adequate relationship between these ($35-44 = -9^\circ$) and a neutral SVA with a TPA of 2° , without compensatory mechanisms, PT = 2° and SS = 33° ($35^\circ = 2^\circ + 33^\circ$).

Note. PI, pelvic incidence; LL, lumbar lordosis; SVA, sacral vertical axis; TPA, T1-pelvic angle; PT, pelvic tilt.

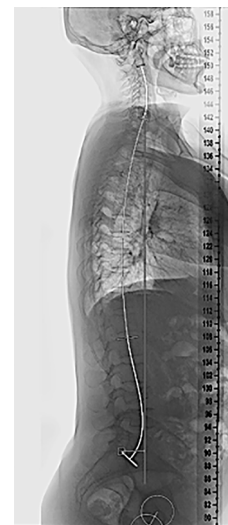


Fig. 12 Compensated imbalance patient: PI of 62° and a LL of 50° , showing an alteration between the relationship of these ($62-50 = 12^\circ$) with a slightly altered TPA of 18° , but with an SVA within normal limits (43 mm), at the expense of compensatory mechanisms such as pelvic retroversion (PT = 21°) and verticalization of the sacrum (SS = 41°). Patients with a high PI have a great capacity for pelvic compensation ($62^\circ = 21^\circ + 41^\circ$), which will allow you to increase PT even more.

Note. PI, pelvic incidence; LL, lumbar lordosis; TPA, T1-pelvic angle; SVA, sacral vertical axis; PT, pelvic tilt; SS, sacral slope.

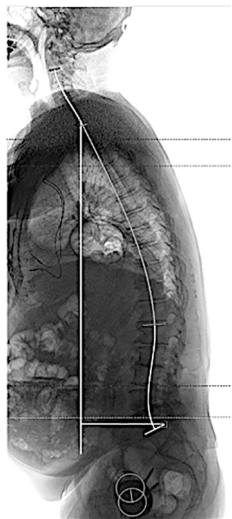

Fig. 13 Decompensated imbalanced patient: PI of 46° and LL of 22° with severe alteration between them ($46 - 22^\circ = 24^\circ$) and an elevated SVA and TPA (130 mm and 27°, respectively) when reaching the physiological limits of pelvic retroversion (PT: 19°) and sacral verticalization (SS: 27°) for his PI ($46^\circ = 19^\circ + 27^\circ$).

Note. PI, pelvic incidence; LL, lumbar lordosis; TPA, T1-pelvic angle; SVA, sacral vertical axis; PT, pelvic tilt; SS, sacral slope.

anterior translation of the plumb line (C7PL) is generated away from the pelvis, exhibited by an increased SVA and resulting with the patient in a decompensated imbalance situation (Fig. 13).

PI by itself is a measurement that provides little information. However, it is considered the key to SB. Faced with the scenario of an adult deformity, where the RP are altered, this is the only one that does not vary, being the point of reference for the categorization of the rest of the RP. As it is a unique value for each patient, it allows determination of the type of sagittal profile according to Roussouly, making it possible, in cases where it is altered by degenerative pathology, to identify the ‘theoretical sagittal shape’ of the patient, guiding where and how much lordosis is necessary to restore with surgery in order to match this theoretical form,⁴³ which could lead to better functional results and fewer mechanical complications.^{11,21,44–47} As Roussouly states, ‘in case of pathology, the PI is the only signature we have to determine the original shape of the spine and restore the balance of the patient’.²¹

A lack of surgical correction of SI has been associated with poor clinical outcomes, as well as an increased risk of biomechanical complications.^{40,47} In this sense, the ‘SRS-Schwab’ classification establishes objective values (PI-LL < 10°, PT < 20° and SVA < 4 cm) to achieve favourable clinical outcomes,³³ while ‘The global alignment and proportion’ (GAP) score, establishes a scoring system for predicting postoperative biomechanical complications, making the understanding of the SI, through RP, gain

additional relevance when facing and surgical planning of a patient with a spinal deformity.

Understanding these parameters allows us to group patients into three categories:

- Balanced
- Compensated imbalance
- Decompensated imbalance

In the case that a balanced patient presents spinal pathology, corrections are not required. In compensated imbalance patients, focal treatment of their symptoms is prioritized, since this situation is preferable to a patient with an adequate SB, at the expense of extensive surgery with long instrumentations.^{48–50} Otherwise, in decompensated imbalance spines, extensive corrective surgeries will be required, since their fixation in situ maintains abnormal loads and represents a great risk of future failure of instrumentation, with possible serious consequences for the patient. All these concepts must be analysed in conjunction with the coronal plane and in the context of the patient, age, comorbidities and, above all, expectations, since they are not without complications.

Conclusion

SB is a dynamic process that involves energy expenditure. As physiological ageing occurs, this balanced condition can be lost, resulting in increased energy expenditure that produces pain and disability.

In the evaluation of the radiographs, there are multiple RPs that help the analysis of the sagittal balance, the SVA, TPA, LL, PT, SS and PI being the most frequently used. The latter is of vital importance as it is a morphological parameter that influences the others and serves as a reference under SI conditions.

The RP described help us to discriminate between balanced, imbalance but compensated or imbalanced decompensated patients, which guides both diagnosis and therapeutic decision-making. It is important to reinforce that the radiographic analysis should be carried out in both planes (coronal and sagittal), complementing the clinical evaluation.

AUTHOR INFORMATION

¹Clínica Universidad de los Andes, Santiago, Chile.

²Hospital del Trabajador, Santiago, Chile.

³Hospital Roberto del Río, Santiago, Chile.

⁴Clínica Universidad de los Andes, Santiago, Chile.

Correspondence should be sent to: Facundo L. Alvarez-Lemos, Los Trigales 7887, Dep: 509. Region Metropolitana, Las Condes, Santiago, Chile.

Email: facundoalemos@gmail.com

ICMJE CONFLICT OF INTEREST STATEMENT

The authors declare no conflict of interest relevant to this work.

FUNDING STATEMENT

No benefits in any form have been received or will be received from a commercial party related directly or indirectly to the subject of this article.

OPEN ACCESS

© 2021 The author(s)

This article is distributed under the terms of the Creative Commons Attribution-Non Commercial 4.0 International (CC BY-NC 4.0) licence (<https://creativecommons.org/licenses/by-nc/4.0/>) which permits non-commercial use, reproduction and distribution of the work without further permission provided the original work is attributed.

REFERENCES

- Dubouset J.** Three-dimensional analysis of the scoliotic deformity. In: Weinstein S, ed. *The pediatric spine: principles and practice*. New York: Raven Press, 1994:479–496.
- Bess S, Line B, Fu KM, McCarthy I, Lafage V, Schwab F, et al.** The health impact of symptomatic adult spinal deformity: comparison of deformity types to United States population norms and chronic diseases. *Spine (Phila PA 1976)* 2016;41:224–233.
- Cobb J.** *Outline for the study of scoliosis*. American Academy of Orthopaedic Surgeons. Instructional Course Lectures, Vol. 5. 1948;5:261–275
- Roussouly P, Gollogly S, Berthonnaud E, Dimnet J.** Classification of the normal variation in the sagittal alignment of the human lumbar spine and pelvis in the standing position. *Spine* 2005;30:346–353.
- Le Huec JC, Hasegawa K.** Normative values for the spine shape parameters using 3D standing analysis from a database of 268 asymptomatic Caucasian and Japanese subjects. *Eur Spine J* 2016;25:3630–3637.
- Legaye J, Duval-Beaupère G, Hecquet J, Marty C.** Pelvic incidence: a fundamental pelvic parameter for three-dimensional regulation of spinal sagittal curves. *Eur Spine J* 1998;7:99–103.
- Duval-Beaupère G, Schmidt C, Cosson P.** A Barycentremetric study of the sagittal shape of spine and pelvis: the conditions required for an economic standing position. *Ann Biomed Eng* 1992;20:451–462.
- Vialle R, Levassor N, Rillardon L, Templier A, Skalli W, Guigui P.** Radiographic analysis of the sagittal alignment and balance of the spine in asymptomatic subjects. *J Bone Joint Surg [Am]* 2005;87-A:260–267.
- Kozanek M, Wang S, Passias PG, et al.** Range of motion and orientation of the lumbar facet joints in vivo. *Spine* 2009;34:E689–E696.
- Boseker EH, Moe JH, Winter RB, Koop SE.** Determination of ‘normal’ thoracic kyphosis: a roentgenographic study of 121 ‘normal’ children. *J Pediatr Orthop* 2000;20:796–798.
- Roussouly P, Nnadi C.** Sagittal plane deformity: an overview of interpretation and management. *Eur Spine J* 2010;19:1824–1836.
- Schwab FJ, Patel A, Ungar B, Farcy JP, Lafage V.** Adult spinal deformity: postoperative standing imbalance. How much can you tolerate? An overview of key parameters in assessing alignment and planning corrective surgery. *Spine* 2010;35:2224–2231.
- Schwab FJ, Lafage R, Liabaud BB, et al.** Does one size fit all? Defining spinopelvic alignment thresholds based on age. *Spine J* 2014;14:S120–S121.
- Lafage R, Schwab F, Challier V, et al; International Spine Study Group.** Defining spino-pelvic alignment thresholds: should operative goals in adult spinal deformity surgery account for age? *Spine* 2016;41:62–68.
- Le Huec JC, Thompson W, Mohsinaly Y, Barrey C, Faundez A.** Sagittal balance of the spine. *Eur Spine J* 2019;28:1889–1905.
- Schwab FJ, Diebo BG, Smith JS, et al.** Fine-tuned surgical planning in adult spinal deformity: determining the lumbar lordosis necessary by accounting for both thoracic kyphosis and pelvic incidence. *Spine J* 2014;14:S73.
- Lim JK, Kim SM.** Comparison of sagittal spinopelvic alignment between lumbar degenerative spondylolisthesis and degenerative spinal stenosis. *J Korean Neurosurg Soc* 2014;55:331–336.
- Obeid I, Boissière L, Yilgor C, et al; European Spine Study Group, ESSG.** Global tilt: a single parameter incorporating spinal and pelvic sagittal parameters and least affected by patient positioning. *Eur Spine J* 2016;25:3644–3649.
- Roussouly P, Berthonnaud E, Dimnet J.** [Geometrical and mechanical analysis of lumbar lordosis in an asymptomatic population: proposed classification]. *Rev Chir Orthop Repar Appar Mot* 2003;89:632–639.
- Roussouly P, Gollogly S, Berthonnaud E, Dimnet J.** Classification of the normal variation in the sagittal alignment of the human lumbar spine and pelvis in the standing position. *Spine* 2005;30:346–353.
- Roussouly P, Pinheiro-Franco JL.** Biomechanical analysis of the spino-pelvic organization and adaptation in pathology. *Eur Spine J* 2011;20:609–618.
- Barrey C, Jund J, Nosedo O, Roussouly P.** Sagittal balance of the pelvis-spine complex and lumbar degenerative diseases: a comparative study about 85 cases. *Eur Spine J* 2007;16:1459–1467.
- Pesenti S, Lafage R, Stein D, et al.** The amount of proximal lumbar lordosis is related to pelvic incidence. *Clin Orthop Relat Res* 2018;476:1603–1611.
- Battié MC, Videman T, Parent E.** Lumbar disc degeneration: epidemiology and genetic influences. *Spine* 2004;29:2679–2690.
- Smith JS, Shaffrey CI, Lafage V, et al; International Spine Study Group.** Spontaneous improvement of cervical alignment after correction of global sagittal balance following pedicle subtraction osteotomy. *J Neurosurg Spine* 2012;17:300–307.
- Barrey C, Roussouly P, Le Huec J-C, D’Acunzi G, Perrin G.** Compensatory mechanisms contributing to keep the sagittal balance of the spine. *Eur Spine J* 2013;22:S834–S841.
- Aurouer N, Obeid I, Gille O, Pointillart V, Vital J-M.** Computerized preoperative planning for correction of sagittal deformity of the spine. *Surg Radiol Anat* 2009;31:781–792.
- Vanneuville G, Garcier JM, Poumarat G, Guillot M, Chazal J.** Mechanisms of orientation of the pelvifemoral base during static loading of the lumbar spine in weight-lifters. *Surg Radiol Anat* 1992;14:29–33.
- Legaye J, Duval-Beaupère G.** Sagittal plane alignment of the spine and gravity: a radiological and clinical evaluation. *Acta Orthop Belg* 2005;71:213–220.
- Obeid I, Hauger O, Aunoble S, Bourghli A, Pellet N, Vital J-M.** Global analysis of sagittal spinal alignment in major deformities: correlation between lack of lumbar lordosis and flexion of the knee. *Eur Spine J* 2011;20:681–685.
- Diebo BG, Ferrero E, Lafage R, et al.** Recruitment of compensatory mechanisms in sagittal spinal malalignment is age and regional deformity dependent: a full-standing axis analysis of key radiographical parameters. *Spine* 2015;40:642–649.
- Lafage V, Schwab F, Patel A, Hawkinson N, Farcy JP.** Pelvic tilt and truncal inclination: two key radiographic parameters in the setting of adults with spinal deformity. *Spine* 2009;34:E599–E606.
- Schwab F, Ungar B, Blondel B, et al.** Scoliosis Research Society-Schwab adult spinal deformity classification: a validation study. *Spine* 2012;37:1077–1082.

- 34. Smith JS, Klineberg E, Schwab F, et al; International Spine Study Group.** Change in classification grade by the SRS-Schwab Adult Spinal Deformity Classification predicts impact on health-related quality of life measures: prospective analysis of operative and nonoperative treatment. *Spine* 2013;38:1663–1671.
- 35. Glassman SD, Bridwell K, Dimar JR, Horton W, Berven S, Schwab F.** The impact of positive sagittal balance in adult spinal deformity. *Spine* 2005;30:2024–2029.
- 36. Lazennec JY, Ramaré S, Arafati N, et al.** Sagittal alignment in lumbosacral fusion: relations between radiological parameters and pain. *Eur Spine J* 2000;9:47–55.
- 37. Schwab FJ, Blondel B, Bess S, et al; International Spine Study Group (ISSG).** Radiographical spinopelvic parameters and disability in the setting of adult spinal deformity: a prospective multicenter analysis. *Spine* 2013;38:E803–E812.
- 38. Ha KY, Jang WH, Kim YH, Park DC.** Clinical relevance of the SRS-Schwab Classification for degenerative lumbar scoliosis. *Spine* 2016;41:E282–E288.
- 39. Chapman TM Jr, Baldus CR, Lurie JD, et al.** Baseline patient-reported outcomes correlate weakly with radiographic parameters: a multicenter, prospective NIH adult symptomatic lumbar scoliosis study of 286 patients. *Spine* 2016;41:1701–1708.
- 40. Faraj SSA, De Kleuver M, Vila-Casademunt A, et al.** Sagittal radiographic parameters demonstrate weak correlations with pretreatment patient-reported health-related quality of life measures in symptomatic de novo degenerative lumbar scoliosis: a European multicenter analysis. *J Neurosurg Spine* 2018;28:573–580.
- 41. Takemoto M, Boissière L, Vital JM, et al.** Are sagittal spinopelvic radiographic parameters significantly associated with quality of life of adult spinal deformity patients? Multivariate linear regression analyses for pre-operative and short-term post-operative health-related quality of life. *Eur Spine J* 2017;26:2176–2186.
- 42. Boissière L, Takemoto M, Bourghli A, et al; European Spine Study Group (ESSG).** Global tilt and lumbar lordosis index: two parameters correlating with health-related quality of life scores—but how do they truly impact disability? *Spine J* 2017;17:480–488.
- 43. Pizones J, Martin MB, Perez-Gruoso FJS, et al; ESSG European Spine Study Group.** Impact of adult scoliosis on Roussouly sagittal shape classification. *Spine* 2019;44:270–279.
- 44. Scemama C, Laouissat F, Abelin-Genevois K, Roussouly P.** Surgical treatment of thoraco-lumbar kyphosis (TLK) associated with low pelvic incidence. *Eur Spine J* 2017;26:2146–2152.
- 45. Yilgor C, Sogunmez N, Boissiere L, et al; European Spine Study Group (ESSG).** Global Alignment and Proportion (GAP) score: development and validation of a new method of analyzing spinopelvic alignment to predict mechanical complications after adult spinal deformity surgery. *J Bone Joint Surg [Am]* 2017;99-A:1661–1672.
- 46. Barrey C, Darnis A.** Current strategies for the restoration of adequate lordosis during lumbar fusion. *World J Orthop* 2015;6:117–126.
- 47. Soroceanu A, Diebo BG, Burton D, et al; International Spine Study Group.** Radiographical and implant-related complications in adult spinal deformity surgery: incidence, patient risk factors, and impact on health-related quality of life. *Spine* 2015;40:1414–1421.
- 48. Le Huec JC, Leijssen P, Duarte M, Aunoble S.** Thoracolumbar imbalance analysis for osteotomy planification using a new method: FBI technique. *Eur Spine J* 2011;20:669–680.
- 49. Kim Y-C, Lenke LG, Lee S-J, Gum JL, Wilartatsami S, Blanke KM.** The cranial sagittal vertical axis (CrSVA) is a better radiographic measure to predict clinical outcomes in adult spinal deformity surgery than the C7 SVA: a monocentric study. *Eur Spine J* 2017;26:2167–2175.
- 50. Diebo BG, Henry J, Lafage V, Berjano P.** Sagittal deformities of the spine: factors influencing the outcomes and complications. *Eur Spine J* 2015;24:S3–S15.
- 51. Schwab F, Lafage V, Boyce R, Skalli W, Farcy JP.** Gravity line analysis in adult volunteers: age-related correlation with spinal parameters, pelvic parameters, and foot position. *Spine* 2006;31:E959–E967.
- 52. Boulay C, Tardieu C, Hecquet J, et al.** Sagittal alignment of spine and pelvis regulated by pelvic incidence: standard values and prediction of lordosis. *Eur Spine J* 2006;15:415–422.
- 53. Roussouly P, Gollogly S, Nosedo O, Berthonnaud E, Dimnet J.** The vertical projection of the sum of the ground reactive forces of a standing patient is not the same as the C7 plumb line: a radiographic study of the sagittal alignment of 153 asymptomatic volunteers. *Spine* 2006;31:E320–E325.
- 54. Berthonnaud E, Dimnet J, Roussouly P, Labelle H.** Analysis of the sagittal balance of the spine and pelvis using shape and orientation parameters. *J Spinal Disord Tech* 2005;18:40–47.
- 55. Protosaltis T, Schwab F, Bronsard N, et al; International Spine Study Group.** The T1 pelvic angle, a novel radiographic measure of global sagittal deformity, accounts for both spinal inclination and pelvic tilt and correlates with health-related quality of life. *J Bone Joint Surg [Am]* 2014;96-A:1631–1640.