



ENDURAGen graft durability in α -Gal disease

Kelly L. Ruland^{*}, Maria Kirzhner

Department of Ophthalmology, University of Virginia, Charlottesville, VA, 1300 Jefferson Park Avenue, Charlottesville, VA, 22903, USA

ARTICLE INFO

Keywords:

Oculoplastic surgery
Eyelid reconstruction
ENDURAGen
Biosynthetic soft tissue graft
 α -Gal disease
Allergy

ABSTRACT

Purpose: We present a case of eyelid reconstruction using ENDURAGen, a porcine-derived acellular collagen graft, complicated by dissolution of the graft in a patient recently diagnosed with α -Gal disease.

Observations: A 33-year-old female status post enucleation of the left eye at age 7 struggling with malposition of her prosthesis due to lower lid retraction and laxity underwent eyelid reconstruction with ENDURAGen. She did well post-operatively for 9 months, but then began having issues with prosthesis dislodgement and rotation. Around that time, the patient was diagnosed with α -Gal disease. Repeat eyelid reconstruction was performed, this time with an ear cartilage graft, and dissolution of the original ENDURAGen graft was confirmed.

Conclusions and importance: This case highlights the need for evaluation of the durability of ENDURAGen in patients with α -Gal and for caution in choosing porcine or bovine-derived implants for tissue reconstruction in this population.

1. Introduction

ENDURAGen is an acellular cross-linked porcine dermal collagen implant used in head and neck soft tissue reconstruction when there is limited availability of autologous tissue.¹ Dermal matrix grafts, including ENDURAGen specifically, have been shown histologically to experience fibroblast infiltration, neovascularization, and epithelialization with low antigenicity.^{2,3} A review of 15 papers evaluating the utility and safety of bioengineered acellular dermal matrix grafts concluded that these grafts are a safe option for eyelid reconstruction after 12 months of follow-up.⁴ A review of complications of upper and lower eyelid reconstruction using ENDURAGen found that it is an appropriate alternative to autologous grafts.¹ Additionally, analysis of gross and microscopic changes to graft matrices over 12 months in vivo in animal models has shown durability of ENDURAGen compared to similar products.² We present a case of eyelid reconstruction using ENDURAGen complicated by complete graft dissolution after 9 months in a patient with a recently diagnosed allergy to galactose- α -(1, 3)-galactose (α -Gal), calling into question the durability of porcine-derived implants in patients with α -Gal disease, the “red meat allergy.”

2. Case

A 33-year-old female status post enucleation of the left eye at age 7

for complex ruptured globe presented with frequent dislodgement and rotation of her prosthesis in the eye socket. On examination she had lower eyelid retraction and mild laxity (Fig. 1). She underwent uncomplicated left lower lid ectropion and retraction repair using ENDURAGen as a spacer graft. Post-operatively, she had appropriate eyelid position and a secure prosthesis (Fig. 2a). In 9 months, she returned with recurrence of symptoms and return of lower eyelid retraction (Fig. 2b). Patient reported she woke up one morning to find her “graft was gone.” Two weeks later, she presented to her family practitioner with diarrhea and rash over her neck, face, abdomen, and extremities starting a few hours after eating red meat. Work-up confirmed elevated levels of α -Gal-specific IgE. She returned to the operating room for left lower eyelid retraction repair with ear cartilage graft. During the repair, complete dissolution of the ENDURAGen graft was noted.

3. Discussion

α -Gal is a component of mammalian glycan structure, absent in primates. Anti- α -Gal IgE antibodies were first isolated during evaluation of anaphylactic reactions to cetuximab, a chimeric mouse-human IgG monoclonal antibody against epidermal growth factor receptor used in cancer treatment.⁵ Based on the observation that geographic distribution of tick-borne illnesses matched that of anaphylaxis to cetuximab, Commins et al. measured serum anti-alpha-gal IgE levels in patients with

^{*} Corresponding author. Department of Ophthalmology, University of Virginia, PO Box 800715 Charlottesville, VA, 22908-0715, USA.
E-mail address: kelly.ruland@vumc.org (K.L. Ruland).

prior tick exposures in Virginia, North Carolina, and Tennessee, concluding that sensitization to α -Gal is the result of a tick bite, namely *Amblyomma americanum* (the lone star tick).⁶

In contrast to rapid-onset anaphylactic reactions occurring within 30 minutes of parenteral cetuximab exposure, patients with known α -Gal sensitization show a delayed hypersensitivity reaction (3–6 hours) after red meat consumption.^{5,6} Wilson et al. hypothesize that the digestion of α -Gal, a glycolipid, results in a Th2-driven reaction resulting from sensitized IgE causing delayed basophil activation.⁷ Hilger et al. citing evidence that parasitic infection stimulates a Th2 response by basophil accumulation and production of interleukin-4,⁹ suggest that the tick bite itself stimulates a Th2, allergic-type immune response.⁵

Diagnosis of α -Gal syndrome is made based on presence of allergic symptoms in response to mammalian meat exposure in combination with confirmed elevation of anti- α -Gal IgE levels. Commins et al. suggest that up to 20% of the population in the southeastern United States where tick bites are prevalent could have elevated anti- α -Gal IgE.⁶ Meanwhile, it is approximated that 3% of the population has α -Gal syndrome.⁸ The degree of antibody elevation has not been shown to correlate with severity of symptoms, and sensitization does not denote α -Gal syndrome.⁵ Occurrence of symptoms depends on the amount of α -Gal present in the food source, as well as patient-dependent factors such as level of physical activity, use of alcohol, presence of infection, and use of non-steroidal anti-inflammatories.⁵ Emphasizing the importance of the basophil response in this immune reaction, Mehlich et al. suggest performing a basophil activation test in sensitized patients to determine the response at different allergen concentrations as an important step in diagnosis and management of the disease.¹⁰

Assessing the risk of anaphylaxis from α -Gal sources other than mammalian meat, Swiontek et al. evaluated the allergenicity of Creon (porcine-derived pancreatic enzymes) and Enzynorm f (bovine-derived pepsin). Skin testing was performed on subjects with α -Gal disease compared with controls and confirmed reactivity in patients also reactive to mammalian meat.¹¹ Further, cases of hypersensitivity to prosthetic cardiac valves of bovine and porcine origin have been reported. Mozzicato et al. described 3 cases of allergic reaction in the perioperative period of valve replacement in patients with α -Gal disease. While one resulted from administration of heparin (also bovine or porcine-derived), the remaining 2 patients required treatment for anaphylaxis intraoperatively or immediately post-operatively from bioprosthetic valve replacement.¹²

Regarding longevity of bovine and porcine valve implants in humans, Konakci et al. describe premature degeneration of valves as compared to mechanical valves caused by an anti- α -Gal IgM-driven immune response leading to recruitment of macrophages, collagen breakdown, and calcification.¹³ Hawkins et al. reported 2 cases of premature bioprosthetic heart valve degeneration in patients with α -Gal. Patients tolerated valves without serious complication for several years prior to α -Gal sensitization. Within two years of diagnosis, patients developed symptomatic valve failure requiring replacement with mechanical valve. Authors hypothesize that failure resulted from immune-mediated degeneration as described by Konakci, proposing that an accelerated process occurred in patients with known alpha-Gal sensitivity and elevated IgE levels.^{13,14}

Bloch et al. showed that even glutaraldehyde treated xenografts carried residual cells with the α -Gal epitope, stimulating production of IgM and IgG. However, there was no immune response noted to porcine collagen I; tissue-engineered, “decellularized” grafts did not stimulate the immune response hypothesized to cause valve calcification and degeneration.¹⁵

Allman et al. evaluated the immune response to porcine small intestinal submucosa, an acellular extracellular matrix (ECM) graft used in tissue reconstruction. By looking at histopathologic evidence of rejection at the graft site, as well as cytokine levels associated with the grafts, they proved that immune reaction to acellular ECM is a Th2 response causing tissue “remodeling.” Histologic analysis at varying time points after implantation showed initial acute inflammation with polymononuclear cells, followed by an infiltration of macrophages by day 10. By day 28, the implant was noted to have an organized fibroblast proliferation, which authors concluded represented acceptance of the implant. Cytokine mRNA analysis showed high levels of interleukin-4 expression and low levels of interferon-gamma in the graft, indicating a strongly Th2 response.¹⁶ Interleukin-4 drives differentiation of macrophages to the M2 phenotype over the M1. M2 macrophages play a major role in wound repair, driving debris clean-up, remodeling, and angiogenesis. In a review of several reports looking at chemoattraction of multipotential progenitor cells to the sites of ECM scaffold implants, Badylak et al. hypothesize that degradation of the ECM itself helps drive the tissue remodeling and the healing process.¹⁷

Xenogeneic medications and bioprosthetic cardiac valves have been reported to cause hypersensitivity reactions in patients with α -Gal disease, and early failure of prosthetic heart valves has been attributed to

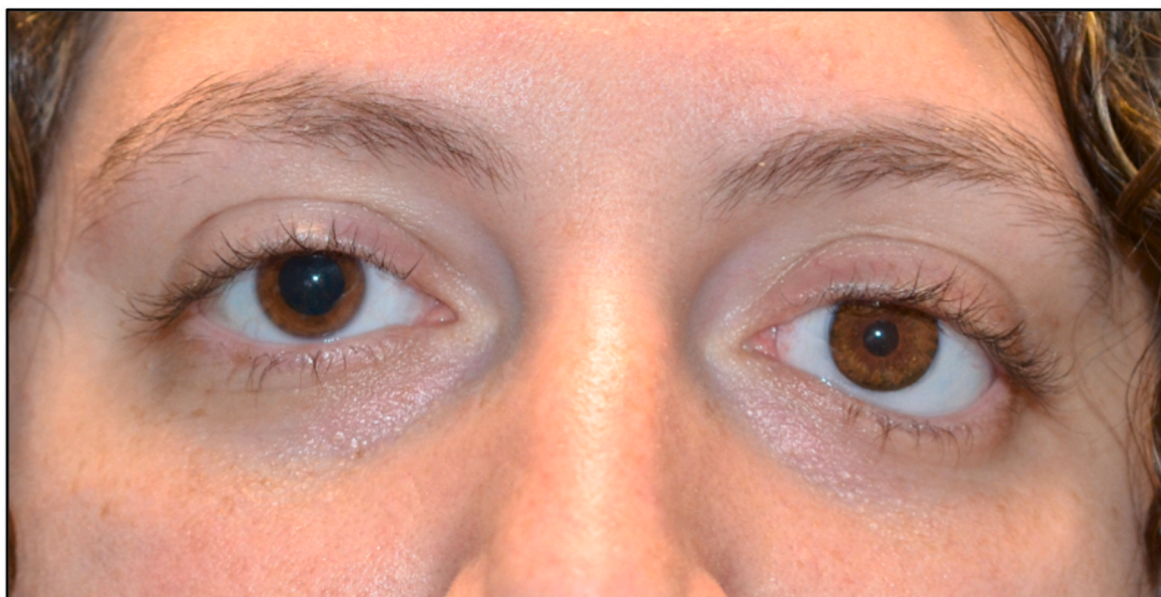


Fig. 1. Pre-operative photograph showing a patient with anophthalmic left socket with prosthesis in place. There is left lower eyelid ectropion with lateral retraction.

immune-mediated destruction in α -Gal sensitized patients. While current literature lacks long-term data on the durability of dermal matrix grafts in eyelid reconstruction,²⁻⁴ we suggest that the sudden dissolution of an ENDURAGen implant in our patient was the result of an immune reaction related to the development of α -Gal disease. ENDURAGen is an acellular collagen matrix unlikely to contain the α -Gal epitope, therefore it is postulated that graft failure in this patient was not caused by an immunoglobulin response as suggested in cases of xenogeneic heart valve failure. α -Gal disease has been shown to correspond with increased basophil activation and production of interleukin-4, an allergic immune response, the same process which allows for wound healing and tissue remodeling in ECM graft placement instead of graft rejection. We propose that the dissolution of our patient's eyelid graft, which coincided with the development of a red meat allergy, occurred because of an amplified Th2 immune response associated with α -Gal sensitization, driving ECM degradation and tissue remodeling of the eyelid reconstruction site.

4. Conclusion

To our knowledge, this is the first reported case of degeneration of an acellular dermal matrix graft in a patient with α -Gal disease. Our case of ENDURAGen failure highlights the need for evaluation of the durability of such products used for eyelid reconstruction in patients with α -Gal and for pre-operative allergy testing in high-risk populations, including patients with sensitivity to red meat or patients with known tick exposure, before choosing porcine or bovine-derived implants for tissue reconstruction.

Patient consent

The patient consented to publication of this case orally and in writing.

Conflict of interest

No conflict of interest exists.

Funding

No funding was received for this work.

Intellectual Property

We confirm that we have given due consideration to the protection of intellectual property associated with this work and that there are no impediments to publication, including the timing of publication, with respect to intellectual property. In so doing we confirm that we have followed the regulations of our institutions concerning intellectual property.

Research ethics

We further confirm that any aspect of the work covered in this manuscript that has involved human patients has been conducted with the ethical approval of all relevant bodies and that such approvals are acknowledged within the manuscript.

IRB approval was obtained (required for studies and series of 3 or more cases)-N/A.

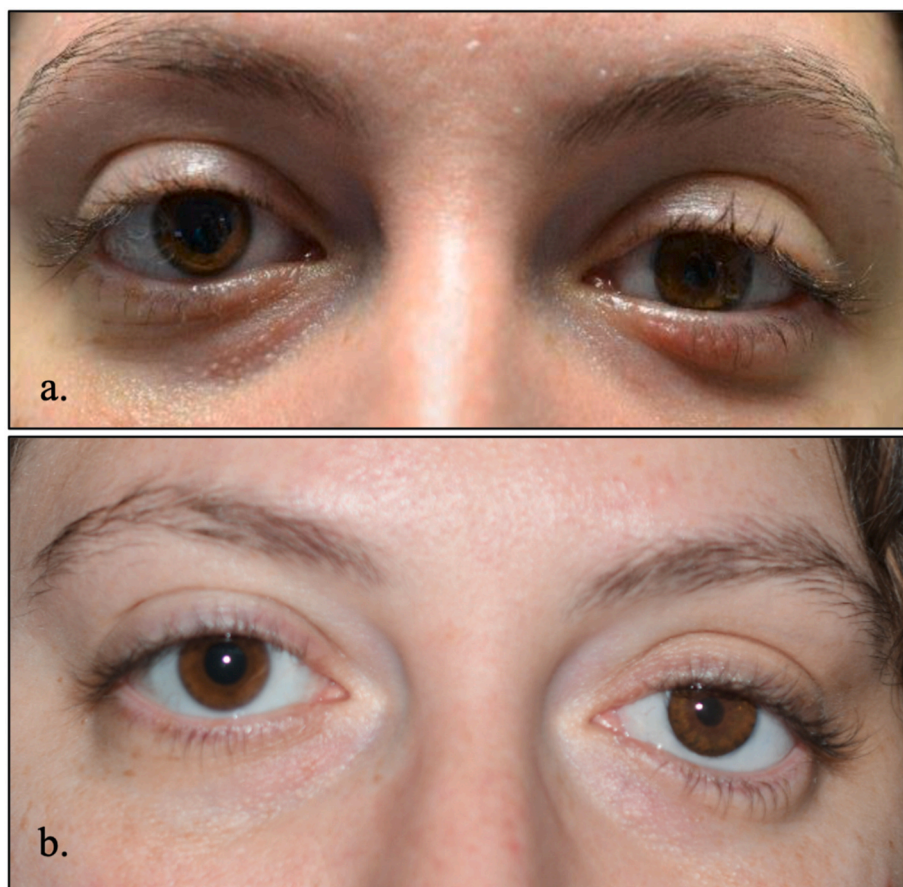

Fig. 2. Post-operative photographs of the same patient (a) at 1 month, showing improved left lower lid position, and (b) at 10 months, showing recurrence of lateral retraction of the left lower lid.

Written consent to publish potentially identifying information, such as details or the case and photographs, was obtained from the patient(s) or their legal guardian(s).

Acknowledgments

No funding or grant support, The following authors have no financial disclosures: KLR and MK All authors attest that they meet the current ICMJE criteria for Authorship, There are no other contributors to the printed work.

References

- McCord C, Nahai F, Codner M, Nahai F, Hester T. Use of porcine acellular dermal matrix (Enduragen) grafts in eyelids: a review of 69 patients and 129 eyelids. *Plast Reconstr Surg*. 2008;122(4):1206–1213.
- Wainwright D, Madden M, Luteran A, et al. Clinical evaluation of an acellular allograft dermal matrix in fullthickness burns. *J Burn Care Rehabil*. 1996;17:124–136.
- Cole PD, Stal D, Sharabi SE, Hicks J, Hollier Jr LH. A comparative, long-term assessment of four soft tissue substitutes. *Aesthetic Surg J*. 2011;31(6):674–681.
- Tao JP, Aakalu VK, Wladis EJ, et al. Bioengineered acellular dermal matrix spacer grafts for lower eyelid retraction repair: a report by the American academy of ophthalmology. *Ophthalmology*. 2020 May;127(5):689–695.
- Hilger C, Fischer J, Wolbing F, Biedermann T. Role and mechanism of galactose-alpha-1,3-galactose in the Elicitation of delayed anaphylactic reactions to red meat. *Curr Allergy Asthma Rep*. 2019;19(3):1–11.
- Commins SP, James HR, Kelly LA, et al. The relevance of tick bites to the production of IgE antibodies to the mammalian oligosaccharide galactose- α -1,3-galactose. *J Allergy Clin Immunol*. 2011 May;127(5):1286–1293.
- Wilson JM, Platts-Mills TAE. The oligosaccharide galactose- α -1,3-galactose and the -gal syndrome: insights from an epitope that is causal in immunoglobulin E-mediated immediate and delayed anaphylaxis. *EMJ Allergy Immunol*. 2018;3:89–98.
- Sharma SR, Karim S. Tick saliva and the alpha-gal syndrome: finding a needle in a haystack. *Front Cell Infect Microbiol*. 2021;11:1–13.
- Min B, Prout M, Hu-Li J, et al. Basophils produce IL-4 and accumulate in tissues after infection with a Th2-inducing parasite. *J Exp Med*. 2004;200:507–517.
- Mehlich J, Fischer J, Hilger C, et al. The basophil activation test differentiates between patients with alpha-gal syndrome and asymptomatic alpha-gal sensitization. *J Allergy Clin Immunol*. 2019 Jan;143(1):182–189.
- Swiontek K, Morisset M, Codreanu-Morel F, et al. Drugs of Porcine Origin- A risk for patients with α -gal syndrome? *J Allergy Clin Immunol Pract*. 2019;7(5):1687–1690.
- Mozzicato S, Tripathi A, Posthumus JB, Platts-Mills TAE, Commins SP. Porcine or bovine valve replacement in three patients with IgE antibodies to the mammalian oligosaccharide galactose alpha-1,3-galactose. *J Allergy Clin Immunol Pract*. 2014;2(5):637–638.
- Konakci KZ, Bohle B, Blumer R, et al. Alpha-gal on bioprostheses: xenograft immune response in cardiac surgery. *Eur J Clin Invest*. 2005;35(1):17–23.
- Hawkins RB, Frischtak HL, Kron IL, Ghanta RK. Premature bioprosthetic aortic valve degeneration associated with allergy to galactose-alpha-1,3-galactose. *J Card Surg*. 2016;31(7):446–448.
- Bloch O, Golde P, Dohmen PM, Posner S, Konertz W, Erdbrugger W. Immune response in patients receiving a bioprosthetic heart valve: lack of response with decellularized valves. *Tissue Eng*. 2011;17(19-20):2399–2405.
- Allman AJ, McPherson TB, Badylak SF, et al. Xenogeneic extracellular matrix grafts elicit a TH2-restricted immune response. *Transplantation*. 2001 Jun 15;71(11):1631–1640.
- Badylak SF, Gilbert TW. Immune response to biologic scaffold materials. *Semin Immunol*. 2008;20(2):109–116.