

# Single-Fiber Laser Ablation in Treating Selected Metastatic Lymph Nodes of Papillary Thyroid Carcinoma and Benign Cold Thyroid Nodules—Preliminary Results

YuQing Guo, ZhiXian Li,\* SiDa Wang, XianShan Liao, and Chen Li

Department of Ultrasound Diagnosis, The First Affiliated Hospital of Guangxi Medical University, No. 6, Shuangyong Road, NanNing, P.R. China

**Background and Objectives:** To evaluate the feasibility and efficacy of single-fiber laser ablation (LA) under ultrasound guidance and appropriate ablation modes in the treatment of selected metastatic lymph nodes of papillary thyroid carcinoma (PTC) and benign cold thyroid nodules

**Study Design/Materials and Methods:** A total of 18 patients (consisting of 8 patients with 18 metastatic lymph nodes of PTC and 10 patients with 10 benign cold thyroid nodules) each underwent one session of single-fiber LA under ultrasound guidance. On the basis of the sizes of the nodules, the ablation modes were chosen accordingly. The single-dot ablation mode was used in the nodules with three orthogonal diameters measuring no greater than 10 mm in diameter, with a dot, a level and an insertion. The double-dots overlapping ablation mode was used in the nodules with the largest diameters measuring greater than 10 mm (in which the nodules measured no more than 15 mm in diameter and with the other two perpendicular diameters measuring no greater than 10 mm in diameter) with two dots, a level and two insertions. The multiple levels and dots overlapping ablation mode was used in the nodules with the three orthogonal diameters all measuring larger than 10 mm, with multiple dots, levels and insertions.

**Results:** After 12 months of follow-up in the treated nodules of the metastatic lymph nodes of PTC and benign cold thyroid nodules, the mean baseline volumes decreased from  $0.29 \pm 0.12$  to  $0.03 \pm 0.03$  ml and  $3.85 \pm 0.64$  to  $1.1 \pm 0.37$  ml, respectively, and the mean volume reduction ratios (VRRs), which was calculated as  $\{[(\text{initial volume} - \text{final volume}) \times 100\%] / \text{initial volume}\}$ , were  $90.3 \pm 7.6\%$  and  $72 \pm 5.8\%$ , respectively. There were six ablative zones that completely disappeared, whereas the ablative zones that still existed presented as scar-like areas or small hyperechoic areas that were compatible with scar tissue among the 18 malignant nodules at the last follow-up.

**Conclusions:** Single-fiber LA under ultrasound guidance, with the appropriate ablation modes, is feasible and effective for the treatment of selected metastatic lymph nodes of PTC and benign cold thyroid nodules. This study suggests that single-fiber LA may be applied to selected cases with appropriate ablation modes. *Lasers Surg. Med.* 2019 © 2019 Wiley Periodicals, Inc.

**Key words:** single-fiber laser ablation; ultrasound guidance; metastatic lymph nodes; papillary thyroid carcinoma; benign cold thyroid nodules

## INTRODUCTION

Thyroid nodules are common clinical problems that are detected in up to 50–60% of healthy people, with thyroid cancer occurring in 7–15% of those individuals [1,2]. In all of the thyroid cancer subtypes, papillary thyroid carcinomas (PTCs) comprise the vast majority of the subtypes. Although the standard treatment for PTC is based on surgery followed by radioiodine treatment, 20–59% of the cases may encounter local recurrences and metastatic lymph nodes after surgery, whereas resection procedures may be burdened by higher risks of complications and morbidities due to scar formation [1,3–5]. Patients with benign thyroid nodules may also require treatments for spontaneous growth, subjective symptoms, and psychological burdens concerning the malignancy and esthetic complaints [6–8]. Despite the treatment of these nodules that are established in surgical resections, treatments still carry some risks of neck scarring, temporary or permanent surgery complications, and postoperative hypothyroidism, which results in long-term thyroid hormone replacement therapy and monitoring [1]. Additionally, the management of the nodules occasionally becomes a dilemma when patients refuse surgery or when

This is an open access article under the terms of the Creative Commons Attribution-NonCommercial-NoDerivs License, which permits use and distribution in any medium, provided the original work is properly cited, the use is non-commercial and no modifications or adaptations are made.

Conflict of Interest Disclosures: All authors have completed and submitted the ICMJE Form for Disclosure of Potential Conflicts of Interest and none were reported. Contract grant sponsor: Innovation Plan in Guangxi Special Funds Project; Contract grant number: 2015CXJHA002; Contract grant sponsor: Guangxi Key Scientific and Technological Project; Contract grant number: 1598012-3.

\*Correspondence to: ZhiXian Li, Department of Ultrasonography, The First Affiliated Hospital of Guangxi Medical University, No. 6, Shuangyong Road, NanNing, Guangxi, 530022, P.R. China. E-mail: zhixianli2017@163.com

Accepted 13 August 2019

Published online 5 September 2019 in Wiley Online Library (wileyonlinelibrary.com).

DOI 10.1002/lsm.23150

the surgery has a high surgical risk. Thus, the questions of how to reduce re-resection to lower levels of complications while improving the quality of life for patients, how to relieve local symptoms and eliminate cosmetic concerns and how to alter the natural history of growing nodules remain to be addressed. In these scenarios, image-guided, minimally invasive interventional techniques may present attractive options [1,2,9].

Since decades, laser has been used in the medical field. Hoyer et al. [10] applied the Neodymium:Yttrium-Aluminum-Granat-Laser (Nd: YAG) to treat the VX 2 cancer cells of *in situ* liver cancer [10]. In 1971, due to the successful development of the quartz fiber, the Nd:YAG laser was able to enter the body cavity for treatment, thus rapidly expanding the application of the field of laser medicine. The concept of laser ablation (LA) was first proposed by British scholar Bown [11], and it refers to the conversion of laser light energy into heat energy, which causes localized biological tissue to coagulate, as well as to undergo necrosis, carbonization, gasification, and even evaporation [11]. LA is utilized in many surgical fields, such as surgeries for the liver, thyroid, metastatic lymph nodes, parathyroid glands, breast, kidney, prostate, and other body organs [8,12–21]. Other competitive procedures include percutaneous ethanol injection (PEI), radiofrequency ablation (RFA), microwave ablation (MWA), and high-intensity focused ultrasound (HIFU) [22–26]. LA under ultrasound guidance is a minimally invasive, thermal ablation technique. The procedure is effective, safe, well-tolerated by patients and has the flexibility of handling with real-time ultrasound guidance [7,8,27,28]. More importantly, the thinness of the optic fiber makes it possible to use a fine needle to easily and accurately reach the target nodule, and the necrosis that is induced by the thermal energy of the laser can be produced in a controllable and precise way under the condition of maintenance of light penetration, which minimizes the risk of injuring structures in the neck [27]. This feature represents an outstanding advantage of LA techniques when it is applied to the neck; specifically, its ability of inducing predictable, precise, and well-defined volumes of necrosis, while avoid the damage to vital, but delicate, structures that are adjacent to the lesions [19–21,29].

To date, however, no studies have focused on the use of single-fiber LA under ultrasound guidance when applied to the neck. A treatment employing the simultaneous placement of multiple fibers implies higher and more significant risks of side effects and complications, as well as poorer real-time ultrasound evaluations of the actual extent of thermal necrosis [7,28]. Additionally, the cost is an important factor in the decision-making for this procedure. Hence, the suitable cases and appropriate ablation modes, as well as the feasibility and efficacy of the use of ultrasound-guided single-fiber LA when applied to the neck are still worth studying. In this study, the results of a preliminary study that was conducted to evaluate the feasibility and effectiveness of single-fiber LA treatment under ultrasound guidance with appropriate ablation modes for selected cases of metastatic lymph nodes of PTC and benign cold thyroid nodules were reported.

## MATERIALS AND METHODS

### Patients

The study was conducted in accordance with the Helsinki Declaration and was approved by the institutional review board (ethical commitment number: 2006-[037]). Having been appropriately informed about the procedures, all of the patients provided their written informed consent. From June 2016 to September 2017, a total of 18 patients (aged 18–72 years), consisting of 8 patients with 18 metastatic lymph nodes of PTC and 10 patients with 10 benign cold thyroid nodules, underwent ultrasound-guided LA with a single fiber. All of the patients had at least a 12-month follow-up period.

The inclusion criteria for the patients with metastatic lymph nodes of PTC consisted of the following: patients who received ultrasound examinations and 18F-fluorodeoxyglucose-positron emission tomography (18FDG-PET) or computed tomography (CT) scans that suggested the presence of metastatic lymph nodes; patients who received ultrasound-guided fine-needle aspiration biopsies (FNABs) that showed malignancies; patients who had no more than a total number of three metastatic lymph nodes; patients who had metastatic lymph node diameters that were no more than 15 mm; patients who had locations of metastatic lymph nodes that could be isolated from large blood vessels and nerves, as well as a sufficiently safe operating space; patients who were ruled out for distant metastases by the use of CT scans; and patients who had received previous total thyroidectomy and neck dissection procedures and who were unsuitable for a second surgery or who were poorly responsive to radioiodine therapies.

The inclusion criteria for the patients with benign cold thyroid nodules were as follows: patients who had a single or dominant nodule with the absence of sonographic signs for malignancies; patients who had twice received ultrasound-guided FNABs or who had once received ultrasound-guided core needle biopsies (CNBs) that showed benignity; patients who were euthyroid with cold nodules from the 99mTc radioisotope scintigraphies; patients who had maximum volumes of the nodules that were no more than 5 ml; patients who had solid components of the nodules exceeding 80%; patients who had unsuspected or familiar histories of thyroid cancer and no history of previous radiation to the neck; patients who encountered subjective problems (local discomfort, foreign body sensation, esthetic disfigurement, and compressive symptoms) due to the nodules or patients who had progressive nodule growths; patients who were at a high surgical risk or who were ineligible for surgery; patients who refused surgeries for cosmetic concerns; and patients who had esthetic complaints or anxieties about a possible malignant change and who refused active surveillance and required minimally invasive treatments.

The exclusion criteria consisted of the following: patients who had abnormal platelet counts and blood coagulation function; patients who had severe cardiopulmonary disease; patients who had abnormal contralateral

vocal cord function; patients who had nodules with contiguous positions to the vessels, esophagus, trachea or nerves; patients who had nodules that were located in the isthmus; and patients who had metastatic lymph nodes with coarse calcifications (a coarse calcification was defined as a strong echo, with a maximum dimension larger than 2 mm, from the ultrasound examination).

### Preassessments

Laboratory tests, ultrasound examinations, contrast-enhanced ultrasound (CEUS), and ultrasound-guided FNAB or CNB for all of the patients were performed before the treatments. Laboratory tests, including a blood coagulation test, a complete blood count and a thyroid function test that contained serum thyroglobulin, were assessed. Electrocardiogram and CT measurements were routinely performed. Patients who were taking warfarin or anti-platelet medications were asked to stop the therapies for at least 2 weeks before the start of the treatments.

All of the ultrasound examinations and LA procedures were evaluated and performed by the same investigator, who had over 20 years of experience in the use of interventional treatments. Ultrasound and CEUS examinations were performed with commercially available ultrasound systems (Logiq 9, GE, CT) that were equipped with a 6–15 MHz linear array transducer (ML 6-15) and a commercially available ultrasound contrast agent (SonoVue; BroccoSpA, Milan, Italy). Patients were examined in the supine decubitus position, with the neck appropriately extended. Before LA, the sizes of the nodules were measured and the locations, ultrasonic characteristics such as shapes, internal echo features, edges, blood flow signals, etc. of the nodules were recorded, and the surrounding structures of the nodules were clarified to assess the feasibility and safety of LA procedures. Three orthogonal diameters of all of the nodules, including the largest diameters and the other two perpendicular diameters, were measured by the use of the ultrasound and CEUS images. These measurements were obtained by repeating each measurement three times, and the mean values were calculated. The volumes of the nodules both before and after the treatments were calculated by using the equation:  $V = \pi \times a \times b \times c / 6$  (where  $V$  is the volume,  $a$  is the largest diameter and  $b$  and  $c$  are the other two perpendicular diameters).

### Procedures

Single-fiber LA was performed in an interventional suite on an inpatient basis. Patients were placed on an operation table in the supine position, with an appropriate extension of the neck, and a venous catheter was inserted into the forearm vein without the use of premedication. Patients were constantly monitored by the use of an electrocardiogram monitor. The procedures were performed by using a commercially available ultrasound system (MyLab ClassC; Esaote, Florence, Italy), which was equipped with a 4–13 MHz linear array transducer (LA523). Under sterile conditions, local

anesthetics, with 2–5 ml 2% lidocaine, were administered. Afterwards, a 21-gauge biopsy needle (PA 21/12; GALLINI S.r.l., Mantova, Italy) was percutaneously penetrated into the target nodule with the use of real-time ultrasound guidance. After the introduced needle was fixed into the correct position and was confirmed by the ultrasound, the stylet of the needle was removed, and a single, 300- $\mu$ m plane-cut optic fiber (Bare Fiber PLAS; Asclepion Laser Technologies GmbH, Jena, Germany) was advanced through the sheath of the needle, after which the distal fiber tip was interstitially placed into the previously designed position of the target nodules. Subsequently, the needle was withdrawn by 5 mm, thus exposing the nude fiber tip that was located *in situ* and that had directly contacted the target nodule. Care was taken to maintain a safety distance of 15 mm between the fiber tip and the vital structures of the neck, in order to avoid thermal injury [27]. If necessary, an infusion of a mixture of 2% lidocaine and physiological saline solution (1:8 dilution) was used beforehand for a hydrodissection, in order to prevent the vital structures of the neck from sustaining a thermal injury. During the ablation, the optic fiber was moved and fixed with the use of real-time ultrasound monitoring and was connected with a laser source, which was a continuous-wave Nd: YAG laser operating at 1.064  $\mu$ m, with an optic beam-splitting device, through which the laser was outputted. (EchoLaser X4; Esaote). Fiber movements were followed certain orders: ablating the deep part of the nodule and then the superficial to reduce the interference caused by the hyperechoic areas generated by the ablation; ablating the nourish blood vessels of the nodule and then the body to reduce less affected by the heat-sink effect [30]. According to our clinical practice and research reports, LA was performed with an output power of 3 W or 3.5 W in the metastatic lymph nodes of PTC and with an output power of 4 W in the benign cold thyroid nodules [12,19–21,27,31]. The ablation time and energy was dependent on the individual nodules and was achieved by using an adequate exposure time and deposited energy to produce a complete ablation. The ablation status were confirmed with real-time ultrasound monitoring by observing the hyperechoic areas generated by the ablation, checking the blood flow signals in the ablation zone by color Doppler ultrasound, and determining the boundary of the ablation zone by CEUS. Additionally, the delivered energy was able to destroy an area that was 2–3 mm larger than the size of the malignant nodule so as to get a larger volume for safety margin [31]. Care was taken to precisely ablate the nourishing blood vessels around or inside of the nodules, as well as the peripheral areas of the nodules.

During laser illumination, the main feature was an irregular hyperechoic area that became enlarged over time (which was detected by the use of ultrasound monitoring), and the procedure was terminated when the hyperechoic area that was formed by LA had completely covered the entire volume of the nodules. When considering the ablated malignant nodules, the hyperechoic areas that were formed by LA were 2–3 mm

larger than the entire volume of the nodules in order to obtain safe borders. During the procedure, patients were asked to make sounds during the procedural time intervals, in order to assess voice changes. After laser irradiation, the laser source was turned off, and the fiber was carefully withdrawn. To avoid the seeding of the needle tract, the fiber was withdrawn while the laser source was still on at the end of the procedures in the ablation of the malignant nodules. Complete ablation was defined as the absence of blood flow signals and partial enhancement being observed within or adjacent to the nodule by the uses of ultrasound and CEUS images. After LA, color Doppler ultrasound examination and CEUS were performed to evaluate if a complete ablation was successful or unsuccessful. When blood flow signals or partial enhancement were observed within or adjacent to the nodules by the uses of ultrasound or CEUS images, an additional ablation procedure was instantly conducted to achieve a lack of blood flow signals or the enhancement throughout the entire nodule. When the ablation procedure was completed, patients were carefully monitored for 60 minutes with the compression of their necks.

All of the patients underwent single-fiber LA procedures under ultrasound guidance for one session for each patient. The selection criteria for the ablation modes of the single-fiber ablation method are shown in Table 5. The single-dot ablation mode was used in nodules that had the three orthogonal diameters measuring no greater than

10 mm in diameter, with the fiber tip placed in the center part of the interstitial space within the volume of the nodule and the ablation involving the use of a single insertion (Fig. 1A). A double-dots overlapping ablation mode was used in nodules that had the largest diameter measuring greater than 10 mm, but no more than 15 mm, in diameter, with the other two perpendicular diameters measuring no greater than 10 mm in diameter. First, two ablation dots were designed in advance along the long-axis when feasible, in order to allow for the two overlapping ablation zones that were completely formed to cover the entire nodule. Next, the fiber tip was set in the designed dots one by one along the short-axis, in order to form the two overlapping ablation zones and to form the ablation using two insertions with two introduced needles (Fig. 1B). A multiple levels and dots overlapping ablation mode was used in nodules that had all three of the orthogonal diameters measuring larger than 10 mm. First, more than one level along the longitudinal axis was previously set up, thus leaving spaces among the levels that were approximately 10 mm in size (Fig. 1C). Then, multiple ablation dots were designed at each level of the transverse axis when feasible, in order to allow for enough multiple overlapping ablation zones to completely ablate each level of the nodule. Finally, the fiber tip was placed in the designed dots one by one at each level until the entire nodule was completely ablated, with the ablation using several insertions (Figs. 1D and 2).

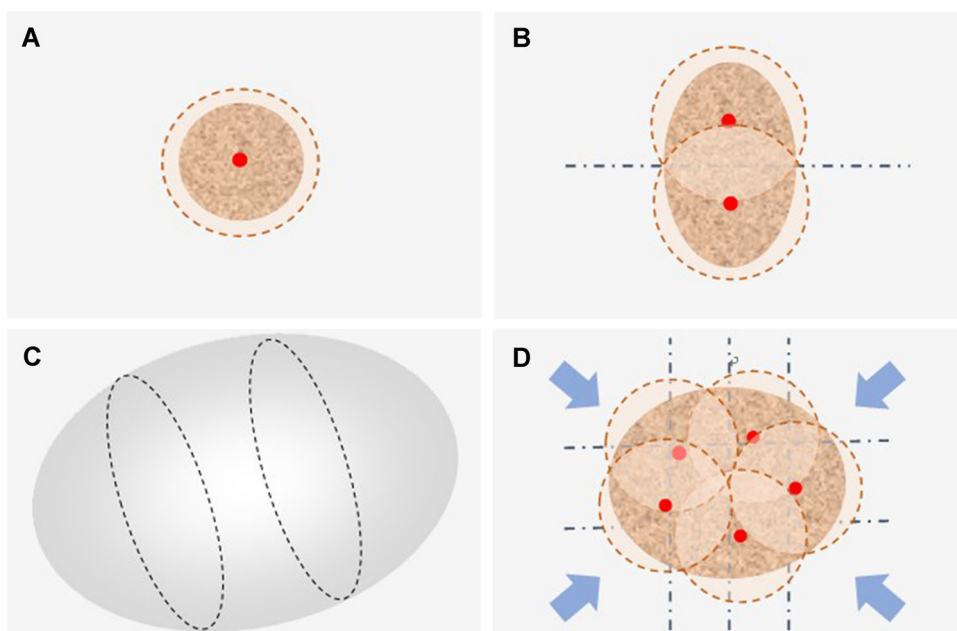


Fig. 1. The schematic diagrams of ablation modes for single-fiber laser ablation under ultrasound guidance. (A) Showed the single-dot ablation mode which was used in the nodules with three orthogonal diameters measuring no greater than 10 mm in diameter, with a dot, a level and an insertion. (B) Showed the double-dots overlapping ablation mode which was used in the nodules with the largest diameters measuring greater than 10 mm (in which the nodules measured no more than 15 mm in diameter) and with the other two perpendicular diameters measuring no greater than 10 mm in diameter) with two dots, a level and two insertions. (C and D) Showed the multiple levels and dots overlapping ablation mode which was used in the nodules with the three orthogonal diameters all measuring larger than 10 mm, with multiple dots, a level and insertions.

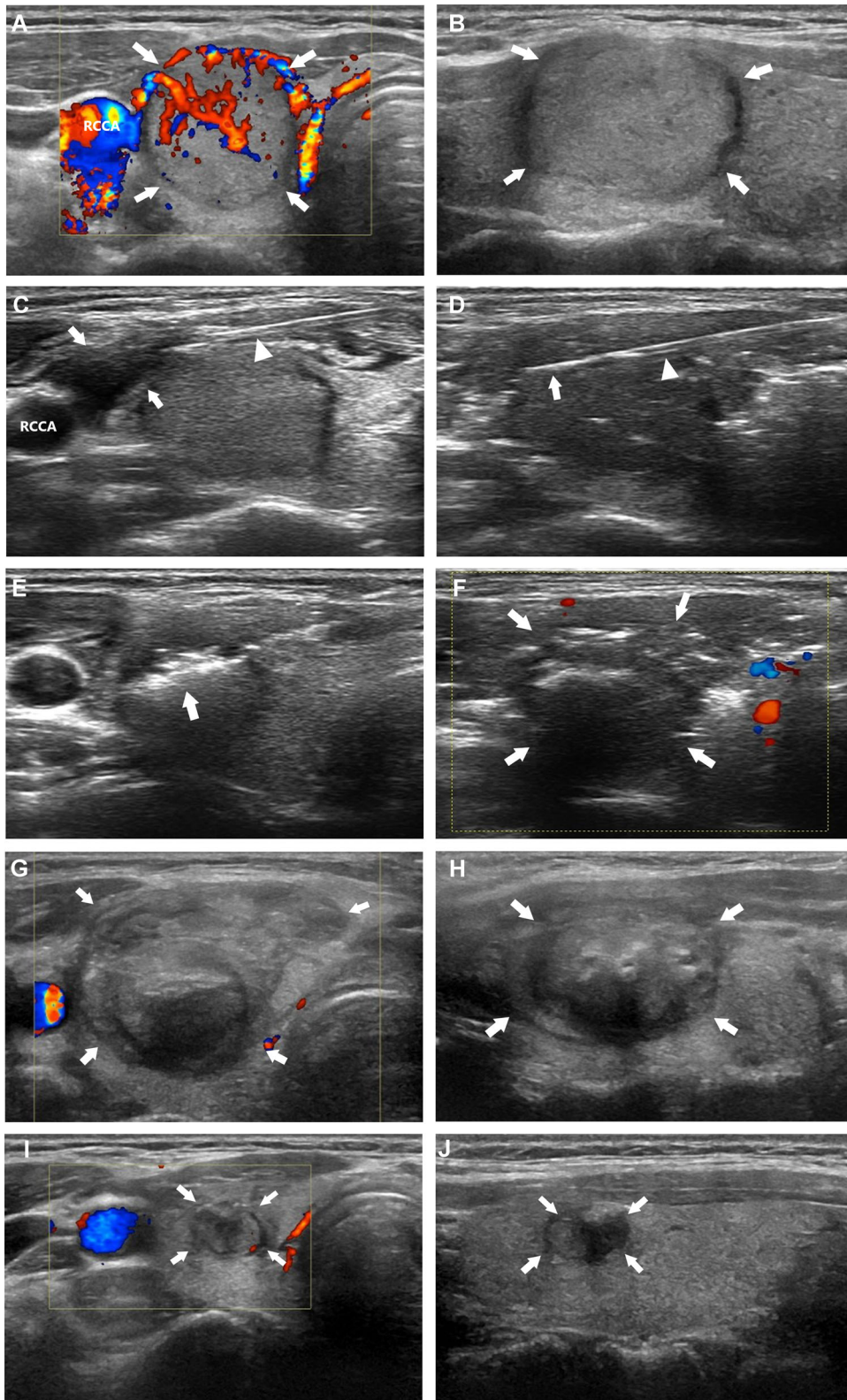


FIGURE 2 Continued.

**TABLE 1. Baseline Demographics and Characteristics of Patients With Metastatic Lymph Nodes of Papillary Thyroid Carcinoma (PTC)**

Patient no.	Sex	Age (years)	Location/level	Initial size (cm)	Initial volume (ml)	Follow-up (months)	Output power (W)	Energy deposition (KJ)
1	F	47	L-III/L-IV	0.8 × 0.52 × 1.06/ 0.84 × 0.56 × 0.62	0.23/0.15	18	3/3	1.3/1
2	F	27	L-III/L-III	0.86 × 0.61 × 1.05/ 0.99 × 0.66 × 1.34	0.29/0.46	12	3/3.5	1.3/1.5
3	M	34	R-III/L-VI	0.71 × 0.39 × 1.09/ 0.6 × 0.42 × 0.71	0.16/0.09	12	3/3	1.2/1
4	M	48	L-III/L-VI	0.55 × 0.9 × 1.5/ 0.6 × 0.62 × 1.15	0.39/0.22	12	3.5/3	1.8/1.3
5	F	47	L-III/L-III	0.42 × 0.95 × 1.4/	0.29/0.35	12	3.5/3.5	1.5/1.8
6	F	30	R-II/R-III	0.44 × 1.0 × 1.5	0.33/0.29	12	3/3	1.8/1.4
7	F	24	R-II	0.62 × 0.9 × 1.12/	0.21	12	3/3.5	1.4/1.7
8	M	55	L-III/L-III	0.65 × 0.72 × 1.2	0.47/0.46	12	3.5	1.6
			L-VI	0.58 × 0.8 × 0.85	0.26	12	3/3	1.5/1.7
			R-II/R-III	0.73 × 0.94 × 1.32/	0.38/0.12	12	3	1.1
				0.8 × 0.75 × 1.45				
				0.5 × 0.79 × 1.25				
				0.84 × 0.63 × 1.37/				
				0.6 × 0.52 × 0.75				

### Follow-Up

The follow-ups consisted of image examinations, laboratory tests and clinical evaluations. Ultrasound examinations were performed at 1 and 7 days, as well as at 1, 3, 6, and 12 months after the end of the study, with examinations then performed every 6 months thereafter. Changes in the ablated zones, including the sizes, volumes, echogenicities, vascularities and presences of other abnormalities in the neck, were carefully assessed by the use of ultrasound. The percentage reduction in the volume of each ablated nodule was defined as the volume reduction ratio (VRR) and was calculated as:  $VRR = \{[(\text{initial volume} - \text{final volume}) \times 100\%] / \text{initial volume}\}$ , which was calculated at each follow-up. CEUS scans were performed at 10 minutes and at 7 days after LA to confirm

the presence of a complete ablation. CT scans were performed once a year. If there were persistently elevated thyroglobulin levels, or if there was no significant decrease in the abnormally elevated serum thyroglobulin levels, in patients with metastatic lymph nodes of PTC after the LA treatment, additional diagnostic examinations, such as 18FDG-PET or CT scans, were performed. Thyroid function tests, including thyroglobulin measurements, were administered to all of the patients at 7 days after the LA treatment, and thyroglobulin measurements were monitored at 7 days, as well as at 1, 3, and 6 months after the end of the study, with measurements, then taken every 6 months thereafter, for patients with metastatic lymph nodes. Adverse effects and complications were recorded during the entire follow-up period.

Fig. 2. A series of ultrasound images taken before laser ablation (**A** and **B**), during laser ablation (**C–F**), 7 days (**G** and **H**) and 12 months (**I** and **J**) after laser ablation of a 45-year-old woman with a solid benign cold thyroid nodule in the right thyroid. (**A**) showed the nodule with peripheral and internal blood flow signals on transverse image. (**B**) Showed the nodule on the longitudinal image. (**C**) Showed an infusion of a mixture of 2% lidocaine and physiological saline solution (1:8 dilution) was used beforehand for a hydrodissection in order to prevent the right common carotid artery (RCCA) from sustaining thermal injury (The arrows referred to the liquid dark area formed by hydrodissection and the triangle referred to the needle). (**D**) Showed an introduced needle and a single fiber (the triangle referred to the introduced needle and the arrow referred to the nude fiber tip). (**E**) Showed an irregular hyperechoic area that became enlarged overtime during laser illumination under ultrasound monitoring. (**F**) Showed the procedure was terminated when the hyperechoic area that was formed by laser ablation had completely covered the entire area of the nodule. (**G** and **H**) Showed the transverse and longitudinal images of the nodule with 7 days after laser ablation. The nodule slightly became larger than before due to reactive edema changes. (**I** and **J**) showed the transverse and longitudinal images of the nodule with 12 months after laser ablation. The nodule significantly decreased in volume and blood flow signals, with the volume reduction ratio of 74%.



**TABLE 2. Baseline Demographics and Characteristics of Patients With Benign Cold Thyroid Nodules**

Patient no.	Sex	Age (years)	Location/level	Initial size (cm)	Initial volume (mL)	Follow-up (months)	Output power (W)	Energy deposition (KJ)
9	F	29	R	1.65 × 1.73 × 2.24	3.35	18	4	5.2
10	F	31	R	1.45 × 1.6 × 2.86	3.47	18	4	5.1
11	F	30	R	1.68 × 1.92 × 2.77	4.68	18	4	6.0
12	F	27	R	1.74 × 1.61 × 2.62	3.84	12	4	5.5
13	M	57	L	1.53 × 1.72 × 3.48	4.8	12	4	6.1
14	F	18	R	2.02 × 1.60 × 2.44	4.13	12	4	4.6
15	F	41	R	1.65 × 1.48 × 2.25	2.88	12	4	3.9
16	F	45	R	1.83 × 1.7 × 2.38	3.88	12	4	5.1
17	F	72	L	1.5 × 2.42 × 1.65	3.14	12	4	4.4
18	F	22	R	1.8 × 2.22 × 2.05	4.29	12	4	5.5

### Statistical Analysis

The continuous variables are presented as the means and standard deviations (means ± SDs). Post-ablation measurements of the mean largest diameters and the mean volumes of the ablated nodules were compared with the pre-ablation measurements by the use of a paired *t* test. The statistical analysis was performed by using SPSS 19.0 (SPSS Inc., Chicago, IL).

### RESULTS

The baseline demographics and characteristics of these patients are presented in Tables 1 and 2. The 18 patients each had at least a 12-month follow-up period. The technical successes of the LA procedures were achieved in all of the patients. The mean total energy depositions for the nodules of the metastatic lymph nodes of PTC and benign cold thyroid nodules were 1.4 ± 0.3 kJ (range, 1–1.8 kJ) and 5.1 ± 0.7 kJ (range, 3.9–6.1 kJ), respectively. Complete ablations that were demonstrated as the absence of blood flow signals and

the lack of enhancement with the uses of ultrasound and CEUS examinations after the LA procedure were achieved in all of the patients. In the eight patients with metastatic lymph nodes of PTC, the thyroglobulin levels decreased from 10.6 ± 5.9 ng/ml before the treatment to 0.12 ± 0.04 ng/ml after the treatment (*P* < 0.05, Wilcoxon signed-ranks test).

The mean values of the largest diameters and volumes, as well as the VRRs, of the metastatic lymph nodes of PTC and benign cold thyroid nodules before and after a single-fiber LA treatment at the 3-, 6- and 12-month follow-up periods are shown in Tables 3 and 4. After 12 months of follow-up, the mean baseline volumes decreased from 0.29 ± 0.12 to 0.03 ± 0.03 ml, and from 3.85 ± 0.64 to 1.1 ± 0.37 ml, with the mean VRRs being 90.3 ± 7.6% and 72 ± 5.8%, in the metastatic lymph nodes of PTC and benign cold thyroid nodules, respectively (*P* < 0.05, paired *t* test). The values of the mean largest diameters and mean volumes for all of the ablative nodules were significantly lower at the 3-, 6- and 12-month follow-up periods, compared to the values

**TABLE 3. Outcomes of Patients With Metastatic Lymph Nodes of PTC Before and After Single Laser Ablation Treatment**

Variable		Preablation	Post-ablation		
		Initial	3-month	6-month	12-month
Mean largest diameter (cm)	Mean ± SD	1.16 ± 0.25	1.01 ± 0.16*	0.73 ± 0.18*	0.37 ± 0.26*
	Range	0.71–1.5	0.8–1.25	0.4–1.03	0–0.73
	Median	1.18	1.02	0.77	0.47
Mean volume (ml)	Mean ± SD	0.29 ± 0.12	0.23 ± 0.06*	0.1 ± 0.05*	0.03 ± 0.03*
	Range	0.09–0.47	0.13–0.33	0.02–0.19	0–0.1
	Median	0.29	0.23	0.1	0.02
Mean VRR (%)	Mean ± SD	–	12.3 ± 22.4	64.7 ± 10.1	90.3 ± 7.6
	Range	–	–44–38	46–83	78–100
	Median	–	19.5	65.5	89.5

VRR (the mean volume reduction ratio) = {(initial volume–final volume) × 100%}/initial volume}.

PLA, percutaneous laser ablation; PTC, papillary thyroid carcinoma; VRR, volume reduction ratio.

\*Significance of the difference compared with before PLA by using the paired *t* test: *P* < 0.05.

**TABLE 4. Outcomes of Patients With Benign Cold Thyroid Nodules Before and After Single Laser Ablation Treatment**

Variable		Preablation	Post-ablation		
		Initial	3-month	6-month	12-month
Mean largest diameter (cm)	Mean $\pm$ SD	2.57 $\pm$ 0.39	2.2 $\pm$ 0.33*	1.88 $\pm$ 0.31*	1.46 $\pm$ 0.26*
	Range	2.22–3.48	1.84–2.95	1.54–2.52	1.2–2.02
	Median	2.43	2.13	1.86	1.4
Mean volume (ml)	Mean $\pm$ SD	3.85 $\pm$ 0.64	2.49 $\pm$ 0.53*	1.77 $\pm$ 0.42*	1.1 $\pm$ 0.37*
	Range	2.88–4.8	1.89–3.5	1.33–2.63	0.73–1.9
	Median	3.86	2.42	1.67	1.05
Mean VRR (%)	Mean $\pm$ SD	–	34.2 $\pm$ 4.4	53.8 $\pm$ 7.6	72 $\pm$ 5.8
	Range	–	27–41	42–65	61–80
	Median	–	33.5	56	72

VRR (the mean volume reduction ratio) =  $\{[(\text{initial volume} - \text{final volume}) \times 100\%] / \text{initial volume}\}$ .

PLA, percutaneous laser ablation; VRR, volume reduction ratio.

\*Significance of the difference compared with before PLA by using the paired *t* test:  $P < 0.05$ .

before the treatment. At the last follow-up period among the eighteen ablative metastatic lymph nodes of PTC, six ablation zones had completely disappeared, whereas the remaining zones remained as scar-like areas or small hyperechoic areas that were compatible with scar tissue. No regrowth of the ablated nodules and no distant metastases were detected during the follow-ups. The thyroid function tests in patients with benign cold thyroid nodules were within normal ranges both before and after the treatment.

The single-fiber LA treatment was well tolerated in all of the patients. No immediate or delayed major complications were observed. Although most of the patients reported mild sensations of pain, heat or both sensations in the neck during the ablation procedure, the symptoms disappeared or were relieved when the energy was turned off and when the ablation procedures were stopped for several seconds to minutes. Two patients complained of neck pain after the procedure, but they recovered within

7 days and without the need for any treatments. No tranquilizers were provided either before or after the treatments.

## DISCUSSION

Ultrasound-guided LA was first experimentally conducted *in vitro* on human, surgically excised thyroid tissue by Pacella et al. [27]. Since then, a series of studies have reported favorable results. However, no studies have focused on single-fiber LA in treating metastatic lymph nodes of PTC and benign cold thyroid nodules [19–21]. In this study, significant nodule volume reductions were obtained in all of the patients, and the values of abnormal serum thyroglobulin in patients with metastatic lymph nodes of PTC returned to normal levels. With regard to safety, a multicenter study on 1,531 patients of LA for thyroid nodules demonstrated that the cases and rates of major complications, minor complications and minor side effects were 17% and 0.9%, 8% and 0.5% and 463% and 30.2%, respectively [32]. In the study, the major complication involved voice changes, and the minor complications included hematoma and skin burn, whereas minor side effects included pain, vasovagal reactions, cough, and fever (37.5–38.5°C) [32]. In this study, no major and minor complications occurred, and only the compliance of pain without the use of analgesic medication was observed. Moreover, on the basis of reported mathematic and overlapping modes for the treatment of large liver tumors with RFA, a single-dot ablation mode, a double-dots overlapping ablation mode and a multiple levels and dots overlapping ablation mode when performing single-LA treatments for these selected cases were performed [33]. Other competitive ablation methods include MWA, RFA, PEI, and HIFU. The thermal efficiency and ablation range of MWA are high and large, respectively, whereas the heat-sink effect is low, in contrast to other thermal ablation methods [34]. RFA is a widely used and well-established ablation method, but it requires the use of skin electrodes, which may cause skin burns and are not

**TABLE 5. Selection Criteria for the Ablation Modes of Single-Fiber Laser Ablation**

Type	Length (mm)	Width (mm)	Thickness (mm)
Single-dot ablation mode	$\leq 10$	$\leq 10$	$\leq 10$
Double-dots overlapping ablation mode	$> 10$ and $\leq 15$	$\leq 10$	$\leq 10$
Multiple levels and dots overlapping ablation mode	$\leq 10$	$> 10$ and $\leq 15$	$\leq 10$
	$\leq 10$	$\leq 10$	$> 10$ and $\leq 15$
Multiple levels and dots overlapping ablation mode	$> 10$	$> 10$	$> 10$

Length and width are measured via the ultrasonography of the transverse section of the thyroid, and the thickness is measured via the ultrasonography of the longitudinal section of the thyroid.



suitable for patients with pacemakers [35]. PEI seems to be an easy, safe, well-tolerated and low-cost procedure, but it has several drawbacks, such as the need for multiple treatment sessions and difficulty in predicting the area of tissue damage because of uneven distributions [24,35]. HIFU is a noninvasive procedure that is less dependent on the tumor location and has very low risks of implant metastasis and bleeding [26,36]. However, it has technical limitations, including the fact that the high-reflection interface affects the penetration of ultrasonic waves, which then results in decreases in focused accuracy and thermal efficiency [26,36]. In comparison with these ablation procedures, the outstanding advantages of LA are that the puncture needle is the smallest of the various needle types, which minimizes the damage to normal tissue, and the accuracy of LA is high, and the risks of needle bleeding and needle tract seeding are extremely low [13].

The majority of benign thyroid nodules remain stable, in terms of size, and nearly asymptomatic. However, a minority of patients who have growing nodules and that also present with local symptoms or cosmetic concerns, as well as patients that have toxic thyroid nodules and that present with local and systemic symptoms, may seek treatment [1,2]. In the past few decades, various image-guided nonsurgical procedures have been proposed as alternative and minimally invasive approaches for these problems [1,2]. For benign cold thyroid nodules, clinical follow-up and several ablative methods, including LA, RFA, MWA, and HIFU, have been applied to these nodules and these ablative methods have demonstrated good results, and LA appears to be superior to the other methods, due to its advantages. A prospective pilot study demonstrated that LA group achieved technique efficacy and clinical improvement in contrast to clinical follow-up group [12]. A 3-year, multicenter, prospective randomized trial demonstrated that LA obtained long-term efficacy, with an absence of thyroid function changes [8]. A recent large scale study of 1,531 patients demonstrated that the risk of complications with the application of LA was very low, and only 17 cases (0.9%) exhibited major complications of voice change, with only 9 cases (0.5%) exhibiting minor complications of hematoma and skin burns [32]. RFA is an effective and safe modality for reducing the volumes of benign cold thyroid nodules, but the incidence and severity of complications of RFA are higher than those for LA [35,37]. A multicenter study of 1,459 patients who had 1,543 thyroid nodules that were treated with RFA exhibited a complication rate of 3.3%, which included 20 major complications and 28 minor complications [38]. In their study, the major complications included voice changes, nodule ruptures, nodule ruptures with abscess formations, hypothyroidism and brachial plexus injuries, whereas the minor complications included hematoma, vomiting and skin burns [38]. A prospective multicenter study assessed the uses of MWA and RFA for the treatment of benign cold thyroid nodules and demonstrated that both MWA and RFA were safe and effective, but the achieved VRR in the RFA group was greater [39].

Another study evaluated the uses of LA and RFA for the treatment of benign cold thyroid nodules and demonstrated that LA and RFA were similarly feasible, safe, and effective [37]. For pure cysts and thyroid lesions with dominant fluid components, studies have proven that PEI is the most appropriate treatment, and guidelines have recommended PEI as being the first-line treatment for relapsing benign cystic lesions [1,2,24,25,40]. For toxic thyroid nodules, traditional treatment options include surgical resection or radioactive iodine treatment (RAI). Surgery has risks that are associated with general anesthesia and permanent hypothyroidism, as well as potential complications. RAI is also associated with permanent hypothyroidism and may not definitively cure hyperthyroidism [41,42]. Likewise, comparable efficacies of LA and RAI for reducing the volumes of toxic thyroid nodules have been reported; however, in contrast to RAI, the normalization of serum thyroid-stimulating hormone concentrations in the LA group was only observed in half of the patients [43]. Of note, the combination of LA and RAI appeared to be an attractive option for the debulking that is achieved with LA and the functional impairment that is induced by RAI [44]. A study by Chianelli et al. [44] demonstrated that the combination of LA and RAI induced faster and greater improvements in local and systematic symptoms, compared to the sole use of RAI.

Of note, the use of multiple fibers for LA under ultrasound guidance may have some disadvantages. First, the usage of multiple fibers for LA may present a greater risk of complications than the use of a single fiber of LA. Døssing et al. pointed out that the use of LA with simultaneous employed placement of multiple fibers in treating larger nodules may induce a greater risk of complications and, transient vocal cord palsy has been reported in two studies when multiple fibers have been used [29,31,45]. Furthermore, a poorer real-time ultrasound overview of the actual extent of thermal necrosis, due to the use of only two-dimensional images, is unavoidable, and the increased acoustic shadowing that results in less clear margins of the thermally induced necrosis appear to be confounding. Moreover, ablation procedures that use multiple fibers are less flexible and manipulative than those that use a single fiber, especially as it pertains to the ablation of the peripheral areas and the blocking of the nourishing vessels of the target nodules. Additionally, multiple fibers result in higher costs. Therefore, the treatment of single-fiber LA with appropriate ablation modes for selected cases may be considered, in order to overcome these disadvantages. In contrast to the use of multiple fibers with LA, LA that uses a single fiber has some unique advantages. First, the lower risk of complications can be expected. Second, single-fiber LA under ultrasound guidance can enable more intuitive and clearer real-time monitoring, as well as more detailed and flexible ablation procedures of the target nodules, which can then achieve precise and specific treatments, to some extent. Third, the combination of single-fiber LA and appropriate ablation modes has the advantages of flexible operation, easy movements,

precise locations and accurate and controllable blockages of nourishing blood vessels, as well as the ablation of peripheral areas of the target nodules, which can achieve complete ablation. Fourth, the better cost-effectiveness for patients who use this treatment cannot be ignored.

It should be noted that single-fiber LA is based on strict selections. Although a multiple levels and dots overlapping ablation mode was used for the ablation of benign cold thyroid nodules when performing LA with a single fiber, it was difficult to accurately determine the exact parameters of volume ranges and energy depositions that corresponded to the unit volumes of the nodules for which a single-fiber laser can be used for achieving complete ablation. As different tissues have different characteristics, such as the amount of colloid, both fibrosis and vascularity may possibly account for the different optical properties of the nodule, thereby resulting in differences in responsiveness and a demand for the amount of deposited energy [31]. In this study, a 5-ml-volume upper limit existed for the benign cold thyroid nodules, which is only a preliminary inclusion that was dependent on our experiences and previous studies [12,27,29]. However, the feasibility and effectiveness of ultrasound-guided single-fiber LA were evaluated, and the appropriate ablation modes for these selected nodules were performed. When performed LA with a single fiber in the neck, the fiber was used in similarity to an embroidered needle in the hands of the operator, whereas the procedure is likely to be referred to as an embroidery technique because of the thin and long nature of the laser fiber, the complex anatomy of the neck and the delicate procedure of LA. Single-fiber LA has the unique advantage of allowing for a flexible operation, easy movements, precise locations and the accurate and controllable blockages of nourishing blood vessels, as well as the ablation of peripheral areas. For multiple levels and dots overlapping modes, with increased ablation levels and dots, it is likely that the more difficult it will be to ensure that the ablation zones completely cover the nodules. Therefore, the sizes of the metastatic lymph nodes of PTC were strictly limited so that only a single level with a single dot, or two dots, were required, in order to ensure the complete ablations of the nodules. However, for benign cold thyroid nodules, multiple levels and dots were needed, which increased the risk that the ablation zones may not completely cover the nodules at first. However, with real-time ultrasound monitoring, and by using the advantages of the flexibility, simplicity and accuracy of single-fiber LA, complete ablation can be achieved.

Some limitations of the study should be taken into account. First, this was a retrospective study with unknown biases. Second, the strict inclusion criteria and small sample size may make the findings less universal. Third, this study only reported on a relatively short follow-up period, and long-term outcomes were not fully obtained. Moreover, the data on whether LA had influences on quality of life and survival were lacking.

In summary, single-fiber LA under ultrasound guidance with appropriate ablation modes for treating selected metastatic lymph nodes of PTC and benign cold thyroid nodules is feasible and effective. Moreover, the single-dot ablation mode, the double-dots overlapping ablation mode and the multiple levels and dots overlapping ablation mode were performed for LA with a single fiber, when applied to treating selected cases. It is hoped that this information will be helpful in improving the efficiency and applicability of the application of ultrasound-guided single-fiber LA.

## ACKNOWLEDGMENTS

This research was supported by the 2015 Innovation Plan in Guangxi Special Funds Project (2015CXJHA002) and the Guangxi Key Scientific and Technological Project (1598012-3).

## REFERENCES

- Haugen BR, Alexander EK, Bible KC, et al. 2015 American Thyroid Association Management Guidelines for adult patients with thyroid nodules and differentiated thyroid cancer: The American thyroid association guidelines task force on thyroid nodules and differentiated thyroid cancer. *Thyroid* 2016;26(1):1–133.
- Gharib H, Papini E, Paschke R, et al. American Association of Clinical Endocrinologists, Associazione Medici Endocrinologi, and European Thyroid Association Medical guidelines for clinical practice for the diagnosis and management of thyroid nodules. *Endocr Pract* 2010;16:1–43.
- Cady B, Rossi R. An expanded view of risk-group definition in differentiated thyroid carcinoma. *Surgery* 1988;104(6):947–953.
- Kim BM, Kim MJ, Kim EK, Park SI, Park CS, Chung WY. Controlling recurrent papillary thyroid carcinoma in the neck by ultrasonography-guided percutaneous ethanol injection. *Eur Radiol* 2008;18(4):835–842.
- Hay ID, Bergstralh EJ, Goellner JR, Ebersold JR, Grant CS. Predicting outcome in papillary thyroid carcinoma: Development of a reliable prognostic scoring system in a cohort of 1779 patients surgically treated at one institution during 1940 through 1989. *Surgery* 1993;114(6):1050–1057.
- Papini E, Guglielmi R, Bizzarri G, et al. Treatment of benign cold thyroid nodules: A randomized clinical trial of percutaneous laser ablation versus levothyroxine therapy or follow-up. *Thyroid* 2007;17(3):229–235.
- Døssing H, Bennedbæk FN, Hegedüs L. Effect of ultrasound-guided interstitial laser photocoagulation on benign solitary solid cold thyroid nodules—A randomised study. *Eur J Endocrinol* 2005;152(3):341–345.
- Papini E, Rago T, Gambelunghe G, et al. Long-term efficacy of ultrasound-guided laser ablation for benign solid thyroid nodules. *J Clin Endocrinol Metab* 2014;99(10):3653–3659.
- Leenhardt L, Erdogan MF, Hegedus L, et al. 2013 European Thyroid Association Guidelines for cervical ultrasound scan and ultrasound-guided techniques in the postoperative management of patients with thyroid cancer. *Eur Thyroid J* 2013;2(3):147–159.
- Hoye RC, Riggle GC, Ketcham AS. Laser destruction of experimental tumors: State of the art and protection of personnel. *Am Ind Hyg Assoc J* 1968;29(2):173–180.
- Bown SG. Phototherapy of tumors. *World J Surg* 1983;7(6):700–709.
- Freitas RMC, Miazaki AP, Tsunemi MH, et al. Laser ablation of benign thyroid nodules: a prospective pilot study with a preliminary analysis of the employed energy. *Lasers Surg Med* 2019. <https://doi.org/10.1002/lsm.23144>

13. Arienti V, Pretolani S, Pacella CM, et al. Complications of laser ablation for hepatocellular carcinoma: A multicenter study. *Radiology* 2008;246(3):947–955.
14. Andrioli M, Riganti F, Pacella CM, Valcavi R. Long-term effectiveness of ultrasound-guided laser ablation of hyperfunctioning parathyroid adenomas: Present and future perspectives. *Am J Roentgenol* 2012;199(5):1164–1168.
15. Lee J, Jung JH, Kim WW, et al. Comparison of laser ablation using multidirectional and forward-firing fibers in breast cancer. *Minim Invasive Ther Allied Technol* 2018;27(5):292–299.
16. Finelli A, Ismaila N, Bro B, et al. Management of small renal masses: American Society of Clinical Oncology Clinical Practice Guideline. *J Clin Oncol* 2017;35(6):668–680.
17. Natarajan S, Raman S, Priester AM, et al. Focal laser ablation of prostate cancer: Phase I clinical trial. *J Urol* 2016;196(1):68–75.
18. Patelli G, Ranieri A, Paganelli A, Mauri G, Pacella CM. Transperineal laser ablation for percutaneous treatment of benign prostatic hyperplasia: A feasibility study. *Cardiovasc Intervent Radiol* 2017;40(9):1440–1446.
19. Papini E, Bizzarri G, Bianchini A, et al. Percutaneous ultrasound-guided laser ablation is effective for treating selected nodal metastases in papillary thyroid cancer. *J Clin Endocrinol Metab* 2013;98(1):E92–E97.
20. Mauri G, Cova L, Tondolo T, et al. Percutaneous laser ablation of metastatic lymph nodes in the neck from papillary thyroid carcinoma: Preliminary results. *J Clin Endocrinol Metab* 2013;98(7):E1203–E1207.
21. Mauri G, Cova L, Ierace T, et al. Treatment of metastatic lymph nodes in the neck from papillary thyroid carcinoma with percutaneous laser ablation. *Cardiovasc Intervent Radiol* 2016;39(7):1023–1030.
22. Sung JY, Baek JH, Jung SL, et al. Radiofrequency ablation for autonomously functioning thyroid nodules: A multicenter study. *Thyroid* 2015;25(1):112–117.
23. Wu W, Gong X, Zhou Q, Chen X, Chen X, Shi B. US-guided percutaneous microwave ablation for the treatment of benign thyroid nodules. *Endocr J* 2017;64(11):1079–1085.
24. Guglielmi R, Pacella CM, Bianchini A, et al. Percutaneous ethanol injection treatment in benign thyroid lesions: Role and efficacy. *Thyroid* 2004;14(2):125–131.
25. Tarantino L, Francica G, Sordelli I, et al. Percutaneous ethanol injection of hyperfunctioning thyroid nodules: Long-term follow-up in 125 patients. *Am J Roentgenol* 2008;190(3):800–808.
26. Lang BH, Woo YC, Chiu KWH. High intensity focused ultrasound (HIFU) ablation of benign thyroid nodule is safe and efficacious in patients who continue taking an anticoagulation or anti-platelet agent in the treatment period. *Int J Hyperthermia* 2019;36:186–190.
27. Pacella CM, Bizzarri G, Guglielmi R, et al. Thyroid tissue: US-guided percutaneous interstitial laser ablation—A feasibility study. *Radiology* 2000;217(3):673–677.
28. Valcavi R, Riganti F, Bertani A, Formisano D, Pacella CM. Percutaneous laser ablation of cold benign thyroid nodules: A 3-year follow-up study in 122 patients. *Thyroid* 2010;20(11):1253–1261.
29. Pacella CM, Bizzarri G, Spiezia S, et al. Thyroid tissue: US-guided percutaneous laser thermal ablation. *Radiology* 2004;232(1):272–280.
30. Nakazawa T, Kokubu S, Shibuya A, et al. Radiofrequency ablation of hepatocellular carcinoma: Correlation between local tumor progression after ablation and ablative margin. *Am J Roentgenol* 2007;188(2):480–488.
31. Døssing H, Bennedbæk FN, Hegedüs L. Long-term outcome following interstitial laser photocoagulation of benign cold thyroid nodules. *Eur J Endocrinol* 2011;165(1):123–128.
32. Pacella CM, Mauri G, Achille G, et al. Outcomes and risk factors for complications of laser ablation for thyroid nodules: A multicenter study on 1531 patients. *J Clin Endocrinol Metab* 2015;100(10):3903–3910.
33. Chen MH, Yang W, Yan K, et al. Large liver tumors: Protocol for radiofrequency ablation and its clinical application in 110 patients—Mathematic model, overlapping mode, and electrode placement process. *Radiology* 2004;232(1):260–271.
34. Wright AS, Sampson LA, Warner TF, Mahvi DM, Lee FT, Jr. Radiofrequency versus microwave ablation in a hepatic porcine model. *Radiology* 2005;236(1):132–139.
35. Jeong WK, Baek JH, Rhim H, et al. Radiofrequency ablation of benign thyroid nodules: Safety and imaging follow-up in 236 patients. *Eur Radiol* 2008;18(6):1244–1250.
36. ter Haar GR. High intensity focused ultrasound for the treatment of tumors. *Echocardiography* 2001;18(4):317–322.
37. Mauri G, Cova L, Monaco CG, et al. Benign thyroid nodules treatment using percutaneous laser ablation (PLA) and radiofrequency ablation (RFA). *Int J Hyperthermia* 2017;33(3):295–299.
38. Baek JH, Lee JH, Sung JY, et al. Complications encountered in the treatment of benign thyroid nodules with US-guided radiofrequency ablation: A multicenter study. *Radiology* 2012;262(1):335–342.
39. Cheng Z, Che Y, Yu S, et al. US-Guided percutaneous radiofrequency versus microwave ablation for benign thyroid nodules: A prospective multicenter study. *Sci Rep* 2017;7(1):9554.
40. Paschke R, Hegedüs L, Alexander E, Valcavi R, Papini E, Gharib H. Thyroid nodule guidelines: agreement, disagreement and need for future research. *Nat Rev Endocrinol* 2011;7(6):354–361.
41. Eyre-Brook IA, Talbot CH. The treatment of autonomous functioning thyroid nodules. *Br J Surg* 1982;69(10):577–579.
42. Bolusani H, Okosieme O, Velagapudi M, Parsons K, Lazarus J. Determinants of long-term outcome after radioiodine therapy for solitary autonomous thyroid nodules. *Endocr Pract* 2008;14(5):543–549.
43. Døssing H, Bennedbæk FN, Bonnema SJ, Grupe P, Hegedüs L. Randomized prospective study comparing a single radioiodine dose and a single laser therapy session in autonomously functioning thyroid nodules. *Eur J Endocrinol* 2007;157(1):95–100.
44. Chianelli M, Bizzarri G, Todino V, et al. Laser ablation and 131-iodine: A 24-month pilot study of combined treatment for large toxic nodular goiter. *J Clin Endocrinol Metab* 2014;99(7):E1283–E1286.
45. Spiezia S, Vitale G, Di Somma C, et al. Ultrasound-guided laser thermal ablation in the treatment of autonomous hyperfunctioning thyroid nodules and compressive nontoxic nodular goiter. *Thyroid* 2003;13(10):941–947.