

## Standard Article

J Vet Intern Med 2016;30:1739–1746

## Development of a Semiquantitative Histological Score for the Diagnosis of Heaves Using Endobronchial Biopsy Specimens in Horses

M. Bullone, P. Hélie, P. Joubert, and J.-P. Lavoie

**Background:** Remodeling of the peripheral airways persists during the asymptomatic phase of heaves. Assessing the histology of large bronchi could facilitate the diagnosis of heaves during remission of the disease.

**Hypothesis:** Airway inflammation and remodeling in endobronchial biopsy (EBB) specimens differentiate horses with heaves from controls, independently of their clinical status (exacerbation or remission).

**Animals:** Fourteen healthy horses and 24 horses with heaves.

**Methods:** A 14-point scoring system assessing central bronchial wall inflammation and remodeling was developed. The score was validated by 2 pathologists using specimens obtained from 18 horses (6 controls, 6 with heaves exacerbation, and 6 with heaves remission) in which lung function had been assessed with impulse oscillometry. Clinical and research application of the score was evaluated using biopsy specimens obtained from 20 additional horses (8 controls, 6 with heaves exacerbation, and 6 with heaves remission).

**Results:** The score was repeatable (interclass correlation coefficient = 69%). It differentiated horses with heaves in exacerbation (mean  $\pm$  SD:  $6.2 \pm 2.2$ ) from those in remission ( $4.0 \pm 1.0$ ) and controls ( $3.6 \pm 1.7$ ,  $P < 0.0001$ ). The histological scores of horses with heaves correlated with the ratio of respiratory resistance ( $R$ ) at 5 and 10 Hz ( $R_5 : R_{10}$  ratio,  $r = 0.65$ ,  $P = 0.03$ ), a parameter assessing airway obstruction.

**Conclusions and Clinical Significance:** The proposed histological scoring system correlates with the degree of airway obstruction measured by impulse oscillometry. However, it does not discriminate horses with heaves in remission from controls. Evaluation of EBB specimens might be considered in future research and clinical studies of respiratory diseases in horses.

**Key words:** Airway; Equine asthma; Inflammation; Lung; RAO; remodeling.

Heaves is a chronic obstructive respiratory condition affecting adult horses. It is characterized clinically by periods of labored breathing at rest caused by airflow obstruction,<sup>1</sup> which results from bronchospasm, chronic pulmonary remodeling, and mucus obstruction in the airways.<sup>2</sup> Clinical signs are largely reversible with treatment. Bronchoalveolar lavage fluid (BALF) cytology discloses neutrophilic inflammation during episodes of disease exacerbation,<sup>3</sup> but completely normalizes (<5%) during periods of remission induced by strict

## Abbreviations:

ASM	airway smooth muscle
BALF	bronchoalveolar lavage fluid
C	control horses
EBB	endobronchial biopsy
ECM	extracellular matrix
ICC	intraclass correlation coefficient
IOS	impulse oscillometry system
HE	horses with heaves in exacerbation
HR	horses with heaves in clinical remission

From the Department of Clinical Sciences, (Bullone, Lavoie); Department of Pathology and Microbiology, Faculty of Veterinary Medicine, Université de Montréal, St-Hyacinthe, QC (Hélie); and the Institut Universitaire de Cardiologie et de Pneumologie de Québec, Université Laval, Québec, QC Canada (Joubert).

This work was performed at the Faculty of Veterinary Medicine of the Université de Montréal. Some of the samples analyzed in this study have been reported in a previous study investigating the physiological and technical variables affecting the quality of equine endobronchial biopsy samples (see reference 12).

Part of this work was presented by MB at the 32nd VCRS Symposium, Kennett Square, PA, October 27–29th, 2014.

Corresponding author: J.-P. Lavoie, Department of Clinical Sciences, Université de Montréal, 3200 rue Sicotte, St-Hyacinthe, QC J2S 2M2, Canada; e-mail: jean-pierre.lavoie@umontreal.ca.

Submitted November 24, 2015; Revised June 3, 2016; Accepted July 6, 2016.

Copyright © 2016 The Authors. Journal of Veterinary Internal Medicine published by Wiley Periodicals, Inc. on behalf of the American College of Veterinary Internal Medicine.

This is an open access article under the terms of the Creative Commons Attribution-Noncommercial License, which permits use, distribution and reproduction in any medium, provided the original work is properly cited and is not used for commercial purposes.

DOI: 10.1111/jvim.14556

antigen avoidance strategies.<sup>4,5</sup> Conversely, remodeling of the peripheral airways in heaves persists during disease remission,<sup>6</sup> and correlates with residual airflow obstruction.<sup>5,7</sup> Whether airway wall inflammation plays a role in perpetuating the disease during asymptomatic periods has not been studied, and could provide insights into heaves pathophysiology. The identification of specific variables of tissue inflammation or remodeling in endobronchial biopsy (EBB) specimens of affected horses could facilitate both diagnosing heaves during disease remission and monitoring the response to treatment.

Endobronchial biopsy yields bronchial samples that permit the assessment of bronchial surface epithelium, extracellular matrix (ECM), blood vessels, seromucous glands, and airway smooth muscle (ASM). Despite EBB having been used in respiratory research of horses for gene expression studies,<sup>8–11</sup> biopsy specimens are rarely evaluated histologically for inflammatory or remodeling features. However, specimens can be easily obtained, and would allow prospective studies to be performed in

both research and clinical settings. Recently, we have developed a detailed protocol for EBB sampling and morphometrical analysis.<sup>12</sup> During that study, and using histomorphometric techniques, we described histopathological features characterizing EBB specimens of horses with heaves, which prompted us to develop a semiquantitative scoring system for rapid and clinically applicable bronchial tissue assessment. Of note, EBB provides information limited to the central airways, because peripheral airways cannot be reached using this procedure, and sampling of peripheral airways requires transcutaneous or thoracoscopic methods. We hypothesized that using this score we could differentiate horses with heaves from controls, independently of the clinical state of the disease (exacerbation or remission). The aims of this study were: (1) to develop and validate a semiquantitative scoring system for evaluating bronchial inflammation and remodeling in EBB specimens from horses, (2) to assess its correlation with airway obstruction, and (3) to estimate cut-off values of the score for differentiating healthy from heaves-affected animals.

## Materials and Methods

### Study Design

**Phase 1.** Previously obtained EBB specimens<sup>12</sup> from 6 horses with heaves in exacerbation, 6 horses with heaves in remission of the disease, and 6 controls were scored by 2 board-certified pathologists (PH, PJ) to assess agreement. The correlation between the score of the board-certified veterinary pathologist and the lung function was studied to assess whether the score reliably assessed the degree of remodeling and inflammation leading to airflow obstruction.

**Phase 2.** Clinical application of the score. Tissues from 20 additional horses (8 controls, 6 horses with heaves in exacerbation and 6 in remission) were obtained from the Equine Respiratory Tissue Bank (<http://www.btre.ca>). They were scored by the board-certified veterinary pathologist and, together with the EBB specimens described in phase 1, were used for investigating the effect of environment on the score, the ability of the score to differentiate healthy and heaves-affected horses, and for calculating cut-off values for the groups.

**Phase 3.** Use of the score in research settings. To verify the potential application of this score in a research setting, an internist (JPL) and a postgraduate student (MB) experienced at evaluating lung histological remodeling features associated with heaves were asked to score the EBB specimens, and their results were compared with those obtained by the board-certified veterinary pathologist.

### Animals

Twenty-four horses with a diagnosis of heaves belonging to the research herd of the Respiratory Cellular and Molecular Biology Laboratory and 14 healthy horses from the teaching herd of the Faculty of veterinary medicine of the Université de Montréal were studied.

**Phase 1.** Score development and validation. The characteristics of the horses studied in this phase and the experimental protocol have been described previously.<sup>12</sup> Briefly, horses were exposed to hay (6 horses with heaves in exacerbation and 6 controls) or kept at pasture for 2 weeks and treated with dexamethasone (0.06 mg/kg PO q24 h, 6 horses with heaves in remission) for 1 week before

EBB specimens were obtained. Impulse oscillometry system (IOS) testing was performed on these horses before bronchoscopy using the Equine MasterScreen IOS system<sup>a</sup> and FAMOS software,<sup>b</sup> as previously described.<sup>12,13</sup> Bronchoscopies were performed on sedated animals (detomidine/butorphanol 0.01/0.015 mg/kg IV). Six EBB specimens were obtained from previously selected sites within 1 randomly chosen lung of each animal, in the absence of bronchodilator pretreatment (Buscopan<sup>c</sup>). All procedures performed on the horses were approved by the local Animal Ethics Committee (Rech-1324).

**Phase 2.** Among the 20 horses included in this phase of the study, 8 were controls kept stabled (EBB specimens also were available after 4 months at pasture for 5 of these horses, and were used to investigate the effect of the environment on the score) and 12 were horses with heaves. Among the horses with heaves, 6 were in exacerbation and 6 were in clinical remission (they were all kept stabled for >4 weeks, with horses in remission receiving dexamethasone at 0.06 mg/kg PO q24 h for 2 weeks before EBB). Lung function data obtained by impulse oscillometry were not available for these horses. Three to 4 EBB specimens were obtained from unspecified sites of 1 lung for each animal.

### Endobronchial Biopsies

Endobronchial biopsy specimens were harvested using smooth oval<sup>d</sup> (3/6 EBB specimens per horse) or alligator jaw<sup>e</sup> (3/6 EBB specimens per horse) forceps in phase 1. Smooth forceps were used instead in phase 2 and 3. A single biopsy instrument was used to obtain EBB specimens from 5 to 8 animals, because this procedure was shown previously not to alter sample quality or size in horses.<sup>12</sup>

### Histology Processing

Endobronchial biopsy specimens were fixed for 24 h in 10% neutral-buffered formalin and then embedded in paraffin. Two consecutive histologic sections of 5- $\mu$ m thickness were obtained from each biopsy specimen and stained with hematoxylin-eosin-phloxine-saffron and modified Russell-Movat's pentachrome.<sup>14</sup>

### Scoring System

A standardized 14-point semiquantitative grading score was developed taking into account histological features thought to be important in heaves. The presence and severity of remodeling and inflammation at the level of bronchial epithelium, lamina propria, and smooth muscle layer were assessed. Figure 1 describes the variables studied and their scoring. Before performing the study, the board-certified veterinary pathologist, the internist, and the postgraduate student were provided with a list of the variables to be evaluated in the score (epithelial hyperplasia, epithelial inflammation, epithelial desquamation, goblet cell hyperplasia, thickening of the basal membrane, submucosal inflammation, presence of mucus glands within the lamina propria and among smooth muscle bundles, ASM fibrosis, and whether the adventitial border of the ASM layer was visible) and were asked to choose the biopsy specimen considered to be of best quality from those available for each horse. This step allowed the operators to familiarize themselves with the variability in the variables to be assessed in these samples. The biopsy specimens chosen by the board-certified veterinary pathologist (1 for each horse) were those used for subsequent blinded analysis. In phase 1 of the study, operators also were asked to monitor the time needed for scoring the biopsy specimens and to make a presumptive diagnosis based on EBB findings (heaves versus control).

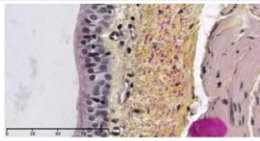
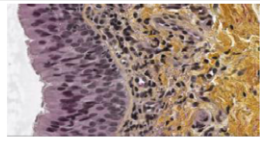
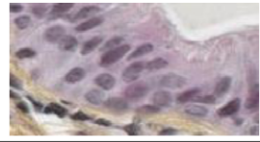
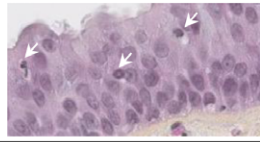
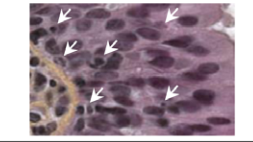
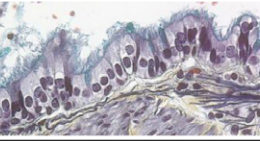
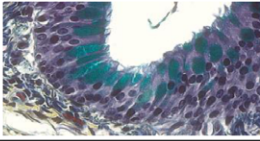
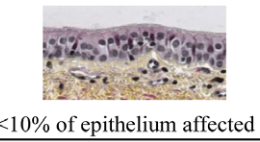
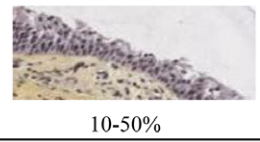
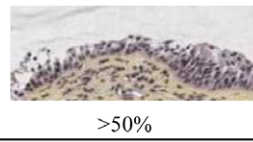
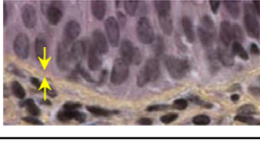

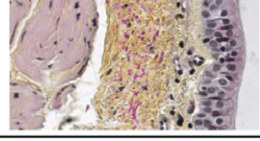
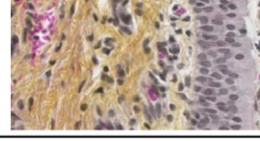
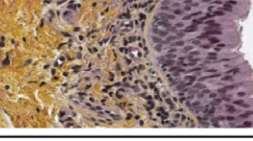
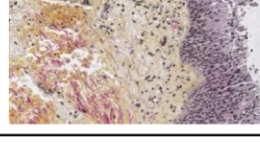
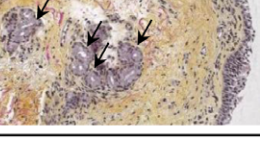
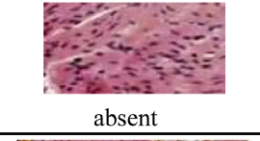
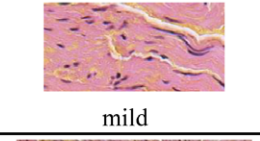
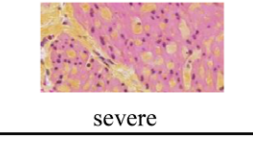
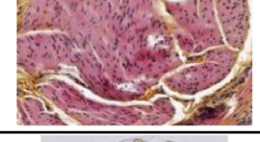
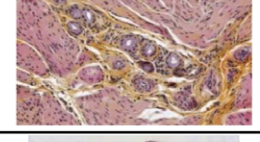
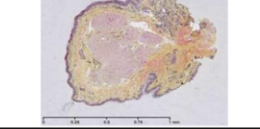
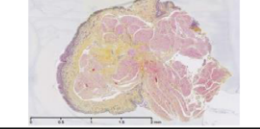
Parameter assessed	Possible values		
	0	1	2
<b>Hyperplasia</b>			-
<b>E P I T H E L I U M</b> <b>Inflammatory infiltrate</b>			
<b>Goblet cells hyperplasia</b>			-
<b>Desquamation</b>	 <10% of epithelium affected	 10-50%	 >50%
<b>Thickened BM</b>			-
<b>E C M</b> <b>Submucosal inflammatory cells</b>			
<b>Mucous glands</b>			-
<b>Fibrosis</b>	 absent	 mild	 severe
<b>A S M</b> <b>Mucous glands</b>			-
<b>ASM ending visible</b>			-

Fig 1. Histological variables assessed with the score.

**Statistical Analysis**

Concordance between operators was evaluated using the Cohen's Kappa test (phase I) and with the interclass correlation

coefficient (ICC) (phase III). The Spearman test was used for correlating scores and lung function results.

The effect of the environment on the score was assessed on the EBB specimens obtained from 5 control horses while stabled

(>4 weeks) or at pasture (>3 months), using 2-tailed paired Wilcoxon sign-ranked tests. Of these EBB specimens, only those obtained during stabling were included in the subsequent analysis. Also, the scores of the biopsy specimens of 12 horses with heaves in remission (6 kept stabled [phase II] and 6 kept at pasture [phase I], all treated with dexamethasone for 1–2 weeks) were compared to assess the effect of the environment in horses with heaves using 2 tailed Mann–Whitney  $U$  tests. Differences among the scores of the 3 groups of horses (heaves exacerbation, heaves remission, and controls) were evaluated using 1-way ANOVA and Tukey's post-hoc test. Sensitivity and specificity of the test for diagnosing heaves were calculated for different cut-off values. The Cochran–Mantel–Haenszel test with Bonferroni correction for multiple comparisons was used to identify the variables of the score better differentiating horses with heaves during exacerbation or remission of the disease, and the group of horses with heaves in remission from the controls. The Bland–Altman test was employed to calculate any significant bias between the operators.

## Results

### Phase 1 – Score Development and Validation

**Agreement.** The agreement between the 2 pathologists for scoring the same biopsy specimen was moderate (weighted  $\kappa = 0.52$ ). For each biopsy specimen, the time needed for performing the score varied from 45 seconds to 3 minutes for both pathologists (1.5 min/biopsy on average).

**Correlation Between Scores and Lung Function.** All IOS data at 5 and 10 Hz had coherence values above 0.95. The scores were significantly correlated with  $R_5 : R_{10}$  ( $r = 0.65$ ,  $P = 0.03$ ) and with the expiratory resonant frequency ( $r = 0.87$ ,  $P = 0.009$ ) in horses with heaves (Fig 2). No significant correlation was observed between  $R_5 : R_{10}$  ( $r = 0.8$ ,  $P = 0.13$ ) or the expiratory resonant frequency ( $r = 0.69$ ,  $P = 0.14$ ) and the biopsy score of control horses.

### Phase 2 – Clinical Application of the Score

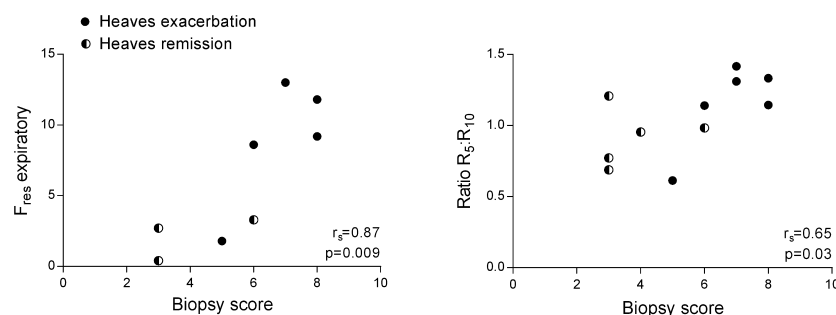
**Effect of the Environment.** The biopsy score was not affected by the environment in control horses (score of  $3.4 \pm 2.3$  [mean  $\pm$  SD] at pasture and of  $4 \pm 1.9$  when stabled,  $P = 0.75$ ) or in horses with heaves in remission ( $3.7 \pm 1.2$  at pasture and  $4.3 \pm 0.8$  when stabled,  $P = 0.19$ ). When the inflammatory variables were

analyzed separately, no difference was observed in epithelial ( $P = 0.62$ ) or submucosal infiltrate ( $P = 0.37$ ) in healthy horses kept at pasture or stabled (fed hay and bedded on shavings, Fig 3A). Horses with heaves in remission kept in both environments also had a similar degree of submucosal and epithelial inflammation ( $P = 0.24$ , Fig 3B).

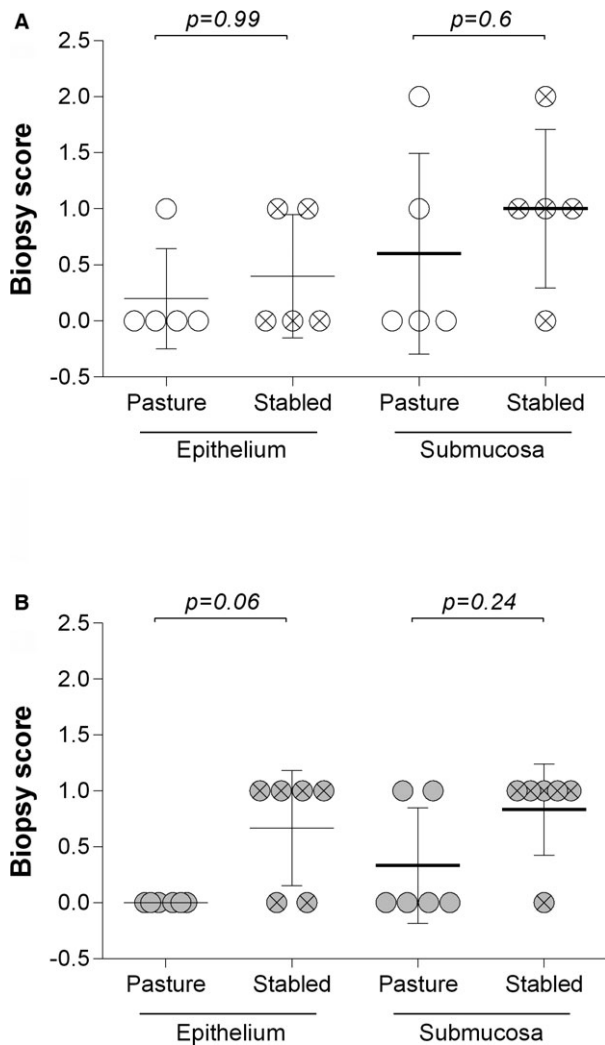
**Histological Scores.** The scores were significantly different among groups ( $P = 0.001$ , Fig 4A). The scores of horses with heaves in exacerbation were significantly higher compared to those of horses with heaves in remission and controls ( $P = 0.01$  and  $P = 0.002$ , respectively). No difference was observed between the scores of horses with heaves in remission and controls ( $P = 0.8$ ). A score  $\geq 5$  could differentiate a horse with heaves (in exacerbation or remission) from a control with a sensitivity of 54.2% and a specificity of 79%. A score  $\geq 5$  allowed identification of horses with heaves in exacerbation compared to controls and horses with heaves in remission with 83.3% sensitivity and 77.4% specificity. The variables of the score better differentiating horses with heaves in exacerbation from those in remission were the epithelial ( $P = 0.02$ ) and submucosal inflammatory infiltrate ( $P = 0.005$ ). None of the variables studied could differentiate horses with heaves in remission from controls (Table 1 and Fig S1 in the online supporting information).

### Phase 3 – Use of the Score in Research Settings

There was moderate agreement between the board-certified pathologist and the internist (weighted  $\kappa$ , 0.44), and with the postgraduate student (weighted  $\kappa$ , 0.45). The ICC for the 3 observers was 69%, indicating that the level of concordance among the 3 observers was good, although a significant difference was observed among the scores of the 3 operators (analysis of variance  $F_{2,38} = 5.17$ ,  $P < 0.01$ ). The observed difference was ascribed to the fact that, based on the Bland–Altman test results, the internist tended to slightly overestimate lower scores and underestimate higher scores compared to the pathologist (slope significantly  $>0$ ,  $P = 0.02$ , with a mean bias of 0.37), whereas the student tended to overestimate higher scores compared to the pathologist (slope significantly  $<0$ ,  $P = 0.005$ , with a



**Fig 2.** Correlation between biopsy score and variables of airway obstruction measured with impulse oscillometry system.  $F_{res}$ : resonant frequency;  $R_5$ ,  $R_{10}$ : respiratory resistance at 5 or 10 Hz; Left panel: values of 4 horses are missing as their reactance curves did not cross the  $x$  axis.



**Fig 3.** Effect of the environment on epithelial and subepithelial inflammation. (A) Endobronchial biopsy (EBB) were obtained from the same control horses while at pasture and after 30 days of stabling. Paired Wilcoxon signed-rank test was used for statistical analysis. (B) EBB were obtained from 12 horses with heaves in which remission was induced by dexamethasone treatment administered for 1 week with horses at pasture ( $n = 6$ ) or for 2 weeks with the horses kept stabled and fed hay ( $n = 6$ ). Mann-Whitney  $U$  test was used for statistical analysis. Bars indicate SD.

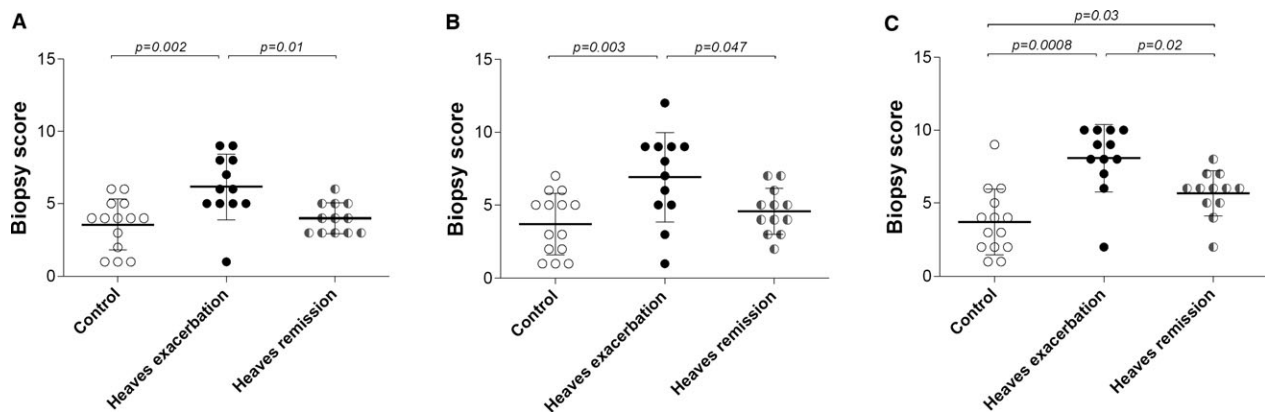
mean bias of  $-1.02$ ). Nevertheless, the scores of all operators were significantly higher for the group of horses with heaves in exacerbation compared to horses with heaves in remission or controls (Fig 4B, C).

## Discussion

Horses with heaves are clinically asymptomatic during periods of remission of the disease and BALF cytology also normalizes when they are kept at pasture. Peripheral airway wall inflammation has been reported to be unaffected by the clinical status of the disease,<sup>5</sup> and peripheral remodeling in only partly decreased during disease remission. Sampling the peripheral airways, however, requires invasive procedures not practical in

clinical settings. Conversely, large airways can be sampled easily by EBB in horses. The effect of heaves treatments on central airway inflammation and remodeling has not been described to date. If the effects of treatment were similar in central and peripheral airways, assessing central airway remodeling could permit the diagnosis of heaves during disease remission. Using a scoring system for the assessment of inflammatory and remodeling variables of the large airway wall, we determined that bronchial inflammation differs significantly between periods of exacerbation and remission of heaves, but not between the asymptomatic phases of heaves and the healthy subjects. Our score was repeatable and it significantly correlated with lung function in horses with heaves, providing a reliable measure of bronchial obstruction in this group of horses. Although the score could not differentiate horses with heaves in remission from controls, its implementation in clinical practice and in research settings may increase the awareness of central airway alterations associated with heaves, and future studies may highlight their possible prognostic value.

Epithelial and subepithelial inflammation were important variables differentiating horses with heaves in exacerbation from horses with heaves in remission and controls in our study. This finding emphasizes the involvement of large airway inflammation in the pathophysiology of heaves. Interestingly, although we have shown a decrease in central airway inflammation after short-term treatment, no changes were observed in the extent of inflammation of peripheral airways after 6 or 12 months of antigen avoidance, inhaled corticosteroid treatment, or both in a group of horses with heaves.<sup>5</sup> Whether this finding was a result of intrinsic differences in small airway compared to large airway physiology or to the inability of inhaled treatments to reach the most distal sites remains unclear. This finding also suggests that large airway inflammation in heaves is intermittent, occurring only during exacerbation of the disease, when it possibly could drive the appearance of overt bronchospasm, increasing airway obstruction and pulmonary resistance. Conversely, small airway wall inflammation persists even during heaves remission, perhaps acting as an active site for disease maintenance or progression. Contrary with what we hypothesized, significant differences in the bronchial inflammatory infiltrate or morphology of horses with heaves in remission and controls were not observed. Because stabling increases lung inflammation in BALF in otherwise healthy horses,<sup>4,6</sup> we compared the scores of horses with heaves in remission and controls whereas at pasture versus stabled. Unexpectedly, neither the score nor the extent of inflammation in healthy horses was significantly affected by environment. With regard to the horses with heaves in remission, the environment did not affect the biopsy total score, but those kept stabled tended to have higher epithelial inflammation compared to those kept at pasture. This finding may indicate an altered immune regulatory function of the airway epithelium in horses with heaves, which is supported by previous studies.<sup>8,15</sup>



**Fig 4.** Effect of the group on the histologic scores. Results of the board-certified pathologist (A), of the specialist in internal medicine (B), and of the postgraduate student (C). Analysis was performed with 1-way ANOVA with Tukey's post-tests. Bars represent SD. It has to be noticed that the operators in B and C had at least a 3-year experience at evaluating pulmonary remodeling in the horse.

**Table 1.** Differences among groups for individual variables of the score.

Parameter	ANOVA	P value		Direction of the Effect (Post-Test)
		Post-Test HE Versus HR	Post-Test HR Versus C	
Epithelium				
Hyperplasia	<b>0.009</b>	0.06	0.29	HE ≥ HR
Inflammatory infiltrate	<b>0.02</b>	<b>0.02</b>	0.92	HE > HR
Goblet cells	<b>0.03</b>	0.56	0.04*	HR ≥ C
Desquamation	0.19	0.59	0.19	
Extracellular matrix				
Thickened BM	0.27	0.25	0.25	
Inflammatory infiltrate	<b>0.01</b>	<b>0.005</b>	0.98	HE > HR
Mucus glands	0.28	0.42	0.47	
ASM				
Fibrosis	0.29	0.16	0.60	
Mucus glands	0.09	0.14	0.03*	HR ≥ C
ASM ending visible	0.67	0.41	0.44	

ASM, airway smooth muscle; HE, heaves exacerbation; HR, heaves remission; C, controls.

The combined scores were used for statistical analysis. > indicates the direction of the effect when significant differences were observed between groups (*P* values in bold), whereas ≥ indicates the direction of the effect when only tendencies to significant differences were observed.

\*Nonsignificant after Bonferroni correction for multiple comparisons.

The contribution of the airway epithelium to the pathogenesis of heaves, however, remains ill-defined. Because of its proximity to the bronchial lumen and exposure to pro-inflammatory agents, the airway epithelium is likely affected by, and perhaps drives, the pathological process in heaves. Whether or not and how this translates into discernible histological changes is

unclear. The histology of large airways of horses suffering from heaves was described in the early 1990s.<sup>16</sup> The main differences observed between the 2 groups involved the bronchial epithelium, in which cellular infiltration by mononuclear leukocytes<sup>16</sup> and mast cells<sup>17</sup> was described. The inflammatory cells infiltrating the epithelial layer in our study were predominantly lymphocytes and neutrophils, but these finding should be confirmed using specific markers, at least for the mononuclear leukocytes. Nevertheless, these findings are in agreement with the paucity of epithelial eosinophils observed in heaves.<sup>18</sup> Whether mucus-producing cells are increased in the airways of horses with heaves compared with controls has been investigated both in central and peripheral airways, with conflicting results.<sup>19–21</sup> In our study, epithelial goblet cells were increased in horses with heaves in exacerbation compared to controls. They also were increased in horses with heaves in remission compared to controls, but the difference was not significant after correction for multiple comparisons, possibly as a result of the short duration of antigen exposure. Notably, the environment in which horses with heaves in remission were kept (pasture versus stabling) did not affect any mucus-related variable of the score.

Both the ECM and smooth muscle mass are increased in the peripheral airways of horses with heaves.<sup>5,7</sup> However, whether the submucosal structures of the large airways of horses with heaves sustain histologic alterations as a consequence of the disease is not well-established. Endoscopic studies have observed a thickening of the tracheal septum and an increased tendency for central airway collapse in horses with heaves compared to controls.<sup>22,23</sup> An increased thickness of the submucosal bronchial wall, most likely because of ASM hyperplasia, hypertrophy, or both also has been reported in central bronchial sections.<sup>24</sup> These findings suggest that the whole airway wall undergoes structural modifications, which alter its physical properties. We observed more prominent submucosal glands in horses with heaves during disease remission compared to controls, but the difference was not significant after

correction for multiple comparisons. This finding however integrates the results of previous work in which the submucosal glands in large airways were reported to be larger in horses with heaves than in controls, and significantly larger in horses with heaves in exacerbation compared to those in remission.<sup>21</sup> Together with the tissue inflammation, likely accompanied by edema of the bronchial wall, this finding could account for the increased thickness of the bronchial lamina propria observed in heaves.<sup>12</sup> Airway smooth muscle-related variables evaluated with the score could not reliably differentiate the groups that we studied. Based on our previously published findings,<sup>12</sup> the possibility that the size of airway carina or the type of forceps used for harvesting the biopsy specimen may have influenced our results (phase I) was considered. However, the distribution of biopsy specimens collected from small or large airway carinae using smooth oval or alligator jaw forceps was similar in the 3 groups studied (data not shown). Previous observations made on small airway remodeling<sup>5</sup> in heaves suggest that substantial reduction in ASM mass is unlikely to occur after only 2 weeks of treatment. However, the fact that EBB specimens are inadequate tools for reliable quantitative assessment of ASM in horses<sup>12</sup> could have accounted for our inability to detect morphological alterations likely present in the group of horses with heaves in remission compared to controls.

As previously reported, the horses studied during phase I underwent IOS testing before and after sedation.<sup>12</sup> The  $R_5 : R_{10}$  ratio has been validated previously as an indicator of airway obstruction in horses with heaves.<sup>25</sup> The resonant frequency indicates the frequency at which the inflation pressure and elastic recoil cancel out, resulting in a reactance equal to zero. It is considered a measure of airway obstruction in asthmatic patients.<sup>26</sup> In our study, the scores recorded by the board-certified pathologist correlated with airflow obstruction variables (namely  $R_5 : R_{10}$  ratio and expiratory resonant frequency) measured 15 minutes after sedation in horses with heaves, indicating that both airway remodeling and inflammation are important determinants of lung function. Importantly, IOS values of respiratory resistance at 5 and 10 Hz ( $R_5$  and  $R_{10}$ ) are not significantly affected by  $\alpha_2$ -agonist sedation in horses,<sup>27</sup> which justifies the use of postsedation IOS values in our study. Furthermore, the head was maintained in a standard position with an angle of approximately 90° during IOS under sedation, which further standardized our measurements. Sedation with  $\alpha_2$ -agonists has the additional advantage of dilating the airways in horses,<sup>28</sup> possibly emphasizing the remodeling and inflammatory (edema) components of obstruction at the expense of bronchospasm.

A limitation of the present study is the possibility that some of the horses used as controls might have had subclinical inflammation based on BALF cytology. However, our aim was to differentiate horses with heaves from horses without heaves, for which we believe our control horses were appropriate. Future studies should to characterize EBB scores in horses with inflammatory airway disease (IAD).

## Conclusions

The histological score that we developed is a reliable tool for the assessment of airflow obstruction caused by inflammation and remodeling of the large airways in horses with heaves. The semiquantitative assessment of the variables we studied was rapid and repeatable with minimum training by operators already familiar with bronchial histology. A score  $\geq 5$  allows differentiating horses with heaves from controls with a sensitivity of 54%, which increases to 83% if the horse has clinical signs. On the other hand, a horse with no clinical respiratory signs and a biopsy score  $< 5$  will be a healthy horse in 79% of instances. Although nonsignificant after correction for multiple comparisons, goblet cell hyperplasia and submucosal mucus gland hyperplasia and hypertrophy were the only variables that differentiated horses with heaves in remission from controls, warranting further investigation. The introduction of EBB specimen assessment in future prospective studies and possibly in clinical practice could facilitate the diagnosis of heaves in asymptomatic horses, identify mechanisms of respiratory diseases as well as elucidate the role and kinetics of large airway inflammation and remodeling.

---

## Footnotes

<sup>a</sup> LabManager version 4.53, Jaeger, Würzburg, Germany

<sup>b</sup> IMC, Meßsysteme, Berlin, Germany

<sup>c</sup> Buscopan™ injectable solution, Boehringer-Ingelheim, Germany

<sup>d</sup> FB-234U, Olympus, Richmond Hill, ON, Canada

<sup>e</sup> FB-214U, Olympus, Richmond Hill, ON, Canada

---

## References

1. Robinson NE. International Workshop on Equine Chronic Airway Disease. Michigan State University 16–18 June 2000. *Equine Vet J* 2001;33:5–19.
2. Herszberg B, Ramos-Barbon D, Tamaoka M, et al. Heaves, an asthma-like equine disease, involves airway smooth muscle remodeling. *J Allergy Clin Immunol* 2006;118:382–388.
3. Jean D, Vrins A, Beauchamp G, et al. Evaluation of variations in bronchoalveolar lavage fluid in horses with recurrent airway obstruction. *Am J Vet Res* 2011;72:838–842.
4. Tremblay GM, Ferland C, Lapointe JM, et al. Effect of stabilizing on bronchoalveolar cells obtained from normal and COPD horses. *Equine Vet J* 1993;25:194–197.
5. Leclere M, Lavoie-Lamoureux A, Joubert P, et al. Corticosteroids and antigen avoidance decrease airway smooth muscle mass in an equine asthma model. *Am J Respir Cell Mol Biol* 2012;47:589–596.
6. Leclere M, Lavoie-Lamoureux A, Gelin-Lymburner E, et al. Effect of antigenic exposure on airway smooth muscle remodeling in an equine model of chronic asthma. *Am J Respir Cell Mol Biol* 2011;45:181–187.
7. Setlakwe EL, Lemos KR, Lavoie-Lamoureux A, et al. Airway collagen and elastic fiber content correlates with lung function in equine heaves. *Am J Physiol Lung Cell Mol Physiol* 2014;307:L252–L260.

8. Ainsworth DM, Wagner B, Franchini M, et al. Time-dependent alterations in gene expression of interleukin-8 in the bronchial epithelium of horses with recurrent airway obstruction. *Am J Vet Res* 2006;67:669–677.
9. Padoan E, Ferrareso S, Pegolo S, et al. Real time RT-PCR analysis of inflammatory mediator expression in recurrent airway obstruction-affected horses. *Vet Immunol Immunopathol* 2013;156:190–199.
10. Riihimaki M, Raine A, Art T, et al. Partial divergence of cytokine mRNA expression in bronchial tissues compared to bronchoalveolar lavage cells in horses with recurrent airway obstruction. *Vet Immunol Immunopathol* 2008;122:256–264.
11. Riihimaki M, Raine A, Pourazar J, et al. Epithelial expression of mRNA and protein for IL-6, IL-10 and TNF-alpha in endobronchial biopsies in horses with recurrent airway obstruction. *BMC Vet Res* 2008;4:8.
12. Bullone M, Chevigny M, Allano M, et al. Technical and physiological determinants of airway smooth muscle mass in endobronchial biopsy samples of asthmatic horses. *J Appl Physiol* (1985) 2014;117:806–815.
13. Richard EA, Fortier GD, Denoix JM, et al. Influence of subclinical inflammatory airway disease on equine respiratory function evaluated by impulse oscillometry. *Equine Vet J* 2009;41:384–389.
14. Russell HK Jr. A modification of Movat's pentachrome stain. *Arch Pathol* 1972;94:187–191.
15. Ainsworth DM, Matychak M, Reyner CL, et al. Effects of in vitro exposure to hay dust on the gene expression of chemokines and cell-surface receptors in primary bronchial epithelial cell cultures established from horses with chronic recurrent airway obstruction. *Am J Vet Res* 2009;70:365–372.
16. Kaup FJ, Drommer W, Deegen E. Ultrastructural findings in horses with chronic obstructive pulmonary disease (COPD). I: Alterations of the larger conducting airways. *Equine Vet J* 1990;22:343–348.
17. Dacre KJ, McGorum BC, Marlin DJ, et al. Organic dust exposure increases mast cell tryptase in bronchoalveolar lavage fluid and airway epithelium of heaves horses. *Clin Exp Allergy* 2007;37:1809–1818.
18. Dubuc J, Lavoie JP. Airway wall eosinophilia is not a feature of equine heaves. *Vet J* 2014;202:387–389.
19. Bartner LR, Robinson NE, Kiupel M, et al. Persistent mucus accumulation: A consequence of delayed bronchial mucous cell apoptosis in RAO-affected horses? *Am J Physiol Lung Cell Mol Physiol* 2006;291:L602–L609.
20. Lugo J, Harkema JR, deFeijter-Rupp H, et al. Airway inflammation is associated with mucous cell metaplasia and increased intraepithelial stored mucosubstances in horses. *Vet J* 2006;172:293–301.
21. Williams A, Rousseau K, Lavoie JP, et al. Distribution of mucin producing cells in equine airways in healthy and RAO-diseased horses housed in dusty stable and open field environments. 13th International Congress of the World Equine Veterinary Association (WEVA), Budapest, Hungary, 2013.
22. Koblinger K, Hecker K, Nicol J, et al. Bronchial collapse during bronchoalveolar lavage in horses is an indicator of lung inflammation. *Equine Vet J* 2014;46:50–55.
23. Koblinger K, Nicol J, McDonald K, et al. Endoscopic assessment of airway inflammation in horses. *J Vet Intern Med* 2011;25:1118–1126.
24. Bullone M, Beauchamp G, Godbout M, et al. Endobronchial ultrasound reliably quantifies airway smooth muscle remodeling in an equine asthma model. *PLoS ONE* 2015;10:e0136284.
25. van Erck E, Votion DM, Kirschvink N, et al. Use of the impulse oscillometry system for testing pulmonary function during methacholine bronchoprovocation in horses. *Am J Vet Res* 2003;64:1414–1420.
26. Shi Y, Aledia AS, Tatavoosian AV, et al. Relating small airways to asthma control by using impulse oscillometry in children. *J Allergy Clin Immunol* 2012;129:671–678.
27. Klein C, Smith HJ, Reinhold P. The use of impulse oscillometry for separate analysis of inspiratory and expiratory impedance parameters in horses: Effects of sedation with xylazine. *Res Vet Sci* 2006;80:201–208.
28. Broadstone RV, Gray PR, Robinson NE, et al. Effects of xylazine on airway function in ponies with recurrent airway obstruction. *Am J Vet Res* 1992;53:1813–1817.

## Supporting Information

Additional Supporting Information may be found online in the supporting information tab for this article:

**Figure S1.** Effect of group (heaves exacerbation, heaves remission, or control) on each score parameter.