



# A clinical review of hand manifestations of cervical myelopathy, cervical radiculopathy, radial, ulnar, and median nerve neuropathies

Hamzeh Jajeh<sup>1</sup>, Anderson Lee<sup>2</sup>, Richy Charls<sup>2</sup>, Megan Coffin<sup>2</sup>, Ambika Sood<sup>2</sup>, Hossein Elgafy<sup>2</sup>

<sup>1</sup>Department of Specialty Medicine, Ohio University Heritage College of Osteopathic Medicine, Dublin, OH, USA; <sup>2</sup>Department of Orthopedic Surgery, University of Toledo College of Medicine and Life Sciences, Toledo, OH, USA

*Contributions:* (I) Conception and design: H Jajeh, A Lee, R Charls, H Elgafy; (II) Administrative support: H Elgafy; (III) Provision of study materials or patients: H Jajeh, A Lee, H Elgafy; (IV) Collection and assembly of data: H Jajeh, A Lee; (V) Data analysis and interpretation: H Jajeh, A Lee, R Charls, M Coffin, H Elgafy; (VI) Manuscript writing: All authors; (VII) Final approval of manuscript: All authors.

*Correspondence to:* Hamzeh Jajeh, BA. Department of Specialty Medicine, Ohio University Heritage College of Osteopathic Medicine, 6775 Bobcat Way, Dublin, OH 43016, USA. Email: hj265421@ohio.edu.

**Abstract:** Cervical spondylotic myelopathy (CSM) is defined as compression of the spinal cord in the neck, resulting in problems with fine motor skills, hand numbness, pain or stiffness of the neck, and difficulty walking due to loss of balance. Brachial plexus (BP) neuropathies arise due to compression to any distal branches arising from C5–T1, whereas cervical radiculopathy involves compression at the nerve root in the neck. Such conditions can present with variable degrees of musculoskeletal pain, weakness, sensory changes, and reflex changes. The pronounced convergence in symptomatic manifestation within these conditions can pose a formidable challenge to clinicians, particularly in primary care. Thus, the primary objective of this paper is to enhance clarity and distinction among these pathological conditions. This objective is pursued through comprehensive delineation of the dermatomal and myotomal distributions characteristic of each condition. Furthermore, a meticulous examination is undertaken to elucidate physical indicators and maneuvers that exhibit a notably high sensitivity in detecting these conditions. Accurate diagnosis and treatment of each nerve pathology is important as long-term spinal cord compression and its roots may result in permanent disability and severely impact one's quality of life. As such, this systematic review serves as a guide that aids clinicians in differentiating the aforementioned conditions based on anatomy, physical exam findings, and imaging studies. Furthermore, this study aims to outline common peripheral nerve neuropathies in the upper extremities and ways to mitigate these pathologies using the least to most invasive treatment modalities.

**Keywords:** Cervical; myelopathy; radiculopathy; peripheral neuropathies

Submitted Mar 24, 2023. Accepted for publication Nov 07, 2023. Published online Dec 25, 2023.

doi: 10.21037/jss-23-39

**View this article at:** <https://dx.doi.org/10.21037/jss-23-39>

## Introduction

Cervical myelopathy, radiculopathy, and brachial plexopathy all can present with musculoskeletal pain, weakness, sensory changes, and reflex changes. Sensory and motor presentation for cervical radiculopathy is limited to the

dermatome and myotome at which the cervical root is compressed. With brachial plexopathy, sensory and motor disturbances are diffuse and may involve various parts of the upper limb and hand, potentially multiple dermatomes and myotomes. Cervical myelopathy is similar to brachial

<sup>^</sup> ORCID: Hamzeh Jajeh, 0009-0005-4761-7037; Anderson Lee, 0000-0002-7854-7159.

**Table 1** Myotome and dermatome distributions of the cervical region

Nerve root	Motor	Sensory
C1	Upper cervical flexion	C1–C4 head distributions: - Angle of the mandible - External ear (posterior part) - Inframandibular region (submandibular triangle) - Occipital protuberance
C2	Upper cervical extension	Posterior half of skull
C3	Cervical lateral flexion	Superior neck, directly inferior to the mandible
C4	Shoulder girdle elevation	Above the clavicle, including upper shoulders and trapezius
C5	Shoulder abduction and elbow flexion	Below the clavicle, including lower shoulders bilaterally and medial biceps
C6	Wrist extension	Lateral aspect of forearms and thumbs
C7	Elbow extension	Middle triceps and mid-palm, including index and middle fingers
C8	Finger flexion	Medial triceps and medial palm, including ring and small fingers

plexopathy in that the clinical presentation of sensory and motor changes are diffuse and not limited to a dermatomal or a single myotome distribution. However, cervical myelopathy can affect the upper and lower limbs; lower limb involvement is more common and often presents as a gait abnormality. Furthermore, hyperreflexia, clonus, and a positive Babinski reflex may be present in cervical spondylotic myelopathy (CSM) (1).

### Cervical myelopathy

CSM is a spinal cord compression within the cervical spine (1). CSM most commonly presents in older adults with concomitant age-related progressive degenerative changes. Symptoms include neck pain, stiffness, reduced range of motion, hyperreflexia, hand and arm weakness, loss of fine motor control, and gait imbalance. Thus, the potential for varied clinical manifestations of CSM can often make it difficult for providers to diagnose and treat effectively (1). This review paper focuses on recognizing specific manifestations of CSM, briefly exploring related and similarly presenting pathologies, and emphasizing the importance of early intervention to halt disease progression.

### Anatomy of the cervical spine

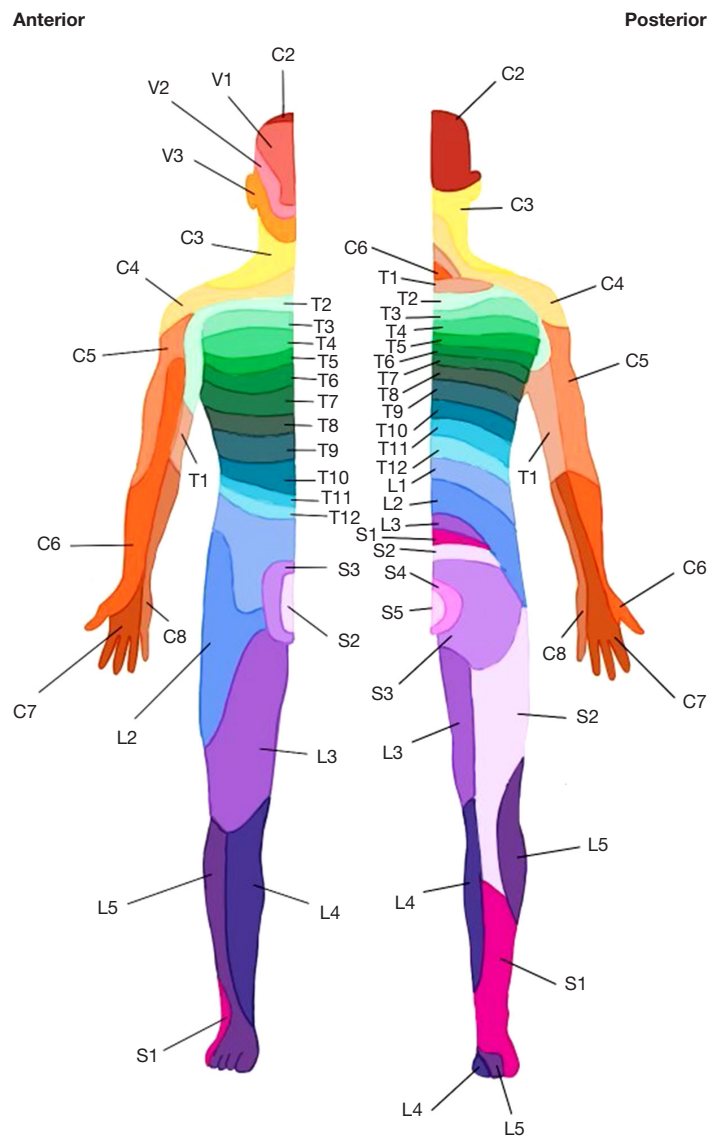
The cervical spine consists of 7 stacked vertebral bodies labeled C1 through C7. They provide the spinal cord

structure, stability, and flexibility at each level. Ventral and dorsal nerve roots arise from the spinal cord, exiting via bilateral intervertebral foramina. The ventral root provides signaling for efferent motor innervation, while the dorsal root transmits afferent sensory information. Spinal nerves within the cervical spine originate above their respective vertebra from C1 to C7, with a final C8 nerve pair exiting between the C7 and T1 intervertebral space. Following this transition point, the remainder of the nerves in the spinal cord are numbered and identified according to the superior vertebra (2).

Each cervical spinal nerve except C1 has a dermatome or area of skin where each spinal nerve provides sensory innervation. Every cervical spinal nerve also has a myotome, or muscles that are innervated by the spinal nerve; however, as there is significant overlap between adjacent spinal nerves in terms of sensation/motor function, these should only be interpreted as approximations and not concrete distributions (*Table 1* and *Figure 1*) (2).

### Etiology & pathophysiology

Cervical cord compression can be multifactorial in nature but by far the most common underlying factor is cervical spondylosis. The increased range of motion of the vertebral bodies at the C5–C7 levels increases the likelihood of degeneration, especially at these levels (1,3,4). However, other factors that would increase the risk of developing



**Figure 1** Illustration depicting the distribution of dermatomes and myotomes along the spinal cord. Dermatomes, representing distinct sensory regions, are demarcated on the body surface, each corresponding to a specific spinal nerve's sensory fibers. Myotomes, indicating muscle group innervation, are shown alongside the dermatomes.

CSM include congenital spinal stenosis, ossification of the ligamentum flavum, spondylolisthesis, exaggerated cervical kyphosis, and spinal cord tethering (4).

The hallmark of cervical spinal cord compression is the presence of cord ischemia. Ischemic changes generate an immune response, recruiting macrophages and microglia to the compressed area resulting in neuronal and oligodendroglial cell death via apoptosis in addition to the original hypoxic injury. The compounding effects of hypoxic and inflammatory changes to the cord lead to

neurologic dysfunction. The most involved tracts include the lateral corticospinal and spinocerebellar tracts, which impair voluntary movement and proprioception. In addition, the spinothalamic tract and posterior column may also be affected, causing a loss of vibrational and positional sensation (1,4).

#### *Diagnosis & clinical presentation*

Symptoms of CSM include a gradual loss of upper

**Table 2** Provocative tests and diagnostic signs of cervical myelopathy (8-10)

Sign	Test	Positive result	Sensitivity	Specificity
Babinski sign	The examiner strokes the sole of the foot with a blunt object, from the heel towards the toes	Upgoing toe sign of great toe	33%	92%
Hoffmann sign	The examiner lightly holds the patient's phalanx while flicking the middle finger's nail downward, enabling it to reflexively flick back upward	Quick flexion and adduction of the thumb and/or index finger on the same hand	44%	75%
Tromner sign	With the patient's hand positioned at the level of the proximal phalanges, the examiner taps the endmost phalanx of a relaxed finger, typically the middle finger, on its palmar side	Significant flexion in terminal phalanx that was tapped; flexion is very asymmetrical comparing both hands	45%	95%
Finger escape sign (9,10)	Patient is asked to extend and adduct their fingers and maintain that position for a minute	Small and ring fingers fall into flexion and abduction	55%	100%
Lhermitte sign	Ask patient to flex their neck	Shooting electric sensation traveling down the spine is felt	3%	97%
Crossed radial reflex	A bicep reflex test	Extension of both the wrist and biceps	44%	71%
Inverted radial reflex	Tapping of the brachioradialis	Finger flexion and wrist extension	61%	78%
Grip test	Patient is asked to make a fist as if they are about to grip an object	Weakness or inability to make a tight fist	38–56%	80–92%
Gait abnormality	The examiner asks the patient to walk and the clinician observes gait from different angles	Wide based gait, spastic gait, or ataxia are observed	19%	94%

extremity fine motor function. Specific examples of fine motor dysfunction are difficulty with keyboard typing, writing, buttoning up a dress shirt, or using house keys (5,6). Myelopathy and radiculopathy can often occur in conjunction with one another. However, when comparing CSM to radiculopathy, pain is not commonly an early symptom; therefore, patients may not be properly diagnosed until their myelopathy becomes severe. The upper extremities are more predominantly affected compared to the lower extremities. One constellation of symptoms includes the “myelopathy hand” in which patients have a positive finger escape sign, grip and release test, and intrinsic hand muscle wasting (5). At the level of C2–C4, the hyperactive pectoralis reflex test is highly sensitive and specific to CSM. Other positive exam signs are the Hoffman sign and posterior inverted radial reflex. Changes in proprioception, pain, temperature, and sensation due to compression of the various spinal tracts can also be present upon presentation (5).

Compressions of the spinal cord in CSM may cause bladder spasticity and urinary retention. Such CNS manifestations are unique to CSM and are absent in cervical radiculopathy. CSM becomes more likely when the following clusters are present: gait deviation (wide-based

gait, and spastic gait), positive Hoffman's sign, positive inverted radial/supinator sign, and positive Babinski reflex. If three symptoms are present, the positive likelihood ratio (LR) for CSM is 30.9 *vs.* 0.18 when one symptom is present (7).

### *Provocative tests & diagnostic signs*

Provocative tests that may indicate signs of CSM are shown in *Table 2* (8-10). While positive findings with these tests strongly suggest cervical myelopathy, they are not definitive diagnostic. Further radiographic evaluation should be performed to elucidate compressed areas and guide surgical planning. X-rays may show degenerated vertebral facet joints, osteophytes, disc degeneration, and decreased sagittal spinal canal diameter. Magnetic resonance imaging (MRI) without contrast should be obtained due to its higher accuracy in comparison to computed tomography (CT) for diagnosis due to the excellent ability of the MRI to visualize spinal cord compression (5,6). Nonetheless, CT scans may be useful for identifying ossification of the posterior longitudinal ligament (OPLL), in patients with contraindications to MRI imaging (thus obtaining a CT myelogram), or in patients with prior spinal hardware to

**Table 3** Radiculopathy symptoms based on level of cervical spine affected

Root	Symptoms
C2	Temporal pain, occipital headaches
C3	Pain at neck and trapezius
C4	Trapezius and lower neck pain, cape distribution of sensory loss
C5	Pain at lateral arm, neck and shoulder; loss of biceps reflex, loss of motor function in deltoid and elbow flexion
C6	Pain at posterior arm, neck, and thumb; loss of brachioradialis reflex, loss of motor function in biceps and wrist extension
C7	Pain at middle finger, loss of triceps reflex, loss of motor function in triceps and wrist flexion
C8	Pain in ring and pinky fingers, loss of motor control in finger flexors

evaluate the quality of fusion mass/bony defects. Other diagnostic modalities such as electrophysiological studies or nerve conduction studies (NCS) are mainly used as rule-out tests for other similarly presenting pathologies but are secondary in importance to the aforementioned imaging (5). Neurological exam and radiographic findings are key in diagnosing CSM (6,7).

### Cervical radiculopathy

Cervical radiculopathy is compression or injury to the nerve root as it exits the spine at the neural foramen. It affects around 85 in 100,000 individuals in the United States (11). Causes include disc herniation, cervical spondylosis, spinal tumors, cysts, or tortuous arteries. The location of pain and symptoms can be widely different between individuals based on the location of the compression (11). Although this topic has been researched, few contrast it with myelopathy and peripheral neuropathies in one review.

#### *Etiology & pathophysiology*

Any pathology that compresses or stretches the nerve root will impair nerve function. Foraminal disc prolapse, uncovertebral joint osteophytes or hypertrophy of the facet joints result in nerve root compression (10,12).

#### *Diagnosis & clinical presentation*

The clinical presentation of cervical radiculopathy is neck and radicular arm pain with or without impaired neurologic function. Symptoms are most commonly unilateral, with radiation to the ipsilateral side of the impacted nerve root. Signs and symptoms may depend on the level of the cervical spine affected and are listed in (Table 3) (12). Pain and

sensory or motor deficits may present similarly to other conditions and peripheral neuropathies, such as carpal tunnel syndrome (CTS).

Radicular pain can be elicited by maneuvers that stretch the impacted nerve root, including sneezing, coughing, and the Valsalva maneuver (13). Spurling's test, in which the patient's neck is extended and laterally flexed and externally rotated to the affected side, can narrow the neural foramen and produce symptoms. This test is specific but not sensitive to cervical radiculopathy and can help rule out peripheral nerve entrapment. Another physical exam maneuver, the Bakody test (shoulder abduction sign), assesses cervical radiculopathy involves the patient abducting the shoulder to 90°, flexing the elbow, and placing the palm on top of or behind the head. The test is positive if the patient describes relief of the radicular pain due to relief of compression on the affected nerve roots (8,12). Compared with the classical radicular signs, brachial plexus (BP) involvement is highly sensitive and reasonably specific in detecting mechanical lesions around the cervical spine and may suggest radicular involvement (13).

Clinical presentation suspicious for cervical radiculopathy may warrant further imaging and diagnostic studies. Imaging techniques include plain radiographs, MRI, CT, myelography and NCS. Plain radiographs may reveal osteophyte formation, narrowing of the neural foramen, or decreased disk height. MRI is best for evaluating disc herniations and nerve root compression, while CT scans can help visualize the pathology causing compression of the spinal cord or nerve roots such as OPLL (12). NCS assess potential isolated or concomitant diagnoses of peripheral neuropathy. Any imaging study that is performed may result in false positives or false negatives and should be read within the context of clinical presentation to establish an accurate diagnosis.

## Upper extremity peripheral neuropathies

BP damage can present with peripheral neuropathy that may share certain features similar to the clinical presentation of CSM and/or cervical radiculopathy. In some cases, peripheral nerve entrapment may cooccur with cervical radiculopathy, a phenomenon known as “double crush” (12). As such, limited research assesses all of these conditions at once. Worldwide, there is a discrepancy in documenting upper limb musculoskeletal disorders that is largely explained by the absence of a universally accepted way of labeling or defining them (14). However, work-related injuries have been computed, and the prevalence of upper limb disorders among workers ranged from 12.3% to 75.9%, with an overall prevalence of 45.4% (15). The incidence rate of upper limb disorders ranged from 0.24 to 11.8 per 100 person-years, with an overall incidence rate of 2.8 per 100 person-years (15).

## BP disturbances

In athletes, up to 50% of players may experience a “burner” or “stinger” injury, which can occur during contact sports, especially football. The injury results from a strong impact that pushes the shoulder downward while the athlete’s neck is twisted and bent to the opposite side. Other causes include traumatic motor vehicle injuries, thoracic outlet syndrome, intraoperative positioning, primary or metastatic cancers (such as lung or breast cancer), inflammatory processes like Parsonage-Turner syndrome, idiopathic brachial neuritis, or radiation therapy. Birth-related trauma, blunt force, or penetrating wounds are other potential causes (16). Damage to all roots is more common than isolated C5–C6 or C8, T1 or lower injuries (16).

Clinical presentation can vary depending on the specific injury. Football players often experience acute episodes of circumferential paresthesia that lasts for minutes, affecting the upper and middle trunks of the BP (C5–C7). Lower trunk injuries (C8–T1) may result in Horner syndrome. MRI, NCS, and electromyography (EMG) may be helpful for further localization or determining the underlying cause (16).

## Radial nerve anatomy

The radial nerve emerges from the posterior cord of the BP and is formed by spinal roots C5–T1. The radial nerve travels along the triangular interval, situated alongside the

deep brachial artery and vein, on the extensor surface of the upper arm. It continues its path downward within the radial (spiral) groove giving rise to the posterior cutaneous nerve and inferior lateral cutaneous nerve (17). It also passes through the lateral intermuscular septum of the arm to enter the anterior compartment of the forearm between brachialis and brachioradialis (17). After passing over the lateral epicondyle, the nerve then traverses through the radial tunnel in the cubital fossa giving off muscular branches and the posterior cutaneous nerve of the forearm. Motor innervation of the radial nerve include muscles of the posterior compartment of the arm (triceps brachii and anconeus muscles), the lateral part of the brachialis muscle, and posterior compartment of the forearm (18). Sensory innervation of the radial nerve includes the radial 2/3 of the dorsal aspect of the hand, the dorsal aspect of the radial 3 1/2 fingers (except the distal and middle phalanges of these digits), and the autonomous sensory zone: 1<sup>st</sup> web space (between the thumb and index finger) (18).

## Etiology of radial nerve neuropathy

Repetitive compression, traction, or direct trauma the axilla, mid-arm, or elbow will present with signs and symptoms of radial nerve neuropathy (*Table 4*) (18). Radial nerve injury is common in humeral shaft fractures and fails to recover spontaneously in 30% of cases (19). Improper crutch usage has been well documented to damage the radial nerve. Poor body weight distribution while using the crutches may load the axilla with compressive forces, resulting in numbness and tingling in the structures below the axilla. Patient positioning that may cause radial nerve neuropathy includes Saturday night palsy which results from compression of the radial nerve at the axilla or proximal arm due to excessive arm draping over a firm piece of furniture and is often associated with intoxication (20). Honeymoon palsy is similar to Saturday night palsy, which involves pressure on the axilla or upper medial arm. Still, honeymoon palsy refers to an individual falling asleep on another person’s arm and consequently compressing the axilla (20). Distally, the superficial radial nerve compression can occur due to cheiralgia paresthetica, otherwise known as handcuff or wristwatch neuropathy; however, this results in only a sensory deficit to the dorsum of the hand.

Radial tunnel syndrome (RTS) is regarded by some as a controversial diagnosis and is characterized by lateral elbow and dorsal forearm pain that may radiate to the wrist and dorsum of the fingers often without symptoms of



**Table 4** Radial nerve injury presentations

Location	Sensory deficits	Motor deficits	Etiology
Axilla	Structures below axilla	Structures below axilla & triceps paralysis if radial nerve is injured	Improper crutch use
Mid-arm (spiral groove)	Everything under & numbness, paresthesia, pain along lateral posterior arm <sup>†</sup>	Structures below axilla & wrist drop	Humeral fracture, Saturday night palsy, honeymoon palsy
Elbow (radial tunnel)	Pain with extension or repetitive pronation/supination	Occasional weakness of extension and supination, secondary to pain	Radial tunnel syndrome, compression within the tunnel
PIN	None	Paralysis of the finger extensors (not a true wrist drop)	Radial head fracture or chronic soft tissue compression
Superficial forearm and wrist	Radial side of the dorsum of the hand numbness (thumb, index finger, and the radial half of middle finger)	None	Cheiralgia paresthetica due tight wrist compression, repetitive supination and pronation

<sup>†</sup>, does not occur in midshaft humerus fracture. PIN, posterior interosseous nerve.

nerve palsy (e.g., weakness, sensory deficits, paresthesias). The source of pain could result from compression at five different locations of which the arcade of Frohse is the most common (21).

### Diagnosis

Radial nerve palsy presents with wrist drop; however, entrapment of the radial nerve will present as weakness in wrist extension. Wrist drop occurs due to the flexor tone overpowering nonfunctional wrist extensors, forcing the hand into a flexed position (18). The wrist may be passively placed into extension, but the patient cannot hold this posture, and the hand cannot be maintained in a functional position. In addition, extension of the fingers and thumb is lost, and patients lose their ability to grip objects. If the lesion is distal to the origin of the posterior interosseous nerve (PIN), extensor carpi radialis longus muscle function will be intact and the wrist will be pulled into radial deviation with attempts at extension (18).

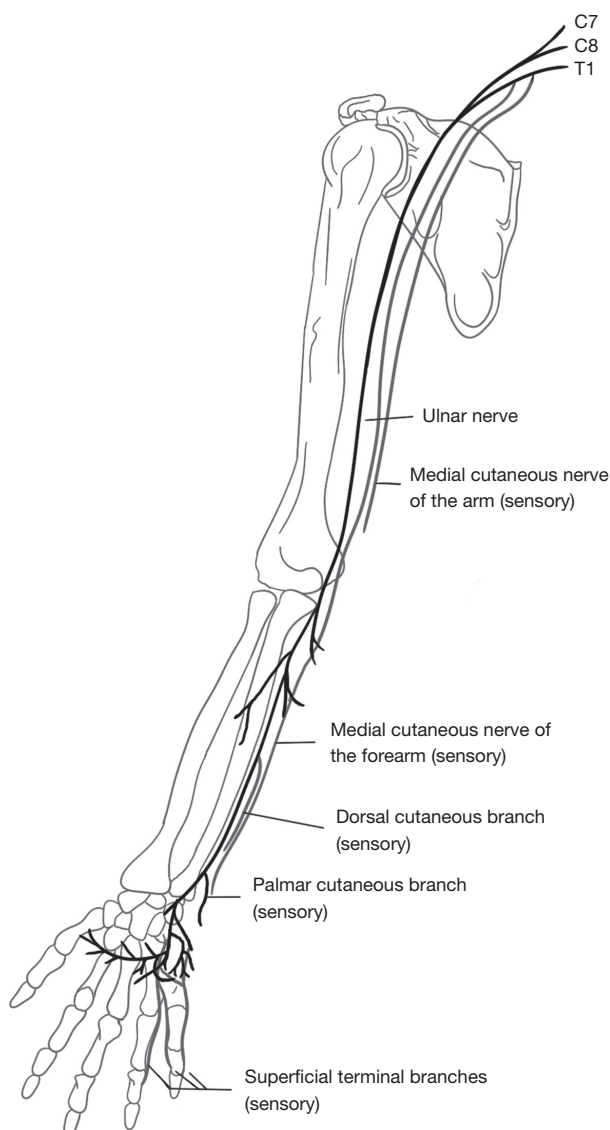
Findings of decreased sensation over the dorsoradial aspect of the forearm or hand help establish the diagnosis. Straining the radial nerve commonly occurs when the wrist is flexed, there's ulnar deviation, or pronation. These actions can frequently recreate or worsen symptoms. Additionally, exerting resistance while extending the middle finger with the elbow extended serves as an indicator of nerve entrapment. This diagnostic sign is commonly employed to identify lateral epicondylitis, yet it also frequently yields positive results in instances of radial nerve entrapment observed in radial tunnel conditions. The Tinel's test is a sign that can differentiate radial mononeuropathy from

myelopathy or radiculopathy. Percussing the radial nerve at possible areas of compression in the upper extremity such as the spiral groove of the upper arm or as it is exiting the deep fascia of the forearm will elicit symptoms of paresthesias, numbness, tingling, or pain (22).

Radiculopathy would present with a positive Spurling's maneuver. It is important to differentiate radial neuropathy from myelopathy and radiculopathy by understanding the specific innervations of the radial nerve itself. For example, a common presentation can be wrist and finger extension weakness, localized to a C7 radiculopathy or radial nerve mononeuropathy, especially the PIN. Entrapment of the PIN branch does not cause sensory changes, and the triceps and wrist flexors are not affected. In C7 radiculopathy, the triceps reflex may be diminished or absent (1). Furthermore, weakness in flexion of the brachioradialis, absent or diminished brachioradialis reflex, and paresthesias in the first dorsal webspace are findings characteristic of radial neuropathy, C7 radiculopathy would feature unique involvement of the wrist pronators and flexors, various shoulder movements, and third digit paresthesias (22).

### Treatment

The Sunderland classification for first- and second-degree radial nerve injuries include: mild neurapraxia, compromised myelin sheath, and disrupted myelin sheath and axon (21). Such injuries respond well to conservative management including physical therapy and wrist splint. Conservative therapy is usually deployed first, with surgery being the last resort (18). The Sunderland classification for third-degree nerve injury includes nerve damage with



**Figure 2** Schematic representation detailing the anatomical course of the ulnar nerve within the upper extremity. Originating from the medial cord of the brachial plexus, the ulnar nerve traverses the posterior humeral region, passes through the cubital tunnel, and continues distally along the forearm's ulnar aspect. The nerve subsequently enters Guyon's canal within the wrist, dividing into superficial and deep branches. The former supplies sensory innervation to the medial two and a half digits (shown in the diagram), while the latter innervates intrinsic hand muscles.

endoneurial scarring; all peripheral nerve components are injured except the perineurium and epineurium (23). For such lesions, surgical repair with potential nerve grafting techniques is employed. Complications related to surgery

include stretching of the nerve, severing of the nerve, incomplete release, and muscle atrophy (18). Surgery has been reported to have diminished the symptoms entirely in 67% to 93% (21).

### *Ulnar nerve anatomy*

The ulnar nerve originates from nerve roots C8–T1 (*Figure 2*), which collectively constitute the medial cord of the BP. This nerve follows a path that is medial to the axillary artery as it traverses through the medial bicipital groove. It then courses dorsally at the medial proximal arm, perforating the medial intermuscular septum and entering the posterior (extensor) compartment (24). The ulnar nerve traverses through the ulnar tunnel between the medial epicondyle and olecranon, giving rise to articular branches and muscular branches as it passes between the two heads of the flexor carpi ulnaris (24). It then passes through the cubital tunnel back to the flexor aspect of the arm to give rise to the dorsal and cutaneous palmar branches (24). Above the wrist, it divides into its terminal branches (superficial and deep branches). At the forearm level, the ulnar nerve provides motor innervation to flexor carpi ulnaris and the medial half of the flexor digitorum profundus (FDP). Motor innervation also extends to the hand, providing input to the intrinsic muscles of the hand, excluding the thenar muscles and two lateral lumbricals (24). Sensory innervation encompasses the palmar and dorsal regions of the hand's medial side, both palmar and dorsal aspects of the ulnar 1 1/2 fingers (specifically, the little finger and the ulnar portion of the ring finger), and the tip of the little finger (24).

### **Etiology of ulnar nerve neuropathy**

The most common site of compression of the ulnar nerve is at or near the cubital tunnel of the elbow and Guyon canal of the wrist (25). Cubital tunnel syndrome frequently arises from compression between Osborne's ligament, characterized as the fascia connecting the two heads of the flexor carpi ulnaris muscle on the surface, and the elbow's deep medial collateral ligament (MCL) (25). This compression could stem from extended pressure on the elbow or prolonged flexion of the elbow, commonly occurring during occupational tasks (like leaning on a desk), sports engagements, or medical interventions (such as general anesthesia). Ulnar neuropathy can occur due to ulnar nerve compression at three regions (24).

❖ Region I: situated before the point where the ulnar



nerve divides, a lesion in this region would manifest with both motor and sensory symptoms. There would be an observable motor weakness in all intrinsic hand muscles innervated by the ulnar nerve and sensory impairments encompassing the hypothenar eminence and the little and ring fingers.

- ❖ Region II: lesions affecting solely the deep motor branch result in motor-related symptoms exclusively within the intrinsic muscles innervated by the ulnar nerve.
- ❖ Region III: lesions occurring in the distal sensory branch lead to sensory-related symptoms, specifically manifesting as disruptions in sensation on the palm side of the little finger and the palm-ular side of the ring finger. Notably, there won't be any observed weakness in the hypothenar region or the interosseous muscles.

Additional factors contributing to cubital tunnel syndrome encompass physical injury to the cubital tunnel, the presence of masses like tumors or hematomas, as well as metabolic irregularities such as diabetes. Guyon canal syndrome is frequently linked with cycling, probably attributable to direct handlebar pressure, although it can also arise from blunt trauma (like a fracture of the hook of hamate) and the occurrence of masses, particularly ganglion cysts.

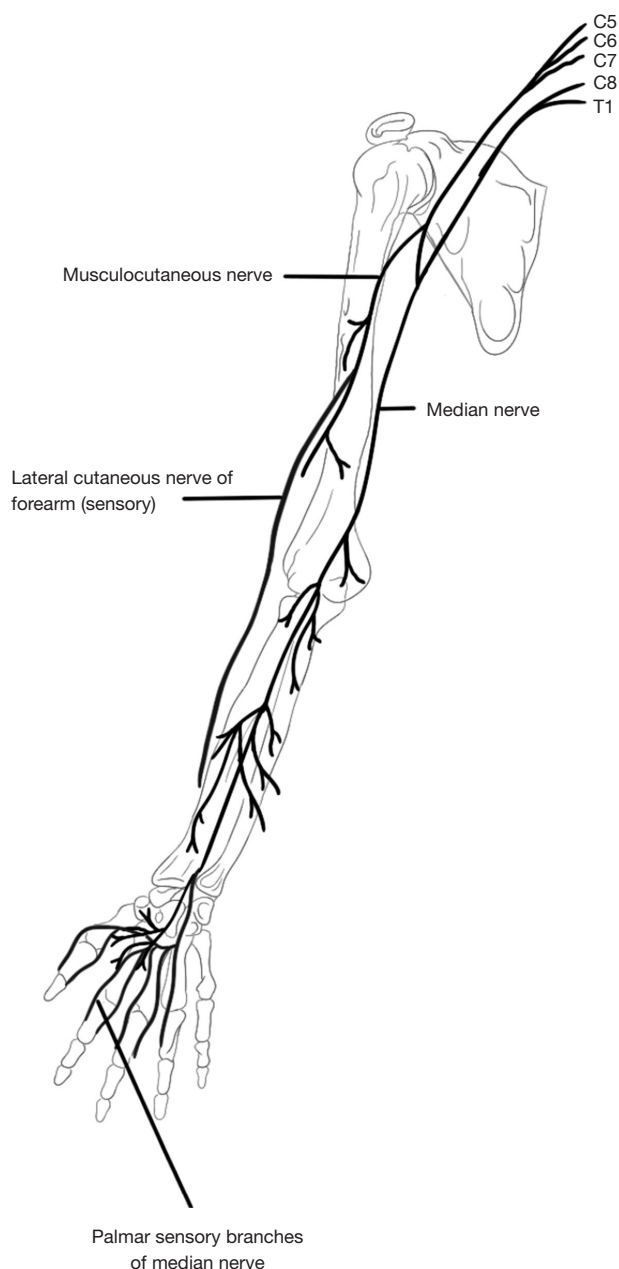
### Clinical features

Symptoms of ulnar nerve compression begin with numbness and paresthesia over the small finger, ulnar half of the ring finger, and hypothenar eminence (24). Weakness and atrophy of the intrinsic hand muscles may present if compression occurs proximal to region 3 of Guyon's canal. Once muscle wasting occurs, patients report excessive clumsiness and decreased pinch strength, highlighted by Froment's test (24,26). This test involves grasping a piece of paper between the thumb and radial side of the index finger to isolate adductor pollicis, which is the only muscle of the thenar eminence supplied by the ulnar nerve. The examiner then pulls the paper. If there is flexion of the thumb at the interphalangeal (IP) joint to keep hold of the paper, the patient is compensating with flexor pollicis longus (FPL) rather than the adductor pollicis, which indicates dysfunction of the ulnar nerve and yields a positive Froment's sign (24,26). Furthermore, Tinel's sign at the cubital and ulnar tunnels may reproduce symptoms of paresthesia and numbness, indicating ulnar nerve neuropathy.

Wartenberg's sign assesses motor weakness associated with the ulnar nerve. During the test, the patient is requested to maintain full adduction of the fingers, including the metacarpophalangeal (MCP) joint, proximal IP (PIP), and distal IP (DIP) with all joints extended. If the little finger drifts apart from the others into abduction, this is considered a positive Wartenberg sign. This outcome signifies impaired function of the palmar interossei muscles, innervated by the ulnar nerve, which are responsible for finger adduction (27). The abducted drifting of the little finger is a result of unopposed action by the extensor digiti minimi and extensor digitorum communis muscles on the small finger, both innervated by the PIN (27). When diagnosing ulnar nerve neuropathy, the examiner must rule out C8 radiculopathy. As the two presents with similar sensory and peripheral nerve distributions. Sensory innervation of the medial forearm is provided by the medial antebrachial cutaneous nerve along with branches originating from the medial cord of the BP. As a result, when comparing C8 radiculopathy to more distal ulnar nerve compression at the elbow, neurological changes are evident primarily in the medial forearm rather than being isolated to the hand. Notably, muscles within the thenar eminence—such as abductor pollicis brevis, flexor pollicis brevis, and opponens pollicis—alongside the radial two lumbricals, are innervated by the C8 nerve root through the median nerve. Consequently, these muscles would exhibit weakness or atrophy in cases of C8 radiculopathy, a phenomenon not observed in instances of peripheral ulnar nerve compressive neuropathy (28).

### Diagnosis

Radiographs of the affected extremity at the elbow and wrist rule out osseous deformity. Also, X-rays of the cervical region are often ordered to rule out radiculopathy and possible first rib involvement (24). A chest X-ray may be warranted to rule out medial cord compression by an apical lung or Pancoast tumor, particularly in a patient with a history of smoking (24). A CT scan can be ordered for the wrist when the examiner suspects a fracture in the hook of the hamate, as X-rays have a low sensitivity for detecting such fractures (24). MRI can be used to look for cervical radiculopathy in the neck or of a ganglion or other space-occupying lesions in the wrist. Ultrasound may be used to assess for any size abnormality of the ulnar nerve (24). EMG is also commonly used to diagnose compression neuropathy with muscle denervation. Compressive neuropathies increase distal latency and decrease conduction velocity (24).



**Figure 3** Diagram illustrating the anatomic course of the median nerve within the upper limb. Emerging from the lateral and medial cords of the brachial plexus, the nerve descends through the anterior arm alongside the brachial artery. Branches arising in the anterior cubital fossa supply forearm flexor muscles. Continuing distally, the median nerve passes between the heads of the pronator teres, traverses the carpal tunnel, and divides within the hand. It provides sensory innervation to the palmar aspects of specific fingers and motor innervation to thumb muscles.

In patients with cubital tunnel syndrome, one is likely to identify a slowing of conduction in the ulnar nerve segment crossing the elbow with the lower limit of normal with the elbow flexed to 135° should be >49 m/s (24).

### Treatment

Patients that lack intrinsic muscle weakness follow a conservative approach that utilizes anti-inflammatory medications, external padding of the nerve, and night splinting with the elbow in 45 degrees of flexion, or of the wrist in neutral position depending on the etiology of the compression (24,29). Also, patients are educated on positions to alleviate their symptoms and are encouraged to undergo occupational therapy to improve their ergonomics in the upper limb. Surgical intervention is indicated for symptomatic patients who have failed the conservative management. Surgeries for cubital tunnel syndrome include release of Osborne's ligament, ulnar nerve transposition, and medial epicondylectomy (24,29). As for ulnar tunnel syndrome, the physician must address the specific pathology causing the underlying pathology. This includes removal of any compressive ganglia or other local masses. Release of Guyon's canal should include all four compartments spanning from proximal to the wrist flexion crease and extending to the mid-palmar line. Patients with failed ulnar nerve transposition may undergo a revision surgery, which is usually successful for relief of pain and paresthesias; however, the recovery of motor function and return of sensibility were variable and unpredictable (30).

### Median nerve anatomy

The median nerve arises from the medial and lateral cords of the BP (C5–T1) (*Figure 3*). It accompanies the brachial artery as it descends the anterior compartment of the arm with no branches at this level. The nerve follows a trajectory toward the forearm and situates itself amidst the pronator teres muscle and the biceps tendon. It then proceeds between the flexor digitorum superficialis (FDS) and FDP muscles before emerging between the FDS and FPL muscles. Upon reaching the hand, the median nerve gains entry through the carpal tunnel, alongside the tendons of FDS, FDP, and FPL. Its terminal branches encompass the anterior interosseous nerve (AIN) branch, the palmar cutaneous branches, recurrent branches to the thenar compartment, and the digital cutaneous branches. The

AIN supplies the deep volar compartment of the forearm except the ulnar digits (4<sup>th</sup> and 5<sup>th</sup>) FDP tendons. The palmar cutaneous branch provides sensory innervation to the lateral palm. The digital cutaneous branches innervate the palmar radial 3 1/2 digits and the index, long, as well as the ring fingers dorsally. The median nerve supplies motor innervation to the superficial volar forearm musculature which includes pronator teres (flexor carpi radialis and palmaris longus), and intermediate group (FDS), a deep group (FDP, FPL, and pronator quadratus), and muscles of the hand (1<sup>st</sup> and 2<sup>nd</sup> lumbricals, opponens pollicis, abductor pollicis brevis, flexor pollicis brevis) (31).

### Etiology of median nerve neuropathy

Median nerve neuropathies typically occur from traumatic injuries such as motor vehicle accidents or chronic compression at the elbow or wrist. Trauma to the wrist and elbow are the most common locations to cause median nerve neuropathy (31,32). There are about 8,000,000 reported cases of median nerve injuries per year reported in the United States with CTS being the most frequently encountered entrapment neuropathy of the upper extremity (32).

### Clinical features

The conditions associated with median nerve entrapment include CTS, AIN neuropathy, and pronator syndrome. Median nerve injuries proximal to the AIN origin presents with the hand of benediction (Pope's blessing).

The indication becomes evident when a patient is requested to create a fist but can solely flex the ring and little fingers. This limitation arises from the absence of thumb opposition and abduction, along with the inability to flex the index and middle fingers. Proximal lesions are also associated with impaired wrist pronation and flexion as well as thenar muscle atrophy if the proximal lesion is chronic. Sensory deficits include loss of sensation at the thumb, index finger, middle finger, and radial side of the ring finger (31). Distal median nerve lesions at the AIN present with AIN syndrome without any sensory deficits. Individuals experience a reduction in the ability to flex the distal joints of the thumb and index finger. This results in their incapacity to pinch small objects, which is referred to as the "pinch sign", or to create the well-known "OK sign". To adapt, these patients resort to a key or lateral pinch, utilizing the thumb adductor and the first dorsal interosseous muscle (31). Distal lesions below the AIN present with a multitude of motor deficits.

The recurrent branch of the median nerve can sustain injury in cases of lacerations near the radial side of the wrist and in the proximal palm area. Such damage leads to the loss of thumb flexion, opposition, and abduction, while sensory and other motor functions remain unaffected. In instances of distal median nerve injury, a median claw hand deformity might manifest, characterized by the impairment of lumbricals I and II alongside preserved extrinsic flexor function. This imbalance culminates in a permanent flexion of the index and middle fingers, which becomes more pronounced when attempting finger extension.

An ape hand deformity can develop as a result of injury to the proximal or distal median nerves, impacting the functionality of the thenar muscles. This condition presents with an inability to oppose and abduct the thumb. Finally, the palmar cutaneous nerve can be damaged, which would present as a pure sensory deficit in the palm. Sensory deficits are seen in distal lesions below the AIN, which present with loss of sensation in the thumb, index finger, middle finger, and radial side of the ring finger (32). Lesions within the wrist present with CTS. Motor deficits associated with this condition include mild impairment of flexion of the index finger, long finger, and thumb (less severe than in other median nerve lesions) and thenar muscle atrophy (in chronic injury) (33). Sensory deficits seen in distal ulnar lesions within the wrist present with loss of sensation in the thumb, index finger and middle finger, and radial side of the ring finger. *Table 5* summarizes all median nerve palsy clinical presentations. Flexing the patient's wrist for one minute, a technique known as the Phalen maneuver, or by hyperextending the wrist in what's called the reversed Phalen maneuver, reproduces symptoms of CTS. This phenomenon is observed in roughly 80% of patients and is seldom associated with false positives (34). Another indicator, the Tinel's sign, which involves tapping the median nerve at the carpal tunnel, resulting in paresthesias in the median nerve's distal distribution, is detected in about 60% of individuals with the condition (34). However, it lacks specificity for CTS and may yield false positive results (34). The most sensitive and specific test for CTS is the carpal compression test or Durkan's test. The examiner elicits a positive test if symptoms of paresthesias, pain, and numbness occur after 30 seconds of holding manual pressure over the carpal tunnel. On physical exam, a key sign indicative of median nerve neuropathy is the presence of a bottle sign. The sign refers to a gap between the grasped object and the skin of the first web space when a patient attempts to hold a large cylindrical object. The sign

**Table 5** Median nerve injury presentations (32)

Lesion	Motor symptom	Sensory symptom	Etiology
Anterior interosseous nerve origin (proximal)	Hand of benediction; impaired wrist pronation and flexion; thenar muscle atrophy (chronic injury)	Thumb; index and middle finger; radial side of ring finger	Humeral fracture
At the anterior interosseous nerve	Anterior interosseous nerve syndrome	None	Supracondylar fractures, puncturing injuries anatomical compression, transient neuritis
Below anterior interosseous nerve origin (distal)	Recurrent branch of median nerve; median claw; ape hand; palmar cutaneous nerve	Thumb; index and middle finger; radial side of ring finger	Anatomical compression
Wrist	Carpal tunnel syndrome		Carpal bone dislocation and chronic compression

is related to the weakness of the thenar muscles innervated by the median nerve (abductor pollicis brevis, opponens pollicis, and superficial head of the flexor pollicis brevis) (35).

Compression of the median nerve between the humeral and ulnar heads of the pronator teres will result in pronator syndrome (32). Although not as common as carpal tunnel, pronator syndrome presents similarly to carpal tunnel as both conditions present with pain and paresthesia in the radial three and one-half digits, with the symptoms often worsening with activity (29,32). Decreased sensibility over the thenar eminence is often unique to pronator syndrome (29,31). Provocative testing for pronator syndrome involves subjecting structures that could potentially trap the median nerve to stress. If symptoms are recreated when resistance is applied during forearm pronation or during resisted elbow flexion/supination, suspicion should be directed towards the involvement of the pronator teres or the lacertus fibrosus, respectively (29).

### Diagnosis

Patient history and signs and symptoms of median nerve neuropathy mentioned above, are usually sufficient in making a diagnosis (32). If the history and physical exam are equivocal, an EMG and NCS may be warranted for their usefulness in excluding polyneuropathy or radiculopathy (31,32). A nerve conduction test can detect impairment in the median nerve conduction across the carpal tunnel while having normal conduction everywhere else in its path. EMG can determine motor deficits associated with median nerve lesions and differentiate between polyneuropathy and radiculopathy (31,32). MRI is beneficial if carpal tunnel symptoms have not improved, and a space-occupying lesion compressing the median nerve is suspected (31,32).

C6 radiculopathy and CTS present with similar pain

distribution. In CTS, patients often report worse symptoms at night, and symptoms improve by shaking the hand (flick sign) (32). Severe cases of carpal tunnel can involve loss of grip, and patients report difficulty in hand fine motor skills (32). C6 radiculopathy pain pattern includes the lateral forearm and first two digits. Another key feature of C6 radiculopathy is weakness limited to the biceps and loss of bicep tendon reflex (22). In contrast to cervical radiculopathy, nerve entrapments in the upper limb, such as CTS, exhibit pain, paresthesia, and weakness spanning across various nerve root distributions. Nevertheless, it's important to note that entrapment neuropathy often gives rise to referred pain, and this pain can extend proximally to the location of the entrapment site (22,14). The motor aspect of the two clinical conditions differs significantly. In CTS, the motor deficit is evaluated by testing the strength of the abductor pollicis brevis, which is supplied by the recurrent branch of the median nerve. In advanced cases of CTS, patients typically exhibit thenar atrophy (32). In contrast, the C6 nerve root supplies motor innervation to both elbow flexors and wrist extensors, with these functions overlapping (22).

During clinical examination, performing Spurling's maneuver will induce stress on C6 radicular pain, but it won't impact median nerve entrapment (22). Conversely, tests like Tinel's sign at the wrist, Durkan's median nerve test, and wrist flexion maneuvers will provoke symptoms related to CTS (31,32).

### Treatment

Conservative treatment for AIN neuropathy is tried first and consists of avoiding repetitive elbow flexion, forearm pronation, or forceful gripping (32). A posterior elbow splint is used to limit overuse of the extremity and patients

may use nonsteroidal anti-inflammatory drugs (NSAIDs) if needed (32). Patients who do not respond to conservative therapy are candidates for operative decompression (29). Conservative treatments for CTS include treating underlying comorbidities, immobilization by splinting, and glucocorticoid injections (32). Surgery is upheld for severe disease or refractory symptoms (32). It includes an endoscopic or open release of the transverse carpal ligament, with most patients returning to normal activities within a few weeks (29,32). Treatment of pronator teres syndrome follows a similar step-wise progression from least invasive to most invasive. It involves NSAIDs, local corticosteroid injections into the tender points of pronator teres, and median nerve decompression surgery if severe (32).

### Electrophysiological studies

Clinical history and physical examination are the main diagnostic tools for differentiating cervical radiculopathy and peripheral neuropathy. Electrodiagnostic studies are used to confirm the diagnosis as they measure sensory nerve action potentials and compound motor action potentials. Amplitude relates integrity of axons and latency relates speed/state of myelination, if latency is more than 25% of baseline, this indicates demyelination. In peripheral neuropathy the amplitudes are reduced, and conduction velocities may be slowed.

#### *Sensory NCS*

Records the electrical activity conducted along a nerve which has been electrically stimulated. The sensory conduction areas evaluated in the upper extremities are the thumb and index fingers (median nerve, radial nerve/C6–C7 nerve roots), and the little finger (ulnar nerve/C8 nerve root).

In cervical radiculopathy, the sensory nerve action potential will be normal in amplitude and latency (36,37). This occurs because the compression at the nerve root occurs in the spinal foramina proximal to the sensory dorsal root ganglion. The presence of abnormal sensory nerve provides useful data for peripheral neuropathy, such as brachial plexopathy, cubital tunnel or carpal tunnel.

#### *Motor NCS*

Muscle action potential amplitudes represent the extent of activation of motor fibers when muscles are stimulated. The

evaluation focuses on motor conduction in specific areas: deltoid (involving the axillary nerve/C5–C6 nerve roots), biceps (influenced by the musculocutaneous nerve/C5–C6 nerve roots), hypothenar muscles (linked to the ulnar nerve/C8), and thenar muscles (connected to the median nerve/C8–T1). Latency, on the other hand, gauges the speed of the fastest muscle fibers.

In cases of cervical radiculopathy, the motor NCS typically yields normal results (38). This is because the impact is confined to only a portion of nerve fascicles within the nerve root. However, when significant root compression occurs to the point where distal parts of axons lose their connection with the cell body, it leads to the development of axon loss through Wallerian degeneration.

#### *EMG*

EMG measures muscle response to a nerve's stimulation of the muscle. It provides useful data in localizing cervical radiculopathy, neuropathy, and myopathy. It determines if the disease is acute or chronic and if there is reinnervation. Wallerian degeneration may occur with severe radiculopathy. The EMG will show fibrillation, a small sharp spike that initiates with a small positive downward deflection, due to muscle fibers spontaneously firing. Fibrillation potentials initially manifest in more proximal muscles, such as the paraspinal muscles, before becoming apparent in limb muscles. Anomalies detected in the paraspinal muscles serve to distinguish between radiculopathy and brachial plexopathy. In the diagnostic process of cervical radiculopathy, at least one paraspinal muscle and two muscles from distinct peripheral nerves innervated by the same root must exhibit positive EMG findings (38). The frequently tested muscles include brachioradialis (C5), deltoid and biceps (C5–C6), flexor carpi radialis (C6), triceps (C6–C7), first dorsal interosseous (C8–T1), FPL (C8), and abductor digiti minimi (C8–T1) (37).

### Conclusions

CSM and radiculopathy may present together and differentiating the two poses a challenge to the clinician. CSM is a progressive neuropathy that often presents in the elderly as ataxia, upper motor neuron dysfunction, and bladder spasticity or retention. In the case of radiculopathy, symptoms are typically unilateral and can be differentiated from CSM with tests such as the Spurling test. Peripheral neuropathies of the upper extremity may also present



with similar clinical manifestations of loss of fine motor control, numbness, tingling, and pain in a nerve-like distribution. Proper evaluation of the source of nerve pathology using clinical tests and diagnostic studies are essential to differentiating CSM from radiculopathy and peripheral neuropathy. While cervical myelopathy, cervical radiculopathy, and upper extremity peripheral neuropathy may present in patients with similar symptoms, specific differential tests and clinical findings can aid clinicians in achieving accurate diagnoses and tailored treatment.

## Acknowledgments

*Funding:* None.

## Footnote

*Peer Review File:* Available at <https://jss.amegroups.com/article/view/10.21037/jss-23-39/prf>

*Conflicts of Interest:* All authors have completed the ICMJE uniform disclosure form (available at <https://jss.amegroups.com/article/view/10.21037/jss-23-39/coif>). The authors have no conflicts of interest to declare.

*Ethical Statement:* The authors are accountable for all aspects of the work in ensuring that questions related to the accuracy or integrity of any part of the work are appropriately investigated and resolved.

*Open Access Statement:* This is an Open Access article distributed in accordance with the Creative Commons Attribution-NonCommercial-NoDerivs 4.0 International License (CC BY-NC-ND 4.0), which permits the non-commercial replication and distribution of the article with the strict proviso that no changes or edits are made and the original work is properly cited (including links to both the formal publication through the relevant DOI and the license). See: <https://creativecommons.org/licenses/by-nc-nd/4.0/>.

## References

1. Donnally III CJ, Hanna A, Odom CK. Cervical Myelopathy. In: StatPearls. Treasure Island (FL): StatPearls Publishing; 2022 Mar 6.
2. Bland JH, Boushey DR. Anatomy and physiology of the cervical spine. *Semin Arthritis Rheum* 1990;20:1-20.
3. Bakhsheshian J, Mehta VA, Liu JC. Current Diagnosis and Management of Cervical Spondylotic Myelopathy. *Global Spine J* 2017;7:572-86.
4. Nouri A, Tetreault L, Singh A, et al. Degenerative Cervical Myelopathy: Epidemiology, Genetics, and Pathogenesis. *Spine (Phila Pa 1976)* 2015;40:E675-93.
5. McCormick JR, Sama AJ, Schiller NC, et al. Cervical Spondylotic Myelopathy: A Guide to Diagnosis and Management. *J Am Board Fam Med* 2020;33:303-13.
6. Davies BM, Mowforth OD, Smith EK, et al. Degenerative cervical myelopathy. *BMJ* 2018;360:k186.
7. Cook C, Brown C, Isaacs R, et al. Clustered clinical findings for diagnosis of cervical spine myelopathy. *J Man Manip Ther* 2010;18:175-80.
8. Cook CE, Wilhelm M, Cook AE, et al. Clinical tests for screening and diagnosis of cervical spine myelopathy: a systematic review. *J Manipulative Physiol Ther* 2011;34:539-46.
9. Kiely P, Baker JF, O'hEireamhoin S, et al. The evaluation of the inverted supinator reflex in asymptomatic patients. *Spine (Phila Pa 1976)* 2010;35:955-7.
10. Wong TM, Leung HB, Wong WC. Correlation between magnetic resonance imaging and radiographic measurement of cervical spine in cervical myelopathic patients. *J Orthop Surg (Hong Kong)* 2004;12:239-42.
11. Magnus W, Viswanath O, Viswanathan VK, et al. Cervical Radiculopathy. (Updated 2022 Jul 22). In: StatPearls (Internet). Treasure Island (FL): StatPearls Publishing; 2022 Jan. Available online: <https://www.ncbi.nlm.nih.gov/books/NBK441828/>
12. Abbed KM, Coumans JV. Cervical radiculopathy: pathophysiology, presentation, and clinical evaluation. *Neurosurgery* 2007;60:S28-34.
13. Uchihara T, Furukawa T, Tsukagoshi H. Compression of brachial plexus as a diagnostic test of cervical cord lesion. *Spine (Phila Pa 1976)* 1994;19:2170-3.
14. Huisstede BM, Bierma-Zeinstra SM, Koes BW, et al. Incidence and prevalence of upper-extremity musculoskeletal disorders. A systematic appraisal of the literature. *BMC Musculoskelet Disord* 2006;7:7.
15. da Costa JT, Baptista JS, Vaz M. Incidence and prevalence of upper-limb work related musculoskeletal disorders: A systematic review. *Work* 2015;51:635-44.
16. Naden CM. Brachial Plexopathy. *Curr Sports Med Rep* 2017;16:121.
17. Sapage R, Pereira PA, Vital L, et al. Surgical anatomy of the radial nerve in the arm: a cadaver study. *Eur J Orthop Surg Traumatol* 2021;31:1457-62.
18. Ljungquist KL, Martineau P, Allan C. Radial nerve

- injuries. *J Hand Surg Am* 2015;40:166-72.
19. Nachef N, Bariatinsky V, Sulimovic S, et al. Predictors of radial nerve palsy recovery in humeral shaft fractures: A retrospective review of 17 patients. *Orthop Traumatol Surg Res* 2017;103:177-82.
  20. Kimbrough DA, Mehta K, Wissman RD. Case of the season: Saturday Night Palsy. *Semin Roentgenol* 2013;48:108-10.
  21. Moradi A, Ebrahimzadeh MH, Jupiter JB. Radial Tunnel Syndrome, Diagnostic and Treatment Dilemma. *Arch Bone Jt Surg* 2015;3:156-62.
  22. Robblee J, Katzberg H. Distinguishing Radiculopathies from Mononeuropathies. *Front Neurol* 2016;7:111.
  23. Seddon HJ. A Classification of Nerve Injuries. *Br Med J* 1942;2:237-9.
  24. Elhassan B, Steinmann SP. Entrapment neuropathy of the ulnar nerve. *J Am Acad Orthop Surg* 2007;15:672-81.
  25. Spies CK, Löw S, Langer MF, et al. Cubital tunnel syndrome : Diagnostics and therapy. *Orthopade* 2017;46:717-26.
  26. Froment J. Prehension and the sign of the thumb in paralysis of the ulnar nerve. *Bull Hosp Joint Dis* 1972;33:193-6.
  27. Bertelli JA, Tavares KE. Little finger abduction and adduction testing in ulnar nerve lesions. *Hand Surg Rehabil* 2018;37:368-71.
  28. Stoker GE, Kim HJ, Riew KD. Differentiating c8-t1 radiculopathy from ulnar neuropathy: a survey of 24 spine surgeons. *Global Spine J* 2014;4:1-6.
  29. Spinner M. Management of nerve compression lesions. *Instr Course Lect* 1984;33:498-512.
  30. Rogers MR, Bergfield TG, Aulicino PL. The failed ulnar nerve transposition. Etiology and treatment. *Clin Orthop Relat Res* 1991;(269):193-200.
  31. Tsai P, Steinberg DR. Median and radial nerve compression about the elbow. *J Bone Joint Surg Am* 2008;90:420-8.
  32. Dydyk AM, Negrete G, Sarwan G, et al. Median Nerve Injury. In *StatPearls*. Treasure Island (FL): StatPearls Publishing; 2022.
  33. Torres-Costoso A, Martínez-Vizcaíno V, Álvarez-Bueno C, et al. Accuracy of Ultrasonography for the Diagnosis of Carpal Tunnel Syndrome: A Systematic Review and Meta-Analysis. *Arch Phys Med Rehabil* 2018;99:758-765.e10.
  34. Jankovic J, Mazziotta JC, Pomeroy SL, et al. *Bradley and Daroff's neurology in clinical practice*. Amsterdam: Elsevier; 2022.
  35. Lad SP, Nathan JK, Schubert RD, et al. Trends in median, ulnar, radial, and brachiolexus nerve injuries in the United States. *Neurosurgery* 2010;66:953-60.
  36. Tsao B. The electrodiagnosis of cervical and lumbosacral radiculopathy. *Neurol Clin* 2007;25:473-94.
  37. Li JM, Tavee J. Electrodiagnosis of radiculopathy. *Handb Clin Neurol* 2019;161:305-16.
  38. Hakimi K, Spanier D. Electrodiagnosis of cervical radiculopathy. *Phys Med Rehabil Clin N Am* 2013;24:1-12.

**Cite this article as:** Jajeh H, Lee A, Charls R, Coffin M, Sood A, Elgafy H. A clinical review of hand manifestations of cervical myelopathy, cervical radiculopathy, radial, ulnar, and median nerve neuropathies. *J Spine Surg* 2024;10(1):120-134. doi: 10.21037/jss-23-39