

## Case Report

# Combined Laparoscopic and Cystoscopic Retrieval of Forgotten Translocated Intrauterine Contraceptive Device

Taiwo O Alabi, Mohan Keshavamurthy<sup>1</sup>, Shabeer Ahmed<sup>2</sup>, Rufus W Ojewola, Mahendra Jain<sup>1</sup>, Kehinde H Tijani

Department of Surgery, Urology Unit, College of Medicine, Lagos University Teaching Hospital, University of Lagos, Lagos, Nigeria, <sup>1</sup>Urology, Andrology, and Transplant Surgery Unit, Fortis Hospital, <sup>2</sup>Minimal Access Surgical Unit, Fortis Hospital, Bengaluru, Karnataka, India

### ABSTRACT

The most commonly used long-term reversible female contraception is intrauterine contraceptive device (IUCD). Its use is however associated with documented complications. Uterine perforation, though rare, is arguably the most surgically important of all these complications. We report a case of a 48-year-old para 4<sup>+0</sup> (4 alive) woman who had IUCD insertion 17 years earlier and had forgotten she had the device having had two children thereafter. The IUCD was subsequently translocated through the dome of the bladder into the peritoneal cavity with calculus formation around the tail and thread of the IUCD in the urinary bladder causing recurrent urinary tract infection. This “Collar Stud” effect made either cystoscopic or laparoscopic retrieval alone unsuccessful necessitating a combined approach. This case report highlights the need for a combined laparoscopic and cystoscopic approach in the retrieval of the unusual presentation of translocated IUCD.

**KEYWORDS:** Retrieval, translocated intrauterine contraceptive device, uterine perforation

## INTRODUCTION

Intrauterine contraceptive devices (IUCDs) are the most commonly used long-acting reversible contraception worldwide.<sup>[1]</sup> Uterine perforation is an uncommon but feared complication of IUCD with estimated rate of less than 0.1%.<sup>[2]</sup> The fate of the IUCD after perforation of the uterine wall varies. Migration through the urinary tract following uterine perforation is a rarer occurrence. We report a case of forgotten IUCD that migrated through the dome of the bladder into the peritoneal cavity with stone formation around the vertical limb and thread of the IUCD in the bladder.

## CASE REPORT

A 48-year-old woman, 2-year postmenopausal presented at the Fortis Hospital, Bengaluru, India in February 2016 with a complaint of severe dysuria of 1-year duration with neither hematuria nor lower urinary tract symptoms. There was neither abdominal pain nor any symptom referable to other systems. She had four children through spontaneous vaginal delivery; two of them were after the IUCD

insertion. The third and fourth deliveries occurred at 3 and 6 years respectively after she had IUCD insertion. Her last delivery was 18 years before presentation. Since the onset of symptom, she had been treated severally for urinary tract infection following repeated microscopy culture and sensitivity testing of her urine at the referring hospital, which grew *Escherichia coli* and *Proteus mirabilis*. There were no comorbidities or significant social history. General and systemic/regional examination findings were essentially normal. Baseline complete blood count, urea, and creatinine were within normal limits. Abdominopelvic computerized axial tomographic scan showed an IUCD at the dome of the urinary bladder with a portion of it in the perivesical space adjacent to the sigmoid colon and the remaining portion being

**Address for correspondence:** Dr. Rufus W Ojewola, Department of Surgery, Urology Unit, College of Medicine, Lagos University Teaching Hospital, University of Lagos, Idi-Araba, Lagos, Nigeria.  
E-mail: rwaleojewola@yahoo.com

This is an open access journal, and articles are distributed under the terms of the Creative Commons Attribution-NonCommercial-ShareAlike 4.0 License, which allows others to remix, tweak, and build upon the work non-commercially, as long as appropriate credit is given and the new creations are licensed under the identical terms.

**For reprints contact:** reprints@medknow.com

**How to cite this article:** Alabi TO, Keshavamurthy M, Ahmed S, Ojewola RW, Jain M, Tijani KH. Combined laparoscopic and cystoscopic retrieval of forgotten translocated intrauterine contraceptive device. Niger J Surg 2018;24:48-51.

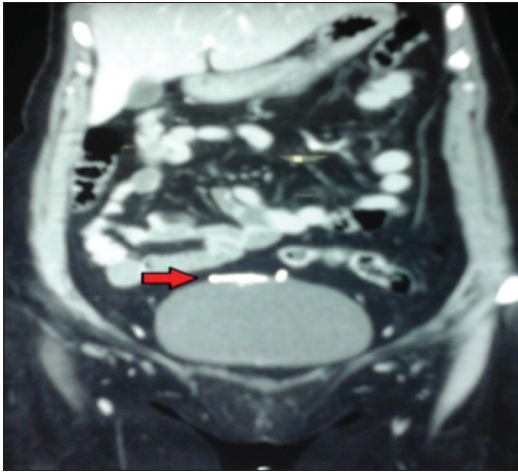
### Access this article online

#### Quick Response Code:

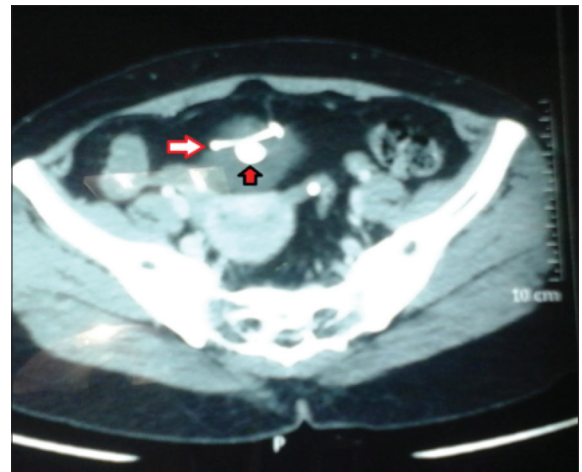


**Website:** www.nigerianjsurg.com

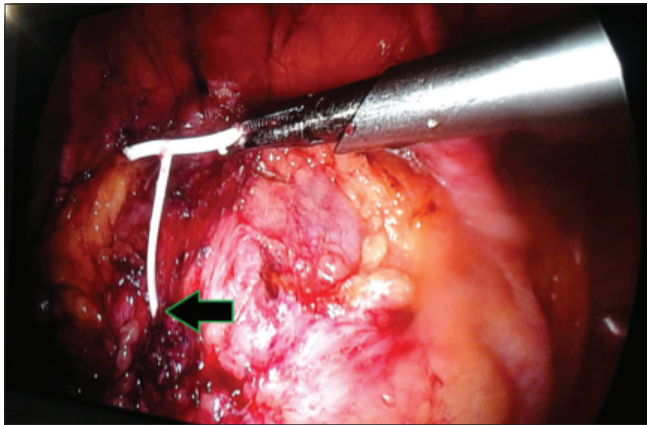
**DOI:** 10.4103/njs.NJS\_18\_17



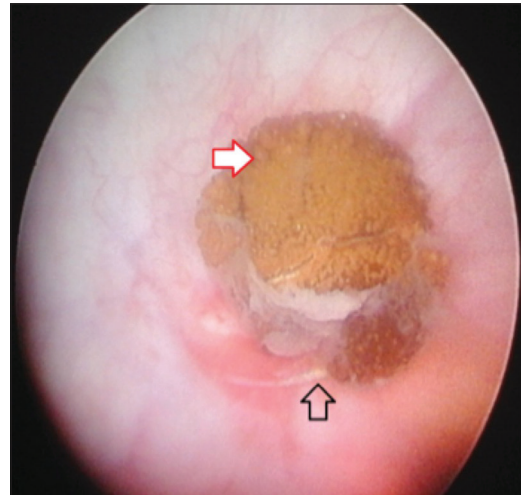
**Figure 1:** Coronal reformatted abdominopelvic computed tomography scan showing the horizontal limb of the T-shaped intrauterine contraceptive device in the peritoneal cavity adjacent to the sigmoid colon (solid red arrow)



**Figure 2:** Computerized axial tomographic scan of the pelvis showing: The vertical limb of the T-shaped intrauterine contraceptive device with calculus formed around it (red solid arrow with black outline) the transverse limb of the intrauterine contraceptive device located intraperitoneally (white arrow with red outline)



**Figure 3:** Laparoscopic view of the intrauterine contraceptive device after dissecting the omentum from it the point of exit of the intrauterine contraceptive device from the fundus of the bladder (black solid arrow with green outline). The intrauterine contraceptive device could not be retrieved due to the intravesical calculus attached to the distal part of the vertical limb and thread of the intrauterine contraceptive device



**Figure 4:** Cystoscopic view of the stone and intrauterine contraceptive device thread in the bladder. Intravesical calculus formed around the vertical limb and the thread of intrauterine contraceptive device (white solid arrow with red outline). Thread of the intrauterine contraceptive device (nonfill arrow with black outline)

intravesical forming about 1.4 cm dense area of nodular calcification [Figures 1 and 2]. These findings prompted her to remember that she had IUCD inserted 17 years earlier (4 months after her second delivery). A diagnosis of forgotten, translocated IUCD was made. She had combined laparoscopy and cystoscopy done. Laparoscopy showed omental adhesion to an intraperitoneal IUCD above the dome of the urinary bladder adjacent to the sigmoid colon with difficulty in pulling out the IUCD due to the intravesical calculus attachment [Figure 3]. Cystoscopy showed an intravesical calculus formed around the distal aspect of the vertical limb and the thread of IUCD [Figure 4]. Intracorporeal pneumatic cystolithotripsy was done, only then was the IUCD retrievable through the 10mm

laparoscopic port. The point of urinary leakage from the bladder into the peritoneal cavity after removal of the IUCD was closed using vicryl suture [Figure 3]. She was discharged home on the 2<sup>nd</sup> postoperative day with an uneventful postoperative period.

## DISCUSSION

Despite its wide acceptability and usage, IUCD is associated with documented complications. Some of these complications include upper genital infection and consequent infertility, pelvic inflammatory disease, uterine perforation and subsequent translocation leading to bowel perforation/obstruction, vesical calculus

formation, and vesicouterine fistula.<sup>[3-6]</sup> Translocation following uterine perforation is perhaps the most surgically important complication.

The possible mechanism of translocation includes initial uterine perforation and complete translocation of the device into the peritoneal cavity, followed by vesical perforation and partial translocation (vertical limb/string only) into the bladder with resultant crust and calculus formation. Alternatively, there is also the possibility of direct utero-vesical perforation and complete translocation of the device into the urinary bladder, followed by vesical perforation and partial translocation of the horizontal limb of the device into the peritoneal cavity. In this index case, complete peritoneal translocation would have been prevented by the encrustation and calculus formation on the vertical limb of the device.

A review of 75 patients with uterine perforation from IUCD over a 13-year period by Kaislasuo *et al.*<sup>[7]</sup> in Finland showed that majority present with abnormal bleeding and/or abdominal pain following uterine perforation whereas, others may remain asymptomatic. In asymptomatic patients, uterine perforation is usually suspected following the occurrence of pregnancy, inability to palpate the string of the device, or inability to pull out the device. The factors associated with uterine perforation include early postpartum insertion; lactation and poor insertion techniques.<sup>[8]</sup> Poor insertion technique is probably the cause in this patient. She had even forgotten that she was carrying the device. Following uterine perforation, greater percentage of IUCD translocated into the peritoneal cavity is usually contained by the omentum such that intraperitoneal visceral injury rarely occurs.<sup>[2,9]</sup> This is corroborated by the findings of our case report where the omentum had walled off the IUCD.

Localization of migrated device is usually done by vaginal ultrasonography, abdominopelvic X-ray, hysteroscopy, and curettage.<sup>[10]</sup> The index patient did abdominopelvic computed tomography scan to determine the possible differential diagnosis since the patient did not initially give the history of IUCD insertion.

Early reports on the laparoscopically assisted IUCD retrieval showed that visualizing and locating the IUCD embedded in the omentum was usually difficult or challenging due to difficulty in visualizing the IUCD.<sup>[2,9]</sup> Nevertheless, advancement in not only the skills but also instrumentation, lightning and imaging has made laparoscopically-assisted retrieval of intraperitoneal translocated IUCD possible.

Most translocated IUCD are usually successfully retrieved laparoscopically or cystoscopically if translocated into the urinary bladder. A combined approach may rarely be required as in the index patient due to the “collar stud” effect created by the horizontal limb of the T-shaped IUCD in the peritoneal cavity and the calculus formation on the vertical limb and thread of the IUCD within the urinary bladder. This effect made the retrieval of the IUCD difficult using either of these approaches alone.

## CONCLUSION

IUCD can perforate the uterus and get translocated long after it has been inserted with or without any of the previously identified predisposing factors. It can perforate the bladder to enter the peritoneal cavity with its tail getting trapped in the bladder by encrustation and calculus formation. Combined cystoscopy and laparoscopy may be required for retrieval in this unusual scenario.

## Declaration of patient consent

The authors certify that they have obtained all appropriate patient consent forms. In the form the patient(s) has/have given his/her/their consent for his/her/their images and other clinical information to be reported in the journal. The patients understand that their names and initials will not be published and due efforts will be made to conceal their identity, but anonymity cannot be guaranteed.

## Financial support and sponsorship

Nil.

## Conflicts of interest

There are no conflicts of interest.

## REFERENCES

1. Darney LS, Philip D. A Clinical Guide for Contraception. 5<sup>th</sup> ed. Philadelphia, PA: Lippincott Williams & Wilkins; 2010. p. 242-3.
2. Zakin D, Stern WZ, Rosenblatt R. Complete and partial uterine perforation and embedding following insertion of intrauterine devices. I. Classification, complications, mechanism, incidence, and missing string. *Obstet Gynecol Surv* 1981;36:335-53.
3. Grimes DA. Intrauterine device and upper-genital-tract infection. *Lancet* 2000;356:1013-9.
4. Dietrick DD, Issa MM, Kabalin JN, Bassett JB. Intravesical migration of intrauterine device. *J Urol* 1992;147:132-4.
5. Thomalla JV. Perforation of urinary bladder by intrauterine device. *Urology* 1986;27:260-4.
6. Jeje EA, Ojewola RW, Atoyebi OA. Intravesical migration of a failed and forgotten intrauterine contraceptive device after 20 years of insertion – A case report. *Nig Q J Hosp Med* 2012;22:221-3.
7. Kaislasuo J, Suhonen S, Gissler M, Lähteenmäki P, Heikinheimo O. Uterine perforation caused by intrauterine

- devices: Clinical course and treatment. *Hum Reprod* 2013;28:1546-51.
8. Kaislasuo J, Suhonen S, Gissler M, Lähteenmäki P, Heikinheimo O. Intrauterine contraception: Incidence and factors associated with uterine perforation – A population-based study. *Hum Reprod* 2012;27:2658-63.
  9. McKenna PJ, Mylotte MJ. Laparoscopic removal of translocated intrauterine contraceptives devices. *Br J Obstet Gynaecol* 1982;89:163-5.
  10. Rafique M. Vesical calculus: A complication of intravesical migration of intrauterine contraceptive device. *Int Urogynecol J Pelvic Floor Dysfunct* 2002;13:380-2.