



Acute severe hepatitis of unknown origin in children: considerations from the perspective of immunology

Si-Hao Gao¹ · Meng-Chun Gong² · Hong-Mei Song¹

Received: 2 June 2022 / Accepted: 6 June 2022 / Published online: 29 June 2022
© Children's Hospital, Zhejiang University School of Medicine 2022

Acute severe hepatitis of unknown origin in children, since it was firstly reported in Scotland on March 31, 2022, has become an international concern with a high risk of acute liver failure requiring liver transplant. The typical causes for hepatitis have been ruled out and investigations revealed possible relationship between the disease and two potential pathogens, a special form of human adenovirus (HAdV) and severe acute respiratory syndrome coronavirus 2 (SARS-CoV-2). Acute hepatitis has been reported in children with multisystem inflammatory syndrome (MIS-C) and incorporating insights from the immunology perspective is necessary to fully understand this disease.

Overview of the situation

On 31 March 2022, Public Health Scotland (PHS) was alerted about five children aged 3–5 years presenting to a hospital with severe hepatitis of unknown aetiology within a 3-week period [1]. On 15 April 2022, World Health Organization (WHO) published the WHO Disease Outbreak News on “Acute hepatitis of unknown aetiology—the United Kingdom of Great Britain and Northern Ireland”. Since then, there have been continuing further reports of cases. As of 31 May 2022, at least 746 cases of acute hepatitis of unknown origin have been reported from 36 countries and regions (Fig. 1), including the United Kingdom of Great Britain and Northern Ireland (the UK) (222), the USA (216), Brazil (72), Japan (31), Spain (29), Italy (27), Indonesia (16), Belgium (14), The Netherlands (14), Israel (12), Portugal (11),

Canada (10), Mexico (10), Argentina (9), Sweden (9), Denmark (7), Ireland (7), Norway (5), Greece (3), Austria (2), Costa Rica (2), Cyprus (2), France (2), Panama (2), Malaysia (1), Moldova (1), Palestine (1), Poland (1), Romania (1), Serbia (1), Singapore (1), South Korea (1), Bulgaria (<5), Maldives (<5), Slovakia (<5), and Slovenia (<5) (Fig. 1).

According to published data, all cases were aged between 1 month to 16 years, with clinical characteristics of abdominal pain, diarrhoea and vomiting, followed by severe acute hepatitis with increased levels of liver enzymes and jaundice, of which more than 6% children have received liver transplantation, and more than 9 deaths have been reported [2–7]. WHO has updated the definition of acute severe hepatitis of unknown origin in children on 23 April (Table 1) and proposed further work on identifying additional cases, common measures of management or prevention, collection of epidemiology and risk factor information, etc. [8].

The etiology of this outbreak of acute severe hepatitis in children remains unknown. There is no evidence of typical viral infections that are known to cause acute viral hepatitis (hepatitis A, B, C, D or E virus) being detected in any of the affected cases, nor have any notable exposures to animals, toxicants or polluted diet and water source been found. Recent studies have shown that half to two-thirds of patients tested positive for HAdVs, dominantly belonging to type 41 in group F in England [9], and SARS-CoV-2 was detected in some cases, revealing that acute severe hepatitis in children may be related to HAdVs or SARS-CoV-2 infection [8].

Human adenovirus: an old bottle with new wine

HAdVs, common pathogens with more than 50 immunologically distinct serotypes and a worldwide distribution, usually cause self-limited infections in the healthy population. More than 5–10% of all febrile illnesses in infants and young children are caused by HAdVs and nearly all adults have serologic evidence of past infection with one or more

✉ Hong-Mei Song
songhm1021@hotmail.com

¹ Department of Pediatrics, Peking Union Medical College Hospital, Chinese Academy of Medical Sciences, Beijing, China

² Institute of Health Management, Southern Medical University, Guangzhou, China

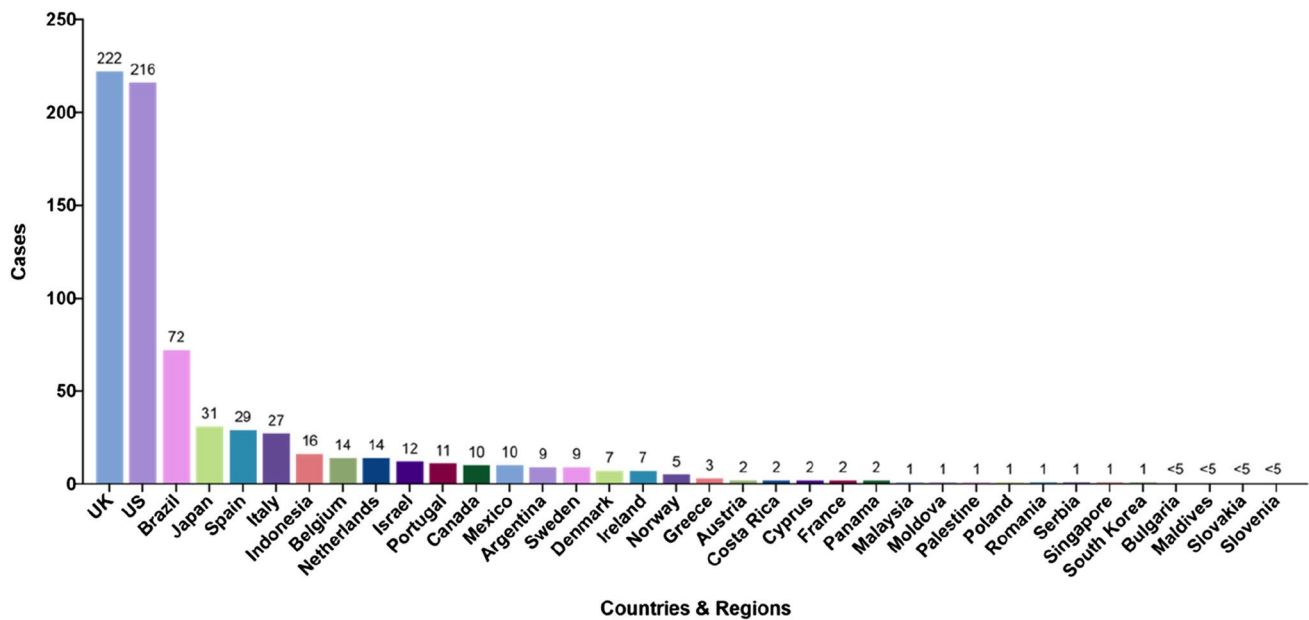


Fig. 1 Distribution of cases of acute severe hepatitis of unknown origin in children in various countries, as of 31 May 2022

Table 1 Case definition updated by WHO on 23 April [2]

Cases	Definition
Confirmed	Not available at present
Probable	A person presenting with acute hepatitis (non-hepA-E*) with serum transaminase > 500 IU/L (AST or ALT), who is 16 years and younger, since 1 October 2021
Epi linked	A person presenting with acute hepatitis (non-hepA-E) of any age who was in close contact with a probable case, since 1 October 2021

HAdVs. However, only a few cases of severe acute hepatitis or even liver failure have been described in immunocompetent children due to HAdV infection [10]. Severe or disseminated HAdV infections may occur in immunocompromised patients, especially in those with cellular immunodeficiencies, notably caused by serotypes 1, 3, 5 and 7. In these patients, hepatitis or an obvious complication could be observed especially in neonates. Additionally, HAdV reactivation may occur in immunocompromised patients [11, 12]. Primary adenovirus infection of serotype 31 in group A and several serotypes in group B and C can cause serious diseases such as fatal pneumonia and hepatitis in children with immunodeficiency syndrome, such as severe combined immunodeficiency disease (SCID) [13]. Adenovirus type 41 infections typically present with diarrhoea, vomiting and fever, frequently accompanied by respiratory symptoms. It was not until recently that adenovirus type 41 was reported to be a cause of hepatitis in healthy children, with many of them showing severe hepatic manifestations and even liver

failures necessitating liver transplantation. The most likely assumption supported by the current data is that the normal HAdV infections were rendered more severe by an additional cofactor such as drugs or secondary immunodeficiencies resulting from other pathogens [14].

There is, of course, another possibility which has been suggested recently: that the outbreak is caused by the emergence of a new HAdV with altered characteristics with or without a contribution of one of the cofactors [14].

SARS-CoV-2: superpower to trigger the immune cascade or just a coincidence?

The relationship between hepatitis and severe acute respiratory syndrome coronavirus-2 (SARS-CoV-2) infection should not be neglected during the coronavirus disease 2019 (COVID-19) pandemic. In fact, hepatic involvement has been described in children with COVID-19 [15]. Meanwhile, SARS-CoV-2 has been identified in 15% of reported hepatitis cases in the UK including 16 (12.8%) of 125 cases in England with available data [4, 9]. A few cases of severe hepatitis have been described in the literature that may occur as part of multisystem inflammatory syndrome in children (MIS-C) with COVID-19 [16]. However, the peak of MIS-C occurs 3–4 weeks later than the peak of COVID-19, and 60% of children with seropositive MIS-C have no detectable virus, which indicates that MIS-C may be caused by an untimely immune response in different individuals after infection, instead of being caused by SARS-CoV-2 itself [17].

Recent studies have shown that SARS-CoV-2 viral persistence in the gastrointestinal tract can lead to continued release of viral proteins across the intestinal epithelium, giving rise to repeated or persistent immune-cell activation, which might be mediated by a superantigen motif within the SARS-CoV-2 spike protein that bears resemblance to staphylococcal enterotoxin B, triggering broad and non-specific T-cell activation [18, 19]. A similar study also showed that MIS-C associated with SARS-CoV-2 exhibited higher number of mucosal homing T cells and higher expression of IL-17, suggesting that the development of MIS-C may be a post-infectious, immunologically mediated sequel of COVID-19 [20]. Of course, it cannot be completely excluded that as part of the ongoing pandemic, SARS-CoV-2 infections may just be a coincidence.

Previous animal experiments have also shown that adenovirus infection sensitizes subjects to subsequent staphylococcal enterotoxin B-mediated toxic shock, leading to liver failure and death, possibly explained by adenovirus-induced type-1 immune dysregulation with excessive IFN- γ production and IFN- γ -mediated apoptosis of hepatocytes [21]. So it has been speculated that acute severe hepatitis in children could be a consequence of adenovirus infection with intestinal tropism in children previously infected by SARS-CoV-2 and carrying viral reservoirs. Based on this hypothesis, it is suggested that children with acute hepatitis should be investigated for SARS-CoV-2 persistence in stool, T-cell receptor skewing and IFN- γ upregulation [22].

Autoimmune hepatitis: something to keep in mind

For acute hepatitis of unknown cause, the possibility of autoimmune hepatitis (AIH) should also be considered, although it is a rare progressive liver disease manifesting as acute hepatitis in 40%–50% of paediatric cases with a few of cases fulfilling the criteria for acute liver failure (ALF) [23].

AIH is characterized by elevated IgG level with various types of autoantibodies present in patients' sera, including antinuclear antibody (ANA), anti-smooth muscle antibody (ASMA), anti-actin antibody (AAA), anti-mitochondrial antibody (AMA), etc. [24]. It is also histopathologically characterized by mononuclear cell infiltrations in the portal area or around the portal vein (generally lymphoplasmacytic, and often accompanied by a small number of eosinophils), forming a well-defined hepatocyte plate (boundary plate), that is, interfacial hepatitis, which can be distinguished from other acute hepatitis [25].

Although the pathogenesis of AIH is not clear, it is recognized that AIH is induced by environmental factors in genetically susceptible individuals. Antigens, major histocompatibility complex (MHC) and T-cell receptor (TCR)

are involved in the genetic background, while viruses, drugs and vaccination are all considered to be inducing factors [26]. Most evidence support that the functional change of T cells plays a central role in the pathogenesis of AIH, in which abnormal regulatory T cells (Treg) lead to persistent inflammation and necrosis of hepatocytes [27]. HLA serotype differs among ethnic groups and territories. For example, AIH is closely related to HLA-DR3 and HLA-DR4 serotypes in Caucasian, to HLA-DRB1*03 homozygous in Nordic children and to DRB1*0405 and DQB1*0401 serotypes in Japanese [28]. Is this the reason for the characteristic distribution of acute severe hepatitis in children from different regions?

SARS-CoV-2 infections may also cause chilblains, also known as “COVID toes” that have been reported in children and young adults infected with COVID-19. Chilblains in COVID-19 probably result from vasculitis characterized by endothelial necrosis, lymphocytic infiltration of CD4⁺ and CD8⁺ T cells and B cells, as well as IgA, IgM and C3 deposition in the vascular wall, which mimic the vasculitis of autoimmune-related chilblains with positive antinuclear antibodies (ANA) [20].

Based on the evidence of superantigen-mediated immune activation, immunomodulatory therapies could be considered in children with severe acute hepatitis. It has been previously reported that JAK1/2 inhibitor baricitinib may diminish the excessive inflammatory response caused by cytokine storm in patients with COVID-19 [29].

Additionally, two points deserve more research attention. First, why did most severe hepatitis occur in young infants? Second, is the disease related to the imperfect immune function of children at these ages or associated with the genetic background of primary immunodeficiency?

On all accounts, it should be speculated reasonably that children with acute severe hepatitis may have underlying immunodeficiencies, which can be a genetic defect or transiently secondary to infection of other pathogens or other factors. Accordingly, genetic test (whole exome sequencing if necessary), MHC molecular phenotyping and immune functional assays including humoral immunity, cellular immunity and innate immune response of these children should be performed, so that the real cause of the disease could be found. The confirmation of pathological changes and pathogens in the liver biopsy tissue is the gold evidence to determine the pathogenesis and the disruptive process in the liver. This will also provide strong support on the suspected immunologic pathways.

Author contribution SHG, MCG and HMS drafted and revised the manuscript. All authors approved the final version of the manuscript

Funding This work was supported by the National Key R&D Program of China (Grant number 2021YFC2702001).

Declarations

Ethical approval Not needed.

Conflict of interest No financial or non-financial benefits have been received or will be received from any party related directly or indirectly to the subject of this article. Hong-Mei Song is an editorial board member of the journal. The paper was handled by the other Editors and has undergone a rigorous peerreview process. Author Hong-Mei Song was not involved in the journal's review or decisions making of this manuscript.

References

1. Marsh K, Tayler R, Pollock L, Roy K, Lakha F, Ho A. Investigation into cases of hepatitis of unknown aetiology among young children, Scotland. *Euro Surveill*. 2022. <https://doi.org/10.2807/1560-7917.ES.2022.27.15.2200318>.
2. World Health Organization. Acute hepatitis of unknown aetiology in children - Multi-country. <https://www.who.int/emergencies/disease-outbreak-news/item/DON-389>. Accessed 31 May 2022.
3. European Centre for Disease Prevention and Control/WHO Regional Office for Europe. Hepatitis of Unknown Aetiology in Children, Joint Epidemiological overview. <https://cdn.ecdc.europa.eu/novhep-surveillance>. Accessed 31 May 2022.
4. UK Health Security Agency. Increase in hepatitis (liver inflammation) cases in children under investigation. <https://www.gov.uk/government/news/increase-in-hepatitis-liver-inflammation-cases-in-children-under-investigation>. Accessed 31 May 2022.
5. Brazilian Ministry of Health. Daily report of the national situation on hepatitis of unknown aetiology. <https://www.gov.br/saude/pt-br/composicao/svs/resposta-a-emergencias/sala-de-situacao-de-saude/hepatites-agudas-graves-de-etilogia-a-esclarecer/atualizacao-dos-casos-no-brasil/informe-diario-da-sala-de-situacao-nacional-de-hepatites-agudas-de-etilogia-a-esclarecer-no-17-se-22>. Accessed 31 May 2022 (in Portuguese).
6. Ministry of Health, Labour and Welfare of Japan. About acute hepatitis of unknown cause in children (27 May 2022). https://www.mhlw.go.jp/stf/newpage_25927.html. Accessed 31 May 2022 (in Japanese).
7. European Centre for Disease Prevention and Control. Epidemiological update issued 19 May 2022: hepatitis of unknown aetiology in children. <https://www.ecdc.europa.eu/en/news-events/epidemiological-update-issued-19-may-2022-hepatitis-unknown-aetiology-children>. Accessed 31 May 2022.
8. World Health Organization. Multi-Country – Acute, severe hepatitis of unknown origin in children. <https://www.who.int/emergencies/disease-outbreak-news/item/2022-DON376>. Accessed 31 May 2022.
9. UK Health Security Agency. Investigation into acute hepatitis of unknown aetiology in children in England. <https://www.gov.uk/government/publications/acute-hepatitis-technical-briefing>. Accessed 31 May 2022.
10. OzbayHoşnut F, Canan O, Ozçay F, Bilezikçi B. Adenovirus infection as possible cause of acute liver failure in a healthy child: a case report. *Turk J Gastroenterol*. 2008;19:281–3.
11. South MA, Dolen J, Beach DK, Mirkovic RR. Fatal adenovirus hepatic necrosis in severe combined immune deficiency. *Pediatr Infect Dis*. 1982;1:416–9.
12. Gu J, Su QQ, Zuo TT, Chen YB. Adenovirus diseases: a systematic review and meta-analysis of 228 case reports. *Infection*. 2021;49:1–13.
13. Johansson ME, Brown M, Hierholzer JC, Thörner A, Ushijima H, Wadell G. Genome analysis of adenovirus type 31 strains from immunocompromised and immunocompetent patients. *J Infect Dis*. 1991;163:293–9.
14. Mücke MM, Zeuzem S. The recent outbreak of acute severe hepatitis in children of unknown origin - what is known so far. *J Hepatol*. 2022;S0168–8278:00271–9.
15. Perez A, Cantor A, Rudolph B, Miller J, Kogan-Liberman D, Gao Q, et al. Liver involvement in children with SARS-CoV-2 infection: two distinct clinical phenotypes caused by the same virus. *Liver Int*. 2021;41:2068–75.
16. Cantor A, Miller J, Zachariah P, DaSilva B, Margolis K, Martinez M. Acute hepatitis is a prominent presentation of the multisystem inflammatory syndrome in children: a single-center report. *Hepatolgy*. 2020;72:1522–7.
17. Verdoni L, Mazza A, Gervasoni A, Martelli L, Ruggeri M, Ciuffreda M, et al. An outbreak of severe Kawasaki-like disease at the Italian epicentre of the SARS-CoV-2 epidemic: an observational cohort study. *Lancet*. 2020;395:1771–8.
18. Yonker LM, Gilboa T, Ogata AF, Senussi Y, Lazarovits R, Boribong BP, et al. Multisystem inflammatory syndrome in children is driven by zonulin-dependent loss of gut mucosal barrier. *J Clin Invest*. 2021. <https://doi.org/10.1172/JCI149633>.
19. Brodin P. SARS-CoV-2 infections in children: understanding diverse outcomes. *Immunity*. 2022;55:201–9.
20. Kabeerdoss J, Pilania RK, Karkhele R, Kumar TS, Danda D, Singh S. Severe COVID-19, multisystem inflammatory syndrome in children, and Kawasaki disease: immunological mechanisms, clinical manifestations and management. *Rheumatol Int*. 2021;41:19–32.
21. Yarovinsky TO, Mohning MP, Bradford MA, Monick MM, Hunninghake GW. Increased sensitivity to staphylococcal enterotoxin B following adenoviral infection. *Infect Immun*. 2005;73:3375–84.
22. Brodin P, Arditi M. Severe acute hepatitis in children: investigate SARS-CoV-2 superantigens. *Lancet Gastroenterol Hepatol*. 2021;41:19–32.
23. Smolka V, Tkachyk O, Ehrmann J, Karaskova E, Zapalka M, Volejnikova J. Acute onset of autoimmune hepatitis in children and adolescents. *Hepatobiliary Pancreat Dis Int*. 2020;19:17–21.
24. Manns MP, Lohse AW, Vergani D. Autoimmune hepatitis—update 2015. *J Hepatol*. 2015;62:S100–11.
25. Mack CL, Adams D, Assis DN, Kerkar N, Manns MP, Mayo MJ, et al. Diagnosis and management of autoimmune hepatitis in adults and children: 2019 practice guidance and guidelines from the American association for the study of liver diseases. *Hepatology*. 2020;72:671–722.
26. Donaldson PT. Genetics of autoimmune and viral liver diseases; understanding the issues. *J Hepatol*. 2004;41:327–32.
27. Peiseler M, Sebode M, Franke B, Wortmann F, Schwinge D, Quaa A, et al. FOXP3+ regulatory T cells in autoimmune hepatitis are fully functional and not reduced in frequency. *J Hepatol*. 2012;57:125–32.
28. Ma Y, Su H, Yuksel M, Longhi MS, McPhail MJ, Wang P, et al. Human leukocyte antigen profile predicts severity of autoimmune liver disease in children of European ancestry. *Hepatology*. 2021;74:2032–46.
29. Kalil AC, Patterson TF, Mehta AK, Tomashek KM, Wolfe CR, Ghazaryan V, et al. Baricitinib plus remdesivir for hospitalized adults with Covid-19. *N Engl J Med*. 2021;384:795–807.

Publisher's Note Springer Nature remains neutral with regard to jurisdictional claims in published maps and institutional affiliations.