


# The Role of Genetic Testing in Hereditary Poikiloderma: A Case Report

Global Pediatric Health  
Volume 4: 1–3  
© The Author(s) 2017  
Reprints and permissions:  
sagepub.com/journalsPermissions.nav  
DOI: 10.1177/2333794X17715840  
journals.sagepub.com/home/gph  


Sarah El-Heis, MBBS<sup>1,2</sup> and Keith M. Godfrey, BM, PhD, FRCP<sup>1,2</sup>

Received April 13, 2017. Accepted for publication May 11, 2017

## Case Report and Hospital Course

This 4-year-old girl who was born at 33 weeks to non-consanguineous parents from Afghanistan presented at the age of 24 months with mottled hypo- and hyperpigmentation. She was otherwise well, growing, and achieving her developmental milestones. Nucleotide excision repair studies and histology ruled out xeroderma pigmentosum; skin biopsy showed an epidermis with focal areas of slight atrophy and flattening, focal very mild hyperkeratosis, basal pigmentation consistent with pigmented skin, a slightly thickened papillary dermis, and dermal melanophages together with pigmentary incontinence (Figure 1a-c). No significant inflammatory infiltrate of the papillary dermis, elastosis, or parakeratosis was evident.

In the following months, the pigmentary changes became more widespread involving the limbs and included the palms and soles and the trunk to a lesser extent (Figure 2a and b). There was evidence of poikiloderma as skin atrophy and telangiectasia were noted. Thickening of the toenails developed. There was no lymphadenopathy or hepatosplenomegaly. Blood counts showed noncyclic neutropenia (neutrophil count  $0.3 \times 10^9/L$ ); however, this was not associated with recurrent infections. A connective tissue disease screen was negative and immunoglobulin concentrations were unremarkable.

The clinical features of poikiloderma and nail changes with neutropenia suggested Clericuzio-type poikiloderma with neutropenia (PN) syndrome. Genetic testing through whole exome and direct Sanger sequencing identified a novel homozygous missense mutation c.623A>G, p.His208Arg in the USB1 gene. The telomere length was normal. With molecular genetic testing confirming the diagnosis of PN, genetic counseling was offered and pediatric monitoring of growth and development, hematological surveillance for dysmyelopoiesis, and dermatological surveillance for malignancy were instigated.

## Diagnosis

Clericuzio-type poikiloderma with neutropenia syndrome.

## Discussion and Conclusion

PN is a rare autosomal recessive inherited genodermatosis, described first in Navajo Indians by Clericuzio in 1991.<sup>1</sup> The clinical features of PN include poikiloderma, nail abnormalities, and noncyclic neutropenia. Skin changes in the first year of life are described as eczematous or a papular erythematous rash evolving into poikiloderma, with telangiectasia and skin atrophy having a marked acral distribution.<sup>2</sup> Nail changes described are primarily pachyonychia, tending to affect the toenails.<sup>2</sup> Growth retardation, lacrimal duct obstruction, and palmo-plantar hyperkeratosis are generally accepted findings. Skeletal defects, dental caries, facial dysmorphism, hepatosplenomegaly, and photosensitivity have also been described.<sup>3,4</sup> Patients may be predisposed to recurrent infections, particularly of the respiratory tract, due to noncyclic neutropenia and neutrophil functional defects.<sup>2</sup> Neutropenia and myelodysplasia arise due to bone marrow alterations, with a risk of leukemic transformation reported to occur before the second decade of life.<sup>2</sup> Furthermore, cutaneous squamous cell carcinoma has been reported in 2 cases.<sup>5,6</sup>

The known causative mutations are mainly biallelic truncating mutations in USB1 (formerly known as

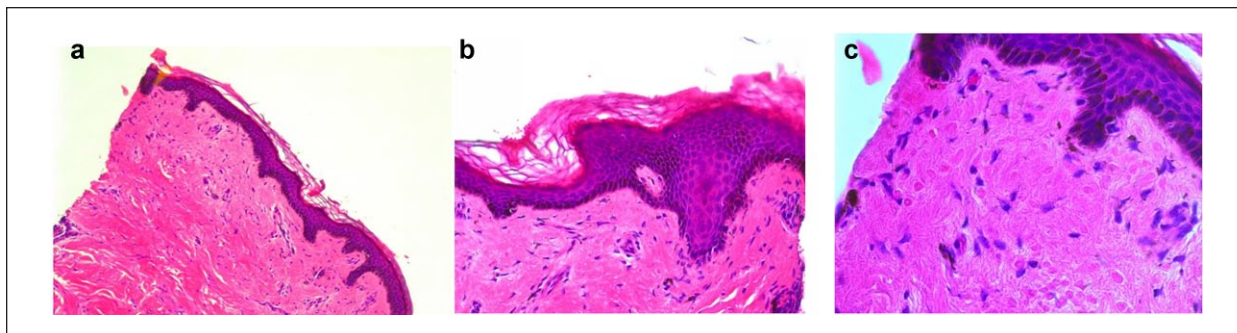
<sup>1</sup>MRC Lifecourse Epidemiology Unit, University of Southampton, Southampton, UK

<sup>2</sup>University Hospital Southampton NHS Foundation Trust, Southampton, UK

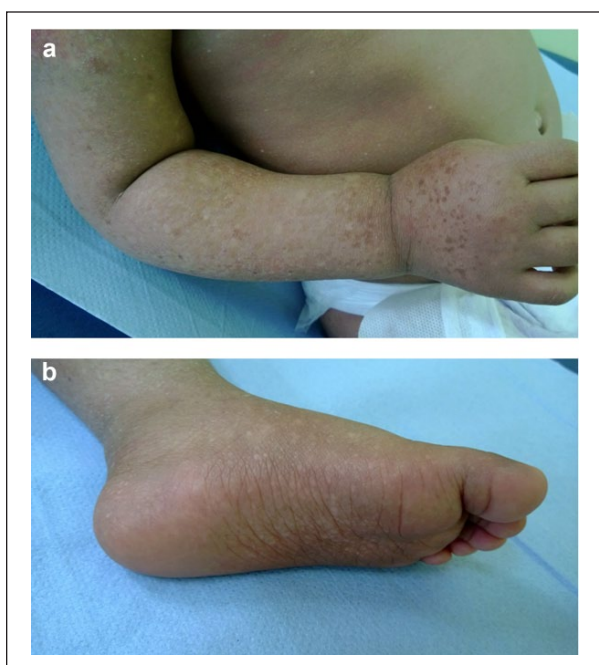### Corresponding Author:

Keith M. Godfrey, MRC Lifecourse Epidemiology Unit (University of Southampton), Southampton General Hospital, Mailpoint 95, Southampton SO16 6YD, UK.  
Email: kmg@mrc.soton.ac.uk





**Figure 1.** Histology of skin demonstrating (a) focal areas of epidermal atrophy and flattening with the loss of the ridges ( $\times 10$  magnification), (b) mild focal hyperkeratosis ( $\times 20$  magnification), and (c) basal pigmentation consistent with pigmented skin. Thickened papillary dermis, dermal melanophages with pigmentary incontinence ( $\times 40$  magnification).



**Figure 2.** Poikilodermatous changes affecting (a) the upper limb and (b) lower limbs including the soles of the feet.

C16orf57), a gene located at 16q21 encoding for a protein that is crucial for U6snRNA (small nucleolar RNA) processing and stability.<sup>7</sup> U6snRNA has a vital role in RNA splicing and functions as a 3'-5' exoribonuclease that removes both adenosine and uridine residues from the 3'-end of U6 snRNA.<sup>7</sup> To date there have been 40 reported cases and 19 disease causing mutations. The variants reported in USB1 are predicted to be loss of function (splicing, nonsense, or frame shift).<sup>8</sup> The current patient has been reported by Walne et al in a recent case series that describes whole exome and direct Sanger sequencing used to identify

casual genetic variants in a subset of patients with a clinical diagnosis of dyskeratosis congenita (DC) or with overlapping features.<sup>9</sup> The missense variant identified in our patient affects pHis208, a crucial residue, which is in 1 of the 2 highly conserved H-x-S motifs shown to mediate the 3'-5' exoribonuclease activity of U6 snRNA in vitro,<sup>7</sup> and therefore thought to be disease causing.

Little is known about USB1 mutations in acquired myelodysplastic syndrome, although mutations in the spliceosome machinery are recognized in leukemogenesis.<sup>10</sup> The defective USB1 gene affects myeloid hemostasis and

neutrophil maturation and reports of myelodysplastic syndrome and acute myeloid leukemia support the classification of PN as a bone marrow failure syndrome with a predisposition to malignancies.<sup>10</sup> In cases where hematopoietic stem cell transplantation may be required, molecular genetic studies can aid in the selection of healthy sibling donors, highlighting the value of these studies in planning management.

Hereditary poikilodermas such as xeroderma pigmentosum (XP), Rothmund-Thomson syndrome (RTS), and DC can be phenotypically similar to PN, but result from different gene mutations. Photodistribution of the poikiloderma is a feature of XP and RTS, the diagnosis of which can be confirmed by nucleotide excision repair studies and identification of RECQL4 gene mutations, respectively. DC can result from a number of various gene mutations encoding for products essential for telomere maintenance. A short telomere length below the first centile is considered to be diagnostic for DC<sup>11</sup>; in PN, however, telomere length is not known to be affected.

Identification of all the coding regions in a gene by whole exome sequencing has been instrumental in determining casual gene mutations in variants of disease, and

can be particularly helpful in conditions with considerable phenotypic overlap, such as those described above. This case illustrates the value of targeted molecular studies of USB1 mutations and telomere length in confirming a clinical diagnosis of PN, enabling selection of further tests and management. Pediatric involvement in monitoring growth and development, hematological monitoring of neutrophil count and evidence of myelodysplastic syndrome or acute myeloid leukemia, and dermatological surveillance for skin malignancies are crucial. The involvement of a clinical geneticist can provide further insights into the family history and offer genetic counselling. Specific guidelines on management and follow-up of PN do not exist and while the risks associated with the condition are not fully understood, it is recognized that a multidisciplinary approach to management is needed.

### Acknowledgments

We would like to acknowledge Dr Amanda Walne and the staff at the Barts and the London Genome Centre for Sanger sequencing analysis and the clinicians who have been involved in this patient's care.

### Author Contributions

SE: Contributed to interpretation; drafted the manuscript; critically revised the manuscript; gave final approval; agrees to be accountable for all aspects of work ensuring integrity and accuracy.

KMG: Contributed to conception and design; contributed to acquisition, analysis, and interpretation; critically revised the manuscript; gave final approval; agrees to be accountable for all aspects of work ensuring integrity and accuracy.

### Declaration of Conflicting Interests

The author(s) declared no potential conflicts of interest with respect to the research, authorship, and/or publication of this article.

### Funding

The author(s) disclosed receipt of the following financial support for the research, authorship, and/or publication of this article: Financial support was provided by The Medical Research Council and Children with Cancer. KMG is

supported by the National Institute for Health Research through the NIHR Southampton Biomedical Research Centre.

### References

1. Clericuzio C, Hoyme HE, Aase JM. Immune deficient poikiloderma: a new genodermatosis. *Am J Hum Genet.* 1991;49(suppl):A661.
2. Volpi L, Roversi G, Colombo EA, et al. Targeted next-generation sequencing appoints C16orf57 as Clericuzio-type poikiloderma with neutropenia gene. *Am J Hum Genet.* 2010;86:72-76.
3. Mostefai R, Morice-Picard F, Boralevi F, et al. Poikiloderma with neutropenia, Clericuzio type, in a family from Morocco. *Am J Med Genet A.* 2008;146A:2762-2769.
4. Arnold AW, Itin PH, Pigors M, Kohlhase J, BrucknerTuderman L, Has C. Poikiloderma with neutropenia: a novel C16orf57 mutation and clinical diagnostic criteria. *Br J Dermatol.* 2010;163:866-869.
5. Rodgers W, Ancliff P, Ponting CP, et al. Squamous cell carcinoma in a child with Clericuzio-type poikiloderma with neutropenia. *Br J Dermatol.* 2013;168:665-667.
6. Walne AJ, Vulliamy T, Beswick R, Kirwan M, Dokal I. Mutations in C16orf57 and normal-length telomeres unify a subset of patients with dyskeratosis congenita, poikiloderma with neutropenia and Rothmund-Thomson syndrome. *Hum Mol Genet.* 2010;19:4453-4461.
7. Hilcenko C, Simpson PJ, Finch AJ, et al. Aberrant 3' oligoadenylation of spliceosomal U6 small nuclear RNA in poikiloderma with neutropenia. *Blood.* 2013;121:1028-1038.
8. Koparir A, Gezdirici A, Koparir E, et al. Poikiloderma with neutropenia: genotype-ethnic origin correlation, expanding phenotype and literature review. *Am J Med Genet A.* 2014;164A:2535-2540.
9. Walne AJ, Collopy L, Cardoso S, et al. Marked overlap of four genetic syndromes with dyskeratosis congenita confounds clinical diagnosis. *Haematologica.* 2016;101:1180-1189.
10. Negri G, Crescenzi B, Colombo EA, et al. Expanding the role of the splicing USB1 gene from poikiloderma with neutropenia to acquired myeloid neoplasms. *Br J Haematol.* 2015;171:557-565.
11. Alter BP, Rosenberg PS, Giri N, Baerlocher GM, Lansdorp PM, Savage SA. Telomere length is associated with disease severity and declines with age in dyskeratosis congenita. *Haematologica.* 2012;97:353-359.