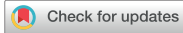

Case Report



Rapid Spontaneous Resolution of Contralateral Lentiform Acute Subdural Hematoma After Burr Hole Trephination for Chronic Subdural Hematoma

Hyun Chul Jung ¹, Jung Hyeon Moon ^{1,2}, and Keun-Tae Cho ^{1,2}

¹Department of Neurosurgery, Dongguk University Ilsan Hospital, Goyang, Korea

²Department of Neurosurgery, Dongguk University, Seoul, Korea



Received: Nov 29, 2021

Revised: Jan 14, 2022

Accepted: Mar 4, 2022

Published online: Mar 28, 2022

Address for correspondence:

Keun-Tae Cho

Department of Neurosurgery, Dongguk University Ilsan Hospital, 27 Dongguk-ro, Ilsandong-gu, Goyang 10326, Korea.
Email: ktcho21@naver.com

Copyright © 2022 Korean Neurotraumatology Society

This is an Open Access article distributed under the terms of the Creative Commons Attribution Non-Commercial License (<https://creativecommons.org/licenses/by-nc/4.0/>) which permits unrestricted non-commercial use, distribution, and reproduction in any medium, provided the original work is properly cited.

ORCID iDs

Hyun Chul Jung

<https://orcid.org/0000-0001-6541-1247>

Jung Hyeon Moon

<https://orcid.org/0000-0003-1582-2288>

Keun-Tae Cho

<https://orcid.org/0000-0002-8372-7250>

Conflict of Interest

The authors have no financial conflicts of interest.

ABSTRACT

Although rare, acute subdural hematoma (ASDH) may occur after burr hole trephination (BHT) for chronic subdural hematoma (CSDH). It usually occurs in the hemisphere ipsilateral to the burr hole site and rarely in the hemisphere contralateral to the burr hole site. On computed tomography (CT), SDH is usually crescent-shaped and occasionally lentiform or biconvex, which can be misdiagnosed as epidural hematoma (EDH). In rare cases, ASDH may resolve spontaneously and rapidly. Here, we report a case of rapid spontaneous resolution of contralateral lentiform ASDH after BHT for CSDH in a patient with brain atrophy. A 55-year-old man developed left CSDH 2 months after traumatic brain injury. Left BHT was performed, and a lentiform hematoma, presumed to be EDH, was found in the right frontal region on the CT scan acquired immediately after BHT. On the CT scan acquired 12 hours later, the lentiform hematoma disappeared and spread along the hemisphere. It was presumed to be ASDH. To prevent contralateral ASDH after BHT, slow decompression and minimal gentle or no irrigation should be performed during BHT, particularly in patients with brain atrophy.

Keywords: Hematoma, subdural, acute; Hematoma, subdural, chronic; Trephining

INTRODUCTION

Burr hole trephination (BHT) is one of treatment modalities for chronic subdural hematoma (CSDH) or subdural hygroma (SH). Postoperative hemorrhage is one of complications of BHT.¹³ Acute subdural hematoma (ASDH), acute epidural hematoma (AEDH), intracerebral hemorrhage, subarachnoid hemorrhage (SAH), and hematoma between inner and outer layers of the dura, brain stem hemorrhage, and cerebellar hemorrhage after BHT have been reported.^{3,10,13} Although these hemorrhages mainly occur in the hemisphere ipsilateral to the burr hole site, in rare cases they can occur at a remote site from the burr hole site or in the hemisphere contralateral to the burr hole site.^{2,3,13} Although contralateral ASDH after BHT is very rare, it is sometimes fatal.^{5,18} Although the typical shape of subdural hematoma (SDH) on computed tomography (CT) scan is a crescent shape, sometimes SDH has a lentiform or

biconvex shape that is typical of epidural hematoma (EDH) on CT scan.^{11,14)} In such case, SDH can be misdiagnosed as EDH.^{11,14)} Although rare, ASDH may disappear spontaneously within a short time without surgery.^{7,12,17,19)}

Herein, we report a case of rapid spontaneous resolution of contralateral lentiform ASDH after BHT for CSDH in a patient with brain atrophy and review relevant literature.

CASE REPORT

A 55-year-old male patient visited the emergency room with worsening headache. He was not taking any medications including antiplatelet agent or anticoagulant. He was an alcoholic. Blood tests showed normal platelet count, prothrombin time, activated partial thromboplastin time, and liver enzyme levels. He had a history of craniotomy in the left temporoparietal area due to EDH and cerebral contusion after traumatic brain injury (TBI) 13 years ago. Since then, he had right hemiparesis of muscle power grade 4 without significant disturbance in daily life.

After falling down 2 months ago, he had a headache. He was admitted to our hospital. Brain CT scan taken at that time showed AEDH with a maximum thickness of 18mm in both parietooccipital region and left cerebellum, bifrontal cerebral contusion, ASDH and traumatic SAH in the right frontal region, and interhemispheric ASDH (**FIGURE 1A-C**). He

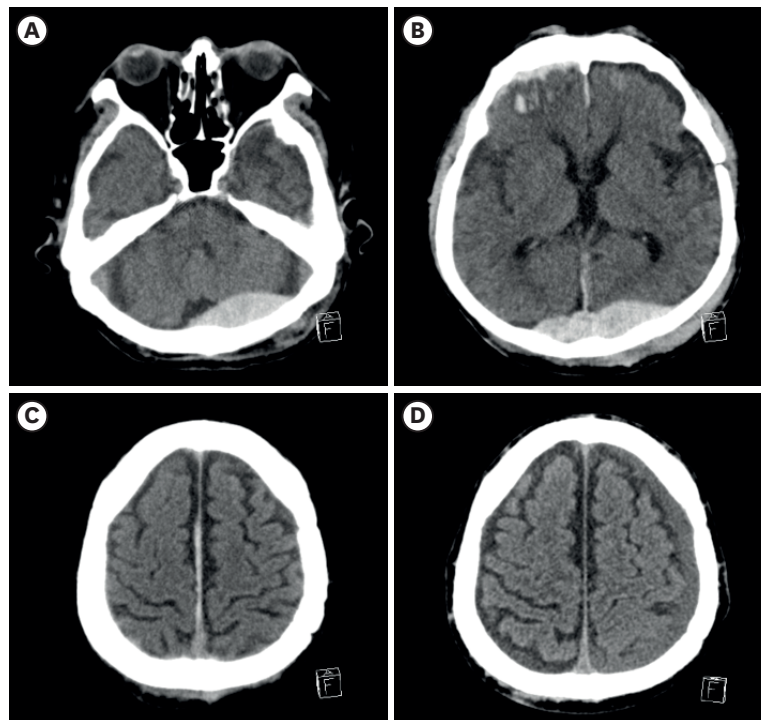


FIGURE 1. Brain CT scan after traumatic brain injury 2 months ago. (A) CT scan shows AEDH in the left cerebellum. (B) CT scan shows AEDH in the bilateral parietooccipital region with a maximum thickness of 18 mm, bifrontal cerebral contusion, and ASDH and traumatic subarachnoid hemorrhage in the right frontal region. CT scan also shows widening of Sylvian fissure. (C) CT scan shows interhemispheric ASDH, widening of interhemispheric fissure, and cortical sulci. (D) CT scan taken 1 month later shows left CSDH with maximum thickness of 8 mm. CT: computed tomography, AEDH: acute epidural hematoma, ASDH: acute subdural hematoma, CSDH: chronic subdural hematoma.

received non-surgical treatment because his headache was mild, he was alert, there was no exacerbation of preexisting neurological deficit, and no midline shift (MLS) on the CT scan. His headache gradually improved. Pre-existing neurological deficits did not worsen. No new neurological deficits developed. On the CT scan taken 1 month later, the amount of AEDH, ASDH, contusion, and traumatic SAH decreased. However, CSDH with maximum thickness of 8 mm was developed in the left cerebral hemisphere (**FIGURE 1D**). The size of the CSDH was less than 10 mm. There were no associated neurologic deficits. Thus, we decided to follow up the patient in the outpatient clinic. He was discharged from the hospital.

However, his headache resumed 2 weeks after discharge and gradually worsened. He was admitted to the emergency room 3 weeks after discharge. Neurological examination showed no new neurological deficits. On CT scan, AEDH, ASDH, contusion, and traumatic SAH almost disappeared (**FIGURE 2A & B**). On the other hand, the left CSDH much increased with a maximum thickness of 30 mm in the high frontal area accompanied by acute blood clot and MLS of 8 mm to the right side on CT scan (**FIGURE 2B & C**). He underwent 2 BHT, irrigation, and drainage catheter insertion under general anesthesia. When opening the dura and outer membrane of the CSDH, a dark brown-colored thick fluid flowed out with high pressure. When the subdural space (SDS) was irrigated with normal saline, a small amount of blood clot also flowed out. There was no active bleeding from the burr hole site. He recovered well from general anesthesia. There was no neurological deterioration after the surgery. No fresh blood or cerebrospinal fluid (CSF) was drained through the drainage catheter during and immediately after the surgery.

On the CT scan taken immediately after the surgery, the amount of CSDH was reduced, and MLS was corrected. However, new lentiform high density lesion presumed to be AEDH occurred in the right frontal region (**FIGURE 3A**). On the follow-up CT scan taken 12 hours later, the lentiform hematoma disappeared and spread along the right SDS. Thus, it was presumed to be ASDH, not AEDH (**FIGURE 3B**). A CT scan taken 3 weeks later showed right CSDH. He received one BHT and drainage catheter insertion without irrigation. Thereafter, he recovered without any problems. He was discharged from the hospital 10 days later.

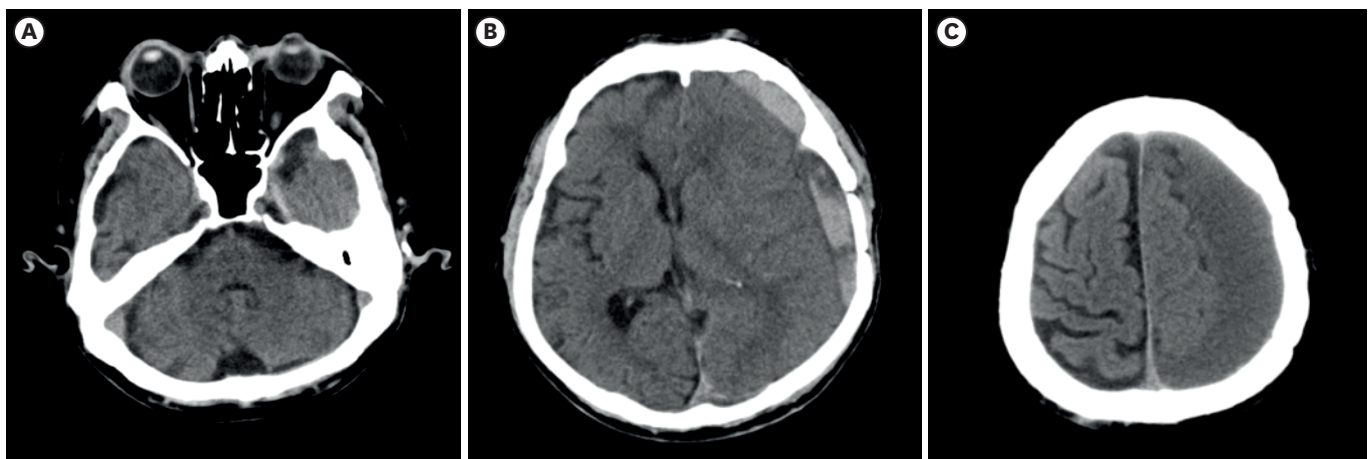


FIGURE 2. Brain CT scan at 3 weeks after discharge. (A) CT scan shows resolution of AEDH in the left cerebellum. (B) CT scan shows resolution of AEDH in the bilateral parietooccipital region, bifrontal cerebral contusion, ASDH and traumatic subarachnoid hemorrhage in the right frontal region. However, CT shows mixed density left SDH with midline shift of 8 mm. (C) CT scan shows CSDH with a maximum thickness of 30 mm in high frontal region. CT: computed tomography, AEDH: acute epidural hematoma, ASDH: acute subdural hematoma, SDH: subdural hematoma, CSDH: chronic subdural hematoma.

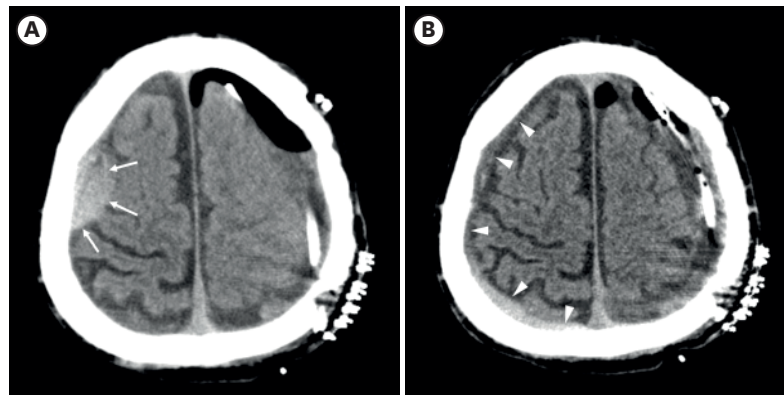


FIGURE 3. Brain CT scan after BHT. (A) CT scan taken immediately after BHT shows lentiform high density hematoma (arrows) in the right frontal region. (B) CT scan taken 12 hours later shows disappearance of lentiform hematoma and spread of the hematoma along the right cerebral hemisphere (arrow heads).
CT: computed tomography, BHT: burr hole trephination.

DISCUSSION

Contralateral ASDH after BHT

After BHT for CSDH or SH, ASDH may occur in the hemisphere ipsilateral to the burr hole site occasionally. However, ASDH occurring in the hemisphere contralateral to the burr hole site is extremely rare. We found a total of 9 cases of contralateral ASDH after BHT for CSDH or SH through literature search in PUBMED and Google Scholar. They are summarized in **TABLE 1**.^{2,4,5,6,8,15,16,18,19)} After BHT and opening the dura and outer membrane of CSDH, as CSDH flows out through the burr hole, intracranial pressure (ICP) decreases, the brain compressed by CSDH is decompressed or expanded, and the brain that has shifted to the contralateral side returns to the midline. When brain shift to the midline occurs too rapidly, contralateral bridging veins (BVs) that run between the dura and brain surface can be stretched and torn, resulting in ASDH.^{2,5,6,8,15,16)} Tear of BV has been confirmed in the cases where surgical treatment was performed to remove contralateral ASDH after BHT.^{4,8,15)} When there is brain atrophy, the subarachnoid space (SAS) and SDS can be widened and the

TABLE 1. CL ASDH after unilateral BHT for CSDH or SH

Authors	Year	Age/Sex	Irrigation	Time of Dx after BHT	Concomitant lesion	Symptoms or signs	OP for CL ASDH	Remark
Harada et al. ⁴⁾	1992	71/M	NM	The next day	(-)	None	Craniectomy	CL lentiform ASDH
Turgut et al. ¹⁸⁾	1998	66/M	NM	The 4th hour	(-)	Intraoperative transient rise in arterial pressure, coma, hemiparesis	BHT	Patient died the 2nd postoperative day
Liang et al. ⁸⁾	2001	44/M	NM	The 6th hour	Subdural effusion	Neurological deterioration	Craniotomy	
Su et al. ¹⁵⁾	2001	78/F	(+)	Immediately	SAH	Bloody fluid flowing into drainage tube at the end of BHT CL pupil dilatation after OP	Craniotomy	Patient died 10 days after craniotomy
Kim et al. ⁶⁾	2007	48/F	NM	7 hours	IL ASDH	Worsening headache, nausea, vomiting	(-)	Craniotomy for IL ASDH
An et al. ²⁾	2011	80/F	(+)	Immediately	CL ICH	Intraoperative 100 mL of hematoma fluid from drainage catheter	(-)	CL CSDH before BHT
Sun et al. ¹⁶⁾	2014	80/M	(+)	3 days	(-)	IL hemiparesis	BHT	CL SH before BHT
Yoo et al. ¹⁹⁾	2018	82/F	(-)	NM	(-)	Postoperative 300 mL of sudden drainage from the CSDH	(-)	Rapid spontaneous resolution of CL ASDH
Kaneshiro et al. ⁵⁾	2019	72/F	(+)	The next day	Interhemispheric ASDH	Persistent headache	(-)	CL CSDH before BHT

CL: contralateral, ASDH: acute subdural hematoma, BHT: burr hole trephination, CSDH: chronic subdural hematoma, SH: subdural hygroma, Dx: diagnosis, OP: operation, M: male, NM: not mentioned, F: female, SAH: subarachnoid hemorrhage, IL: ipsilateral, ICH: intracerebral hemorrhage.

distance between the dura and brain surface can increase, which can lead to more stretched BVs.⁹⁾ Thus, even a slight trauma can cause rupture of BVs.⁹⁾ In our literature review, CSDH or SH on the contralateral side of the burr hole site was present before BHT in 3 cases.^{2,5,16)} In these cases, as in the case of brain atrophy, the distance between the dura and brain surface increased. Thus, it was presumed that BVs had already been stretched before BHT.

In the present case, the patient is an alcoholic. He had a history of recent and remote TBI. He seemed to have brain atrophy based on findings of widening of the Sylvian and interhemispheric fissure, and cortical sulci on CT scan. It was presumed that BV had already been weakened by stretching due to brain atrophy before CSDH developed. As the shifted brain rapidly returned to the midline during or after drainage of CSDH, tear of BV might have occurred in the present case.

Massive irrigation might be a cause of rapid brain shift and resultant tear of BV in the present case. Kaneshiro et al.⁵⁾ have speculated in their case report that irrigation might change ICP rapidly. In our literature review, irrigation was performed in 4 out of 5 cases that mentioned whether or not irrigation was performed (**TABLE 1**).^{2,5,15,16,19)} In addition, contralateral ASDH developed after BHT when there was an episode of intraoperative transient rise in arterial pressure, intraoperative drainage of bloody fluid or hematoma fluid, or postoperative sudden drainage of a large amount of CSDH (**TABLE 1**).^{2,15,18,19)} In the present case, there were no aforementioned events during or immediately after the surgery. Symptoms and signs of contralateral ASDH after BHT ranged from asymptomatic as in the present case or mild symptoms such as headache, nausea, or vomiting, to grave signs such as hemiparesis, dilated pupil, and coma (**TABLE 1**).^{4,5,6,15,16,18)} In 5 cases, surgical treatment including craniotomy, craniectomy, or BHT was performed to remove contralateral ASDH (**TABLE 1**).^{4,8,15,16,18)} In most cases, the prognosis was good. However, in 2 cases patients died despite surgical treatment to remove contralateral ASDH (**TABLE 1**).^{15,18)} In the present case, no surgical treatment for removal of contralateral ASDH was performed because the amount of ASDH was small and there was no symptom or sign related to contralateral ASDH. In the present case, although the patient received another BHT due to progression of ASDH to CSDH, the prognosis was good.

To prevent contralateral ASDH after BHT, some authors have argued that slow decompression is necessary to minimize rapid dynamic intracranial changes including rapid brain shift.^{5,15,16)} However, an appropriate rate of decompression or a method for controlling decompression rate is not known yet. Turgut et al.¹⁸⁾ have argued that blood pressure control during surgery is important in addition to slow decompression. Kaneshiro et al.⁵⁾ have suggested exclusion of irrigation or gentle irrigation for removal of CSDH because irrigation may change ICP rapidly. In the present case, in order to drain CSDH slowly during right BHT, several sheets of cottonoid were placed on the burr hole after opening the dura and outer membrane of CSDH. These sheets were then removed one by one without performing irrigation.

Lentiform or biconvex-shaped ASDH

In the present case, lentiform high density lesion appeared in the hemisphere contralateral to the burr hole site on the CT scan taken immediately after BHT. We thought it was AEDH until the follow-up CT scan was taken. Since the SDS is a potential space without barriers, the typical finding of ASDH on CT scan is a hyperdense crescent-shaped lesion between the dura and the SAS along the cerebral hemisphere.^{11,14)} In most cases, it is not difficult to differentiate between lentiform or biconvex-shaped AEDH and crescent-shaped ASDH on CT scan.¹⁴⁾ However, sometimes lentiform or biconvex-shaped ASDHs may occur and cause

ASDH to be misdiagnosed as AEDH.¹⁴⁾ Cases of lentiform ASDH in the hemisphere ipsilateral or contralateral to the burr hole site within 3 days after BHT have been reported.^{1,4)} In 2017, Prasad et al.¹¹⁾ reviewed their 1 case of lentiform ASDH and 15 such cases reported previously, and suggested situations in which the possibility of ASDH rather than AEDH should be considered even for lentiform hematoma. “Patients with contralateral or a previously evacuated CSDH” was one of such situations.¹¹⁾ However, they did not comment on the causes.¹¹⁾

The cause of lentiform or biconvex-shaped ASDH remains unclear. In previous studies, SDS blockage due to adhesion in the SDS has been suggested as one possible cause.^{4,14)} Su et al.¹⁴⁾ have reported 5 cases of ASDH mimicking AEDH on CT scan. In 4 of 5 cases, they surgically confirmed subdural adhesions, which was presumably secondary to previous intracranial surgery or hemorrhage into the SDS.¹⁴⁾ In the present case, since the patient had a recent and remote history of TBI, the possibility of subdural adhesions due to remote TBI or due to small amount of contralateral CSDH after recent TBI could not be ruled out.

Brain atrophy has been suggested as another cause of lentiform or biconvex-shaped ASDH.¹⁴⁾ Since the arachnoid membrane and brain parenchyme have less resistance than the dura which is firmly attached to the skull, they can be indented more easily.¹¹⁾ In addition, Su et al.¹⁴⁾ have suggested that the possibility that when there is brain atrophy due to TBI, the brain can be more easily indented, which can lead to localized accumulation of ASDH toward the arachnoid rather than toward the dura. This can make lentiform SDH more possible in patients with brain atrophy.¹⁴⁾

In the present case, given that lentiform hematoma disappeared and resolution or redistribution of ASDH appeared in the CT scan taken 12 hours later, it seemed that brain atrophy was more likely to be the cause of lentiform ASDH than subdural blockage. Su et al.¹⁴⁾ have proposed that in patients with subdural blockage, ASDH could not be washed away, eventually causing lentiform ASDH.

Rapid spontaneous resolution of ASDH

In the present case, lentiform ASDH disappeared and the hematoma spread along the cerebral hemisphere on the CT scan taken 12 hours later. Although the true incidence of rapid spontaneous resolution or redistribution of ASDH is unknown, it can occur very rarely.^{7,12,17,19)} Rathore et al.¹²⁾ have reviewed their 5 cases of rapid spontaneous resolution of ASDH within 72 hours and 39 such cases reported previously. In their review, radiological findings of resolution of ASDH or clot reduction started at 1 hour after trauma.¹²⁾

Although the exact mechanism of this phenomenon has not been identified yet, 2 popular hypotheses have been proposed.^{7,12,17)} One hypothesis is that ASDH does not really disappear from the SDS.^{7,12,17)} Rather, it is redistributed along the SDS.^{7,12,17)} ASDH might be compressed by the pressure from underlying cerebral swelling or edema and increased ICP, resulting in redistribution of ASDH along the SDS.^{7,12,17)} In addition, increased ICP due to ASDH can decrease brain compliance.¹²⁾ When pulsation of the brain is well maintained, decreased brain compliance can increase brain pulsation.¹²⁾ Increased brain pulsation can compress and put pressure on ASDH, resulting in redistribution of ASDH along the SDS.¹²⁾

The other hypothesis is dilution of ASDH by CSF.^{7,12,17)} If the arachnoid membrane is torn, CSF can flow out of the tear and dilute ASDH.^{7,12,17)} The ASDH diluted or dissolved by CSF may spread into the SDS rapidly.^{7,12,17)} Sometimes both of these mechanisms may contribute

to rapid resolution of ASDH.¹⁷⁾ In patients with brain atrophy, such as alcoholics, rapid resolution of ASDH may occur easily because there is a wide SDS or SAS where ASDH can be diluted, washed out, or redistributed.^{7,12,17)}

In the present case, there were no evidence of cerebral swelling on CT scan. The patient had no symptoms or signs to suspect increased ICP. The patient recently had cerebral contusion and traumatic SAH in the right frontal region. Thus, arachnoid tear might have occurred. The patient had brain atrophy, presumably caused by alcoholism or previous TBI. Therefore, the cause of rapid spontaneous resolution of ASDH was assumed to be dilution of ASDH by CSF rather than redistribution of ASDH due to cerebral swelling or edema in the present case. On the CT scan taken 12 hours later, hematoma showed mixed density including low density portion in the upper part of SDH. Thus, there was a possibility that CSF was mixed with ASDH. The ASDH diluted by CSF might have spread easily to the wide SDS due to brain atrophy in the present case.

CONCLUSION

Although very rare, ASDH may occur in the hemisphere contralateral to the burr hole site after BHT for CSDH or SH. If there is intraoperative drainage of bloody fluid or hematoma fluid or postoperative sudden drainage of a large amount of CSDH, if there is a sudden transient rise in arterial pressure during BHT, or if there is a persistence or worsening of symptoms or neurological deterioration after BHT, the possibility of contralateral ASDH should be considered as one of the causes. To prevent contralateral ASDH after BHT, slow decompression should be performed during surgery, and irrigation should be avoided as much as possible. If irrigation is required, gentle and minimal irrigation should be performed, especially in patients with brain atrophy.

REFERENCES

1. Ak H, Yolcu S, Atalay T, Kış N. Iatrogenic subdural hematoma mimicking acute epidural hematoma on computed tomography. *J Clin Exp Invest* 4:367-369, 2013
[CROSSREF](#)
2. An GH, Jwa CS. "Contralateral" acute subdural and intracerebral hemorrhage occurring simultaneously after evacuation of huge chronic subdural hematoma. *J Korean Neurotraumatol Soc* 7:39-42, 2011
[CROSSREF](#)
3. Eom KS, Kim TY, Park JT. Contralateral acute interdural haematoma occurring after burr hole drainage of chronic subdural haematoma. *Br J Neurosurg* 23:213-215, 2009
[PUBMED](#) | [CROSSREF](#)
4. Harada K, Ohtsuru K, Nakayama K, Takagi S, Shigemori M, Tokunaga T, et al. Contralateral development of acute subdural hematoma following surgery for chronic subdural hematoma--case report. *Neurol Med Chir (Tokyo)* 32:969-971, 1992
[PUBMED](#) | [CROSSREF](#)
5. Kaneshiro Y, Yamauchi S, Urano Y, Murata K. Remote hemorrhage after burr-hole surgery for chronic subdural hematoma: a report of two cases. *Surg Neurol Int* 10:18, 2019
[PUBMED](#) | [CROSSREF](#)
6. Kim SW, Lee SM, Shin H. Bilateral acute subdural hematoma following evacuation of chronic subdural hematoma. *J Korean Neurosurg Soc* 41:267-268, 2007
[CROSSREF](#)
7. Kwon HC, Hwang YS, Shin HS. Rapid spontaneous resolution of large acute subdural hematoma. *Korean J Neurotrauma* 17:162-167, 2021
[PUBMED](#) | [CROSSREF](#)

8. Liang CL, Rau CS, Lu K, Chen HJ. Contralateral acute subdural haematoma after burr-hole for chronic subdural haematoma. *Injury* 32:499-500, 2001
[PUBMED](#) | [CROSSREF](#)
9. Mortazavi MM, Denning M, Yalcin B, Shoja MM, Loukas M, Tubbs RS. The intracranial bridging veins: a comprehensive review of their history, anatomy, histology, pathology, and neurosurgical implications. *Childs Nerv Syst* 29:1073-1078, 2013
[PUBMED](#) | [CROSSREF](#)
10. Park KJ, Kang SH, Lee HK, Chung YG. Brain stem hemorrhage following burr hole drainage for chronic subdural hematoma-case report-. *Neurol Med Chir (Tokyo)* 49:594-597, 2009
[PUBMED](#) | [CROSSREF](#)
11. Prasad GL, Menon GR. Lentiform subdural hematoma-a rare mimicker of extradural hematoma. *World Neurosurg* 97:738-741, 2017
[PUBMED](#) | [CROSSREF](#)
12. Rathore L, Sahana D, Kumar S, Sahu RK, Jain AK, Tawari M, et al. Rapid spontaneous resolution of the acute subdural hematoma: case series and review of literature. *Asian J Neurosurg* 16:33-43, 2021
[PUBMED](#) | [CROSSREF](#)
13. Rusconi A, Sangiorgi S, Bifone L, Balbi S. Infrequent hemorrhagic complications following surgical drainage of chronic subdural hematomas. *J Korean Neurosurg Soc* 57:379-385, 2015
[PUBMED](#) | [CROSSREF](#)
14. Su IC, Wang KC, Huang SH, Li CH, Kuo LT, Lee JE, et al. Differential CT features of acute lentiform subdural hematoma and epidural hematoma. *Clin Neurol Neurosurg* 112:552-556, 2010
[PUBMED](#) | [CROSSREF](#)
15. Su TM, Shih TY, Yen HL, Tsai YD. Contralateral acute subdural hematoma occurring after evacuation of subdural hygroma: case report. *J Trauma* 50:557-559, 2001
[PUBMED](#) | [CROSSREF](#)
16. Sun HL, Chang CJ, Hsieh CT. Contralateral acute subdural hematoma occurring after evacuation of subdural hematoma with coexistent contralateral subdural hygroma. *Neurosciences (Riyadh)* 19:229-232, 2014
[PUBMED](#)
17. Tsui EY, Fai Ma K, Cheung YK, Chan JH, Yuen MK. Rapid spontaneous resolution and redistribution of acute subdural hematoma in a patient with chronic alcoholism: a case report. *Eur J Radiol* 36:53-57, 2000
[PUBMED](#) | [CROSSREF](#)
18. Turgut M, Akalan N, Sağlam S. A fatal acute subdural hematoma occurring after evacuation of "contralateral" chronic subdural hematoma. *J Neurosurg Sci* 42:61-63, 1998
[PUBMED](#)
19. Yoo M, Kim JS. Rapid spontaneous resolution of contralateral acute subdural hemorrhage caused by overdrainage of chronic subdural hemorrhage. *J Neurocrit Care* 11:119-123, 2018
[CROSSREF](#)