

# A 10-year Follow-up of a Free Vascularized Fibula Flap Clavicle Reconstruction in an Adult

Louie Ye, MD, PhD  
G. Ian Taylor, AO, MD, FRACS

**Summary:** The free vascularized fibula flap has been widely used for clavicle reconstruction. Limited evidence exists for the long-term outcome of clavicle reconstruction using the free vascularized fibula flap in adults. We report the functional and aesthetic outcome in a 52-year old man a decade after clavicle reconstruction using a free vascularized fibula flap in combination with a modified Richardson Hook Plate. At the 10-year follow-up, panoramic shoulder X-ray showed the modified Richardson Hook Plate had remained firmly in place with the fibula and the hook positioned beneath the acromion. Functionally, the patient presented with a constant shoulder score of 77, with a pain-free symmetrical full range of motion. In conclusion, reconstruction of lateral clavicle defect using free vascularized fibula flap in conjunction with modified Richardson Hook plate may provide patients with excellent long-term functional and aesthetic outcomes. (*Plast Reconstr Surg Glob Open* 2017;5:e1317; doi: 10.1097/GOX.0000000000001317; Published online 21 April 2017.)

Since its first description by Taylor in 1975,<sup>1</sup> the free vascularized fibula flap has become the solution to long bone defects in the humerus, radius, ulna, femur, and tibia. In recent years, we and others have used the free vascularized fibula flap for clavicle reconstruction.<sup>2-8</sup> No previous studies, however, have examined the long-term outcome (ie, beyond 4 y) for clavicle reconstruction using the free vascularized fibula flap in the pediatric or adult population. The objective of this report was to review the functional and aesthetic outcome in a single patient a decade after free vascularized fibula flap clavicle reconstruction.

## PATIENT AND METHODS

As previously described by Taylor in 2009,<sup>8</sup> a 52-year-old man initially presented with a 5-cm recurrent dermatofibrosarcoma adherent to the periosteum of the lateral third of the left clavicle that required wide local excision a decade ago (Fig. 1). A left osseocutaneous fibular flap raised on the peroneal vessels was used to bridge the 9.5-cm defect created by removal of the affected clavicle and associated soft tissues, including the deltoid muscle. The transverse cervical artery and external

jugular vein were used for end-to-end anastomosis. The fibula was secured with plates and unicortical screws, including a modified and straightened (Alakus) curved Richardson clavicular dislocation hook plate, which was positioned beneath the acromion to prevent subluxation of the acromioclavicular (AC) joint (Fig. 1). To ensure further clavicular stabilization, a split short head of biceps tendon was used to reconstruct the coracoclavicular ligament. At the 12-month follow-up, the patient displayed normal shoulder movements with aesthetically satisfactory contour of the shoulder. The patient was invited back to the clinic recently to complete a 10-year follow-up.

A panoramic shoulder x-ray was taken at the 10-year follow-up to assess anatomical position of the graft, plate, and hook. The functional outcome was assessed by the Constant–Murley score, an assessment tool used commonly by others to assess shoulder function after clavicle reconstruction.<sup>2,6</sup> The assessment is made up of a 100-points scale including subjective assessment of patient's daily activity of living, and pain level as well as objective assessment of the range of motion: forward elevation, external rotation, abduction, and internal rotation of the shoulder. A high score corresponds to a high quality of the function.

## RESULTS

Panoramic shoulder x-ray taken at the 10-year follow-up showed that the modified Richardson hook plate had remained firmly in place with the fibula and the hook positioned beneath the acromion (Fig. 2). Functionally, the patient presented with a Constant shoulder score of 77, with a pain-free symmetrical full range of motion. Of par-

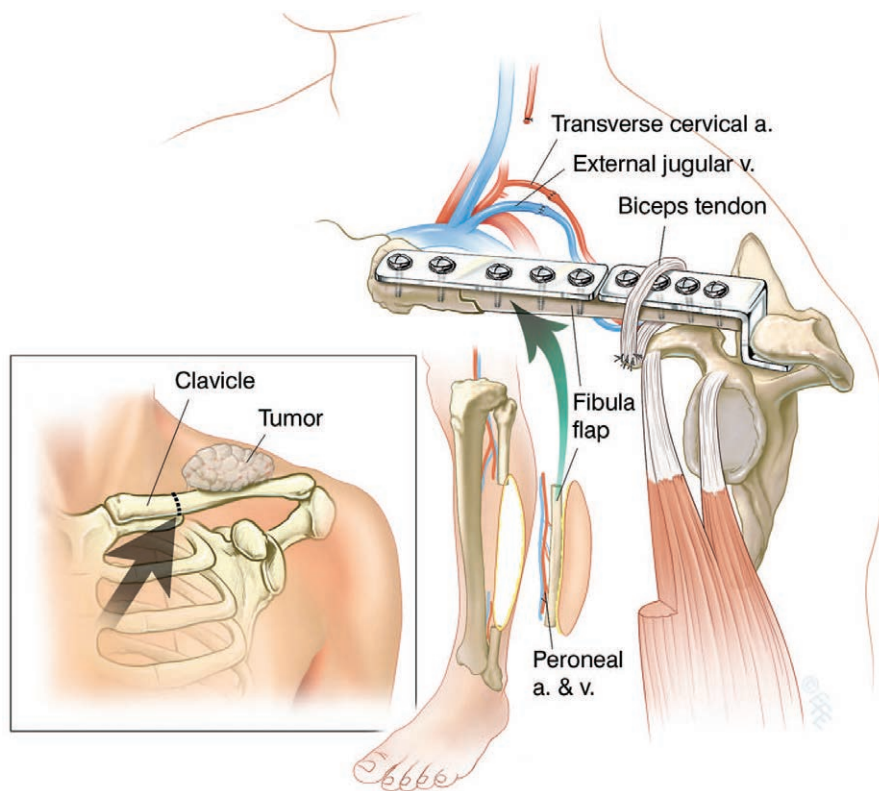
From the Department of Plastic and Reconstructive Surgery, Royal Melbourne Hospital, Melbourne, Victoria, Australia; and Department of Surgery, University of Melbourne, Melbourne, Victoria, Australia.

Received for publication January 26, 2017; accepted March 7, 2017.

Copyright © 2017 The Authors. Published by Wolters Kluwer Health, Inc. on behalf of The American Society of Plastic Surgeons. This is an open-access article distributed under the terms of the Creative Commons Attribution-Non Commercial-No Derivatives License 4.0 (CCBY-NC-ND), where it is permissible to download and share the work provided it is properly cited. The work cannot be changed in any way or used commercially without permission from the journal.

DOI: 10.1097/GOX.0000000000001317

**Disclosure:** The authors have no financial interest to declare in relation to the content of this article. The Article Processing Charge was paid for by the authors.



**Fig. 1.** Schematic diagram illustrates the tumor location, fibular transfer, the split short head of biceps tendon reconstruction of the conoid ligament, and the position of the modified Richardson Hook Plate and the AC joint (reproduced with permission from Taylor et al. Free vascularized fibula flap reconstruction of the clavicle combined with biceps tendon repair of the conoid ligament and customized plate stabilization of the acromioclavicular joint. *Plast Reconstr Surg.* 2009;123:113e–115e).

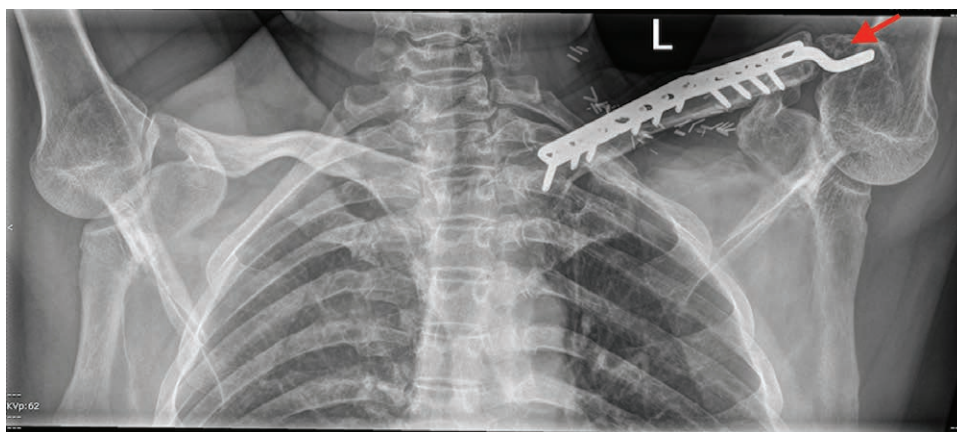
ticular note is the patient’s capacity to fully elevate his left arm above his head without pain or discomfort (Fig. 3). The shoulders showed equal height and positioning. The patient denied any discomfort over his left shoulder despite loss of the deltoid muscle.

### DISCUSSION

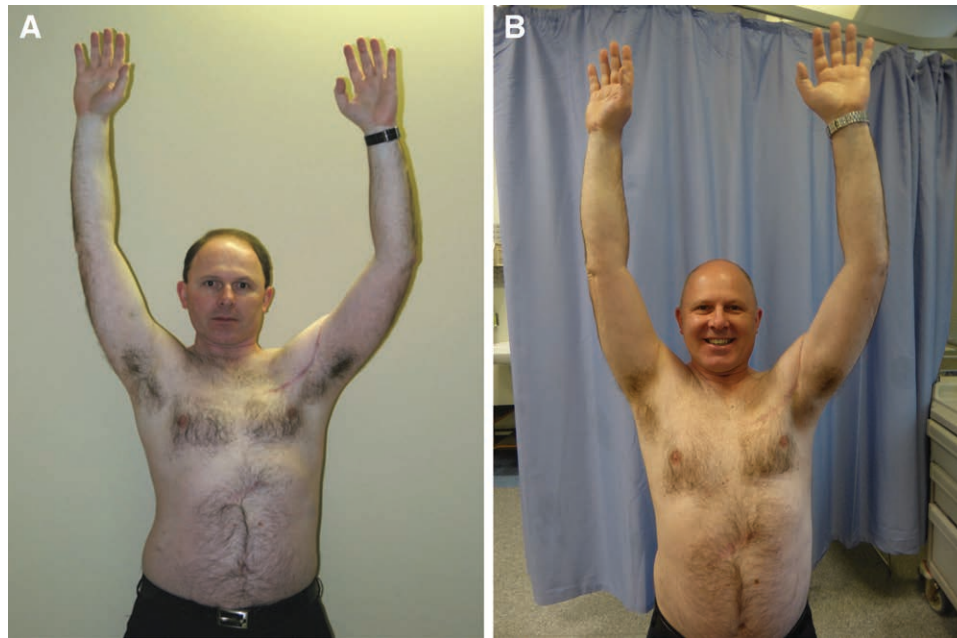Clinical situations that require clavicle reconstruction are rare. Therefore, the current literature on clavicle re-

constructions consists of only a small set of case reports using different repair techniques without consensus on the ideal method for repair.

One common reconstructive approach involving both the clavicle and the AC joint utilizes plate fixation of the transplant (eg, free vascularized fibula flap) and Kirschner wire (K-wire) fixation of AC joint.<sup>3,4,8,9</sup> A common problem with wire fixation reported at short-term follow-up by others and us is limitation in shoulder elevation and the po-



**Fig. 2.** Panoramic shoulder x-ray taken at the 10-year follow-up with both shoulders fully abducted. Arrow points to the acromion.



**Fig. 3.** Postoperative result at follow-up: (A) shoulders in maximum elevation at 12 months (reproduced with permission from Taylor et al. Free vascularized fibula flap reconstruction of the clavicle combined with biceps tendon repair of the conoid ligament and customized plate stabilization of the acromioclavicular joint. *Plast Reconstr Surg.* 2009;123:113e–115e) and (B) 10-year follow-up.

tential for AC-joint subluxation.<sup>4,8,9</sup> Instead of stabilizing the AC joint with a K-wire, we have shown here that long-term fixation of the allograft with a modified Richardson hook plate provides full range of shoulder motion without risk of subluxation of the AC joint, thereby providing better functional outcome for the patient.

The fixation plate has remained in situ for the last decade in our patient. By contrast, others have removed bone plates after union of the clavicle and allograft albeit with incidence of stress fractures after removal.<sup>4,7</sup> Past animal study has not shown negative impacts on bone density from long-term bone plate fixation.<sup>10</sup> Further long-term human studies are required to fully assess the impact of bone plates on bone density.

Regarding the Constant score, our patient scored lower in comparison to the follow-up Constant score (ie, 92) of a pediatric patient after clavicle reconstruction reported previously using vascularized fibula flap/external fixation technique.<sup>6</sup> The lower score seen in our patient is largely due to diminished abduction strength likely explained by the removal of the deltoid muscle rather than pain or limitation in the range of shoulder movement.

Internal fixation using a modified Richardson hook plate may serve as an ideal approach for lateral clavicle reconstruction involving the AC joint in adults. By contrast, in the pediatric population, one must take into consideration the growth and remodeling potential of bones. An alternative approach using external fixation of the free vascularized fibula flap may be more suitable for pediatric patients.<sup>6</sup>

### CONCLUSIONS

Several lessons can be drawn from this case report: (1) Lateral clavicle and AC-joint reconstruction using a free

vascularized fibula flap with internal fixation using a modified Richardson hook plate is a reliable technique for long-term repair of the lateral clavicle where previous attempts using other techniques have resulted in shoulder instability and (2) the involvement of mechanical engineering in the modification of the plate highlights the importance of a multidisciplinary collaboration in finding the best solution for individual patients.

**Louie Ye, MD, PhD**

Department of Plastic and Reconstructive Surgery  
Royal Melbourne Hospital  
Melbourne, Victoria  
Australia  
E-mail: Louie.ye@mh.org.au

### PATIENT CONSENT

*The patient provided written consent for the use of his image.*

### ACKNOWLEDGMENTS

*We like to thank the patient for participating in this clinical follow-up and Prue Dodwell and Van Tran from the Royal Melbourne Hospital for their support.*

### REFERENCES

1. Taylor GI, Miller GD, Ham FJ. The free vascularized bone graft. A clinical extension of microvascular techniques. *Plast Reconstr Surg.* 1975;55:533–544.
2. Lenoir H, Williams T, Kerfant N, et al. Free vascularized fibular graft as a salvage procedure for large clavicular defect: a two cases report. *Orthop Traumatol Surg Res.* 2013;99:859–863.
3. Abarca J, Valle P, Valenti P. Clavicular reconstruction with free fibula flap: a report of four cases and review of the literature. *Injury* 2013;44:283–287.

4. Kalbermatten DF, Haug M, Schaefer DJ, et al. Computer aided designed neo-clavicle out of osteotomized free fibula: case report. *Br J Plast Surg*. 2004;57:668–672.
5. Erdmann D, Pu CM, Levin LS. Nonunion of the clavicle: a rare indication for vascularized free fibula transfer. *Plast Reconstr Surg*. 2004;114:1859–1863.
6. Heidt C, Ziebarth K, Erni D, et al. Four years follow-up after clavicle reconstruction in a child: a case report. *J Plast Reconstr Aesthet Surg*. 2014;67:1735–1739.
7. Momberger NG, Smith J, Coleman DA. Vascularized fibular grafts for salvage reconstruction of clavicle nonunion. *J Shoulder Elbow Surg*. 2000;9:389–394.
8. Taylor GI, Seneviratne S, Jones I, et al. Free vascularized fibula flap reconstruction of the clavicle combined with biceps tendon repair of the conoid ligament and customized plate stabilization of the acromioclavicular joint. *Plast Reconstr Surg*. 2009;123:113e–115e.
9. Rodriguez Martin J, Pretell Mazzini J, Viña Fernandez R, et al. Ewing sarcoma of clavicle in children: report of 5 cases. *J Pediatr Hematol Oncol*. 2009;31:820–824.
10. Glennon JC, Flanders JA, Beck KA, et al. The effect of long-term bone plate application for fixation of radial fractures in dogs. *Vet Surg*. 1994;23:40–47.