

# Deep Inferior Epigastric Artery Perforator Flap Breast Reconstruction in a Patient with a History of Toxic Epidermal Necrosis

Mikhail Y. Sinelnikov, MD  
Olesya I. Starceva, MD, PhD  
Dmitriy V. Melnikov, MD, PhD  
Semen I. Ivanov, MD  
Dmitriy A. Makarenko, MD

**Summary:** Breast reconstruction is a procedure that is in increased demand due to high incidence of breast cancer. To provide high-quality esthetic and functional results, each patient should be properly managed. Patients with comorbid conditions have become more common and account for higher difficulty in perioperative patient management. Despite the ongoing diversification of comorbidities in patients undergoing breast reconstruction, it is the patient's right to receive this final stage in rehabilitation after a mastectomy. We present a clinical vignette of a patient with a severe comorbid hypersensitivity disorder undergoing breast reconstruction with the deep inferior epigastric artery perforator flap. Despite early postoperative complications, our brigade managed to maintain flap viability without the use of surgical or pharmacological assistance in a patient with a history of toxic epidermal necrosis syndrome. (*Plast Reconstr Surg Glob Open* 2019;7:e2190; doi: 10.1097/GOX.0000000000002190; Published online 3 May 2019.)

Modern reconstructive surgery shows a tendency of minimal tissue traumatization, improvement of esthetic results, and complete functional and psychological patient rehabilitation.<sup>1</sup> Breast reconstruction using the deep inferior epigastric artery perforator flap (DIEP flap) has shown to improve psychological well-being of patients who have undergone a mastectomy. Patient management is one of the most important aspects of surgical treatment. Preoperative care, intraoperative therapy, and postoperative assistance are of utmost importance in patient treatment and rehabilitation.<sup>2</sup> Clinical recommendations have been developed on effective pharmacological management of patients undergoing microsurgical reconstruction with a DIEP flap.

Evaluation of modifiable and nonmodifiable risk factors during breast reconstruction with the DIEP flap is necessary for proper patient preparation and management. Correction of modifiable risk factors is mandatory to decrease complication rates. Nonmodifiable risk factors are a significant burden, but do not always represent complete contraindications for surgical intervention.<sup>3-5</sup> Nonmodifi-

able risk factors are often comorbid conditions, such as oncology, diabetes, psychoaffective disorders, and other numerous syndromes and symptoms. Pathological immune response to certain drugs and medications is a modifiable risk factor, but significantly increases the difficulty of proper and complete patient rehabilitation after surgical intervention. Hypersensitivity to anesthesia components requires individual preparation of anesthesiologic care.

One of the most dangerous allergic dermatosis conditions is toxic epidermal necrolysis (TEN) or Lyell's syndrome. In cases of TEN, patients react to minimal amounts of allergens, resulting in severe intoxication, formation of large flat blisters on the skin and mucous membranes filled with serous and hemorrhagic fluid, which quickly burst and form massive erosions. Mortality rates in cases of TEN are up to 70%.<sup>6-8</sup> Our clinical vignette features a patient undergoing breast reconstruction with the DIEP flap with a history of polyallergenic Lyell's syndrome.

## CASE REPORT

A 31-year-old woman was referred to our hospital with a history of breast cancer (Fig. 1). She was diagnosed in 2016 and underwent full treatment, including a mastectomy in July 2016. Once admitted she disclosed of her severe allergic history in the form of TEN (manifestation at the age of 12 and 28 years), providing documentation and examination results, which showed a wide spectrum of drugs that could induce a life-threatening reaction in the form of toxic epidermal necrosis. The list of contraindicated drugs con-

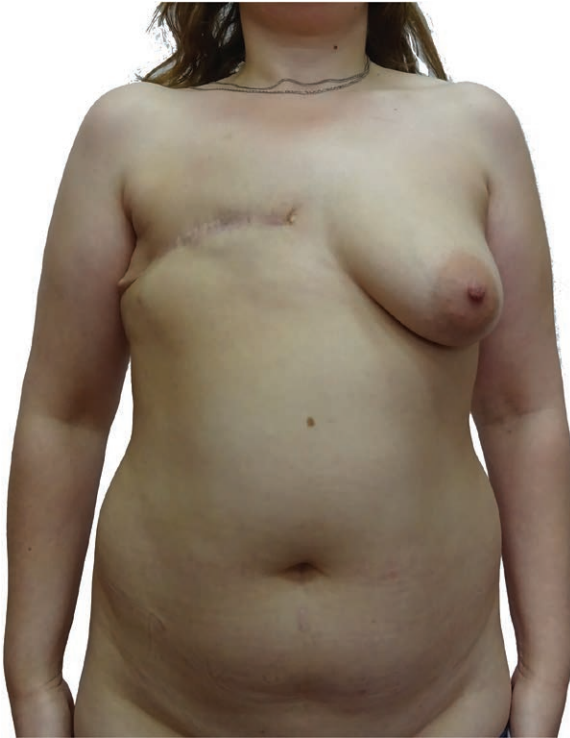From the Department of Oncology, Radiotherapy, and Plastic Surgery, Sechenov University, Moscow, Russia.

Received for publication October 1, 2018; accepted January 25, 2019.

Copyright © 2019 The Authors. Published by Wolters Kluwer Health, Inc. on behalf of The American Society of Plastic Surgeons. This is an open-access article distributed under the terms of the Creative Commons Attribution-Non Commercial-No Derivatives License 4.0 (CCBY-NC-ND), where it is permissible to download and share the work provided it is properly cited. The work cannot be changed in any way or used commercially without permission from the journal.

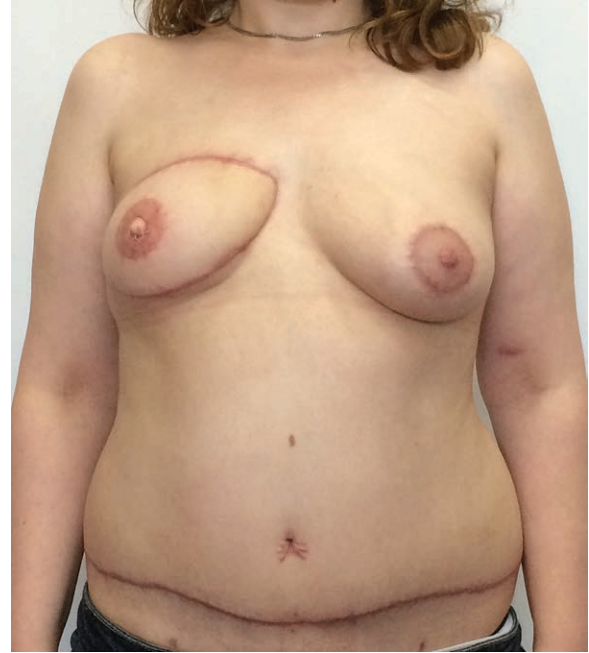
DOI: 10.1097/GOX.0000000000002190

**Disclosure:** The authors have no financial interest to declare in relation to the content of this article.



**Fig. 1.** Patient on admission.

sisted of >50 substances and classes of drugs, many of which are regularly recommended for use when performing breast reconstruction with a DIEP flap, including commonly used antibiotics (tetracyclines, penicillins, cephalosporins, sulfonamides, aminoglycosides), anesthetics (novocaine), anti-inflammatory agents, pain management drugs (acetaminophen), bronchodilators (aminophylline), antihistamines, diuretics, antimycotics, pentoxifylline, hypotensive agents (enalapril), and anticoagulant drugs (enoxaparin sodium). After consultation with a clinical pharmacologist, allergologist, and anesthesiologist, an individual treatment plan was devised. Previous anesthesiologic protocol was taken into account. Before administration of anesthesia, the patient underwent allergenic tests for compatibility to anesthesia components. The surgery was successfully performed with no intraoperative complications, without the use of any additional medication apart from the general anesthesia. A medial perforator DIEP flap was transferred and connected to the right internal mammary artery and vein. Superficial venous superdrainage was performed with outflow through an anterior chest wall perforator vessel. A total of 3 anastomoses (1 arterial, 2 venous) were performed and was deemed appropriate for a flap weighing 387.45 g. In the postoperative period, the patient developed partial flap congestion (<25%). Due to a strict limitation on drug use, and advisement from clinical pharmacologists to refrain from drug administration, we managed to restore proper flap perfusion with the application of leeches and dilution of patient blood with saline. 0.9% NaCl of 750 ml was administered intravenously daily for 5 days. Oral hydration was sufficient. Leeching was performed for 3 consecutive days to maintain low blood viscosity. As a result of



**Fig. 2.** Six months after surgery.

a drug-free postoperative period, the flap was stabilized and the patient did not develop any allergic reactions. Six months after surgery, the functional and esthetic results are satisfactory (Fig. 2).

## DISCUSSION

The importance of this case is defined by a strict algorithmic approach to patient management and pharmacological guidelines for a patient with a diverse hypersensitivity disorder. TEN is a life-threatening pathological reaction. Immunological mechanisms of Lyell's syndrome pathology include activation of CD8+ T cells, which induce a cascade of cytokines (perforin, granzyme B, granulysin, tumor necrosis factor alpha, Fas ligand) inducing keratocytolysis with epidermal detachment. Allergenic factors include pharmaceutical drugs and products of their metabolism, which interact with immune CD8+ cells, causing a cascade of hyperactive reactions, which lead to severe clinical manifestations of this pathology.<sup>9</sup>

A successful reconstructive treatment was possible in a patient with a history of Lyell's syndrome due to following of a strict individual protocol and proper patient preparation. It should be noted that flap viability does not depend solely on pharmacological support but also on the success of primary vascular anastomosis. Partial flap congestion can be managed without the implication of drugs with leeching and saline blood dilution.

## CONCLUSIONS

Breast reconstruction is the final stage of rehabilitation after combined breast cancer treatment. A series of deforming surgeries performed with no esthetic motivation in the course of exhausting treatment of breast cancer leaves patients with an anterior chest wall defect, which often results

in physical and emotional distress. The introduction and perfection of reconstructive techniques provides patients with an opportunity to receive complete postmastectomy rehabilitation. Clinical guidelines and surgical protocol account for many different scenarios of pharmacological regimen for patients undergoing breast reconstruction. These guidelines yield a way for a complication-free perioperative period. We offer a case of a 31-year-old woman with a postmastectomy anterior chest wall deformity with a request for reconstructive treatment. Due to the history of polyallergenic toxic epidermal necrosis, the use of drugs was strictly limited. The patient received breast reconstruction surgery with a DIEP flap under “minimal drug use” protocol, which was prepared before surgery. Despite postoperative perfusion complications, we managed to save the flap without surgical revision or pharmacological assistance. Six months after surgery, the patient is living a better life with a new esthetically and functionally sufficient breast. Patients with severe comorbid conditions should not be dismissed from surgery, but should be offered individual preparation and management.

**Mikhail Y. Sinelnikov, MD**

Udaltzova Ulitza, 4, 370

Moscow 119415, Russia

E-mail: mikhail.y.sinelnikov@gmail.com

## REFERENCES

1. Tønseth KA, Hokland BM, Tindholdt TT, et al. Quality of life, patient satisfaction and cosmetic outcome after breast reconstruction using DIEP flap or expandable breast implant. *J Plast Reconstr Aesthet Surg.* 2008;61:1188–1194.
2. Silver JK. Rehabilitation in women with breast cancer. *Phys Med Rehabil Clin N Am.* 2007;18:521–537.
3. Vyas RM, Dickinson BP, Fastekjian JH, et al. Risk factors for abdominal donor-site morbidity in free flap breast reconstruction. *Plast Reconstr Surg.* 2008;121:1519–1526.
4. Garvey PB, Salavati S, Feng L, et al. Perfusion-related complications are similar for DIEP and muscle-sparing free TRAM flaps harvested on medial or lateral deep inferior epigastric artery branch perforators for breast reconstruction. *Plast Reconstr Surg.* 2011;128:581e–589e.
5. Herold C, Gohritz A, Meyer-Marcotty M, et al. Is there an association between comorbidities and the outcome of microvascular free tissue transfer? *J Reconstr Microsurg.* 2011;27:127–132.
6. Pereira FA, Mudgil AV, Rosmarin DM. Toxic epidermal necrolysis. *J Am Acad Dermatol.* 2007;56:181–200.
7. Becker DS. Toxic epidermal necrolysis. *Lancet.* 1998;351:1417–1420.
8. Dolan PA, Flowers FP, Araujo OE, et al. Toxic epidermal necrolysis. *J Emerg Med.* 1989;7:65–69.
9. Bastuji-Garin S, Rzany B, Stern RS, et al. Clinical classification of cases of toxic epidermal necrolysis, Stevens-Johnson syndrome, and erythema multiforme. *Arch Dermatol.* 1993;129:92–96.