

Sequential Double-guidewire Technique and Transpancreatic Precut Sphincterotomy for Difficult Biliary Cannulation

Chang W. Kim, Jae H. Chang, Tae H. Kim, Sok W. Han

Department of Internal Medicine, College of Medicine, The Catholic University of Korea, Seoul, Republic of Korea

Address for correspondence:

Dr. Jae Hyuck Chang,
Division of Gastroenterology,
Department of Internal Medicine, Bucheon St. Mary's Hospital, College of Medicine, The Catholic University of Korea, 222 Banpo-daero, Seocho-gu, Seoul 137-701, Republic of Korea.
E-mail: wwjjjaang@catholic.ac.kr

ABSTRACT

Background/Aims: The double-guidewire technique (DGT) and transpancreatic precut sphincterotomy (TPS) are introduced as alternative biliary cannulation techniques for difficult biliary cannulation. This study aimed to evaluate the sequential use of DGT and TPS compared with a needle-knife precut papillotomy (NK). **Patients and Methods:** Six hundred and thirty-five consecutive patients with naïve papilla and who underwent endoscopic retrograde cholangiopancreatography (ERCP) for biliary cannulation from March 2010 to April 2014 in a single institute were analyzed. When standard techniques were unsuccessful, DGT or NK was performed. TPS was sequentially performed if DGT failed. **Results:** DGT and NK were attempted in 65 and 58 patients, respectively. A sequential DGT-TPS was performed in 38 patients after a failed DGT. Biliary cannulations were successful in 42%, 74%, and 66% of the DGT, sequential DGT-TPS, and NK patients, respectively ($P = 0.002$). The cannulation rate was higher in the DGT ± TPS patients (85%) than in the NK patients ($P = 0.014$). Post-ERCP pancreatitis (PEP) developed in 26% of the successful DGT patients, 37% of the sequential DGT-TPS patients, and 10% of the NK patients ($P = 0.008$). Of the sequential DGT-TPS patients, the incidence of PEP was significantly reduced in patients with a pancreatic duct (PD) stent compared with patients without a PD stent (24% vs. 62%, $P = 0.023$). **Conclusions:** Sequential DGT-TPS is a useful alternative method compared with NK for patients in whom biliary cannulation is difficult. In the sequential DGT-TPS patients, the incidence of PEP was significantly reduced with the use of a PD stent.

Key Words: Bile duct, cannulation, endoscopic sphincterotomy, endoscopic retrograde cholangiopancreatography, guidewire

Received: 23.09.2014, Accepted: 02.11.2014

How to cite this article: Kim CW, Chang JH, Kim TH, Han SW. Sequential double-guidewire technique and transpancreatic precut sphincterotomy for difficult biliary cannulation. Saudi J Gastroenterol 2015;21:18-24.

As endoscopic retrograde cholangiopancreatography (ERCP) becomes almost exclusively therapeutic, the need to reliably achieve biliary access is an important prerequisite.^[1] Accordingly, appropriate cannulation techniques during ERCP are essential, and these techniques may affect the development of post-ERCP pancreatitis (PEP). Established standard cannulation techniques are based on the initial contrast opacification of the desired duct using a standard ERCP cannula or sphincterotome [Figure 1].^[2] With the advent of guidewires, guidewire-based techniques have been reported to confer some technical advantage for

primary cannulation, which may reduce the incidence of PEP.^[3-5] However, difficulties in selective cannulation of the bile duct with standard techniques including guidewire techniques are reported in approximately 3%–38% of ERCP procedures.^[4-7] In an attempt to overcome difficult biliary cannulation, several techniques have been developed. Among these, a needle-knife precut papillotomy (NK) is the most commonly used approach to open the biliary entrance, and this technique is generally successful when performed by an expert endoscopist.^[8,9] Although NK is a useful technique, it has a higher rate of complications, which occur in 2%–34% of patients.^[6,10-12] Furthermore, NK is somewhat technically demanding; therefore, it is generally reserved for experienced endoscopists.

When the pancreatic duct (PD) is repeatedly instrumented inadvertently and without selective biliary access, two alternative cannulation strategies that use a guidewire in the PD can be applied instead of NK: The double-guidewire technique (DGT) and transpancreatic

Access this article online	
Quick Response Code:	Website: www.saudijgastro.com
	PubMed ID: 25672234
	DOI: 10.4103/1319-3767.151212

precut sphincterotomy (TPS).^[13,14] DGT is a biliary cannulation technique that uses a second guidewire in the sphincterotome, whereas the first guidewire remains in the PD. TPS incises the septum between the bile duct and the PD, and then, a sphincterotome proceeds into the bile duct via the incised septum. DGT and TPS have been reported to show high cannulation rates and reasonable complication rates.^[15-21] Additionally, DGT and TPS do not require a large amount of skill;^[13] therefore these techniques do not require a highly experienced endoscopist. Although these techniques are useful for difficult cannulations, whether to use DGT and TPS individually or sequentially has not been well established. Based on the invasiveness of TPS and to improve the success rate of this technique, it is suggested that DGT be performed first, followed by TPS. However, the sequential performance of DGT-TPS has not been evaluated. Thus, we investigated the usefulness and potential complications of sequential DGT-TPS compared with NK.

PATIENTS AND METHODS

Patients

We consecutively enrolled 635 patients with naïve papilla undergoing ERCP for biliary cannulation between March 2010 and April 2014. The patients who underwent Billroth II surgery (23) were excluded from the present study. Serum hematological and biochemical tests, including liver function tests and amylase/lipase levels, were performed on samples collected before ERCP and at 4, 24, 48, and 72 h after ERCP. No drugs for the prophylactic prevention of PEP were administered. PEP was diagnosed based on newly developed, distinct abdominal pain and a serum amylase greater than three times the upper normal limit 24 h after ERCP. The degree of pancreatitis was classified as mild, moderate, or severe based on a prolonged admission of less than 3 days, 4–10 days, or more than 10 days, respectively.^[22] Post-ERCP bleeding was defined as a decrease in hemoglobin greater than 2 g/dL. Post-ERCP cholangitis was diagnosed when

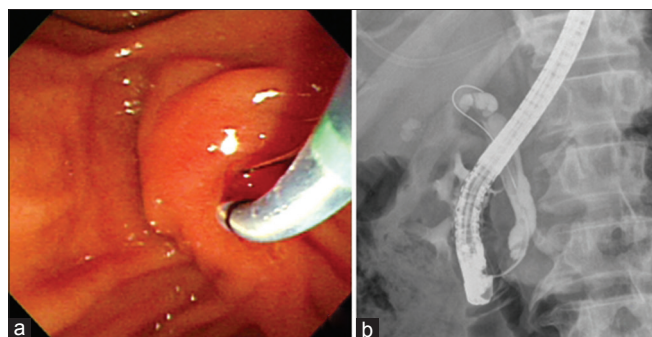


Figure 1: Standard technique for biliary cannulation. (a) A sphincterotome with a guidewire was inserted into the bile duct via the papilla. (b) The common bile duct was opacified on the fluoroscopic image

the patient had a body temperature greater than 38°C for more than 24 h and had abnormal liver function test results. Successful biliary cannulation was defined as a guidewire that proceeded into the bile duct and provided sustained biliary access.

We retrospectively analyzed patient demographics, laboratory results, and procedure-related data that were prospectively recorded in the study cohort. Patient anonymity was preserved, and the Institutional Review Board of our hospital approved this study (HC14RISI0068). This study protocol is in complete compliance with the Declaration of Helsinki, as revised in Seoul in 2008.

Double-guidewire technique, transpancreatic precut sphincterotomy, and needle-knife papillotomy

ERCPs were initially performed with standard techniques that utilized various ERCP catheters, sphincterotomes, or guidewires. After 10 unsuccessful attempts to selectively cannulate the bile duct using ERCP catheters or sphincterotomes with a guidewire, DGT or NK was performed according to guidewire passage through the PD. If a guidewire (0.025 in., Tracer Metro, Cook Endoscopy, Winston-Salem, NC, USA) was placed in the PD, DGT was performed. If a guidewire was not placed in the PD, NK was performed. DGT was initiated by placing a guidewire in the PD through the papilla. Next, biliary cannulation was attempted at the papilla orifice with a sphincterotome (Clever Cut, Olympus Corporation, Tokyo, Japan) preloaded with a second guidewire while the first guidewire remained in the PD [Figure 2]. If DGT failed, TPS was then performed [Figure 3]. The sphincterotome

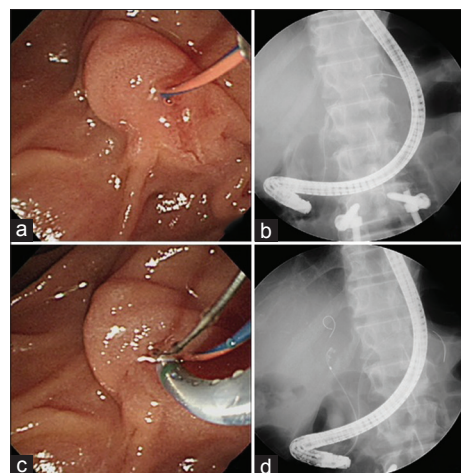


Figure 2: Double-guidewire technique. Endoscopy (a) and fluoroscopy (b) showed that the guidewire had been placed in the pancreatic duct. (c) A sphincterotome with another preloaded guidewire was introduced at the papilla to cannulate the bile duct, while the first guidewire remained in the pancreatic duct. (d) Cannulation into the bile duct was successfully performed

was placed with the pancreatic guidewire, and then, the septum was cut toward an 11 o'clock position using an electro-surgical unit (VIO 300D with endocut I mode, Erbe Elektromedizin, Tübingen, Germany). TPS created an approximately 5 mm cut. Biliary cannulation was re-attempted with a sphincterotome through the TPS site. After 2012, a PD stent was placed in the sequential DGT-TPS patients. We used a PD stent that was 5 Fr/5 cm and straight or single pigtail. The PD stent was removed 1 month after ERCP in the outpatient clinic. Contrast injection into more than 50% of the PD was performed in the DGT or TPS patients when the guidewire did not easily insert into the deep portion of the PD. NK was performed via infundibular fistulotomy or a precut from the papillary orifice with a needle-knife (Triple lumen needle-knife, Olympus Corporation, Tokyo, Japan). In the NK patients, contrast injection into the PD was performed by chance during the procedure to cannulate the bile duct before NK. As a rule, the DGT and NK patients did not receive a PD stent. If biliary cannulation failed after the use of all of these techniques, percutaneous transhepatic biliary drainage (PTBD), surgery, or continued observation of the patients was performed. All procedures were performed by two endoscopists who had performed over 1000 ERCPs. The levels of experience of the two endoscopists were similar.

Statistical analysis

Pearson's Chi-square test or Fisher's exact test was used for categorical data, and Student's *t*-test was used for continuous data to compare the DGT ± TPS patients, which included the successful DGT patients and sequential DGT-TPS patients,

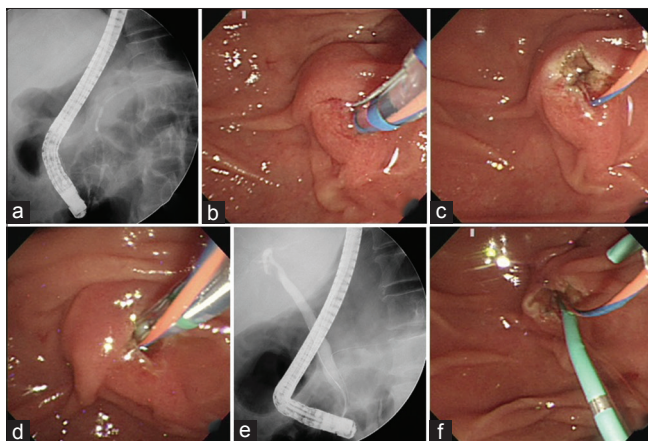


Figure 3: Transpancreatic precut sphincterotomy. (a) Fluoroscopy image showed opacification of the pancreatic duct. (b) The endoscopic transpancreatic precut sphincterotomy was performed with a sphincterotome. (c) A small cut of approximately 5 mm was created with a guidewire in the pancreatic duct. (d) A sphincterotome that was preloaded with another guidewire was introduced at the small cut, while the first guidewire remained in the pancreatic duct. (e) Biliary cannulation was successfully performed. (f) A stent was placed in the pancreatic duct

and the NK patients. These tests were also used to analyze PEP in the sequential DGT-TPS patients. The cannulation rates and complications of the DGT, sequential DGT-TPS, and NK patients were compared using Pearson's Chi-square test. Statistical analyses was performed with SPSS, version 20 (SPSS, Inc., Chicago, IL, USA). *P* < 0.05 were considered significant.

RESULTS

Patients

The overall selective biliary cannulation rate using standard techniques in patients with naïve papilla was 78%. Of 135 patients in whom the standard technique failed, DGT ± TPS or NK was attempted in 65 and 58 patients, respectively [Figure 4]. Twelve patients discontinued ERCP: Five patients who underwent PTBD, five patients who underwent surgery, and two patients who were observed without a further intervention. The characteristics of the DGT ± TPS patients and the NK patients are described in Table 1. The major indications of ERCPs included 72 cases (59%) of suspicious bile duct stones and 39 cases (32%) of malignant bile duct obstructions. The DGT ± TPS patients and the NK patients did not differ in age, gender, ERCP indications, periampullary diverticulum, or procedure time. However, contrast injection via the PD and biliary sphincterotomy were performed more frequently in the DGT ± TPS patients than in the NK patients (*P* < 0.001 and 0.002, respectively). A PD stent was placed significantly more frequently in the DGT ± TPS patients (27 cases, 42%) than in the NK patients (1 case, 2%, *P* < 0.001). In the DGT ± TPS patients, 25 (66%) of the sequential DGT-TPS patients received a PD stent, and 2 (7%) of the successful DGT patients received a PD stent.

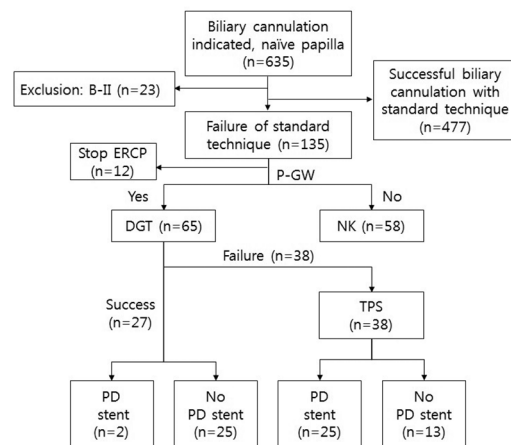


Figure 4: Algorithm of procedures for difficult biliary cannulation. P-GW, pancreatic guidewire; DGT, double-guidewire technique; NK, needle-knife precut papillotomy; TPS, transpancreatic precut sphincterotomy; PD, pancreatic duct

Cannulation rates and complications

DGT was successfully performed to achieve biliary cannulation in 27 (42%) patients of 65 patients. When DGT failed to access the bile duct, TPS was subsequently performed in 38 patients (sequential DGT-TPS patients). A successful biliary cannulation was performed in 42%, 74%, and 66% of the DGT, sequential DGT-TPS, and NK patients, respectively ($P = 0.002$, Table 2). The cannulation rate was higher for the DGT \pm TPS patients (85%) than for the NK patients ($P = 0.014$). In 12 sequential DGT-TPS patients, a small additional needle-knife precut papillotomy was performed after the pancreatic sphincterotomy and the PD stent placement. Among these, successful biliary cannulations were achieved in six patients. Overall, a failed cannulation occurred in 10 sequential DGT-TPS patients due to a large peripapillary diverticulum in five of the patients, unsuitable papilla position for cannulation with a sphincterotome or additional NK in three of the patients, and a suspicious spreading of the contrast in the pancreas head portion beyond the PD in two of the patients.

Twenty-seven cases of PEP occurred in the DGT \pm TPS and NK patients during this study, including 25 mild cases and two severe cases of pancreatitis. One case of severe pancreatitis occurred in the DGT patients who had both perforation and severe PEP, although DGT was successful. The perforation occurred around the papilla during the retraction of a retrieval balloon, not during DGT. The other case of severe pancreatitis was found in sequential DGT-TPS patients who failed biliary cannulation without a PD stent. The pancreatitis progressed to multiorgan failure and death. PEP developed more frequently in the sequential DGT-TPS patients (37%) than in the NK patients (10%, $P = 0.002$). However, of the sequential DGT-TPS patients, PEP developed less frequently in those with a PD stent than in those without a PD stent ($P = 0.023$, Table 3). The rate of PEP was not significantly different between the sequential DGT-TPS patients with a PD stent and the NK patients. There were no specific complications concerning the PD stent, such as pancreatic ductitis or chronic pancreatitis.

Several other complications were observed in the patients after TPS. Acute cholangitis and PEP developed in one patient with a Klatskin tumor type I. In this patient, biliary cannulation with TPS failed, and PTBD was subsequently performed. The acute cholangitis subsided after three days of medical treatment. Migration of PD stents and post-ERCP bleeding occurred in two patients and one patient, respectively. Two patients had a PD stent that migrated from the PD, and one patient had delayed bleeding from the papilla, which caused obstruction of the PD stent. In these three patients, the serum amylase level further increased two days after ERCP compared with one day after ERCP. The

PD stents were removed two days after ERCP, after which the amylase levels normalized.

DISCUSSION

When the PD is instrumented inadvertently in cases of difficult biliary cannulation, two alternative cannulation techniques are introduced in place of NK: DGT and TPS. These techniques

Table 1: Patient and procedure characteristics

	DGT \pm TPS (n=65)	NK (n=58)	P
Age (year), mean \pm SD	65.4 \pm 12.5	64.2 \pm 13.1	0.578
Male: female	33:32	23:35	0.217
ERCP indication			
Suspicious BD stone (%)	36 (55)	36 (62)	0.365
Malignant BD obstruction (%)	24 (37)	15 (26)	
Miscellaneous ^a (%)	5 (8)	7 (12)	
Periapillary diverticulum (%)	12 (18)	10 (17)	0.860
Procedure time (min), mean \pm SD	32.2 \pm 11.2	31.0 \pm 13.2	0.565
ERCP procedures (%)			
Contrast injection in PD ^b	52 (80)	20 (34)	<0.001
EST	52 (80)	31 (53)	0.002
Stone extraction	19 (29)	20 (34)	0.532
EPBD	5 (8)	9 (16)	0.173
ENBD	25 (38)	19 (33)	0.510
BD stent	12 (18)	6 (10)	0.204
PD stent	27 (42)	1 (2)	<0.001

^aPostoperative bile leak and benign biliary stricture. ^bGreater than 50% of the pancreatic duct. DGT: Double-guidewire technique, TPS: Transpancreatic precut sphincterotomy, NK: Needle-knife precut papillotomy, SD: Standard deviation, BD: Bile duct, PD: Pancreatic duct, EST: Endoscopic sphincterotomy, EPBD: Endoscopic papillary balloon dilation, ENBD: Endoscopic nasobiliary drainage

Table 2: Cannulation rates and complications in DGT, TPS, and NK patients

	Successful DGT (n=27)	Sequential DGT-TPS (n=38)	NK (n=58)	P
Successful cannulation, n (%) ^a	27 (42) ^b	28 (74)	38 (66)	0.002
n (%) ^a		55 (85) ^c	38 (66)	0.014
Contrast injection in PD	19 (70)	33 (87)	20 (34)	<0.001
PD stent	2 (7)	25 (66)	1 (2)	<0.001
Complications				
Pancreatitis	7 (26)	14 (37) ^d	6 (10) ^d	0.008
Mild	6 (22)	13 (34)	6 (10)	
Moderate to severe	1 (4)	1 (3)	0 (0)	
Delayed bleeding	0	1	0	0.324
Perforation	1	0	0	0.167
Cholangitis	0	1	0	0.324
Procedure-related death	0	1	0	0.324

^aPrimary cannulation rate. ^bAmong 65 patients who underwent DGT. ^cDGT \pm TPS. ^d $P=0.002$. DGT: Double-guidewire technique, TPS: Transpancreatic precut sphincterotomy, NK: Needle-knife precut papillotomy, PD: Pancreatic duct

Table 3: Post-ERCP pancreatitis in sequential DGT-TPS patients with and without a PD stent

	Severity		Overall (%)	P	Related complication
	Mild	Moderate/severe			
With PD stent	6	0	6/25 (24)	0.023	Delayed bleeding (n=1)
Without PD stent	7	1	8/13 (62)		Death (n=1)

DGT: Double-guidewire technique, TPS: Transpancreatic precut sphincterotomy, PD: Pancreatic duct, ERCP: Endoscopic retrograde cholangiopancreatography

are not highly demanding procedures and can be performed more conveniently. In DGT, a hydrophilic wire is placed into the PD in the body or tail if possible in an atraumatic fashion.^[2] Having the wire in such a position will “straighten out” the intramural segment of the bile duct,^[2] which facilitates biliary cannulation and prevents repeated pancreatic cannulation.^[14,23] The success rate of DGT is variable and has been reported at 47% and 93% in two prospective randomized studies.^[15,16] According to previous studies, DGT alone may not provide high cannulation rates. TPS is another precut technique that was first described in 1995 by Goff *et al.*^[13] TPS can facilitate cannulation of the biliary orifice because the cut either opens the bile duct or runs alongside the duct, thus exposing the orifice.^[21,24] In two prospective studies, a successful biliary cannulation was immediately achieved in 60% and 85% of the patients.^[17,18] These success rates were comparable to our results that showed that 74% of the sequential DGT-TPS patients and 85% of the DGT ± TPS patients underwent a successful cannulation. The attempt rates of TPS during biliary cannulation have differed considerably in previous studies. While Goff *et al.* reported these rates to be as high as 36%,^[19] others reported rates of 1.4%–7%.^[18,20,21] Our attempt rate of TPS for biliary cannulation was 6%.

The usefulness of performing DGT and TPS individually or sequentially has not been determined. Considering that DGT is easier to perform and is less invasive than TPS, we suggest that DGT should be utilized first, with subsequent TPS if DGT fails. The sequential DGT-TPS technique is easy for endoscopists to perform and may raise the rates of biliary cannulation. However, the usefulness of sequential DGT-TPS has not been evaluated. In the present study, DGT alone did not achieve a high biliary cannulation rate (42%), which was similar to previously reported findings (47%).^[16] However, when TPS was performed after DGT in patients with failed DGTs, the cannulation rate increased to 85%, which was significantly higher than that of NK (66%) in our study.

Although sequential DGT-TPS can be performed conveniently and successfully, the complication rates of the procedure are an important point of consideration. In DGT, the complication rates were reported as 0% and 17% in two prospective randomized studies.^[15,16] In

TPS, the reported complication rates vary between 2% and 13%.^[17,18,20,25] The complication rates for TPS were reported to be significantly higher (9.9%) than those of standard biliary sphincterotomy (0.8%) in one study. Other studies have shown no difference in the occurrence of PEP after TPS compared with conventional biliary sphincterotomy.^[17,18] Concerning PEP, Wang *et al.* reported similar pancreatitis rates of 11.4% and 11.8% in TPS and NK patients, respectively,^[26] and Catalano *et al.* reported a marginally lower pancreatitis rate of 3.5% in TPS patients compared with 11.8% in NK patients.^[20] In previous reports, the rates of success and complication had wide ranges, which may be attributable to differences in indications, anatomic factors, patient characteristics, precut timing, and endoscopist experience.^[26] In our study, the PEP rate in the sequential DGT-TPS patients was higher than that of the NK patients, which may be associated with a pancreatic deep wire pass and cannulation time >10 min compared with NK patients.^[27–29] Moreover, in DGT or TPS patients, an increase in mechanical trauma to the papilla orifice and an increase in contrast injections into the PD can frequently occur during the placement of a pancreatic guidewire or sphincterotomy. In contrast, we performed infundibular fistulotomy in 84% of the NK patients rather than using a precut from the papillary orifice to reduce trauma to the papilla, and we performed less opacification of the PD, which was related to the occurrence of PEP.^[5,30] These factors might influence the differences in PEP rates between the sequential DGT-TPS and NK patients that were observed in our study. It is not clear if the complications were related to DGT or TPS in the sequential DGT-TPS patients. We evaluated sequential DGT-TPS rather than each procedure alone. Thus, it cannot be concluded from our study that the complications were related to DGT or TPS in sequential DGT-TPS patients. Further studies on separate DGT and TPS are needed.

Use of a PD stent for the prevention of PEP has been assessed in many previous studies. A meta-analysis assessing the efficacy of prophylactic pancreatic stenting for PEP with eight randomized controlled trials and 10 nonrandomized trials showed a lower pancreatitis rate of 4.9% compared with 19.7% in favor of the placement of a PD stent.^[1,31] However, the PEP rate related to PD stents in TPS patients has not been evaluated. Our study showed that the rate of PEP significantly decreased in the sequential DGT-TPS patients with a PD stent and that this PEP rate did not differ from that of the NK patients. This result demonstrated that a PD stent has a protective role against PEP in TPS patients.

In the present study, one of the sequential DGT and TPS patients who underwent a failed biliary cannulation and did not have a PD stent placed died due to severe pancreatitis. Similar to our study, a previous study

reported that two patients without a PD stent died from PEP after TPS.^[21] Therefore, endoscopists should keep the possibility of severe PEP during DGT-TPS in mind and recognize that the placement of a PD stent may be helpful for preventing severe PEP. During TPS, a modified technique, consisting of an early pancreatic stent placement with wire cannulation of the bile duct above the stent or a needle-knife sphincterotomy over the stent, can also be performed.^[2] We did not perform a wire cannulation of the bile duct above the stent; however, we performed a needle-knife sphincterotomy over the stent in 12 patients. This is a known modified TPS technique that can be used to gain access to the bile duct.

There are some limitations to this study. First, this study has a retrospective design and compared two techniques in a nonrandomized nature. Therefore, it is not appropriate to directly compare the sequential DTG-TPS and NK techniques in this study. However, the groups of sequential DGT-TPS and NK were all with difficult biliary cannulation (after 10 unsuccessful attempts), and a randomized distribution of patients was not possible because the groups were determined based on the guidewire passage into the PD. Second, the placement of PD stents was not randomly determined and was decided by a set time. Thus, other factors could have influenced the efficacy of the prevention of PEP by the PD stents. Although the skill of the endoscopists could have stabilized during the study period, there were no differences in the procedures and no meaningful improvement in skill. Third, our cannulation data consisted of only the primary success rate. If ERCP was repeatedly performed, the success rate may have increased. We generally performed PTBD, surgery, or observed the patients rather than repeat ERCP in patients who had a failed cannulation.

Overall, the present study demonstrated that sequential DGT-TPS is a useful alternative technique compared with NK for patients who have undergone failed standard techniques, when a guidewire inadvertently proceeds into the PD. Although the rate of PEP was higher in the DGT-TPS patients than in the NK patients, the incidence of PEP was significantly reduced with the placement of a PD stent. We are expecting randomized controlled studies using a larger population in the near future before making recommendation for routine clinical practice.

REFERENCES

1. Chan CH, Brennan FN, Zimmerman MJ, Ormonde DG, Raftopoulos SC, Yusoff IF. Wire assisted transpancreatic septotomy, needle knife precut or both for difficult biliary access. *J Gastroenterol Hepatol* 2012;27:1293-7.
2. Bourke MJ, Costamagna G, Freeman ML. Biliary cannulation during endoscopic retrograde cholangiopancreatography: Core technique and recent innovations. *Endoscopy* 2009;41:612-7.

3. Lella F, Bagnolo F, Colombo E, Bonassi U. A simple way of avoiding post-ERCP pancreatitis. *Gastrointest Endosc* 2004;59:830-4.
4. Artifon EL, Sakai P, Cunha JE, Halwan B, Ishioka S, Kumar A. Guidewire cannulation reduces risk of post-ERCP pancreatitis and facilitates bile duct cannulation. *Am J Gastroenterol* 2007;102:2147-53.
5. Bailey AA, Bourke MJ, Williams SJ, Walsh PR, Murray MA, Lee EY, *et al.* A prospective randomized trial of cannulation technique in ERCP: Effects on technical success and post-ERCP pancreatitis. *Endoscopy* 2008;40:296-301.
6. Freeman ML, Guda NM. ERCP cannulation: A review of reported techniques. *Gastrointest Endosc* 2005;61:112-25.
7. Schwacha H, Allgaier HP, Deibert P, Olschewski M, Allgaier U, Blum HE. A sphincterotomy-based technique for selective transpapillary common bile duct cannulation. *Gastrointest Endosc* 2000;52:387-91.
8. Tweedle DE, Martin DF. Needle knife papillotomy for endoscopic sphincterotomy and cholangiography. *Gastrointest Endosc* 1991;37:518-21.
9. Bailey AA, Bourke MJ, Kaffes AJ, Byth K, Lee EY, Williams SJ. Needle-knife sphincterotomy: Factors predicting its use and the relationship with post-ERCP pancreatitis (with video). *Gastrointest Endosc* 2010;71:266-71.
10. Rabenstein T, Ruppert T, Schneider HT, Hahn EG, Ell C. Benefits and risks of needle-knife papillotomy. *Gastrointest Endosc* 1997;46:207-11.
11. Dowsett JF, Polydorou AA, Vaira D, D'Anna LM, Ashraf M, Croker J, *et al.* Needle knife papillotomy: How safe and how effective? *Gut* 1990;31:905-8.
12. Gholson CF, Favrot D. Needle knife papillotomy in a university referral practice. Safety and efficacy of a modified technique. *J Clin Gastroenterol* 1996;23:177-80.
13. Goff JS. Common bile duct pre-cut sphincterotomy: Transpancreatic sphincter approach. *Gastrointest Endosc* 1995;41:502-5.
14. Gotoh Y, Tamada K, Tomiyama T, Wada S, Ohashi A, Satoh Y, *et al.* A new method for deep cannulation of the bile duct by straightening the pancreatic duct. *Gastrointest Endosc* 2001;53:820-2.
15. Maeda S, Hayashi H, Hosokawa O, Dohden K, Hattori M, Morita M, *et al.* Prospective randomized pilot trial of selective biliary cannulation using pancreatic guide-wire placement. *Endoscopy* 2003;35:721-4.
16. Herreros de Tejada A, Calleja JL, Diaz G, Pertejo V, Espinel J, Cacho G, *et al.* Double-guidewire technique for difficult bile duct cannulation: A multicenter randomized, controlled trial. *Gastrointest Endosc* 2009;70:700-9.
17. Akashi R, Kiyozumi T, Jinnouchi K, Yoshida M, Adachi Y, Sagara K. Pancreatic sphincter precutting to gain selective access to the common bile duct: A series of 172 patients. *Endoscopy* 2004;36:405-10.
18. Kahaleh M, Tokar J, Mullick T, Bickston SJ, Yeaton P. Prospective evaluation of pancreatic sphincterotomy as a precut technique for biliary cannulation. *Clin Gastroenterol Hepatol* 2004;2:971-7.
19. Goff JS. Long-term experience with the transpancreatic sphincter pre-cut approach to biliary sphincterotomy. *Gastrointest Endosc* 1999;50:642-5.
20. Catalano MF, Linder JD, Geenen JE. Endoscopic transpancreatic papillary septotomy for inaccessible obstructed bile ducts: Comparison with standard pre-cut papillotomy. *Gastrointest Endosc* 2004;60:557-61.
21. Halttunen J, Keranen I, Udd M, Kylanpaa L. Pancreatic sphincterotomy versus needle knife precut in difficult biliary cannulation. *Surg Endosc* 2009;23:745-9.
22. Cotton PB, Lehman G, Vennes J, Geenen JE, Russell RC, Meyers WC, *et al.* Endoscopic sphincterotomy complications and their management: An attempt at consensus. *Gastrointest Endosc* 1991;37:383-93.
23. Gyokeres T, Duhl J, Varsanyi M, Schwab R, Burai M, Pap A. Double guide wire placement for endoscopic pancreaticobiliary procedures. *Endoscopy* 2003;35:95-6.

24. Yoo YW, Cha SW, Lee WC, Kim SH, Kim A, Cho YD. Double guidewire technique vs transpancreatic precut sphincterotomy in difficult biliary cannulation. *World J Gastroenterol* 2013;19:108-14.
25. Kapetanios D, Kokozidis G, Christodoulou D, Mistakidis K, Dimakopoulos K, Katodritou E, *et al.* Case series of transpancreatic septotomy as precutting technique for difficult bile duct cannulation. *Endoscopy* 2007;39:802-6.
26. Wang P, Zhang W, Liu F, Li ZS, Ren X, Fan ZN, *et al.* Success and complication rates of two precut techniques, transpancreatic sphincterotomy and needle-knife sphincterotomy for bile duct cannulation. *J Gastrointest Surg* 2010;14:697-704.
27. Wang P, Li ZS, Liu F, Ren X, Lu NH, Fan ZN, *et al.* Risk factors for ERCP-related complications: A prospective multicenter study. *Am J Gastroenterol* 2009;104:31-40.
28. Freeman ML, Nelson DB, Sherman S, Haber GB, Herman ME, Dorsher PJ, *et al.* Complications of endoscopic biliary sphincterotomy. *N Engl J Med* 1996;335:909-18.
29. Freeman ML, DiSario JA, Nelson DB, Fennerty MB, Lee JG, Bjorkman DJ, *et al.* Risk factors for post-ERCP pancreatitis: A prospective, multicenter study. *Gastrointest Endosc* 2001;54:425-34.
30. Cheng CL, Sherman S, Watkins JL, Barnett J, Freeman M, Geenen J, *et al.* Risk factors for post-ERCP pancreatitis: A prospective multicenter study. *Am J Gastroenterol* 2006;101:139-47.
31. Choudhary A, Bechtold ML, Arif M, Szary NM, Puli SR, Othman MO, *et al.* Pancreatic stents for prophylaxis against post-ERCP pancreatitis: A meta-analysis and systematic review. *Gastrointest Endosc* 2011;73:275-82.

Source of Support: Nil, **Conflict of Interest:** None declared.