



## An ultra-long new onset refractory status epilepticus: Winning the battle but losing the war?



Niccolò Orlandi<sup>a,b,1</sup>, Giada Giovannini<sup>a,h,1</sup>, Laura Mirandola<sup>b,c</sup>, Giulia Monti<sup>d</sup>, Andrea Marudi<sup>e</sup>, Francesco Mosca<sup>e</sup>, Alessandra Lalla<sup>f</sup>, Giuseppe d'Orsi<sup>g</sup>, Matteo Francavilla<sup>i</sup>, Stefano Meletti<sup>a,b,\*</sup>

<sup>a</sup> Neurology Unit, OCB Hospital, Azienda Ospedaliera-Universitaria, Modena, Italy

<sup>b</sup> Department of Biomedical, Metabolic and Neural Science, University of Modena and Reggio Emilia, Modena, Italy

<sup>c</sup> Neurology Unit, San Giovanni Bosco Hospital, Turin, Italy

<sup>d</sup> Neurology Unit, Ospedale Ramazzini di Carpi, AUSL Modena, Italy

<sup>e</sup> Intensive Care Unit, OCB Hospital, Azienda Ospedaliera-Universitaria, Modena, Italy

<sup>f</sup> Epilepsy Centre – S.C. Neurologia Universitaria, Policlinico Riuniti, Foggia, Italy

<sup>g</sup> Neurology Unit, IRCCS Casa Sollievo della Sofferenza, Foggia, Italy

<sup>h</sup> PhD Program in Clinical and Experimental Medicine, University of Modena and Reggio Emilia, Modena, Italy

<sup>i</sup> NORSE Institute, Summit, NJ, United States

### ARTICLE INFO

#### Article history:

Received 28 December 2021

Revised 20 March 2022

Accepted 21 March 2022

Available online 24 March 2022

#### Keywords:

New-Onset-Refractory Status Epilepticus

MRI

Claustrium

Treatment

Outcome

### ABSTRACT

New onset refractory status epilepticus (NORSE), is a rare and challenging condition occurring in previously healthy people. The etiology often remains undiscovered and is frequently associated with an unfavorable outcome. We report the electroclinical and neuroradiological evolution of an ultra-long case of NORSE of unknown etiology.

A 38-year-old woman with a prodrome of fever, vomiting and diarrhea was admitted to our Intensive Care Unit for refractory convulsive status epilepticus (SE). Her past medical history was unremarkable. Extensive examinations were negative for potential viral, autoimmune and metabolic etiologies. Despite multiple therapeutical attempts with antiseizures medications, anesthetics and immunotherapy, seizures persisted. After nearly 6 months of enduring seizures, SE finally ceased and the patient gradually recovered to a minimum state of awareness. She was then able to communicate through one-word utterances and to understand simple tasks. At a three-years follow-up, she developed multifocal drug-resistant epilepsy, subcortical myoclonus and severe spastic quadraparesis, becoming completely dependent for activities of daily living.

To our knowledge, this represents one of the longest cases of NORSE with final status resolution at this time. However, ultra-long SE in this case led to severe and disabling neurological sequelae. Future studies focused on disease modifying treatments for refractory SE are needed.

© 2022 The Author(s). Published by Elsevier Inc. This is an open access article under the CC BY-NC-ND license (<http://creativecommons.org/licenses/by-nc-nd/4.0/>).

### Introduction

New onset refractory status epilepticus (NORSE) is a neurologic syndrome characterized by highly refractory and abrupt-onset serial or prolonged seizures in people without active epilepsy or

preexisting relevant neurological disorders. In case of a preceding febrile illness preceding NORSE, this entity is subclassified as FIRES (Febrile Infection-Related Epilepsy Syndrome) and is more frequently reported in school-aged children.[1,2].

Despite extensive investigations, many cases remain without clear causes so that physicians are unable to provide an etiology-based therapy. Furthermore, patients are frequently exposed to prolonged and aggressive treatment in the attempt to suppress seizures. For these reasons, NORSE represents a challenging disorder with frequently unfavorable outcome.[3,4] Nevertheless, a few reports of variable recovery after prolonged SE have been reported.[5–7].

*Abbreviations:* FIRES, febrile infection-related epilepsy syndrome; NORSE, new onset refractory status epilepticus; PMA, peri-ictal MRI abnormality.

\* Corresponding author at: Department of Biomedical, Metabolic, and Neural Sciences, Center for Neurosciences and Neurotechnology, University of Modena and Reggio Emilia, Via Giardini, 1355 – Ospedale Civile S. Agostino Estense, Modena 41126, Italy.

E-mail address: [stefano.meletti@unimore.it](mailto:stefano.meletti@unimore.it) (S. Meletti).

<sup>1</sup> These authors contributed equally to the manuscript.

<https://doi.org/10.1016/j.ebr.2022.100537>

2589-9864/© 2022 The Author(s). Published by Elsevier Inc.

This is an open access article under the CC BY-NC-ND license (<http://creativecommons.org/licenses/by-nc-nd/4.0/>).

We present, herein, the electroclinical and neuroradiological evolution of a patient with 6 months of new-onset super-refractory SE of unknown etiology. We have focused on the ultra-long treatment course as well as on the long-term consequences of this condition. To date and to our knowledge, this represents one of the longest cases of NORSE consisting of 187 days of enduring seizures including a 42-month follow-up.

## Case presentation

### Acute phase

#### SE onset and initial manifestations

On August 14th 2016, a healthy 38-year-old woman presented to the emergency department for progressive asthenia, agitation and confusion. These symptoms were preceded by a weekly prodrome of high fever, vomiting, diarrhea and arthralgias for which she had already assumed amoxicillin. Her past medical and family history were unremarkable. She denied recent travels abroad and any possible substance abuse. Exposures to environmental toxins were also excluded, either at home or at work. On general physical examination, there were no signs of jaundice, petechial haemorrhages, splenomegaly or neck stiffness. Blood tests showed mild leucopenia and thrombocytopenia, associated with a moderate elevation of liver cytolysis enzymes. All microbiological examinations were negative, with the exception of low IgM antibody levels for Toscana virus (an arbovirus diffuse in Italy as well as in the Mediterranean region in Europe). Chest x-ray identified a right lung thickening, suggestive of a lobar pneumonia, so antibiotic therapy was started. Within hours from hospital admission, her mental status further deteriorated as she gradually became disoriented, disinhibited and lethargic. Encephalitis was suspected and a lumbar puncture was performed without abnormal findings in the cerebrospinal fluid (CSF). Afterwards, recurrent focal motor seizures occurred, which rapidly evolved into convulsive status epilepticus. Intravenous lorazepam was followed by a loading dose of 800 mg of phenytoin that was without benefit. Thereafter, the patient was transferred to the intensive care unit (ICU) and treated with tiopental (3 mg/Kg/h) and midazolam (0,13 mg/Kg/h). Initial round of anesthesia was titrated to clinical seizures suppression and a electroencephalogram (EEG) was obtained on day 2 which demonstrated diffuse slowing of electrocerebral activity without epileptiform discharges. Nevertheless, as soon as anesthesia was withdrawn, ocular and perioral myoclonia recurred, followed by generalized tonic-clonic seizures.

On day 7, the patient was transferred to the ICU of our institution. At that time, her antiseizures medications (ASMs) included lacosamide (400 mg/day), phenytoin (500 mg/day) levetiracetam (3000 mg/day) and phenobarbital (200 mg/day).

#### Laboratory and radiology examinations

An extensive investigation to exclude a central nervous system (CNS) infection was repeated. All microbiological investigations were negative, with the exception of low blood antibody titers for *Mycoplasma* and *Chlamydia Pneumoniae*, likely responsible for the previously identified pneumoniae (see Table 1). The aforementioned Toscana virus antibody seropositivity was no longer detectable, as well as signs of viral replication in the CSF.

Next, the hypothesis of an autoimmune disease was investigated. However, rheumatological screening, autoimmune and paraneoplastic surveys, including onconeural and surface antibodies testing, were negative. Repeat lumbar punctures (performed on day 10 and day 21) did not show significant results nor signs of intrathecal antibody synthesis. Conversely, p-tau was significantly increased as a marker of neurodegeneration. In addition,

onconeural and surface antibodies panel was negative in the CSF as well. The metabolic survey was unremarkable and genetic testing for POLG1-associated diseases was normal.

Additionally, a total body computerized tomography performed on day 11 did not identify a neoplasm. On day 52, an ultrasound of the ovaries was negative for teratomas. Due to the absence of anti-NMDAR antibodies, a dedicated magnetic resonance imaging (MRI) of the ovaries was not performed nor a selected ovariectomy was considered.

#### Neuroradiology and EEG examinations

A chronological description of the electroclinical and neuroradiological evolution of our patient is reported in Fig. 1. The first MRI of the brain, acquired on day 7, was normal (Fig. 1A). On day 29, the second MRI showed multiple, bilateral and asymmetric increased signal intensities on diffusion-weighted images and on T2/Fluid-attenuated inversion recovery sequences in several cortical and subcortical regions. These findings showed a fluctuating evolution on the following MRIs, without signs of ischemic or hemorrhagic infarction, nor involvement of specific vascular territories. Therefore, the hypothesis of a primary angiitis of CNS was considered to be remote and the aforementioned abnormalities were interpreted as perictal MRI changes (PMAs).[8–10] Consequently, we did not perform a digital subtraction angiography. In particular, PMAs involved the fronto-opercular, temporo-parietal, fronto-sagittal and insular cortex bilaterally, as well as the hippocampi, amygdala and thalamus. In most severe phases, bilateral claustrum involvement and diffuse leptomeningeal enhancement were documented too (Fig. 1B and C).

Continuous EEG monitoring (cEEG) documented several patterns during the course of the disease. The most striking pattern was represented by generalized periodic discharges (GPDs) with perioral myoclonia. The association of GPDs and myoclonus raised the concern of diffuse hypoxic-ischemic injury. However, periods of cardiac arrest or severe hypotension were not reported at seizures onset nor were documented in our ICU. Thereafter, other electroclinical patterns were identified, such as bilateral independent fronto-temporal seizures with facial myoclonia and lateralized periodic discharges (LPDs), mainly in the right temporo-occipital area, and bilateral independent focal seizures of frontal lobe origin with evolution to focal to bilateral tonic-clonic seizures. Of note is that the aforementioned EEG patterns showed a close topographical correlation with PMAs.

#### Therapeutic approach and clinical evolution

A combined polytherapy with ASMs and anesthetics was initiated. The dose ranges are reported in Fig. 2. Among the ASMs, maximum doses of the following ones were intravenously administered: phenytoin, levetiracetam, valproic acid, lacosamide and phenobarbital. Moreover, topiramate and perampanel were administered by enteral route. Third-line agents included propofol, midazolam, thiopental and ketamine. Despite multiple general anesthetic cycles titrated to a burst-suppression pattern on cEEG, seizures recurred after each attempt to taper anesthetics. Consequently, trials of immunotherapies were empirically initiated, including intravenous immunoglobulin (0.4 g/Kg over 5 days for two times), intravenous pulse steroid therapy (1 gr/day over 5 days for three times) and plasma exchange (one cycle of 5 consecutive days) yet SE persisted. After an initially promising result, the ketogenic diet was interrupted due to an elevation of liver and pancreatic enzymes, whereas other unconventional approaches, including sevoflurane-induced burst-suppression and therapeutic hypothermia, did not influence seizure frequency. Finally, on day 59, the patient was enrolled in the clinical trial SAGE-547, evaluating the role of intravenous allopregnanolone in super-refractory SE treatment, without benefit.

**Table 1**  
Serological and CSF investigations.

Blood tests		Results
<u>Serologies</u>	<i>Analysis</i> HSV1, HSV2, HHV6, HHV8, VZV, CMV, EBV, Polyomavirus, HBV, HCV, HIV, Morbillo virus, Enterovirus, Mycoplasma Pneumoniae, Chlamydia Pneumoniae, Borrelia Burgdorferi, Bartonella Henselae, Coxiella Burnetii, Rickettsia Conorii, Brucella Abortus, Brucella Melitensis, Salmonella Typhi, Salmonella Paratyphi, Micobacterium Tuberculosis, Treponema Pallidum, Rubella virus, Toxoplasma Gondii, Aspergillus spp, Cryptococcus neoformans, Chikungunya, Dengue, WNV, Toscana virus	All negative, with the exception of low antibody titers for Mycoplasma and Chlamydia Pneumoniae
<u>PCR tests</u>	HSV1, HSV2, HHV6, HHV7, HHV8, VZV, Adenovirus, Enterovirus, Morbillo virus, CMV, WNV, Zika virus, Toscana virus, Leishmania sp.	All negative
<u>Onco-hematological survey</u>	Lymphocyte typing, Beta 2-microglobulin protein, Serum protein electrophoresis, CA 19.9, CA15.3, CA 125, CEA	All negative, with the exception of slight increase of Beta 2-microglobulin level (3.93 mg/L; n.v. 0.8–2.4 mg/L)
<u>Autoimmune panel</u>	ANA, ANCA, ASMA, AMA, anti-LC1 Ab, ARIA, LAC, anti-cardiolipin Ab, anti-beta2-GPI Ab, AOVA, C3, C4, Rheumatoid Factor, anti-TGB Ab, anti-TPO Ab, Cryoglobulins, anti-NMDAR Ab, anti-AMPA Ab, anti LGI-1 Ab, anti-CASPR2 Ab, anti-GABAR Ab, anti-GAD Ab, anti-Yo Ab, anti-Hu Ab, anti-Ri Ab, anti-DPPX Ab, anti-Ma2 Ab.	All negative
<u>Metabolic survey</u>	Ammonia, urea, lactic acid, lead, copper	All negative
Cerebrospinal fluid analysis (1 <sup>st</sup> LP, day #10)		
<u>Cytochemical evaluation</u>	Appearance	Clear
	Glucose	113 mg/dl
	Proteins	47 mg/dl
	White blood cells	3 cells/mm <sup>3</sup>
	Citology	Rare neutrophil granulocytes
<u>Microbiology panel</u>	HSV1, HSV2, HHV6, HHV7, HHV8, VZV, CMV, EBV, Adenovirus, Polyomavirus JC, Polyomavirus BK, Parvovirus B19, Enterovirus, Morbillo virus, Respiratory syncytial virus, Borrelia Burgdorferi, Micobacterium Tuberculosis, Treponema Pallidum, Toxoplasma Gondii, Aspergillus spp, Cryptococcus spp, Chikungunya, Dengue, WNV, Zika virus, Toscana virus	All negative
<u>Autoimmune panel</u>	anti-NMDAR Ab, anti-AMPA Ab, anti LGI-1 Ab, anti-CASPR2 Ab, anti-GABAR Ab, anti-GAD Ab, anti-Yo Ab, anti-Hu Ab, anti-Ri Ab, anti-DPPX Ab, anti-Ma2 Ab.	All negative
<u>Neuroimmunology survey</u>	Albumin serum	2290 (n.v 3500–5200 mg/dl)
	IgG serum	721 (n.v 800–1700 mg/dl)
	Albumine liquor	13,17 (n.v 15–30 mg/dl)
	IgG liquor	3 (n.v 2–4 mg/dl)
	Link index (QIgG/QALb)	0,72 (n.v <0,70)
	Reiber index	0,03 (n.v <= 0)
	BCSFB index	0,58 (n.v <0,7%)
	Isoelectrofocusing	Type 3 pattern (2 additional OCB in CSF)
<u>Neurodegeneration biomarkers</u>	Tau protein	> 2358 pg/ml (n.v <300 pg/ml)
	p-Tau protein	58 pg/ml (n.v < 61 pg/ml)
	B-amiloide 1-42	576 pg/ml (n.v > 500 pg/ml)
	14-3-3	Positive
Cerebrospinal fluid analysis (2 <sup>nd</sup> LP, day #21)		
<u>Cytochemical evaluation</u>	Appearance	Clear
	Glucose	86 mg/dl
	Proteins	57 mg/dl
	White blood cells	1 cell/mm <sup>3</sup>
<u>Autoimmune panel</u>	anti-NMDAR Ab, anti-AMPA Ab, anti LGI-1 Ab, anti-CASPR2 Ab, anti-GABAR Ab, anti-GAD Ab, anti-Yo Ab, anti-Hu Ab, anti-Ri Ab, anti-DPPX Ab, anti-Ma2 Ab.	All negative
<u>Neuroimmunology survey</u>	Albumin serum	3350 (n.v 3500–5200 mg/dl)
	IgG serum	500 (n.v 800–1700 mg/dl)
	Albumine liquor	33,77 (n.v 15–30 mg/dl)
	IgG liquor	2,96 (n.v 2–4 mg/dl)
	Link index (QIgG/QALb)	0,59 (n.v <0,70)
	Reiber index	–1,01 (n.v ≤ 0)
	BCSFB index	1,01 (n.v <0,7%)
	Isoelectrofocusing	Type 4 pattern
<u>Neurodegeneration biomarkers</u>	Tau protein	> 2358 pg/ml (n.v <300 pg/ml)
	p-Tau protein	53 pg/ml (n.v <61 pg/ml)
	B-amiloide 1-42	786 pg/ml (n.v >500 pg/ml)

HSV1: Herpes simplex virus 1; HSV2: Herpes simplex virus 2; HHV6: Human herpes virus 6; HHV7: Human herpes virus 7; HHV8: Human herpes virus 8; VZV: Varicella Zoster virus; CMV: Cytomegalovirus; EBV: Epstein Barr virus; WNV: West Nile virus; ARIA: Anti-ribosomal antibodies; AMA: Anti-mitochondrial antibodies; ANCA: Anti-neutrophil granulocytes antibodies; anti-TPO antibodies: anti- thyroperoxidase antibodies; TGB: thyroglobulin; BCSFB: Blood cerebral spinal fluid barrier; OCB: oligoclonal bands; AOVA: anti-ovarian antibodies; LP: Lumbar puncture.

As we were facing multiple therapeutical failures, several medical complications occurred. Particularly, the extremely prolonged length of stay in an intensive care setting led to recurrent infections, pressure ulcers and anesthetics-related side effects (e.g

hypotension requiring catecholamine support, bradycardia, acute lung injury and multiple organ failure). In the most critical situations, the issue whether proceeding to a palliative care was raised, but not pursued. Even if resolution of SE led to life with severe dis-

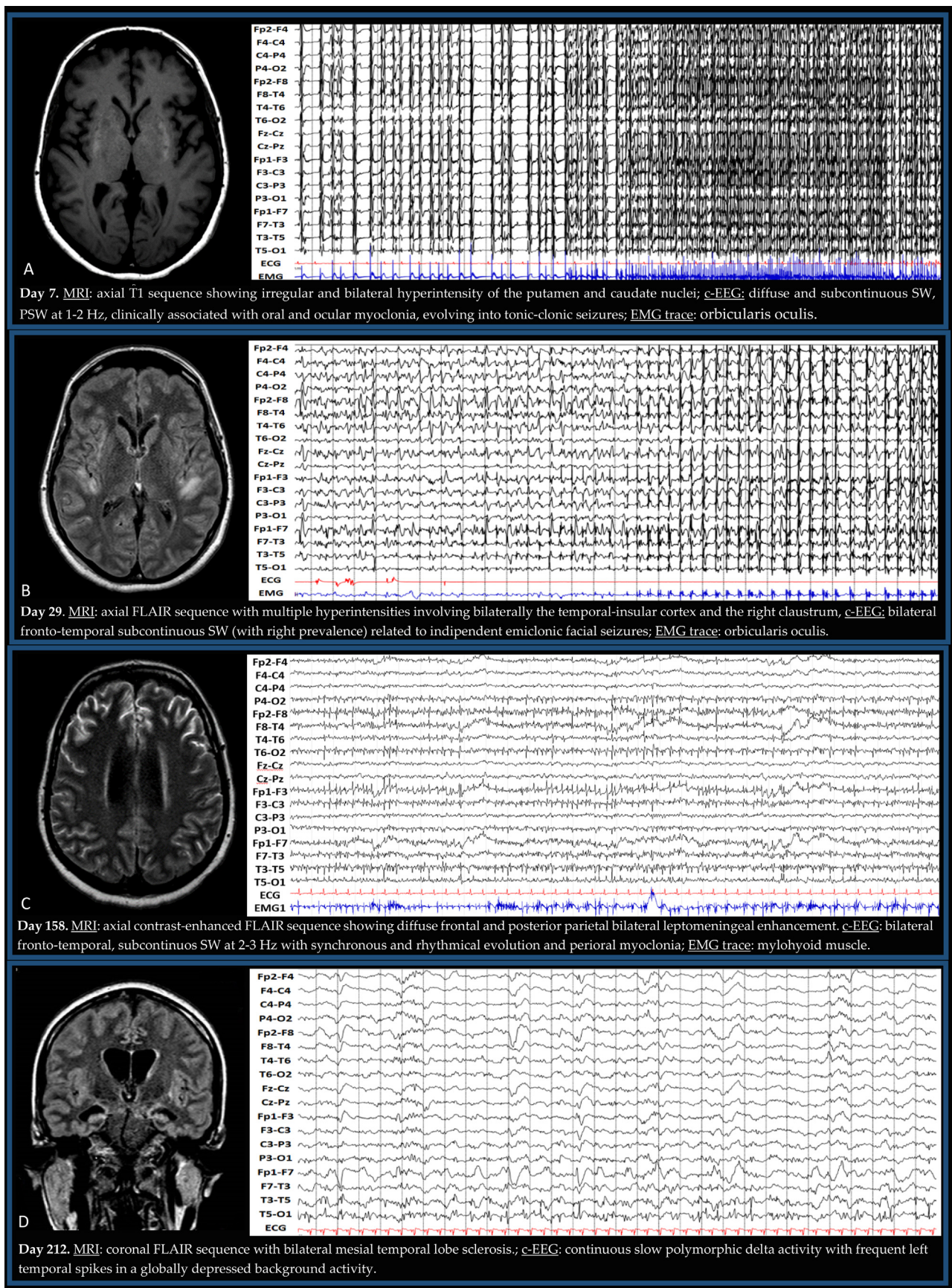
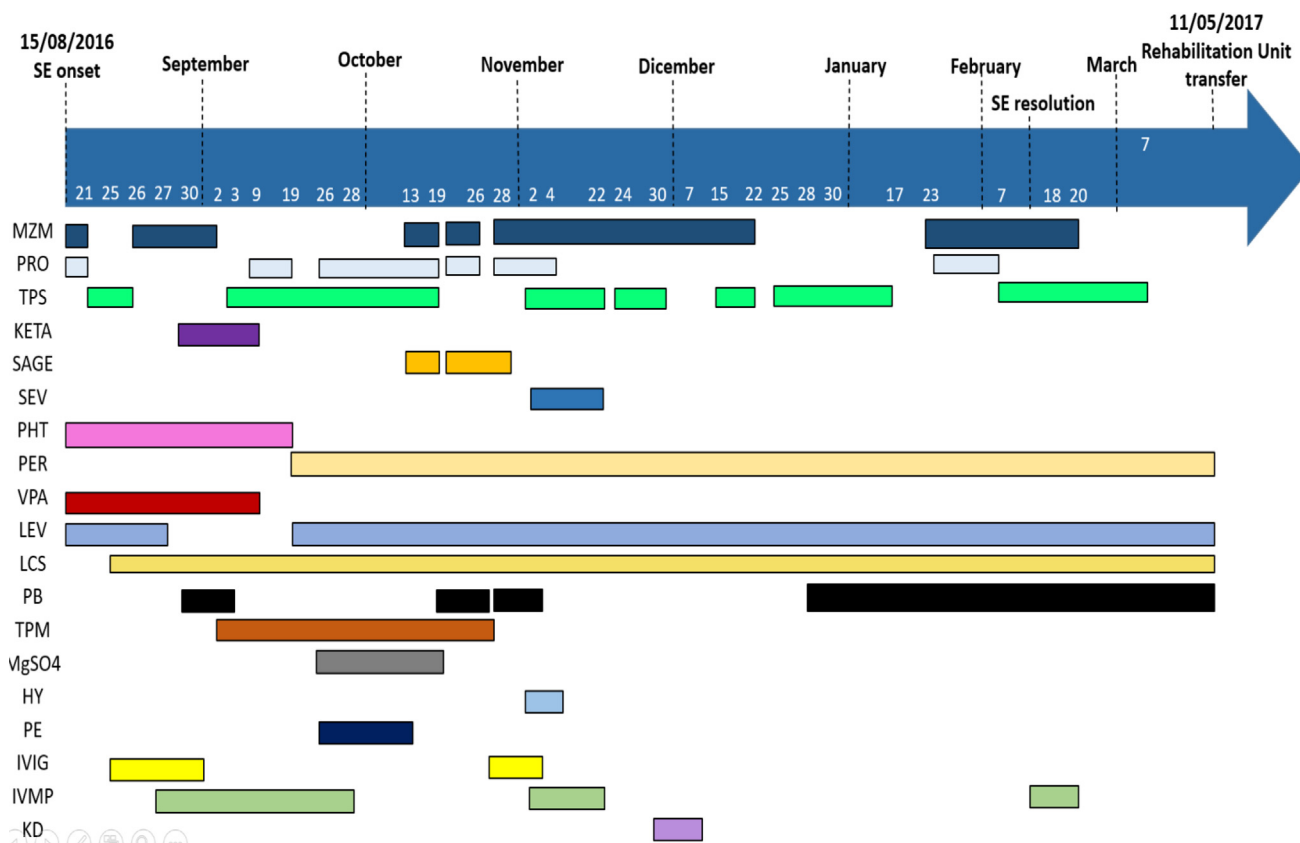


Fig. 1. MRI and EEG evolutions. EEG recording parameters: high pass filter: 0.3 Hz, low pass filter: 30 Hz, Notch: 50 Hz, amplitude: 14 uV/mm, frequency: 30 s/ppg.



**Fig. 2.** Therapeutical management of SE. Figure legend and range of dosages: MZM: Midazolam (0,13–0,3 mg/Kg/h); PRO: Propofol (2–6,6 mg/Kg/h); TPS: Thiopental sodium (1–5 mg/Kg/h); KETA: Ketamine (2–4 mg/Kg/h); SAGE: Allopregnanolone; SEV: Sevoflurane; PHT: Phenytoin (250–750 mg/day); PER: Perampanel (8–16 mg/day); VPA: Valproate (500–2000 mg/day); LEV: Levetiracetam (2000–3000 mg/day); LCS: Lacosamide (400–600 mg/day); PB: Phenobarbital (200–300 mg/day); TPM: Topiramate (300–600 mg/day); MgSO4: Magnesium Sulphate; HY: Hypothermy; PE: Plasma exchange; IVIG: Intravenous immunoglobulin; IVMP: Intravenous Methylprednisolone; KD: Ketogenic diet.

ability, family members and clinicians agreed to keep supportive measures. Consequently, on day 14 tracheostomy was performed for protection of the airway. On day 157, percutaneous endoscopic gastrostomy (PEG) tube nutrition was initiated to provide adequate nutritional support.

*SE resolution and late clinical evolution*

Unexpectedly, on February 17th 2017 (187 days from its onset), SE finally resolved. At this stage ASMs included: levetiracetam (3000 mg/day), lacosamide (600 mg/day), perampanel (12 mg/day) and phenobarbital (200 mg/day). The patient was also sedated with midazolam (0,1 mg/Kg/h) and thiopental (2 mg/kg/h).

Continuous EEG monitoring showed a progressive reorganization of background electrocerebral activity and the development of slow-wave sleep patterns. Concomitantly, PMAs gradually resolved and the last brain MRI showed diffuse brain atrophy, multifocal gliosis and bilateral mesial temporal sclerosis (Fig. 1D). On day 263, the patient was discharged to a neuro-rehabilitation center in a minimal state of self-awareness. At this stage, she was awake, able to inconsistently execute simple tasks and able to orient her gaze to the examiner. Sometimes, she also showed contextualized emotional expressions, such as smiles, in response to her relatives. She developed a critical illness polyneuropathy/myopathy with flaccid tetraplegia and subcortical myoclonus. At hospital discharge, ASMs included: clonazepam (6 mg/day), lacosamide (600 mg/day), perampanel (8 mg/day), levetiracetam (3000 mg/day) and phenobarbital (300 mg/day).

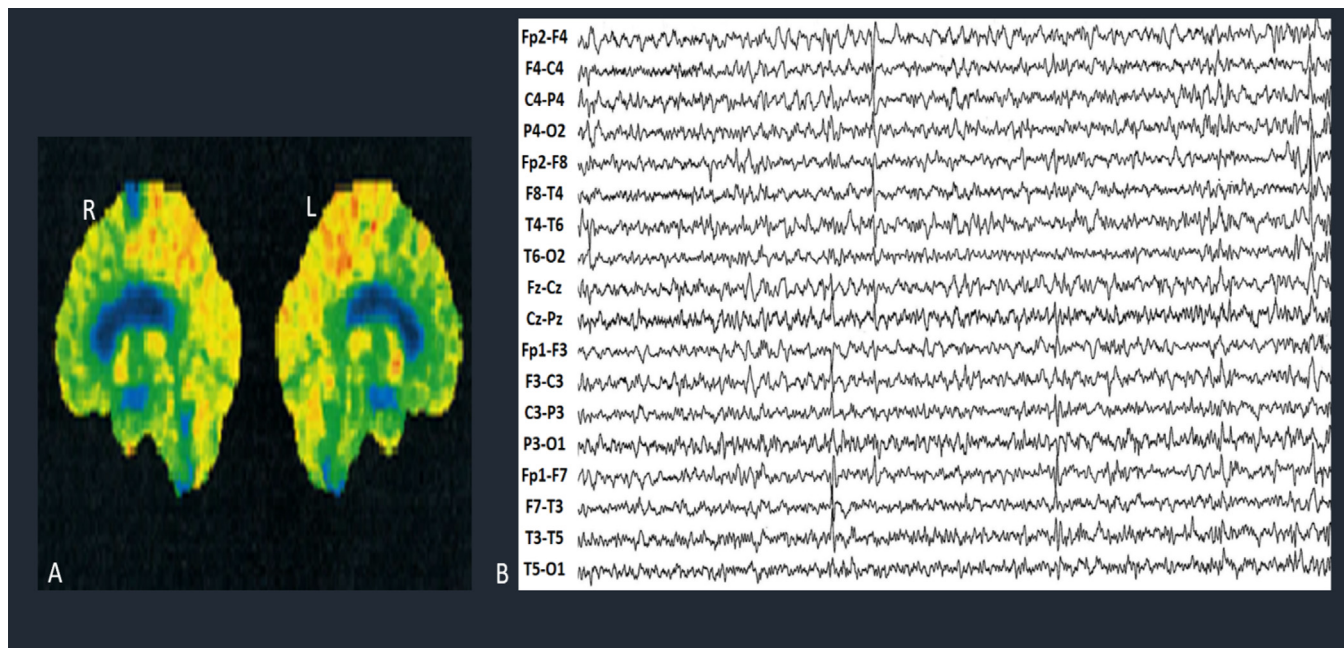
*Chronic phase*

Fourteen months after SE resolution, the patient was able to communicate through one-word utterances and to understand simple tasks. Nevertheless, she presented daily consciousness fluctuations, sphincteric incontinence and a severe spastic quadraparesis. A 18-FDG-PET documented a multifocal brain hypometabolism, mainly involving the right frontal cortex and the cingulate gyrus bilaterally, while video-EEG showed bilateral independent fronto-centro-temporal spike-and-slow waves (Fig. 3).

The patient continued intensive neurological rehabilitation and, 19 months after SE resolution, she was finally discharged home, with partial improvement in the interaction with the surrounding environment.

Tracheostomy was removed while PEG was maintained with a semi-solid oral diet. She could not walk nor converse, so that it was not possible to perform a neuropsychological evaluation. In addition, she became completely dependent as determined by the Activities of Daily Living (ADL 0/6) and the Instrumental Activities of Daily Living (IADL 0/8) scales.

At the last medical contact (42-months after SE resolution), she continued to take ASMs for multifocal drug-resistant epilepsy with montly generalized myoclonic seizures and focal non-motor seizures with behavioral arrest and oral automatisms. Less frequently, focal to bilateral tonic-clinic seizures were also documented. No other episode of SE occurred, even in case of concurrent infections. Her current antiseizure medications included clonazepam (2.5 mg/day), lacosamide (400 mg/day), perampanel (8 mg/day), brivarac-



**Fig. 3.** Long-term neuroradiological and EEG evolution 14 months after SE resolution. A) 18-Fluorodeoxyglucose brain PET scan showing hypometabolism in the right posterior frontal cortex and in the cingulate gyrus bilaterally; B) EEG showing bilateral independent fronto-centro-temporal spike-and-slow waves on a slightly depressed and partially reactive background. EEG recording parameters: high pass filter:0.3 Hz, low pass filter: 30 Hz, Notch: 50 Hz, amplitude:14 uv/mm, frequency: 30 s/pg. Legend: R: Right, L: Left.

etam (200 mg/day) and phenobarbital (50 mg/day). Multiple attempts to remove phenobarbital were performed, but constantly led to an increase in seizure frequency.

**Discussion**

We described the eletroclinical and neuroradiological evolution of a six-month-lasting case of adult-onset FIRES (as a subcategory of NORSE). As previously reported in other series,[11,12] this entity shows typical clinical features such as: (a) a prodromal mild febrile illness, (b) recurrent focal motor or focal to bilateral tonic-clonic seizures evolving into prolonged SE without a prior history of epilepsy and (c) the absence of identifiable causative factors.

During the course of the disorder, cEEG monitoring and close neuroradiological evaluations documented several cerebral changes related to recurring seizures. As previously reported in other series,[4,12] an initial negative brain MRI was followed by diffuse T2/FLAIR hyperintense foci variably involving cortical, subcortical and infratentorials regions. These abnormalities have been proposed to be the reflection of a variety of biochemical and histological changes occurring at tissutal and cellular level, due to seizure recurrence.[8,9] To date, definite radiologic prognostic factors for assessing functional outcome in NORSE have not yet been validated. However, diffuse leptomenigeal enhancement seems to be associated with a worse functional outcome,[13] while claustrum involvement is typically associated with aggressive refractory SE after a febrile illness.[10,14].

The physiopathological mechanisms responsible for seizures onset and perpetuation in NORSE/FIRES have not been completely understood. Recently, Sculier and Gaspard[15] proposed a helpful diagnostic and treatment algorithm and reviewed latest relevant findings. Particularly, autoimmune or paraneoplastic encephalitis have been suggested to be a possible cause of this entity,[11,16] even in the case where a specific anti-neural antibodies has not been detected. Consequently, immunotherapeutic strategies have been increasingly proposed in the treatment of NORSE of unknown

etiology, with variable results.[12] On the other hand, following the increasing knowledge of the relationship between inflammation and epileptogenesis, it has been speculated that seizures could be caused (or exacerbated) by an excess of pro-inflammatory molecules in the brain following a systemic trigger (e.g even a minor infection) in susceptible individuals.[17] This hypothesis is supported by experimental data demonstrating microglia[18] and astrocytic involvement in increasing cortical excitability through proconvulsant cytokine release,[19,20] with upregulation of CSF cytokines levels during NORSE and FIRES.[21–23] Seizures, themselves, can lead to a cascade of cytokine-mediated events, further contributing to the progression of an inflammation-mediated status epilepticus.[16] Encouraging results have been reported regarding the administration of IL-6 and IL-1 receptor antagonist antibodies in case series of patients with NORSE[22] and FIRES [23,24]. Regarding our case, interleukin inhibitors were not administered due to the limited supporting evidence at that time of occurrence in 2016 though despite this lack of treatment, SE eventually resolved. We were not able to assess whether a combination of drugs was effective in inducing seizures resolution or if status epilepticus simply “burned out”. The absence of a clear etiological agent and a prodromal phase with flu-like symptoms further validate the hypothesis of an inflammation-mediated process, that finally resolved. From this standpoint, it has been suggested that long-standing drug-resistant epilepsies may eventually reach a point of spontaneous terminal resolution and result in seizure freedom.[25].

Our patient spent 187 days in SE, whereas Aurangzeb[7] and Sawicka[6] described two cases lasting 210 and 110 days, respectively. At hospital discharge, the first patient was able to communicate appropriately and to mobilize, whereas the latter patient had mild cognitive deficits and infrequent seizures as a residual effect. In comparison with the aforementioned studies, neurological sequelae were much more disabling in our case. Limited details on long-term outcomes and quality of life have been previously provided.

## Conclusion

We described the third longest case of NORSE recorded in the literature, involving a patient with severe neurological sequelae persisting at 42 months following resolution of SE. Our report highlights how enduring epileptic seizures can lead to a wide array of neuroradiological and EEG alterations and how a multidisciplinary approach is required in the management of ultra-long cases.

Satisfactory outcomes are unusual after NORSE patients, raising the need for urgent disease modifying therapies that in the future could change a patients' clinical outcome and facilitate their recovery to result in a more favorable quality of life.

## Ethical statement

The authors declare their compliance with all relevant ethical regulations. We also confirm that we have read the Journal's position on issues involved in ethical publication and affirm that this work is consistent with those guidelines.

## Declaration of Competing Interest

The authors declare the following financial interests/personal relationships which may be considered as potential competing interests: S.M. has received personal compensation as scientific advisory board member for UCB and Eisai. None of the other authors has any conflict of interests to disclose.

## References

- [1] Gaspard N, Hirsch LJ, Sculier C, et al. New-onset refractory status epilepticus (NORSE) and febrile infection-related epilepsy syndrome (FIRES): State of the art and perspectives. *Epilepsia* 2018;59(4):745–52.
- [2] Hirsch L, Gaspard N, van, Baalen A, et al. "Proposed consensus definitions for new-onset refractory status epilepticus (NORSE), febrile infection-related epilepsy syndrome (FIRES), and related conditions". *Epilepsia* 2018;59(4):739–44.
- [3] Kang C, Gaspard N, LaRoche S, et al. Survey of the diagnostic and therapeutic approach to new-onset refractory status epilepticus. *Seizure* 2017;46:24–30.
- [4] Matthews E, Alkhatroum A, Massad N, et al. New-onset super-refractory status epilepticus: A case series of 26 patients. *Neurology* 2020;95(16):e2280–5.
- [5] Ferlisi M, Greco E, Zanoni T, et al. A case of very prolonged new onset refractory status epilepticus (NORSE) with no evidence of autoimmune activation and a good neurological recovery. *Neurol Sci* 2020;41(10):3003–6.
- [6] Sawicka K, Cooley R, Hunter G. New Onset Refractory Status Epilepticus (NORSE) Lasting 100 days resulting in a positive outcome. *Neurology* April 05 2016;86(16 Supplement).
- [7] Aurangzeb S, Prisco L, Adcock J, et al. New-onset super refractory status epilepticus: A case-series. *Seizure* 2020;75:174–84.
- [8] Giovannini G, Kuchuchidze G, McCoy M, et al. Neuroimaging alterations related to status epilepticus in an adult population: definition of MRI findings and clinical-EEG correlation. *Epilepsia* 2018;59(Suppl 2):120–7.
- [9] Meletti S, Monti G, Mirandola L, et al. Neuroimaging of status epilepticus. *Epilepsia* 2018;59(Suppl 2):113–9.
- [10] Meletti S, Slonkova J, Mareckova I, et al. Claustrum damage and refractory status epilepticus following febrile illness. *Neurology* 2015;85(14):1224–32.
- [11] Gaspard N, Foreman B, Alvarez V, et al. New-onset refractory status epilepticus. Etiology, clinical features, and outcome". *Neurology*. 2015 Nov 3. 85(18), 1604–1613.
- [12] Iizuka T, Kanazawa N, Kaneko J, et al. Cryptogenic NORSE: Its distinctive clinical features and response to immunotherapy. *Neurol Neuroimmunol Neuroinflamm* 2017;4(6):e396.
- [13] Kim H, Lee S, Kim H, et al. The timelines of MRI findings related to outcomes in adult patients with new-onset refractory status epilepticus. *Epilepsia* 2020;61(8):1735–48.
- [14] Meletti S, Giovannini G, d'Orsi G, et al. New-Onset Refractory Status Epilepticus with Claustrum Damage: Definition of the Clinical and Neuroimaging Features. *Front Neurol* 2017;27(8):111.
- [15] Sculier C, Gaspard N "New onset refractory status epilepticus (NORSE)". *Seizure* 2019;68:72–8.
- [16] Lattanzi S, Leitinger M, Rocchi C, et al. Unraveling the enigma of new-onset refractory status epilepticus: a systematic review of aetiologies. *Eur J Neurol* 2022;29(2):626–47.
- [17] Saitoh M., Kobayashi K., Ohmori I, et al. "Cytokine-related and sodium channel polymorphism as candidate predisposing factors for childhood encephalopathy FIRES/AERRPS". *Journal of the Neurological Sciences*. 2016 Jul. 368, 272–276.
- [18] Hiragi T, Ikegaya Y, Koyama R. Microglia after Seizures and in Epilepsy. *Cells* 2018;7(4):26.
- [19] Rodgers K, Hutchinson M, Northcutt A, et al. The cortical innate immune response increases local neuronal excitability leading to seizures. *Brain* 2009;132(Pt 9):2478–86.
- [20] Vezzani A, Balosso S, Ravizza T. "The role of cytokines in the pathophysiology of epilepsy". *Brain Behav Immun*. 2008 Aug. 22(6). 797–803.
- [21] Sakuma H, Tanuma N, Kuki I, et al. "Intrathecal overproduction of proinflammatory cytokines and chemokines in febrile infection-related refractory status epilepticus. *J Neurol Neurosurg Psychiatry* 2015;86(7):820–2.
- [22] Jun J, Lee S, Kim R, et al. Tocilizumab treatment for new onset refractory status epilepticus. *Ann Neurol* 2018;84(6):940–5.
- [23] Kenney-Jung D, Vezzani A, Kahoud R, et al. Febrile infection-related epilepsy syndrome treated with anakinra. *Ann Neurol* 2016;80(6):939–45.
- [24] Westbrook C, Subramaniam T, Seagren R, et al. Febrile Infection-Related Epilepsy Syndrome Treated Successfully With Anakinra in a 21-Year-Old Woman. *WMJ* 2019;118(3):135–9.
- [25] Rajakulendran S et al. Late-life terminal seizure freedom in drug-resistant epilepsy: "Burned-out epilepsy". *J Neurol Sci* 2021;431:120043.