

## Evaluation of Thyroid Lesions by Fine-needle Aspiration Cytology According to Bethesda System and its Histopathological Correlation

### Abstract

**Background:** The Bethesda system is a uniform reporting system for thyroid cytology that facilitates the clarity of communication among cytopathologists, radiologists, and surgeons and facilitates cytohistologic correlation for thyroid diseases. **Objective:** This study was carried out to evaluate thyroid lesions by fine-needle aspiration cytology (FNAC) based on Bethesda system of reporting and to correlate the cytological findings with histopathology. **Materials and Methods:** A total of 606 patients with thyroid lesions were studied by FNAC at our institute between January 1, 2006, and January 31, 2016, and results were compared with histopathology wherever possible. **Results:** Based on the Bethesda system of classification of thyroid lesions, out of 580 satisfactory samples; 501 lesions were diagnosed as benign (Group 1), five were in category of atypical follicular lesion of atypia undetermined significance (Group 2), 55 were diagnosed as suspicious for follicular neoplasm (Group 3), 7 as suspicious for malignancy (Group 4), and 12 cases were malignant (Group 5). 26 aspirates were nondiagnostic even after reaspiration. In the present study, cytohistopathological correlation was done in 148 benign and 18 malignant lesions. The sensitivity of FNAC was 85.7%, specificity 98.6%, and diagnostic accuracy 97.7%. **Conclusion:** Reviewing the thyroid FNAs with the Bethesda system for reporting allowed precise cytological diagnosis. It represents standardization and reproducibility in reporting thyroid cytology with improved clinical significance and greater predictive value. Nature of the disease, experience of cytopathologist, and understanding of certain limitations determine its diagnostic utility.

**Keywords:** *Cytohistologic correlation, fine-needle aspiration, thyroid lesions*

### Introduction

The incidence of clinically apparent thyroid swellings in the general population is 4%–5%.<sup>[1]</sup> Majority of these swellings are benign in nature, among which goiter being most common. The prevalence of goiter is more than 40 million in India with more than 2 billion globally.<sup>[2]</sup> The incidence of thyroid cancer in nodules varies from approximately 0.1% in the general population to 20% in surgically biopsied nodule.<sup>[3,4]</sup>

Fine-needle aspiration cytology (FNAC) of the thyroid gland is now a well-established, first-line diagnostic test for the evaluation of diffuse thyroid lesions as well as of thyroid nodules with the main purpose of confirming benign lesions and thereby, reducing unnecessary surgery.<sup>[5]</sup> Thyroid cytology can provide a definite diagnosis of malignancy, with tumor type, enabling appropriate therapeutic surgery in one

stage. It can triage the remaining patients into those who potentially require surgical as opposed to medical/endocrinological management.<sup>[6]</sup> Role of thyroid cytology is twofold: Therapeutic and diagnostic.<sup>[7]</sup> Patients got relieved from compressive symptoms after aspiration of fluid from their thyroid swellings, thus serving a therapeutic function. Thyroid swellings that are considered for FNAC include diffuse, firm, palpable, solitary nodules, nodules associated with suspicious clinical or ultrasonographic features, dominant nodules in a multinodular goiter, recurrent cystic nodules, and nodules associated with palpable lymph nodes.<sup>[8]</sup>

However, limitations in FNAC due to scanty sample, vascularity of thyroid swelling, variation in sampling technique, and skill of the performing expert as well as the experience of pathologist interpreting the aspirate do pose a problem in definitive diagnosis.<sup>[9]</sup> Previously, thyroid FNAC had a reporting confusion due to multiplicity of

**Shirish S. Nandedkar,**  
**Monal Dixit<sup>1</sup>,**  
**Kamal Malukani<sup>1</sup>,**  
**Amit V Varma<sup>1</sup>,**  
**Shankhini Gambhir<sup>1</sup>**

*Department of Pathology, R. D. Gardi Medical College, Ujjain, <sup>1</sup>Department of Pathology, Sri Aurobindo Institute of Medical Sciences, Indore, Madhya Pradesh, India*

**Received:** 15 May, 2017.  
**Accepted:** 25 Jan, 2018.

### Address for correspondence:

*Dr. Kamal Malukani,  
601, Akansha Apartment,  
Sri Aurobindo Medical College  
Campus, Indore-Ujjain Highway,  
Indore, Madhya Pradesh, India.  
E-mail: kamal.malukani@yahoo.  
com*

### Access this article online

**Website:**  
[www.ijabmr.org](http://www.ijabmr.org)

**DOI:**  
10.4103/ijabmr.IJABMR\_169\_17

### Quick Response Code:



**How to cite this article:** Nandedkar SS, Dixit M, Malukani K, Varma AV, Gambhir S. Evaluation of thyroid lesions by fine-needle aspiration cytology according to Bethesda system and its histopathological correlation. *Int J App Basic Med Res* 2018;8:76-82.

This is an open access journal, and articles are distributed under the terms of the Creative Commons Attribution-NonCommercial-ShareAlike 4.0 License, which allows others to remix, tweak, and build upon the work non-commercially, as long as appropriate credit is given and the new creations are licensed under the identical terms.

**For reprints contact:** [reprints@medknow.com](mailto:reprints@medknow.com)

category terminologies. To overcome this, The Bethesda System For Reporting Thyroid Cytopathology was introduced in 2007 at “Thyroid Fine Needle Aspiration State of the Science Conference” held in Bethesda, Maryland, for unifying the terminology and morphologic criteria along with the corresponding risk of malignancy.<sup>[10]</sup>

### Aim

The aim of the present study was to assess the diagnostic utility of the Bethesda system of reporting thyroid cytology and to find out the accuracy of FNAC by comparing the results with histopathology.

### Materials and Methods

A cross-sectional type of study during the 10 years period, from January 1, 2006 to January 31, 2016, was conducted in the Department of Pathology with approval from ethical committee of our institute. All patients having clinically palpable thyroid swellings, irrespective of their age and sex, were included in the study. Exclusion criteria were (1) patients not willing for FNAC of thyroid lesions even after explaining the purpose, utility, and consequences of the procedure, (2) lesions of parathyroid, lymph nodes, and other surrounding structures.

For retrospective study, the records of the patients who have undergone FNAC of thyroid were collected from the files. For prospective cases, before FNA, clinical history, physical findings, and provisional clinical diagnosis was noted in a pro forma. Written informed consent was obtained from all the patients. FNAC was done under aseptic conditions using 23G needles with 10 cc or 20 cc disposable syringes. Two to three passes were made. If the swelling was cystic, fluid was aspirated. The material aspirated was immediately transferred onto glass slides, half of which were air dried and half alcohol fixed for Giemsa stain and Papanicolaou stain, respectively. Stained smears were evaluated according to Bethesda system of reporting thyroid lesions. Smears were considered adequate for evaluation if it contained at least six well-preserved and well-stained follicular groups, each containing at least ten cells. In cases of colloid cysts, abundant thick colloid obtained was considered as adequate for diagnosis, irrespective of a minimum number of follicular cells. Smears showing atypical cells were never considered inadequate, regardless of cellularity. Subsequent histopathologic examination was done in 171 cases. For retrospective cases, paraffin blocks and slides were retrieved from the Department of Surgical Pathology and reviewed. For prospective cases, all surgical specimens were received in 10% neutral buffered formalin. The findings of gross examination of surgical specimens were noted. Tissues were processed; sections were cut by microtome and evaluated after staining by Hematoxylin and Eosin method. Analysis of various thyroid lesions in relation to age and gender was done,

cytological correlation was done in all 171 cases, and diagnostic accuracy of FNAC was calculated.

### Results

A total of 606 patients were included in this study, of which 81% were females and 19% were males with F:M ratio 4.2:1. The age of presentation ranged from 2 years to 87 years with a mean age of 37.6 years. Most of the patients ( $n = 458$ ) were in age range of 21–50 years accounting for 75.5% of the total cases. The youngest patient was of 2-year-old and diagnosed as having thyroglossal cyst, whereas oldest patient was 87 years old and diagnosed as having non-Hodgkin's lymphoma. Majority of cases presented with thyroid swellings ( $n = 532$ ) that moved with deglutition. Out of 606 cases, 15 swellings moved up with both deglutition and protrusion of tongue which were later confirmed on cytology and histopathology as thyroglossal cysts. A few patients complained of pain and difficulty during swallowing or breathing. All the patients tolerated the FNA procedure well without any complications.

On gross examination, the majority of thyroid aspirates were hemorrhagic (37.9%), followed by colloid-like aspirate (29.8%), and cystic fluid (27.3%). Majority of cases (78.87%,  $n = 478$ ) yielded good cellularity on FNAC done in the first attempt whereas in 83 cases (13.69%) more number of needle passes were tried. In 45 cases (7.42%), we did not have any data about the number of passes taken. Out of total 606 aspirates, 580 were satisfactory for interpretation based on Bethesda system of classification of thyroid lesions while 26 aspirates were unsatisfactory.

According to routine cytological reporting, more than half the numbers of cases in the present study were diagnosed as goiter (57.41%,  $n = 333$ ) which also included goiter with cystic degeneration or other secondary change as well as nodular goiter. Second most common lesion diagnosed was colloid cyst (10.34%,  $n = 60$ ) which also included one case of infected cystic lesion. Among other benign lesions, lymphocytic thyroiditis accounted for 8.10% ( $n = 47$ ), adenomatous goiter/hyperplastic nodule 6.9% ( $n = 40$ ), thyroglossal cyst 3.28% ( $n = 19$ ), Hashimoto's thyroiditis 2.59% ( $n = 15$ ), and granulomatous thyroiditis 1.21% ( $n = 7$ ). Among malignant lesions, 7.07% cases ( $n = 41$ ) were diagnosed as follicular neoplasms (FN), 2.24% ( $n = 13$ ) as papillary carcinoma, 0.52% ( $n = 3$ ) as medullary carcinoma, and 0.34% ( $n = 2$ ) as anaplastic carcinoma.

According to the Bethesda system of reporting thyroid lesions, nondiagnostic category (Group 1) included 26 cases (4.29%), and histopathology was not available in any of the case of this category. Out of 580 satisfactory samples, 501 (82.67%) cases were diagnosed as benign (Group 2), 5 (0.82%) cases were in the category of atypia of undetermined significance (AUS)/atypical follicular lesion of undetermined significance (Group 3), 55 (9.07%) cases were diagnosed as suspicious for

FN (SFN) (Group 4), 7 (1.15%) cases were suspicious for malignancy (SM) (Group 5), and 12 (1.98%) cases were malignant (Group 6).

- Group 1: Inadequate/nondiagnostic category-26 aspirates (4.29% of total cases) were categorized as inadequate for evaluation or nondiagnostic
- Group 2: Benign lesions included colloid goiter (57.07%,  $n = 331$ ), colloid cyst (10.34%,  $n = 60$ ), lymphocytic thyroiditis (7.93%,  $n = 46$ ), adenomatous goiter/hyperplastic nodule (3.96%,  $n = 23$ ), thyroglossal cyst (3.27%,  $n = 19$ ), Hashimoto thyroiditis (2.59%,  $n = 15$ ), and granulomatous thyroiditis (1.21%,  $n = 7$ )
- Group 3: AUS/atypical follicular lesion of undetermined significance (AFLUS) – Two cases (0.34%) of hyperplastic nodule/FN with papillary hyperplasia, two cases (0.34%) of multinodular goiter/FN and one case of lymphocytic thyroiditis with hurthle cell change were diagnosed in this category
- Group 4: FN/SFN – There were 55 (9.48%) such cases; Out of which 40 cases (6.89%) were cytologically diagnosed as FN, 13 cases (2.24%) as adenomatous goiter, and two cases (0.34%) as hyperplastic nodule
- Group 5: SM – included seven cases; five cases of papillary carcinoma (including a case of follicular variant of papillary carcinoma), one case of FN, and one case of medullary carcinoma/oncocytic neoplasm
- Group 6: Malignant – There were 12 cytologically diagnosed malignancies; eight cases of papillary carcinoma, two cases each of anaplastic carcinoma, and medullary carcinoma.

Out of total 606 cases, histopathology was available in 171 cases. Among 171 patients who underwent surgery, 87.72% (150) were having benign, and 12.28% (21) were having malignant lesion. Figures 1 and 2 show gross and

microscopic photographs of various thyroid lesions. In the present study, most common benign lesion ( $n = 64$ ) on histopathology was goiter including colloid cyst, simple colloid goiter, nodular goiter and multinodular goiter; followed by goiter with secondary change ( $n = 51$ ) and then follicular adenoma ( $n = 12$ ). Out of 21 malignant lesions, ten (48%) were follicular carcinoma being the most common one, followed by six cases of papillary carcinoma (28%), four cases of medullary carcinoma (19%), and one rare case of non-Hodgkin's lymphoma. Table 1 shows cytohistological correlation of thyroid lesions.

Out of 21 histologically proven malignant cases, 18 were malignant on cytology also. There were three such cases which were benign on cytology but turned out to be malignant on histopathology; One case of nodular goiter diagnosed on cytology proved to be follicular carcinoma on histopathology; one case was reported as goiter with cystic degeneration on cytology but diagnosed as papillary carcinoma on histopathology and one case was reported as adenomatous goiter on cytology but proven to be medullary carcinoma on histopathology. False-negative error rate of FNAC was 1.8% in the present study.

Out of 150 histologically proven benign/nonneoplastic cases, 148 were benign/nonneoplastic on cytology also. Two cases were reported as FN on cytology and were diagnosed as multinodular goiter and lymphocytic thyroiditis, respectively, on histopathology; hence, the false-positive error rate of FNAC was 1.2% in the present study. Seven cases of FN were diagnosed as follicular adenoma on

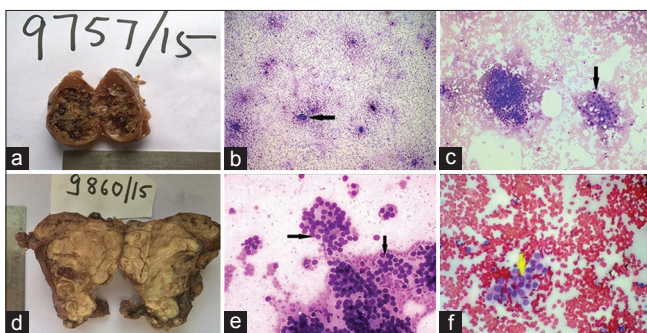


Figure 1: (a) Photograph of colloid goiter with cystic change: Multiple cysts filled with blood clot and colloid-like material with surrounding rim of normal thyroid tissue. (b) Colloid Goiter: Smear showing few groups of follicular epithelial cells (arrow) in a background of abundant colloid (Giemsa,  $\times 40$ ). (c) Hashimoto's Thyroiditis: Smear showing lymphoid cell population along with follicular cells and Hurthle cells (arrow) in a hemorrhagic background (Giemsa,  $\times 100$ ). (d) Photograph of medullary carcinoma of thyroid showing a grayish-white, multinodular mass with well-delineated margins along with normal thyroid tissue at periphery. (e) Follicular neoplasm: Smear showing monolayered sheets of follicular epithelial cells arranged in repetitive follicular pattern (Arrow). (Giemsa,  $\times 400$ ). (f) Papillary carcinoma: Smear showing monolayered clusters of tumor cells showing nuclear inclusions (arrow) (PAP,  $\times 400$ )

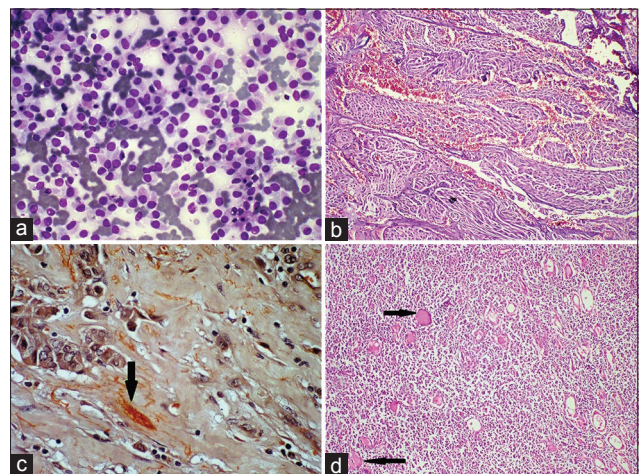


Figure 2: (a) Medullary carcinoma: Smear showing loosely clustered and dissociated round and polygonal tumor cells with eccentric nuclei and well-defined cell margins in a hemorrhagic background. (Giemsa,  $\times 400$ ); (b) Medullary carcinoma: Section showing a tumor arranged in an organoid and Zell ballen pattern, forming sheets and lobules separated by fibrovascular stroma (H and E,  $\times 100$ ); (c) Medullary carcinoma: Section showing amyloid (resembling colloid) stained red; (Congo Red,  $\times 400$ ); (d) Non-Hodgkins lymphoma: Section showing thyroid parenchyma replaced by lymphoid population with remaining few colloid-filled follicles (H and E,  $\times 100$ )

**Table 1: Cytohistopathologic correlation of thyroid lesions**

Histopathology		Bethesda category (n)	Cytology	
Diagnosis	Number of cases		Diagnosis	Number of cases
Thyroglossal cyst	7	Benign (7)	Thyroglossal cyst	7
CG	30	Benign (30)	CG	23
			NG	3
			GCD	4
CC	13	Benign (13)	CC	12
			IC	1
Colloid	51	Benign (50)	CC	8
GCD/secondary change (GCD)			AG	1
			NG	2
			CG	12
			GCD	26
		AUS/AFLUS (1)	HPN	1
AHG	8	Benign (8)	GCD	4
			CG	3
			AG	1
Nodular colloid goiter/NG	17	Benign (17)	AG	1
			NG	4
			CC	1
			CG	8
			GCD	3
MNG	4	Benign (3)	AG	2
			CG	1
		FN/SFN (1)	FN	1
HT	4	Benign (4)	HT	2
			CG	2
LT	4	Benign (3)	LT	2
			GCD	1
		FN/SFN (1)	FN	1
FA	12	Benign (4)	LT	2
			NG	1
			CG	1
		FN/SFN (7)	FN	7
		AUS (1)	HPN	1
FC	10	Benign (1)	NG	1
		FN/SFN (8)	FN	8
		SM (1)	PC	1
PC FC	6	Benign (1)	GCD	1
		SM (1)	PC	1
		Malignant (4)	PC	4
MC	4	Benign (1)	AG	1
		SM (1)	FN	1
		FN/SFN (1)	FN	1
		Malignant (1)	MC	1
NHL	1	Malignant (1)	AC	1

AHG: Adenomatoid hyperplastic goiter; CG: Colloid goiter; MNG: Multi NG; HT: Hashimoto's thyroiditis; LT: Lymphocytic thyroiditis; FA: Follicular adenoma; FC: Follicular carcinoma; PC: Papillary carcinoma; MC: Medullary carcinoma; CC: Colloid cyst; NHL: Non-Hodgkin's lymphoma; AUS: Atypia of undetermined significance; AFLUS: Atypical follicular lesion of undetermined significance; FN: Follicular neoplasm, SFN: Suspicious for FN, SM: Suspicious for malignancy; NG: Nodular goiter; GCD: Goiter with cystic degeneration; HPN: Hyperplastic nodule; AG: Adenomatoid goiter; IC: Infected cystic lesion in thyroid; AC: Anaplastic carcinoma

histology, and eight cases of FN were diagnosed as follicular carcinoma on histology. Since diagnosis of carcinoma needs histopathological evidence of capsular/vascular invasion by

the tumor; hence, this was taken as a positive correlation only. There were two cases of FN which were diagnosed as medullary carcinoma on histopathology.

Table 2 shows malignant risk for each Bethesda category in 171 cases. In the present study, positive predictive value, negative predictive value, false-positive error rate, and false negative error rate of FNAC were 90.0%, 98.0%, 1.2% and 1.8%, respectively, whereas the sensitivity,

specificity, and accuracy of FNAC for the detection of malignancy were 85.7%, 98.6%, and 97.1%, respectively. Table 3 shows comparison of sensitivity, specificity, and accuracy of thyroid FNAC reported in present study with various previous studies.

**Table 2: Malignancy risk for each Bethesda category in 171 cases**

Bethesda category	Histopathologic diagnosis	Cases which turned out to be malignant	Malignancy risk (%)
Benign (n=142)	CG-30	3	2.11
	CC-13		
	Colloid GCD/secondary change-50		
	MNG-3		
	Thyroglossal cyst-7		
	Nodular colloid goiter-17		
	AHG-8		
	HT-4		
	LT-3		
	FA-4		
	FC-1 (false negative)		
	PC-1 (false negative)		
	MC-1 (false negative)		
AUS/AFLUS (n=2)	GCD/HPN-1	0	0
	FN/HPN-1		
FN/SFN (n=18)	FA-7	9	50
	FC-8		
	MC-1		
	LT-1 (false positive)		
	MNG-1 (false positive)		
SM (n=3)	PC-1	3	100
	MC-1		
	FC-1		
Malignant (n=6)	PC-4	6	100
	MC-1		
	NHL-1		
Nondiagnostic	NA	-	-
Total cases (n=171)		21	

AHG: Adenomatoid hyperplastic goiter; CG: Colloid goiter; MNG: Multi NG; HT: Hashimoto's thyroiditis; LT: Lymphocytic thyroiditis; FA: Follicular adenoma; FC: Follicular carcinoma; PC: Papillary carcinoma; MC; Medullary carcinoma; CC: Colloid cyst; NHL: Non-Hodgkin's lymphoma; AUS: Atypia of undetermined significance; AFLUS: Atypical follicular lesion of undetermined significance; FN: Follicular neoplasm, SFN: Suspicious for FN, SM: Suspicious for malignancy; NG: Nodular goiter; GCD: Goiter with cystic degeneration, NA: Not applicable; HPN: Hyperplastic nodule

**Table 3: Comparison of sensitivity, specificity, and accuracy of thyroid fine-needle aspiration cytology reported in various studies**

Author's name	Year of publication	Number of cases	Sensitivity (%)	Specificity (%)	Accuracy (%)
El Hag <i>et al.</i> <sup>[11]</sup>	2003	303	86.7	97.6	-
Sangalli <i>et al.</i> <sup>[12]</sup>	2006	5469	93.4	74.9	95.4
Aravinthan <i>et al.</i> <sup>[13]</sup>	2007	110	80.2	87.2	98.0
Guhamallick <i>et al.</i> <sup>[14]</sup>	2008	288	92.7	98.2	-
Handa <i>et al.</i> <sup>[15]</sup>	2008	434	97	100	-
Mandal <i>et al.</i> <sup>[16]</sup>	2011	120	90	84.6	-
Bamanikar <i>et al.</i> <sup>[17]</sup>	2014	300	50	100	94.2
Present study		606	85.7	98.6	97.1

## Discussion

FNAC is a safe, simple, and inexpensive technique that has emerged as a valuable and popular adjunct in the diagnosis and management of various thyroid lesions. In the present study, cytological features of thyroid lesions were studied according to Bethesda system of reporting and correlated with histopathology, wherever available, to determine its diagnostic accuracy. Male:female ratio was 1:4.2 and majority of the cases were reported in the age group 21–50 years with a mean age of presentation 37.6 years. The findings are comparable to the studies of Handa *et al.*,<sup>[15]</sup> Mandal *et al.*,<sup>[16]</sup> Bamanikar *et al.*,<sup>[17]</sup> and El Hag *et al.*<sup>[11]</sup> It is a well-known fact that thyroid lesions are most commonly seen in middle-aged females.<sup>[18]</sup>

The repeat aspiration was done in 83 cases (13.7%) due to sample inadequacy, poor preparation, cystic lesions, suspected neoplastic lesions, or bigger lumps. The inadequacy of material can be attributed to inexperienced aspiration techniques. The number of needle passes was restricted to <3. Multiple/repeat aspirations led to hemorrhagic smears as thyroid is a highly vascular organ.<sup>[19]</sup> Jayaram and Orell *et al.*<sup>[19]</sup> suggested that the average number of needle passes recommended for adequate sampling of thyroid lumps is two to five. As thyroid gland is a highly vascular organ, with each impending trauma the chances of aspirating hemorrhagic fluid rises each time, so they advised to keep the number of aspirates to minimum. Repeat passes were reported by Mandal *et al.*<sup>[16]</sup> and Mondal *et al.*<sup>[20]</sup> in 5.5% and 6.76% of their cases, respectively. So comparatively, repeat passes were more in the present study.

In the present study, 96% ( $n = 580$ ) cytological smears were satisfactory for evaluation whereas 4% ( $n = 26$ ) were inadequate for interpretation, which is comparable to most of the previous studies and closest to Sangalli *et al.*<sup>[12]</sup> Most of the authors believe that cellularity criteria for adequacy also vary depending on whether the aspirated lesion is solid or cystic and whether aspirate was performed under palpation or ultrasound guidance. All thyroid FNAs must be technically adequate, with well-preserved and well-prepared thyroid follicular epithelial cells for interpretation. Aspirates that contain only cyst fluid and erythrocytes are inadequate.

The present study reported 4.3% aspirates as nondiagnostic or unsatisfactory which correlates with studies of Yassa *et al.*<sup>[21]</sup> and Nayar and Ivanovic,<sup>[22]</sup> who reported 7% and 5% unsatisfactory smears in their studies, respectively, whereas Jo *et al.*<sup>[23]</sup> reported much higher percentage (18.6%) of nondiagnostic/unsatisfactory smears in their study. Usually, an ultrasound-guided FNAC is performed for small nodules or nodules that appear heterogeneous on palpation and cytopathologist himself performs the procedure of FNAC, thereby ensuring a lower percentage of cases in nonsatisfactory category as well as giving a better quality of adequate aspirate.

There was good correlation of incidence of benign thyroid lesions reported in the present study with that of Mondal *et al.*<sup>[20]</sup> The reason of higher number of benign cases is that patients usually come directly to the tertiary care center without any reference. Hence, the present study group is a representative of general population. On the other hand, Jo *et al.* (59%),<sup>[23]</sup> Yassa *et al.* (66%),<sup>[21]</sup> and Nayar and Ivanovic (64%)<sup>[22]</sup> have reported lower incidence of benign thyroid lesions in their studies as compared to the present study.

There were less number of cases (0.8%) diagnosed under category AUS/AFLUS in the present study which could be explained by the strict adherence to diagnostic criteria and the cytopathologist's efforts in our practice setting to avoid ambiguity and keep the use of AUS/AFLUS to a minimum. Mondal *et al.*<sup>[20]</sup> have also reported lower percentage of AUS/AFLUS (1%) in their study because they strictly adhered to diagnostic criteria and they also had large sample size. Jo *et al.*,<sup>[23]</sup> Yassa *et al.*,<sup>[21]</sup> and Nayar and Ivanovic<sup>[22]</sup> have reported 3.4%, 4%, and 8% lesions as AUS/AFLUS in their studies, respectively. Thyroid lesions categorized as "SM" in the present study were 1.9% of total cases. This finding is in concordance with the study of Mondal *et al.*,<sup>[20]</sup> who have reported 1.4% thyroid lesions as SM, while Yassa *et al.*<sup>[21]</sup> have reported much higher number (9%) of cases as suspicious of malignancy in their study. Nayar and Ivanovic<sup>[22]</sup> and Jo *et al.*<sup>[23]</sup> have reported 2% and 2.3% cases, respectively, as SM.

Out of 606 thyroid FNACs over 10 years, 171 cases underwent surgery. By the Bethesda categorization in six categories and corresponding cytohistopathological correlation, the malignancy-risk of each category was obtained in 171 cases as shown in Table 2. On histopathology, 21 out of 171 cases were malignant. Maximum cases (142/171) were from the *benign* category of Bethesda system, with goiter as most common histopathological diagnosis. One case each of follicular, medullary, and papillary carcinoma were diagnosed as benign on cytology making them as false negative with malignancy risk of 2.11%. The AUS/AFLUS category included two cases which were both benign on histopathologic study with 0% malignancy rate. The category of SFN included 18 cases, out of which 9 cases were malignant on histopathology. There were two false-positive cases with cytological diagnosis of FN and histopathological diagnosis as multinodular goiter and lymphocytic thyroiditis respectively, bringing down the malignancy rate to 50% in our study. The category of SM included only three cases both of which were malignant on histopathology with malignancy rate of 100%. The malignant category included six cases which were confirmed as malignant on histopathology in 6 of those cases with malignancy rate of 100%. Out of 171 cases, there was not any single case under nondiagnostic category.

Results of various case series reported by previous authors showed the sensitivity of thyroid cytology ranged widely from 50% to 97%. In the present study, sensitivity of thyroid cytology was 85.7%. On the other hand, specificity of thyroid cytology ranged from 74.9% to 100% in different case series. In the present study, the specificity of thyroid cytology was 98.6% which is comparable to the other studies and closest to reported by Guhamallick *et al.*<sup>[14]</sup> The accuracy of thyroid cytology reported by previous authors ranged from 64.6% to 99%. In the present study, the accuracy of thyroid cytology was 97.1% which is comparable to the other studies and closest to reported by Aravinthan *et al.*<sup>[13]</sup>

The present study showed that Bethesda system of reporting thyroid cytology is standardized initial modality for diagnosing different thyroid lesions. It can detect benign and malignant lesions thus avoid unnecessary surgery for benign thyroid lesions. However, a study over a larger population would provide more information about the merits and demerits of the Bethesda system.

#### Financial support and sponsorship

Nil.

#### Conflicts of interest

There are no conflicts of interest.

#### References

- Gharib H, Papini E, Valcavi R, Baskin HJ, Crescenzi A, Dottorini ME, *et al.* American association of clinical endocrinologists and associazione medici endocrinologi medical guidelines for clinical practice for the diagnosis and management of thyroid nodules. *Endocr Pract* 2006;12:63-102.
- Shah SN, Joshi SR. Goiter and goitrogenesis-some insights. *J Assoc Phys* 2000;48 Suppl 1:13-4.
- Hoffman HW. Diagnostic accuracy of fine needle aspiration biopsy in the diagnosis of thyroid malignancy. *Pathologist* 1986;9:9-14.
- Ashcraft MW, Van Herle AJ. Management of thyroid nodules. II: Scanning techniques, thyroid suppressive therapy, and fine needle aspiration. *Head Neck Surg* 1981;3:297-322.
- Orell SR, Sterrett GF, Walters MN, Whitakar D, editors. In: Manual and Atlas of Fine Needle Aspiration Cytology. 4<sup>th</sup> ed. New Delhi: Churchill-Livingstone; 2005. p. 125-64.
- Ogilvie JB, Piatigorsky EJ, Clark OH. Current status of fine needle aspiration for thyroid nodules. *Adv Surg* 2006;40:223-38.
- Grace MK. Role of fine needle aspiration cytology in the diagnosis of thyroid lesions. *J R Soc Med* 1998;91 Suppl 33:28-32.
- Gulia S, Chaudhury M, Sitaramam E, Reddy K. Diagnostic accuracy of fine needle aspiration cytology in the diagnosis of thyroid lesions. *Internet J Pathol* 2010;13:101-5.
- Pandey P, Dixit A, Mahajan NC. Fine-needle aspiration of the thyroid: A cyto-histologic correlation with critical evaluation of discordant cases. *Thyroid Res Pract* 2012;9:32-9.
- Cibas ES, Ali SZ, NCI Thyroid FNA State of the Science Conference. The Bethesda system for reporting thyroid cytopathology. *Am J Clin Pathol* 2009;132:658-65.
- El Hag IA, Kollur SM, Chiedozi LC. The role of FNA in the initial management of thyroid lesions: 7-year experience in a district general hospital. *Cytopathology* 2003;14:126-30.
- Sangalli G, Serio G, Zampatti C, Bellotti M, Lomuscio G. Fine needle aspiration cytology of the thyroid: A comparison of 5469 cytological and final histological diagnoses. *Cytopathology* 2006;17:245-50.
- Aravinthan T, Banagala AS, Gamage KJ. Use of fine needle aspiration cytology on thyroid lumps. *Galle Med J* 2007;12:25-9.
- Guhamallick M, Sengupta S, Bhattacharya NK, Basu N, Roy S, Ghosh AK, *et al.* Cytodiagnosis of thyroid lesions-usefulness and pitfalls: A study of 288 cases. *J Cytol* 2008;25:6-9.
- Handa U, Garg S, Mohan H, Nagarkar N. Role of fine needle aspiration cytology in diagnosis and management of thyroid lesions; a study of 434 cases. *J Cytol* 2008;25:13-6.
- Mandal S, Barman D, Mukherjee A, Mukherjee D, Saha J, Sinhas R, *et al.* Fine needle aspiration cytology of thyroid nodules – Evaluation of its role in diagnosis and management. *J Indian Med Assoc* 2011;109:258-61.
- Bamanikar S, Soraisham P, Jadhav S, Kumar H, Jadhav P, Bamanikar A. Cyto-histology and clinical correlation of thyroid gland lesions: A 3 year study in a tertiary hospital. *Clin Cancer Investig J* 2014;3:208-12.
- Kumar V, Abbas AK, Fausto N, Aster JC. Robbins and Cotran Pathologic Basis of Disease. 8<sup>th</sup> ed. Philadelphia: Saunders; 2010. p. 1107-26.
- Jayaram G, Orell SR. Thyroid. In: Orell SR, Sterrett GF, editors. *Fine Needle Aspiration Cytology*. 5<sup>th</sup> ed. Gurgaon: Reed Elsevier India Private Limited; 2012. p. 118-55.
- Mondal SK, Sinha S, Basak B, Roy DN, Sinha SK. The Bethesda system for reporting thyroid fine needle aspirates: A cytologic study with histologic follow-up. *J Cytol* 2013;30:94-9.
- Yassa L, Cibas ES, Benson CB, Frates MC, Doubilet PM, Gawande AA, *et al.* Long-term assessment of a multidisciplinary approach to thyroid nodule diagnostic evaluation. *Cancer* 2007;111:508-16.
- Nayar R, Ivanovic M. The indeterminate thyroid fine-needle aspiration: Experience from an academic center using terminology similar to that proposed in the 2007 national cancer institute thyroid fine needle aspiration state of the science conference. *Cancer* 2009;117:195-202.
- Jo VY, Stelow EB, Dustin SM, Hanley KZ. Malignancy risk for fine-needle aspiration of thyroid lesions according to the Bethesda system for reporting thyroid cytopathology. *Am J Clin Pathol* 2010;134:450-6.