



Minimally invasive trans-sacral approach to L5-S1 interbody fusion: Preliminary results from 1 center and review of the literature

W. Daniel Bradley, MD ^{a,*}, Michael S. Hisey, MD ^a, Sunita Verma-Kurvari, PhD ^b,
Donna D. Ohnmeiss, DrMed ^b

^a Texas Back Institute, Denton, TX

^b Texas Back Institute Research Foundation, Plano, TX

Abstract

Background: Lumbar interbody fusion has long been used for the treatment of painful degenerative spinal conditions. The anterior approach is not feasible in some patients, and the posterior approach is associated with a risk of neural complications and possibly muscle injury. A trans-sacral technique was developed that allows access to the L5-S1 disc space. The purposes of this study were to investigate the clinical outcome of trans-sacral interbody fusion in a consecutive series of patients from 1 center and to perform a comprehensive review of the literature on this procedure.

Methods: A literature search using PubMed was performed to identify articles published on trans-sacral axial lumbar interbody fusion (AxiaLIF). Articles reviewed included biomechanical testing, feasibility of the technique, and clinical results. The data from our center were collected retrospectively from charts for the consecutive series, beginning with the first case, of all patients undergoing fusion using the AxiaLIF technique. In most cases, posterior instrumentation was also used. A total of 41 patients with at least 6 months' follow-up were included (mean follow-up, 22.2 months). The primary clinical outcome measures were visual analog scales separately assessing back and leg pain and the Oswestry Disability Index. Radiographic assessment of fusion was also performed.

Results: In the group of 28 patients undergoing single-level AxiaLIF combined with posterior fusion, the visual analog scale scores assessing back and leg pain and mean Oswestry Disability Index scores improved significantly ($P < .01$). In the remaining 13 patients, back pain improved significantly with a trend for improvement in leg pain. Reoperation occurred in 19.5% of patients; in half of these, reoperation was not related to the anterior procedure.

Conclusions: A review of the literature found that the AxiaLIF technique was similar to other fusion techniques with respect to biomechanical properties and produced acceptable clinical outcomes, although results varied among studies.

Clinical relevance: The AxiaLIF approach allows access to the L5-S1 interspace without violating the annulus or longitudinal ligaments and with minimal risk to dorsal neural elements. It may be a viable alternative to other approaches to interbody fusion at the L5-S1 level. It is important that the patients be selected carefully and surgeons are familiar with the presacral anatomy and the surgical approach.

© 2012 ISASS - International Society for the Advancement of Spine Surgery. Published by Elsevier Inc. All rights reserved.

Keywords: Trans-sacral approach; Clinical outcome; Interbody fusion; Lumbar spine; Review

A wide variety of surgical techniques and implants have been developed for lumbar spinal fusion. Interbody fusion can be performed through an anterior, posterior, transforaminal, trans-sacral, or lateral approach. The choice of surgical method depends on the pathology, the patient's history of previous surgery, and the surgeon's training and preferences. Factors considered when determining the approach to

the interbody space are previous surgeries, size of the implant to be placed, and the potential injury to neural and vascular structures, as well as to the musculature. To minimize the potential for muscle damage, minimally invasive techniques may be beneficial.

Axial lumbar interbody fusion (AxiaLIF) is a relatively new approach designed for distraction and fusion of the L5-S1 anterior disc space through a trans-sacral approach, which is minimally invasive and preserves the anterior and posterior longitudinal ligaments. The purposes of this study were to evaluate the results of AxiaLIF in a consecutive series of patients beginning with the first case experience at

* Corresponding author: W. Daniel Bradley, MD, Texas Back Institute, 2817 S Mayhill Rd, Ste 100, Denton, TX 76208; Tel: 940-382-2204; Fax: 940-483-8933.

E-mail address: dbradley@texasback.com

a spine specialty center and to review the literature on this procedure.

Methods

Literature review

A literature search using PubMed was performed to identify articles published on AxiaLIF. Presentations at major spine meetings were also searched for any additional reports. Each study was reviewed and the following data recorded: age, gender, number of patients enrolled, procedure performed, perioperative data, length of follow-up, clinical and radiologic results, complications, and reoperations.

The concept for AxiaLIF (TranS1, Inc., Wilmington, NC) was to gain access to the interbody space at L5-S1 through a minimally invasive approach without disturbing the anterior or posterior longitudinal ligaments, leaving the disc annulus intact. The approach reduces the potential for vascular injury associated with traditional anterior interbody fusion and avoids potential neural injury associated with posterior interbody fusion. The system has a threaded axial rod made from titanium alloy and stainless steel and is designed to use for fusion at the L5-S1 or L4-S1 levels. The implant is available in various lengths and diameters. The primary indications for the procedure are pseudarthrosis, stenosis, low-grade spondylolisthesis, and degenerative disc disease. It is not intended for use in patients with severe scoliosis, tumor, or trauma. The AxiaLIF procedure has been described in detail.^{1–3} In brief, a 2-cm incision extending from the inferior-most aspect of the superficial pubococcygeal ligament to the tip of the coccyx and approximately 5 mm from the midline is made. The lumbosacral disc space is approached through the precoccygeal and presacral region. A guidewire is advanced through the sacrum, disc space, and distal portion of the L5 vertebral body. Sequential dilation through the sacrum is performed. Disc tissue is removed by use of radial disc cutters and tissue extractors. The evacuated disc space is filled with the graft material. A threaded rod is advanced through the disc space and into the lower portion of the L5 vertebral body. The threading of the rod allows variable distraction of the disc space as desired.

A few cadaveric and animal model studies have been performed to investigate the feasibility of the procedure and to determine the safe zone for entry into the presacral space.^{1,3} Post-procedure dissection found that the approach was feasible, and no bowel or soft-tissue injury was identified.

Biomechanical studies with single- and 2-level constructs have been performed.^{4–6} In range-of-motion (ROM) studies, single-level AxiaLIF was shown to be comparable to other fusion types.⁶ In cadaveric studies with single-level constructs, unconstrained ROM was reduced by 40% with a standalone trans-sacral rod,⁴ whereas trans-sacral rod augmentation with a facet or pedicle screw reduced ROM by

between 70% and 90%. In 2-level standalone constructs, ROM decreased by greater than 42% at the L4-5 level and 66% at the L5-S1 level.⁵ The addition of bilateral facet or pedicle screws further reduced the motion. In both studies it was recommended that posterior fixation with pedicle or facet screws be used to reduce the stress at the bone-implant interface and to provide greater stability.

On the basis of the literature review, data from 3 studies were combined for a total of 259 patients undergoing AxiaLIF.^{7–9} In most patients AxiaLIF was used for treatment of degenerative disc disease refractory to conservative treatment. Other diagnoses included pseudarthrosis, herniated disc, stenosis, and spondylolisthesis. The mean age of the patients was 47 years. Single-level AxiaLIF was performed in 95.4% of patients (n = 247) and 2-level AxiaLIF in 4.6% of patients (n = 12). In 81.9% of patients (n = 212) AxiaLIF was supplemented by posterior fusion and pedicle or facet screw instrumentation. Clinical results were reported for 241 patients.^{7,9,10} Improvement in pain across studies was 55.5% to 63.0%, and improvement in Oswestry Disability Index (ODI) scores was 47.6% to 54.0%. In 1 study mean graft subsidence of 1.6 mm was noted at 1 year; however, the clinical results were not affected by it.⁷

The mean follow-up for complications and other results was 25.7 months (range, 10–61 months) (n = 259).^{7–9} Fusion was achieved in more than 91% of patients in all studies, and pseudarthrosis was reported in 7.4% of patients (19 of 258), with 8 patients opting for revision fusion. Reoperations (5.4% [14 of 258]) included 2 cases of irrigation and debridement, 1 AxiaLIF removal with fusion for correction of pseudarthrosis, 7 fusions for correction of pseudarthrosis, 2 sacral fracture repairs, and 2 rectal injury repairs.^{7–9} In case the AxiaLIF rod needs to be removed, the manufacturer recommends that the rod be taken out by the presacral route used to implant it. A transabdominal retroperitoneal approach to access the disc space followed by rod removal and revision anterior lumbar interbody fusion has been described as well.¹¹

Reported complications (3.1% [8 of 259]) included 3 infections that were treated with antibiotics, 1 pseudarthrosis, 1 transient nerve irritation, 1 open wound drainage, and 2 hematomas.^{7–9} The overall complication rate may not be exact because of lack of standardization in reporting complications.

One additional use of AxiaLIF was reported by Anand et al.¹² They have used the technique with extreme lateral interbody fusion and other minimally invasive approaches for the treatment of spinal deformities. They reported good outcomes with this combined approach.

Clinical study

Data from patients undergoing interbody fusion using the trans-sacral approach at our center were analyzed. Most of the cases were performed by 1 surgeon. Clinical, perioperative, and radiographic data were collected for the consecutive series of all patients with the trans-sacral implant

beginning with the first case experience. All patients had disc degeneration, sometimes in combination with less than grade I spondylolisthesis and/or stenosis. Approximately one-third of the patients had prior back surgery. Before being considered for AxiaLIF surgery, the patients must have failed to gain relief after months of nonoperative care, including physical therapy, use of analgesics, and other interventions, such as a home exercise program, chiropractic care, or injections. The study was reviewed by our institutional review board.

A total of 47 patients who had undergone the AxiaLIF procedure were identified. Of these, 6 did not meet the 6-month minimum follow-up criterion. The results of the study are based on data from 41 patients (Table 1). The 45-mm implant was used for the majority of patients followed by 40-, 50-, and 60-mm implants. The most commonly used graft in the interbody procedures was bone morphogenetic protein (BMP) combined with demineralized bone matrix and/or local bone. After completion of the axial interbody procedure, instrumented posterior fusion was performed at the surgeon's discretion through a minimally invasive approach in most patients. Pedicle screws were used in 21 patients and facet screws in 14. The mean follow-up was 22.2 months (range, 6–43 months).

Outcome measures and data analysis

Demographic and perioperative data recorded included age, height, weight, diagnosis, smoking status, gender, prior lumbosacral surgeries, type of posterior instrumentation, operative time, implant size, interbody fusion graft material used, blood loss, length of hospital stay, and complications. The primary clinical outcome measures were visual analog scales (VASs) (0 to 10 scale) separately assessing back and leg pain and the ODI assessing function. If the patient had not recently returned to the clinic for follow-up, data were collected from questionnaires that were mailed to the patients.

Table 1
Overview of patient population and procedures

	Data
Gender	
Male	18 (43.9%)
Female	23 (56.1%)
Mean age (yr)	47.0 (range, 14–68)
Mean BMI	28.6 (range, 18.3–37.7)
Smoker	15 (36.6%)
Prior lumbar surgery	14 (34.1%)
Procedure	
Single-level AxiaLIF + PLF	28 (68.3%) (1 uninstrumented)
Single-level AxiaLIF only	5 (12.2%)
Single-level AxiaLIF + PLF \geq 1 level	3 (7.3%)
2-level AxiaLIF + PLF	4 (9.7%)
AxiaLIF + PLF (L5-S1) + XLIF + PLF (L4-5)	1 (2.4%)
Mean clinical follow-up (mo)	22.2 (range, 6–43)
Mean radiographic follow-up (mo)	16.6 (range, 4–38)

Abbreviation: XLIF, extreme lateral interbody fusion.

Table 2

Perioperative data for primary group (single-level AxiaLIF with PLF) and secondary group (AxiaLIF without PLF and surgeries involving levels other than L5-S1)

	Primary group (n = 28)	Secondary group (n = 13)
Operative time (min)	125.2 (72–212)	157.0 (59–307)
Interbody blood loss (mL)	28.3 (10–100)	30.8 (10–100)
Posterior blood loss (mL)	36.0 (10–150)	116.3 (10–400)
Length of stay (d)	1.6 (0–13*)	1.7 (1–3)

NOTE. Values provided are mean (range).

* Length of stay was extended for patient with rectal tear; otherwise, the mean was 1.2 days, with a range from 0 to 3 days.

For data analysis purposes, the population was divided into 2 subgroups. The primary group comprised the 28 patients who underwent single-level AxiaLIF with posterior lumbar fusion (PLF), which is the most typical AxiaLIF procedure. In almost all of these cases, PLF was performed with a minimally invasive approach. Data for the remaining 13 patients, the secondary group, who underwent AxiaLIF without PLF or whose surgeries involved levels in addition to L5-S1, were analyzed separately.

Outcomes were determined by comparing preoperative and postoperative scores using a paired *t* test. Radiographs were reviewed to assess incorporation of the fusion. Patients were classified as having fusion based on (1) lack of motion at the operated segment on flexion/extension radiographs and (2) bridging bone being noted at the operated levels. All data were analyzed with SPSS software (SPSS, Inc., Chicago, Illinois).

Results

The operative time, blood loss, and hospital stay are presented in Table 2. The mean operative time for the single-level combined AxiaLIF and PLF group was approximately 2 hours. In the primary group, the mean back and leg pain VAS scores improved significantly ($P < .01$) (Fig. 1), with back pain improving by 40.8% and leg pain improving by 50.0%. The mean ODI scores also improved

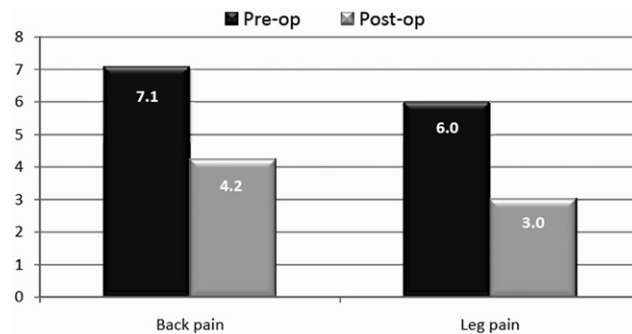


Fig. 1. VAS scores assessing back and leg pain both improved significantly ($P < .01$, paired *t* test).

significantly from 45.5 to 32.6 ($P < .01$). In the secondary subgroup of 13 patients, back pain improved significantly ($P < .05$), from 6.1 to 3.8; there was a trend for leg pain to improve, from 4.6 to 2.7 ($.05 < P < .08$); and the mean ODI score improved from 41.5 to 32.1 ($P > .10$).

The duration of radiographic follow-up (mean, 16.6 months; range, 4–38 months) was shorter than that of the clinical follow-up because some patients who had not recently been seen in the clinic to have radiographs obtained, completed and returned mailed questionnaires. Of the 28 patients in the primary group, 18 had fusion, 2 did not have fusion, 4 had radiographic follow-up of only 4 to 7 months and the fusion was incorporating but was not completely incorporated at that visit, and radiographs could not be located for 4. Among the 13 patients in the secondary group, 8 had fusion, 1 did not have fusion, 3 showed partially incorporated fusion at 8- to 10-month follow-up, and radiographs could not be located for 1.

Reoperations and complications

Eight patients (19.5%) underwent reoperation. Four reoperations (9.7%) were directly related to the AxiaLIF procedure. Two were reoperated on for pseudarthrosis to revise the fusions, leaving the trans-sacral fusion cage in place. One patient had a rectal tear followed by trans-sacral cage removal 2 days after index surgery. The remaining patient underwent incision and debridement for a wound infection. The other reoperations included 2 patients in whom the posterior instrumentation was removed because of pain, 1 patient with posterior instrumentation removal and fusion revision because of pedicle screw migration, and 1 patient who had a spinal cord stimulator implanted for pain control. Complications in the series included 2 patients with dural tears that were repaired intraoperatively without event, 1 patient with an asymptomatic pseudarthrosis, and 1 patient with a fractured posterior fixation screw that was asymptomatic.

Discussion

Spinal fusion is performed to treat a variety of lumbar spinal conditions, which frequently occur at the L5-S1 level. The commonly used anterior and posterior interbody fusion approaches have the potential for injury to the great vessels, ligaments, posterior musculature, or neural structures. The trans-sacral approach is a minimally invasive procedure designed to avoid these problems, as well as leaving the disc annulus intact. The design of the AxiaLIF device provides segmental stiffness across the disc space, and the implanted device is resistant to translation and shear. Indirect decompression can be obtained by distracting the rod construct to the desired height.

The AxiaLIF surgical technique is sufficiently different from other fusion techniques and requires strong knowledge of sacral anatomy. The presacral space is smaller in women than in men, and surgeons must ensure that a suitable

trajectory for correct rod placement is feasible.^{1,3,13} The location of incision in the trans-sacral approach may predispose patients to infection. However, the risk of infection can be reduced by making the incision a little bit smaller and possibly higher above the coccyx.¹ It is important to review axial images and patient history to identify any factors, such as altered rectal-sacral anatomy or history of surgery, that may have produced scar tissue in the path of the operative approach.

In our results improvements in back pain, leg pain, and self-reported function as assessed by the ODI were seen. Although few clinical studies have been published to date reporting the results of AxiaLIF, the clinical outcomes have generally been good with a greater than 91% fusion rate.^{7–9} More than 55% improvement in pain was reported in several studies.^{7,9,10,14} The threaded cage used for the procedure allows distraction of the disc space to the desired height, which may facilitate an increase in the neuroforaminal space, as well as unloading the annular fibers in a previously collapsed disc space. Either of these mechanisms may play a role in reducing leg pain as reported in the AxiaLIF literature and noted in our data.

In trying to put AxiaLIF results in the context of other fusion techniques for single-level fusion, the combined anterior/posterior fusion group that served as a control group in a total disc replacement trial was used.¹⁵ In that study most cases were at L5-S1. Although different versions of the VAS and ODI were used in the studies, the clinical outcomes were similar. In comparing the AxiaLIF results with a study involving minimally invasive transforaminal interbody fusion (TLIF), open TLIF, and combined anterior/posterior fusion, the perioperative data in the AxiaLIF studies were favorable and the reoperation rate was similar to that in the anterior/posterior fusion group but higher than that in either of the TLIF groups.¹⁶ However, determining and comparing complication and reoperation rates in the literature may not be very reliable because classifications of these were not well-defined. For example, it could not be determined whether all studies considered irrigation and debridement, adjacent-segment surgery, or the addition or removal of pedicle screws as reoperations. In our data the reoperation rate was greater than the rates reported in other studies, but it included all additional interventions after the index procedure. Half of the reoperations were not related to the AxiaLIF procedure, and most involved the removal of the posterior instrumentation.

One of the more severe potential complications associated with the trans-sacral approach is bowel injury. This occurred in 1 patient in our series and has been reported in 2 other patients.^{8,17} In 2 of the 3 reported cases of bowel injury, the patient had previously undergone surgery in the same anatomic area (not noted in the remaining reported case). This suggests that great detail of patient history and possibly imaging studies may be helpful in determining whether a patient may be at greater risk for this complication and a change in surgical plan warranted.

The primary limitation of our study is the retrospective study design. Patients with minimum follow-up of 6 months were included in the study, which is shorter than desired. However, a recent analysis of studies involving a variety of spinal implants found that the results do not change significantly after 6 months' follow-up.¹⁸

In summary, published results on AxiaLIF as well as our clinic's results found reduced pain and improved function, although there was variability in the extent of relief reported. The fusion rate reported in the literature was high and could not be addressed adequately in our study because of the length of follow-up. The trans-sacral approach appears to be a feasible alternative to other interbody fusion methods. The complication associated with the approach not commonly found with others is bowel injury. This may be reduced or prevented by evaluating axial imaging of the surgical path and obtaining details of prior surgery from patients. Studies with extended follow-up, as well as radiographic follow-up, will continue to expand our knowledge of this interbody fusion technique.

References

- Cragg A, Carl A, Casteneda F, Dickman C, Guterman L, Oliveira C. New percutaneous access method for minimally invasive anterior lumbosacral surgery. *J Spinal Disord Tech* 2004;17:21–8.
- Marotta N, Cosar M, Pimenta L, Khoo LT. A novel minimally invasive presacral approach and instrumentation technique for anterior L5-S1 intervertebral discectomy and fusion: technical description and case presentations. *Neurosurg Focus* 2006;20:E9.
- Yuan PS, Day TF, Albert TJ, et al. Anatomy of the percutaneous presacral space for a novel fusion technique. *J Spinal Disord Tech* 2006;19:237–41.
- Akesen B, Wu C, Mehbod AA, Transfeldt EE. Biomechanical evaluation of paracoccygeal transsacral fixation. *J Spinal Disord Tech* 2008;21:39–44.
- Erkan S, Wu C, Mehbod AA, Hsu B, Pahl DW, Transfeldt EE. Biomechanical evaluation of a new AxiaLIF technique for two-level lumbar fusion. *Eur Spine J* 2009;18:807–14.
- Ledet EH, Tymeson MP, Salerno S, Carl AL, Cragg A. Biomechanical evaluation of a novel lumbosacral axial fixation device. *J Biomech Eng* 2005;127:929–33.
- Aryan HE, Newman CB, Gold JJ, Acosta FL, Coover C, Ames CP. Percutaneous axial lumbar interbody fusion (AxiaLIF) of the L5-S1 segment: initial clinical and radiographic experience. *Minim Invasive Neurosurg* 2008;51:225–30.
- Lindley EM, McCullough MA, Burger EL, Brown CW, Patel VV. Complications of axial lumbar interbody fusion. *J Neurosurg Spine* 2011;15:273–9.
- Tobler WD, Gerszten PC, Bradley WD, et al. Minimally invasive axial pre-sacral L5-S1 interbody fusion: two year clinical and radiographic outcomes. *Spine* 2011;36:E1296–301.
- Patil SS, Lindley EM, Patel VV, Burger EL. Clinical and radiological outcomes of axial lumbar interbody fusion. *Orthopedics* 2010;33:883.
- DeVine JG, Gloystein D, Singh N. A novel alternative for removal of the AxiaLIF (TranS1) in the setting of pseudarthrosis of L5-S1. *Spine J* 2009;9:910–5.
- Anand N, Baron EM, Thaiyananthan G, Khalsa K, Goldstein TB. Minimally invasive multilevel percutaneous correction and fusion for adult lumbar degenerative scoliosis: a technique and feasibility study. *J Spinal Disord Tech* 2008;21:459–67.
- Oto A, Peynircioglu B, Eryilmaz M, Besim A, Sürücü HS, Celik HH. Determination of the width of the presacral space on magnetic resonance imaging. *Clin Anat* 2004;17:14–6.
- Stippler M, Turka M, Gerszten P. Outcomes after percutaneous TranS1 AxiaLIF® L5-S1 interbody fusion for intractable lower back pain. *Internet J Minimally Invasive Spinal Technology* 2009;3.
- Zigler J, Delamarter R, Spivak JM, et al. Results of the prospective, randomized, multicenter food and drug administration investigational device exemption study of the ProDisc-L total disc replacement versus circumferential fusion for the treatment of 1-level degenerative disc disease. *Spine* 2007;32:1155–62.
- Villavicencio AT, Burneikiene S, Bulsara KR, Thramann JJ. Perioperative complications in transforaminal lumbar interbody fusion versus anterior-posterior reconstruction for lumbar disc degeneration and instability. *J Spinal Disord Tech* 2006;19:92–7.
- Botolin S, Agudelo J, Dwyer A, Patel V, Burger E. High rectal injury during trans-1 axial lumbar interbody fusion L5-S1 fixation: a case report. *Spine* 2010;35:E144–8.
- Ohnmeiss DD, Guyer RD. Twenty-four month follow-up for reporting results of spinal implant studies: is this guideline supported by the literature? *SAS J* 2009;3:100–7.