

# Immune Checkpoint Inhibitor Exposure in Pregnancy: A Scoping Review

Iman Salehi,\* Ludmila Porto,† Christine Elser,‡ Jessica Singh,§ Samuel Saibil,|| and Cynthia Maxwell†

**Summary:** Since their approval, immune checkpoint inhibitors (ICIs) have become the standard of care for multiple malignancies. ICIs enhance tumor destruction by blocking important immunomodulatory pathways that regulate T-cell activation. These pathways include programmed cell death protein-1 and its ligands (programmed cell death protein-1 and programmed death ligand-1, respectively) and cytotoxic T-lymphocyte-associated protein 4. While blocking these pathways can enhance tumor destruction, these pathways are critical for the development of maternal tolerance towards the fetus. Therefore, if ICIs disrupt these immunomodulatory pathways, there could be a maternal immune response against the fetus, as was found in animal studies. With few reported cases of human pregnancy exposure to ICIs, the effects of ICIs on human pregnancy remain largely unknown. Here, we review and summarize the 6 cases of maternal exposure to immunotherapy that have been published before the present study. To add to the evidence, we present a case series of 2 patients who have been exposed to immunotherapy in pregnancy.

**Key Words:** pregnancy, cancer, immunotherapy, radiation

(*J Immunother* 2022;45:231–238)

Since the approval of ipilimumab in 2011, immune checkpoint inhibitors (ICIs) have become the backbone of treatment for a growing number of malignancies. There have been few case reports on ICI exposure during pregnancy.<sup>1–6</sup> A cancer diagnosis in pregnancy is uncommon, complicating 0.02%–0.1% of all pregnancies.<sup>7,8</sup> Breast cancer, hematological malignancies, cervical cancer, and melanoma are among the most diagnosed cancers in pregnancy.<sup>9,10</sup> Despite the relatively low number of cases, the occurrence of several age-dependent malignancies in pregnancy is expected to rise, as decisions to delay childbearing is becoming increasingly common.<sup>8</sup>

Immunotherapy is becoming an increasingly common component of cancer therapy, and the incidence of cancer in pregnancy is on the rise. Therefore, it is of great importance to understand the effect of immunotherapy exposure on maternal and fetal outcomes.

Received for publication June 29, 2021; accepted February 22, 2022. From the \*Mount Sinai Hospital; †Mount Sinai Hospital, University of Toronto; ‡Princess Margaret Cancer Centre, Mount Sinai Hospital, University of Toronto; §Simcoe Muskoka Regional Cancer Program, Royal Victoria Regional Health Centre; and ||Princess Margaret Cancer Centre, Toronto, ON, Canada.

Reprints: Cynthia Maxwell, OPG 3-901, Sinai Health, 700 University Avenue, Toronto, ON, Canada M5G1Z5 (e-mail: cynthiadr.maxwell@sinaihealth.ca).

Copyright © 2022 The Author(s). Published by Wolters Kluwer Health, Inc. This is an open access article distributed under the terms of the Creative Commons Attribution-Non Commercial-No Derivatives License 4.0 (CCBY-NC-ND), where it is permissible to download and share the work provided it is properly cited. The work cannot be changed in any way or used commercially without permission from the journal.

Commonly used ICIs, the immunomodulatory checkpoints they target, and the cancer-specific Food and Drug Administration (FDA) approval of each treatment are shown in Table 1.

## BACKGROUND

Pregnancy entails physiological changes in all maternal systems, including alterations at different levels of the maternal immune system. Since the pregnant person and fetus are genetically discordant, the pregnant person must develop a tolerance to the fetus to allow the coexistence of 2 genetically distinct organisms.<sup>18–20</sup> Programmed cell death protein-1 (PD-1) and its ligands (PD-L1 and PD-L2) and cytotoxic T-lymphocyte-associated protein 4 (CTLA-4) have been linked to the development of maternal tolerance towards the fetus.<sup>21</sup> The existence of these immune checkpoints is essential to induce a maternal immune tolerance to prevent the existence rejection of the semiallogenic fetus by regulating maternal T-lymphocyte activation.<sup>22</sup> Moreover, the available drugs that inhibit these pathways are immunoglobulin (Ig) G4 antibodies, which can traverse the placenta and potentially cause direct teratogenic effects to the fetus.<sup>22</sup> As expected from their ability to regulate undesirable immune responses, the PD-1, and CTLA-4 pathways are expressed at the maternal-fetal interface during pregnancy.<sup>19,20,23</sup> Figures 1A, B, 2A, and B illustrate how these immune checkpoints interact with the immune system and how ICIs might interfere.

## PD-1

PD-1 is a receptor expressed by T cells, B cells, natural killer cells, and antigen-presenting cells (APCs).<sup>24,25</sup> PD-1 generates a strong inhibitory signal when bound to its ligands, PD-L1 and PD-L2, resulting in an inhibition of T-cell activity.<sup>26</sup>

Compared to the peripheral immune system, PD-1 expression is significantly elevated on the surface of decidual CD8<sup>+</sup>, CD4<sup>+</sup>, and regulatory T (Treg) cells.<sup>27</sup> The increased expression of PD-1 on the surface of T cells at the maternal-fetal interface has emerged as a central function in maintaining immune tolerance in pregnancy.<sup>22</sup>

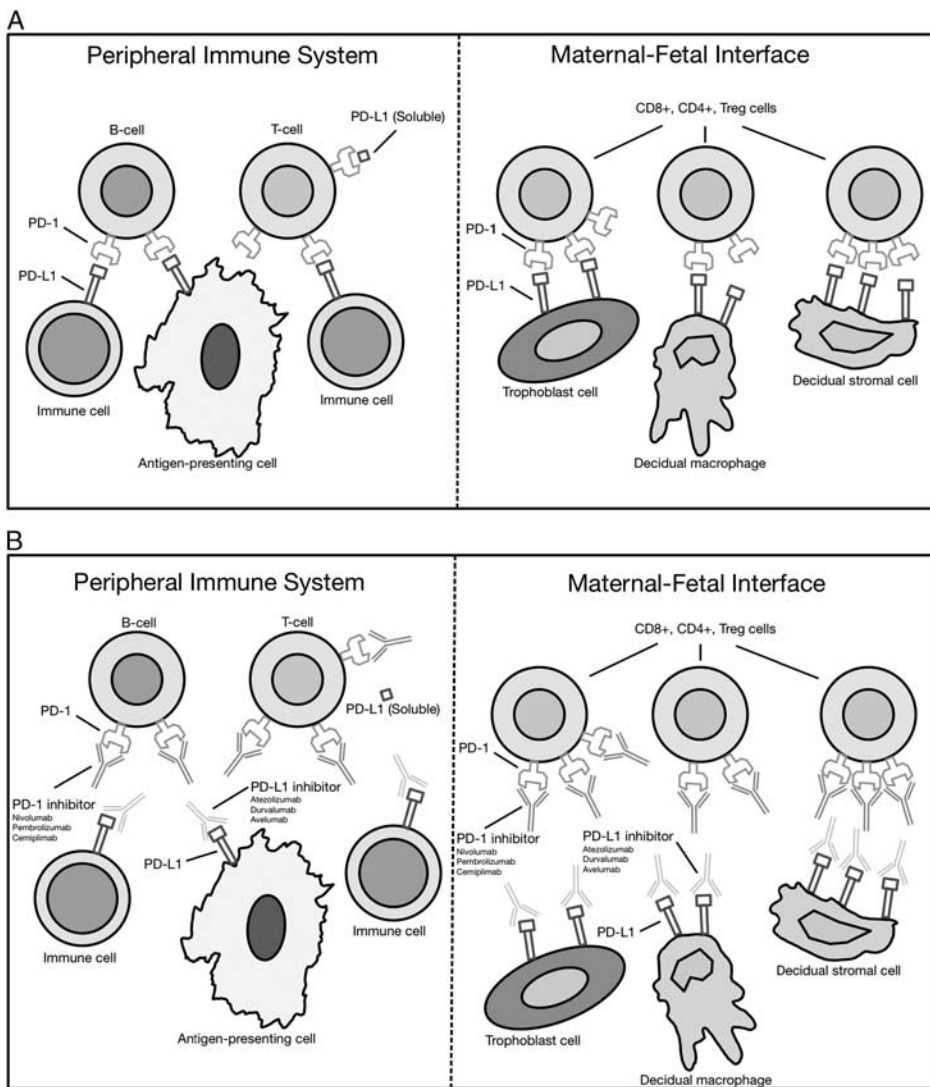
While the immunologic acceptance of the fetus is largely determined by maternal tolerance mechanisms at the maternal-fetal interface, it also has a significant effect on systemic immunity.<sup>28</sup> The frequency of PD-1 expression on the surfaces of T cells and soluble PD-L1 levels in the blood of pregnant patients have been shown to be elevated compared with nonpregnant patients.<sup>29</sup>

The implications of blocking the PD-1 pathway have been shown through studies of murine models of allogeneic pregnancy.<sup>19</sup> Treatment with anti-PD-L1 monoclonal antibodies (mAb) resulted in a 5-fold increase in the rate of spontaneous abortion of allogeneic (CBA×C56BL/6) murine concepti from 18% to 86%. In contrast, no significant

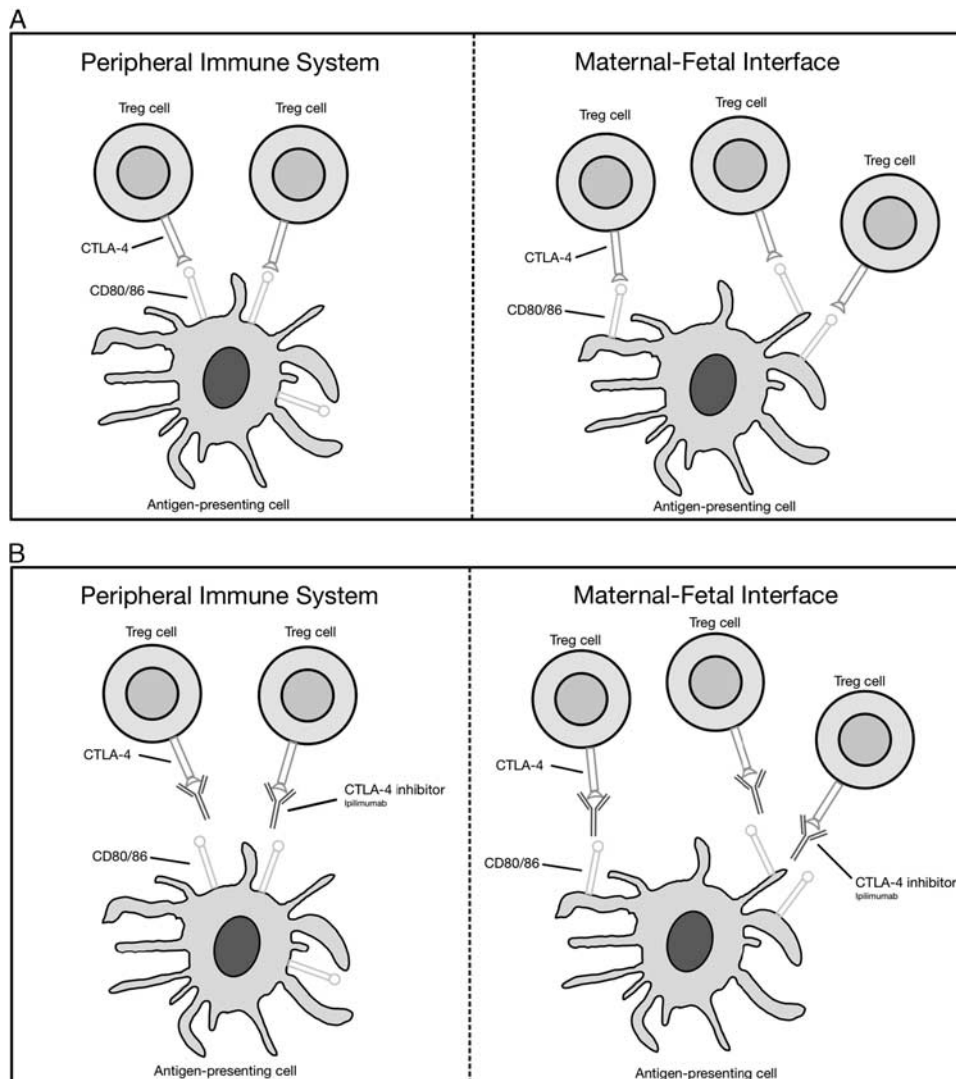
**TABLE 1.** Common Drugs That Inhibit the Activity of Important Immune Checkpoints

Immune Checkpoint	Immune Checkpoint Inhibitor	FDA Approval <sup>11–17</sup>
PD-1	Nivolumab (Opdivo)	Melanoma, NSCLC, RCC, cHL, HNSCC, urothelial carcinoma, CRC, HCC
	Pembrolizumab (Keytruda)	Melanoma, NSCLC, HNSCC, cHL, PMBCL, urothelial carcinoma, CRC, gastric cancer, cervical cancer, HCC, MCC
PD-L1	Cemiplimab (Libtayo)	CSCC
	Atezolizumab (Tecentriq)	Urothelial carcinoma, NSCLC, TNBC
	Durvalumab (Imfinzi)	NSCLC, urothelial carcinoma
	Avelumab (Bavencio)	MCC, urothelial carcinoma
CTLA-4	Ipilimumab (Yervoy)	Melanoma

cHL indicates classic Hodgkin lymphoma; CRC, colorectal cancer; CSCC, cutaneous squamous cell carcinoma; CTLA-4, cytotoxic T-lymphocyte-associated protein 4; FDA, Food and Drug Administration; HCC, hepatocellular carcinoma; HNSCC, head and neck squamous cell cancer; MCC, Merkel cell carcinoma; NSCLC, non-small cell lung cancer; PD-1, programmed cell death-1; PD-L1, programmed cell death ligand-1; PMBCL, primary mediastinal large B-cell lymphoma; RCC, renal cell carcinoma; SCLC, small cell lung cancer; TNBC, triple-negative breast cancer.



**FIGURE 1.** A, An illustration of the PD-1/PD-L1 pathway at baseline, before immune checkpoint inhibitor exposure. If PD-1 is bound to PD-L1, there is no T-cell activation and an immunotolerant effect toward the fetus is observed. B, An illustration of the PD-1/PD-L1 pathway after exposure to immune checkpoint inhibitors. The introduction of an anti-PD-1/PD-L1 monoclonal antibody promotes T-cell activation (enhancing tumor destruction) and possible fetal rejection. PD-1 indicates programmed cell death-1; PD-L1, programmed cell death ligand-1.



**FIGURE 2.** A, An illustration of the CTLA-4 pathway at baseline, before immune checkpoint inhibitor exposure. If CTLA-4 is bound to the B7 ligands, there is no T-cell activation and an immunotolerant effect toward the fetus is observed. B, An illustration of the CTLA-4 pathway after exposure to immune checkpoint inhibitors. The introduction of an anti-CTLA-4 monoclonal antibody promotes T-cell activation (enhancing tumor destruction) and possible fetal rejection. CTLA-4 indicates cytotoxic T-lymphocyte-associated protein 4.

effects were noted upon antimurine PD-L1 mAb exposure in syngeneic (CBA×CBA) concepti. In the same experiment, fetal rejection of allogeneic mice concepti was confirmed to be T cell but not B-cell dependent in 2 ways. First, by using immunohistochemistry of placental sections, it was determined that T-cell infiltration clustered at the fetal resorption site in anti-PD-L1 treated animals with allogeneic pregnancy. Second, treatment with antimurine PD-L1 mAb significantly increased fetal rejection in B-cell-deficient females, but not in female mice who lacked both T cells and B cells.

The effect of blocking PD-L1 was further shown to be dependent on the presence of Treg cells.<sup>22</sup> The enzyme indoleamine 2,3-dioxygenase present on trophoblastic giant cells in mice and on villous and extravillous trophoblasts in humans degrades tryptophan.<sup>22</sup> It has been hypothesized that the deprivation of tryptophan inhibits the proliferation of maternal T cells and drives the generation of Treg

cells.<sup>20,30–32</sup> There is, therefore, an increase in Treg cells during gestation, and they have been shown to have a fundamental role in maternal tolerance to the developing fetus.<sup>33,34</sup>

Habicht et al<sup>35</sup> showed significantly increased fetal resorption in murine models related to the depletion of Treg cells; control mice treated with IgG experienced an 18.8% rate of spontaneous abortion, whereas mice treated with anti-CD25, which is constitutively expressed on Treg cells, experienced a 31.9% rate of a fetal resorption.

Furthermore, Wafula et al<sup>36</sup> found that blocking PD-L1 was dependent on the presence of Treg cells. This experiment showed that PD-1 was a fundamental mediator of Treg-induced fetal protection in a model of abortion-prone murine models (CBA/J×DBA/2J). These abortion-prone mice, lacking Treg cells, were transfused with Treg cells from normal pregnant mice and subsequently experienced normal pregnancy. After restoring normal pregnancy

**TABLE 2.** Reported Cases of Immune Checkpoint Exposure in Pregnancy

	Mehta et al <sup>1</sup>	Burotto et al <sup>2</sup>	Xu et al <sup>4</sup>
Maternal age (y)	34	31	32
Maternal parity	Unknown	Unknown	G0P0
Singleton or twins	Singleton	Singleton	Singleton
Gene status	BRAF V600E mutant	BRAF V600E mutant	BRAF V600E mutant
Cancer type	Metastatic melanoma	Metastatic melanoma	Metastatic melanoma
Site of metastasis	Cutaneous in-transit, subcutaneous, nodal	Breast, nodal, lung, liver, bone	Nodal, lung, liver
Systemic treatment before pregnancy	Vemurafenib	None	Ipilimumab (3 mg/kg)+nivolumab (1 mg/kg) q2w
Systemic treatment at point of conception	Ipilimumab (3 mg/kg q3w) +intralesional IL-2 (aldesleukin)	None	Nivolumab (3 mg/kg) q2w
Systemic treatment given during pregnancy	Ipilimumab (3 mg/kg q3w) and intralesional IL-2 in the first trimester, continued after discovery of pregnancy but ceased before the second trimester	Ipilimumab (3 mg/kg)+nivolumab (1 mg/kg) initiated during the first trimester, ceased in the second trimester due to immune hepatitis	Nivolumab (3 mg/kg) q2w in the first trimester, ceased upon discovery of pregnancy in the first trimester
Maternal iRAE before pregnancy	G1 diarrhea	NA	G3 GGT elevation, G2 rash, hypophysitis bursitis, vitiligo
Maternal iRAE during pregnancy	Nil	Immune hepatitis with G3 bilirubin rise; G3 AST/ALT elevation; G4 GGT elevation	Nil
Immunosuppressive therapy given during pregnancy	Not required	Steroids+azathioprine for immune hepatitis	Not required
Maternal disease response during pregnancy	PD of in-transit and nodal disease	Mixed response with reduction in liver and bone metastases, but progression in breast, lung metastases, and new brain metastases	Sustained CR
Maternal disease response after pregnancy	Further PD despite switch to pembrolizumab	PD to immunotherapy, PR after switch to vemurafenib	Sustained CR at 7 mo postpartum
Delivery date and modality	Unknown	32/40 elective delivery by LUSCS	33/40 spontaneous premature labor, delivery by LUSCS
Obstetric complications	Nil	Placental insufficiency, nonpainful contractions, placental calcifications, and low fetal heart rate	IUGR
Placental melanoma involvement	Unknown	Unknown	No
Fetal melanoma transmission	No	No	No
Fetal iRAE	Nil	Nil	Congenital hypothyroidism
Fetal outcome	Normal development at 2.75 y	Normal development at 11 mo	Normal development at 6 mo
	Menzer et al <sup>3</sup>	Bucheit et al <sup>5</sup>	Haiduk and Ziemer <sup>6</sup>
Maternal age (y)	34	32	39
Maternal parity	Unknown	G3P3	Unknown
Singleton or twins	Singleton	Twins	Twins
Gene status	NRAS Q61 mutant	BRAF V600E mutant	No mutations detected
Cancer type	Metastatic melanoma	Metastatic melanoma	Metastatic melanoma
Site of metastasis	Lung, pleura, nodal, spine, liver, spleen	Nodal, breast, peritoneal space, brain, ovarian	Pulmonary micronodules
Systemic treatment before pregnancy	None	Nodal involvement: CVD+interferon (interferon omitted after 1 cycle); breast involvement: vemurafenib +cobimetinib+atezolizumab	Nivolumab (240 mg) q2w
Systemic treatment at point of conception	None	Ipilimumab (3 mg/kg q3w) +nivolumab (1 mg/kg q3w)	Nivolumab (240 mg) q2w
Systemic treatment given during pregnancy	Ipilimumab (3 mg/kg)+nivolumab (1 mg/kg) q3w initiated during the first trimester, ceased at week 24 +2 after the second cycle	Ipilimumab (3 mg/kg)+nivolumab (1 mg/kg) q3w for 4 cycles, then changed to single-agent nivolumab, ceased 7 d before the cesarean section	Nivolumab (240 mg) q2w, suspended at 6 wk gestation upon discovery of pregnancy
Maternal iRAE before pregnancy	NA	G3 rash; G3 thrombocytopenia (both from vemurafenib exposure)	Elevated liver enzymes
Maternal iRAE during pregnancy	Nil	Nil	Suspected immune hepatitis due to history of elevated liver enzymes
Immunosuppressive therapy given during pregnancy	Not required	Not required	Azathioprine for suspected immune hepatitis (discontinued after discovery of pregnancy)

TABLE 2. (continued)

	Mehta et al <sup>1</sup>	Burotto et al <sup>2</sup>	Xu et al <sup>4</sup>
Maternal disease response during pregnancy	Mother died from underlying disease 1 d after delivery	No progression during pregnancy	No progression after cessation of nivolumab at 6 wk
Maternal disease response after pregnancy	NA	New nodular enhancement in brain; No other sites of metastatic disease	CR at 9 mo postpartum
Delivery date and modality	24+2/40 introduction of lung maturation in the infant, delivery by emergent cesarean section	32/40, course of betamethasone for fetal lung maturity before delivery, delivery by cesarean section	30/40, delivery due to maternal development of HELLP syndrome
Obstetric complications	Nil	IUGR	Hemolysis, elevated liver enzymes, low platelet count (HELLP syndrome)
Placental melanoma involvement	Yes, but only at the maternal site	No	No
Fetal melanoma transmission	No	No	No
Fetal iRAE	Nil	Nil	Nil
Fetal outcome	Other than prematurity-related complications, normal development at 12 mo	Both infants were admitted into NICU where they did well; also did well at home. No long-term report of their development	Smaller twin missing left hand (likely due to amniotic cord strangulation), normal development at 9 mo
	Case Presentation 1		Case Presentation 2
Maternal age (y)	34		33
Maternal parity	G2P2		G0P0
Singleton or twins	Singleton		Singleton
Gene status	No mutations detected		No genetic testing performed
Cancer type	Metastatic melanoma		Renal cell carcinoma
Site of metastasis	Brain, abdominal wall, chest subcutaneous, pelvis subcutaneous, nodal, pulmonary		Pulmonary, left adrenal gland, nodal, spine, retroperitoneum
Systemic treatment before pregnancy	None		Gemcitabine+cisplatin for 3 cycles; nivolumab+ipilimumab
Systemic treatment at point of conception	None		Nivolumab
Systemic treatment given during pregnancy	Ipilimumab (3 mg/kg)+nivolumab (1 mg/kg) for 1 cycle		Nivolumab, suspended at 8 wk gestation upon discovery of pregnancy
Maternal iRAE before pregnancy	NA		Nil
Maternal iRAE during pregnancy	G3 immune hepatitis; elevated (but stable) liver enzymes including G3 AST elevation; G1 ALT elevation; normal bilirubin levels		Nil
Immunosuppressive therapy given during pregnancy	Steroids for elevated liver enzymes		Not required
Maternal disease response during pregnancy	Extensive (but stable) metastatic disease after the dose, including intra-axial progression		Increase in size of retroperitoneal nodule and multilobulated lesion along the left gonadal vessels; spinal metastases remained unchanged
Maternal disease response after pregnancy	Mild improvement in brain metastases; mixed response extracranially		Postnatally, patient resumed immunotherapy with nivolumab
Delivery date and modality	31/40, antenatal steroids were given for fetal lung maturation, delivery by elective cesarean section		38/40, delivery by emergency cesarean section
Obstetric complications	Nil		Arrest of cervical dilation and abnormal fetal heart tracing
Placental melanoma/renal involvement	No		No
Fetal melanoma transmission	No		No
Fetal iRAE	Nil		Nil
Fetal outcome	Infant showed normal development with no signs of metastatic melanoma		Infant showed normal development with no signs of renal metastases

ALT indicates alanine aminotransferase; AST, aspartate aminotransferase; CR, complete response; CVD, cisplatin, vinblastine, dacarbazine; GGT,  $\gamma$ -glutamyltransferase; IL-2, interleukin-2; iRAE, immune-related adverse event; IUGR, intrauterine growth restriction; LUSCS, lower uterine segment cesarean section; NA, not available; NICU, neonatal intensive care unit; PD, progressive disease; PR, partial response; q2w, every 2 weeks; q3w, every 3 weeks.

in CBA/J×DBA/2J mice, treatment with anti-PD-1 mAb abolished the protective effects of Tregs and showed increased abortion rates similar to the abortion-prone mating of CBA/J×DBA/2J mice. This experiment provides compelling evidence that PD-1 has a fundamental role in Treg-mediated fetal protection in murine models.

In the DART study, pregnant cynomolgus monkeys exposed to nivolumab, an anti-PD-1 mAb, experienced a non-dose-related increase in the rate of spontaneous abortion and premature infant death, especially in the third trimester of pregnancy (US FDA, Reference ID: 4421379). No teratogenic effects were observed in monkeys exposed to nivolumab. In the surviving infants exposed to nivolumab in utero, there were no visible malformations and no effects on neurobehavioral, immunologic, or clinical pathology outcomes throughout the 6-month postnatal period.

### CTLA-4

CTLA-4 is an inhibitory receptor that is primarily and constitutively expressed on the cell surface of Treg cells.<sup>37,38</sup> The inhibitory effects of CTLA-4 stem from its competition with CD28 for binding the B7 ligands (CD80/86) found on the cell surface of APCs.<sup>39</sup> CD28 is also a receptor that is constitutively expressed on the cell surface of T cells, and it provides a costimulatory signal for T-cell activation when bound to the B7 ligands on APCs.<sup>21</sup>

Studies have suggested that the primary function of CTLA-4 is not to act as an inhibitory signal when bound to the B7 ligands.<sup>38,40</sup> Instead, these studies suggest that CTLA-4 removes the B7 ligands from the cell surface of APCs, thereby preventing the binding of the B7 ligands to the costimulatory CD28 found on the surface of Treg cells. Therefore, the inhibition of the CTLA-4 checkpoint by anti-CTLA-4 antibodies results in T-cell activation, which is expected to cause adverse effects on pregnancy.

In the DART study, pregnant cynomolgus monkeys exposed to ipilimumab, an anti-CTLA-4 mAb, experienced a dose-related increase in abortion, stillbirths, premature delivery, and higher incidences of infant mortality, beginning in the third trimester. No treatment-related adverse effects were identified with ipilimumab exposure during the first 2 trimesters of pregnancy. In addition, developmental abnormalities of the urogenital system were identified in 2 infant monkeys exposed to 30 mg/kg of ipilimumab. One female infant developed unilateral renal agenesis of the left kidney and ureter, and 1 male infant developed an imperforate urethra with associated urinary obstruction and subcutaneous scrotal edema (US FDA, Reference ID: 4248855).

### Cases of Human Exposure in Pregnancy

There have been no reported cases of humans exposed to ICIs in pregnancy until recently. Upon conducting an extensive literature search, we identified 6 patients exposed to ICIs during pregnancy from 2018 to 2021. These patients were treated for metastatic melanoma with either single-agent or combined immunotherapy. To add to the evidence, we present 2 novel cases of ICI exposure in pregnancy; 1 patient was treated for metastatic melanoma, and another for metastatic renal cell carcinoma. Table 2 summarizes the relevant details of each case report.

## CASE PRESENTATIONS

### Case 1

The patient is a 34-year-old female who presented with a skin lesion along the left thigh in 2017. Biopsy identified malignant

melanoma with 1.48 mm thickness. Wide local excision with sentinel lymph node biopsy was performed the same year, showing no residual lesion at the primary melanoma site and no lymph node involvement (0/5). Genetic testing was performed given a positive family history of malignant melanoma in the patient's mother and grandfather, with negative results. Dermatology follow-up was performed every 6 months. The medical history was otherwise noncontributory. She had 2 uncomplicated pregnancies in 2017 and 2019, which resulted in the vaginal births of healthy infants.

In 2020, a neck lump was noted on clinical assessment. Shortly after, the patient noted other lumps along the breasts and chest wall. Ultrasound identified 7 breast nodules and 5 other lesions in the chest wall. Abdominal ultrasound revealed an intrauterine pregnancy at 13 weeks and 6 days gestational age. Subsequent results of breast node biopsy confirmed metastatic melanoma. Magnetic resonance imaging (MRI) of the brain revealed multiple brain lesions (the largest measuring 1.6 cm), abdominal ultrasound showed lesions in the abdominal wall, and subcutaneous and computed tomography of the chest identified pulmonary metastasis and possible mediastinal nodes.

The treatment plan included stereotactic radiotherapy of the brain and neck and combination immunotherapy with anti-PD-1 and anti-CTLA-4 checkpoint inhibitors. The patient was referred for consultation with Maternal-Fetal Medicine for counseling and ongoing management of the pregnancy. Pregnancy care options were reviewed, including termination of pregnancy, considering the maternal burden of disease and limited data on the safety of most immunotherapy agents. The patient opted to continue the pregnancy. The options of proceeding with maternal imaging and treatment (immunotherapy, radiotherapy) during pregnancy versus proceeding with intentional preterm birth and delayed maternal treatment were presented to the patient. The patient opted to proceed with full maternal treatment during pregnancy with a plan for delivery consideration at or after 32 weeks gestational age. This timing was chosen to reduce complications of extreme prematurity, limit fetal exposure to 1 course of immunotherapy, and allow the patient time to recover from the initiation of treatment.

Gadolinium-enhanced MRI revealed over twelve brain lesions with potential meningeal spread. The radiotherapy approach was then modified to the whole brain and posterior neck with hippocampal sparing and was commenced at 24 weeks gestational age, with a final estimated fetal dose of 3.4 cGy.

Dual immunotherapy with ipilimumab 3 mg/kg and nivolumab 1 mg/kg was commenced at 27 weeks gestational age, and 1 course was given in pregnancy. One week following the dose, head computed tomography showed 9 intra-axial enhancing mass lesions, the largest measuring 1.4 cm. Additional imaging continued to identify extensive metastatic disease, predominantly stable. The clinical course was further complicated by pneumonia and transaminitis (aspartate aminotransferase elevation by 5-fold the reference range), prompting admission for in-patient investigations and management. All workup for obstetrical and secondary causes was negative, and transaminitis was attributed to grade 3 hepatitis in the context of immunotherapy. Liver enzymes remained elevated but stable, with a slow response to steroids. The patient was placed on 2 mg/kg of solumedrol, then upon discharge, was sent home on prednisone at 112.5 mg. Following the patient's discharge from the hospital, the prednisone was tapered gradually. Liver enzymes normalized 4 weeks into prednisone taper, and the patient was rechallenged with nivolumab 6 weeks into the taper. Pneumonia symptoms resolved following a single course of antibiotics.

Serial fetal ultrasound scans showed normal growth and well-being and the absence of signs of placental or fetal metastasis. An elective cesarean delivery by patient request was performed at 31 weeks gestational age. The mode of delivery was based on the deterioration of maternal status and patient preference. Antenatal steroids were given for fetal lung maturation. The patient delivered a female infant weighing 1.69 kg, with Apgar scores of 8 and 9 at 1 and 5 minutes, respectively. The postpartum course was uneventful. The multidisciplinary care team recommended against breastfeeding considering the lack of data regarding the safety of immunotherapy agents and the manufacturers' recommendations

to refrain from breastfeeding 5 and 3 months after the last doses of nivolumab and ipilimumab, respectively. Placental pathology did not show evidence of metastatic disease. The infant was followed by the pediatric oncology team. The abdominal ultrasound of the neonate was normal, with no signs of hepatic mass. A small nevus was identified in the right leg and deemed benign. The infant remained in the neonatal intensive care unit after delivery for a short term because of early delivery but has no concerns related to maternal exposure to immunotherapy during gestation.

## Case 2

A 33-year-old nulliparous female presented with left flank and back pain in 2018, renal calculi, and frank hematuria leading to the diagnosis of high-grade medullary renal cell carcinoma. Surgical treatment included cytoreductive left nephrectomy, splenectomy, distal pancreatectomy, and lymph node dissection, which was complicated by a renal vein thrombosis.

Pulmonary metastases were detected 6 months after the initial diagnosis. The patient was treated with gemcitabine and cisplatin for 3 cycles. Subsequently, the patient developed lumbar pain and spinal compression from lumbar spine metastases. Radiation therapy was administered with a significant improvement in symptoms. Dual immunotherapy with ipilimumab and nivolumab was started.

Two years later, while on monotherapy with nivolumab, the patient had a pelvic ultrasound revealing an intrauterine pregnancy at 8 weeks gestation. Nivolumab was discontinued due to side effects, including dry mouth, swollen, painful gums, and loose teeth. The patient elected to continue the pregnancy and not to restart treatment due to concern with the potential side effects of immunotherapy on the fetus.

The patient underwent enhanced first-trimester screening, which was abnormal with an aneuploidy risk of 1:199. Given advanced reproductive age, the patient wanted further assessment with noninvasive prenatal testing (NIPT), with inconclusive results. Both early and routine fetal anatomic ultrasound scans were normal. The patient developed mild renal insufficiency by the second trimester with a creatinine level of 94 IU/L and worsening back pain. Spinal nonenhanced MRI was performed and showed an increase in the size of a previously identified retroperitoneal nodule at the level of T3 (from 13 mm 6 mo before 32 mm) and an increase in the size of a multilobulated lesion along the left gonadal vessels. Additional findings included postradiation treatment effects on metastases in the lower thoracic and the upper lumbar spine, mostly unchanged from the previous examination. Further imaging was carried out to restage disease and assess organ damage. Abdominal ultrasound showed similar findings described in spinal MRI. Brain MRI was deferred as there were no compatible clinical signs. The pulmonary function test and echocardiogram were normal.

The pregnancy progressed without complication with the exception of mild iron deficiency anemia, which was treated with oral iron supplementation. Creatinine levels decreased and remained normal throughout pregnancy. Serial fetal ultrasounds showed normal growth and well-being. Prophylactic anticoagulation with low-molecular-weight heparin was done throughout pregnancy and up to 6 weeks postpartum. Induction of labor was initiated at 38 weeks gestational age with cervical Foley and oral misoprostol. An emergency cesarean delivery was indicated for the arrest of cervical dilation and abnormal fetal status in labor. A male infant weighing 2980g was delivered with Apgar scores of 4 and 8 at 1 and 5 minutes, respectively. The postpartum course was uneventful, and both the patient and infant were discharged from the hospital after 2 days. Breastfeeding was initiated successfully. Immunotherapy was resumed 1 month postpartum, and breastfeeding was discontinued at that point.

## DISCUSSION

Contrary to what the animal experiments suggest, reports of anti-PD-1/PD-L1 and anti-CTLA-4 mAb exposure (notably nivolumab and ipilimumab) in pregnant patients have primarily resulted in favorable fetal outcomes with no developmental

abnormalities. One exception is a newborn who presented with congenital hypothyroidism, which was thought to have resulted from maternal exposure to anti-PD-1 treatment.<sup>4</sup>

Including our patients, there are 8 reports of patients exposed to ICIs in pregnancy as described in the literature.

Our first case report describes the maternal and fetal outcomes of a woman diagnosed with metastatic melanoma and is the fourth case that describes maternal treatment with dual checkpoint inhibitors (nivolumab and ipilimumab) in pregnancy. While maternal disease response was mixed during pregnancy, the fetus showed normal development at birth. It is interesting to note that, our patient treated for metastatic melanoma is the first to receive treatment with dual checkpoint inhibitors during the third trimester of gestation. It is theoretically possible that the steroids initiated for the treatment of hepatic toxicity shortly after the administration of dual immunotherapy with anti-CTLA-4 and anti-PD-1 could have had a protective effect against the adverse effects on pregnancy. Previous cases reporting fetal outcomes after exposure to dual checkpoint inhibitors in pregnancy have also reported favorable fetal outcomes, with no reported immune-related adverse events in the fetus upon exposure in the first trimester of gestation.<sup>2,3,5</sup>

Our second case report describes the maternal and fetal outcomes of a woman diagnosed with medullary renal cell carcinoma. This case is unique because all the previously identified cases in the literature describe patients diagnosed with metastatic melanoma. Our patient was treated with single-agent nivolumab at conception, which was discontinued upon discovering the pregnancy at 8 weeks gestation. Despite exposure to nivolumab in the first trimester, the patient gave birth to an infant that showed normal development at birth. There have been 3 previous reports of fetal outcomes after exposure to single-agent nivolumab therapy in pregnancy, 2 of which reported no immune-related adverse events in the fetus.<sup>1,6</sup> As mentioned previously, Xu et al<sup>4</sup> reported the development of congenital hypothyroidism. This immune-related adverse event was believed to have resulted from nivolumab exposure in the first trimester of pregnancy.

Both pregnancy and malignancy are risk factors for venous thromboembolism, so both of our patients received prophylactic anticoagulation. Importantly, our second patient (with a diagnosis of renal cell carcinoma) had a history of venous thromboembolism, which further prompted the use of prophylactic anticoagulation.

Our second patient requested NIPT for fetal aneuploidy screening. NIPT showed inconclusive results, presumably because apoptotic tumor DNA was released into maternal circulation and was detected at the time of NIPT.<sup>41</sup> The presence of tumor DNA may have caused discordance with the direct fetal karyotype and interfered with the fetal DNA fraction.

In conclusion, our case reports add to the growing body of evidence that favorable pregnancy outcomes may be achievable despite antenatal exposure to ICIs. Nevertheless, given the lack of data, we recommend that all patients undergoing immunotherapy treatment be counseled about dual contraceptive methods, which should be used both during treatment and for an established period after the cessation of treatment. Furthermore, we emphasize the importance of assembling a multidisciplinary care team, especially given the unique needs of a patient concurrently experiencing pregnancy and malignancy.

## CONFLICTS OF INTEREST/FINANCIAL DISCLOSURES

None reported. All authors have declared that there are no financial conflicts of interest with regard to this work.

## REFERENCES

- Mehta A, Kim KB, et al. Case report of a pregnancy during ipilimumab therapy. *J Glob Oncol*. 2018;4:1–3.
- Burotto M, Gormaz JG, Samtani S, et al. Viable pregnancy in a patient with metastatic melanoma treated with double checkpoint immunotherapy. *Semin Oncol*. 2018;45:164–169.
- Menzer C, Beedgen B, Rom J, et al. Immunotherapy with ipilimumab plus nivolumab in a stage IV melanoma patient during pregnancy. *Eur J Cancer*. 2018;104:239–242.
- Xu W, Moor RJ, Walpole ET, et al. Pregnancy with successful foetal and maternal outcome in a melanoma patient treated with nivolumab in the first trimester: case report and review of the literature. *Melanoma Res*. 2019;29:333–337.
- Bucheit AD, Hardy JT, Szender JB, et al. Conception and viable twin pregnancy in a patient with metastatic melanoma while treated with CTLA-4 and PD-1 checkpoint inhibition. *Melanoma Res*. 2020;30:423–425.
- Haiduk J, Ziemer M. Pregnancy in a patient with metastatic uveal melanoma treated with nivolumab. *J Dtsch Dermatol Ges*. 2021;19:762–765.
- Pereg D, Koren G, Lishner M. Cancer in pregnancy: gaps, challenges and solutions. *Cancer Treat Rev*. 2008;34:302–312.
- Koren G, Carey N, Gagnon R, et al. Cancer chemotherapy and pregnancy. *J Obstet Gynaecol Can*. 2013;35:263–278.
- Calsteren KV, Heyns L, Smet FD, et al. Cancer during pregnancy: an analysis of 215 patients emphasizing the obstetrical and the neonatal outcomes. *J Clin Oncol*. 2010;28:683–689.
- Stensheim H, Møller B, Van Dijk T, et al. Cause-specific survival for women diagnosed with cancer during pregnancy or lactation: a registry-based cohort study. *J Clin Oncol*. 2009;27:45–51.
- US Food and Drug Administration. KEYTRUDA package insert. 2014. Available at: [www.accessdata.fda.gov/drugsatfda\\_docs/label/2019/125514s0401bl.pdf](http://www.accessdata.fda.gov/drugsatfda_docs/label/2019/125514s0401bl.pdf). Accessed June 2021.
- US Food and Drug Administration. LIBTAYO package insert. 2018. Available at: [www.accessdata.fda.gov/drugsatfda\\_docs/label/2018/761097s0001bl.pdf](http://www.accessdata.fda.gov/drugsatfda_docs/label/2018/761097s0001bl.pdf). Accessed June 2021.
- US Food and Drug Administration. OPDIVO package insert. 2014. Available at: [www.accessdata.fda.gov/drugsatfda\\_docs/label/2019/125545s0701bl.pdf](http://www.accessdata.fda.gov/drugsatfda_docs/label/2019/125545s0701bl.pdf). Accessed June 2021.
- US Food and Drug Administration. TECENTRIQ package insert. 2016. Available at: [www.accessdata.fda.gov/drugsatfda\\_docs/label/2019/761034s0181bl.pdf](http://www.accessdata.fda.gov/drugsatfda_docs/label/2019/761034s0181bl.pdf). Accessed June 2021.
- US Food and Drug Administration. IMFINZI package insert. 2017. Available at: [www.accessdata.fda.gov/drugsatfda\\_docs/label/2018/761069s0021bl.pdf](http://www.accessdata.fda.gov/drugsatfda_docs/label/2018/761069s0021bl.pdf). Accessed June 2021.
- US Food and Drug Administration. BAVENCIO package insert. 2017. Available at: [www.accessdata.fda.gov/drugsatfda\\_docs/label/2019/761049s0061bl.pdf](http://www.accessdata.fda.gov/drugsatfda_docs/label/2019/761049s0061bl.pdf). Accessed June 2021.
- US Food and Drug Administration. YERVOY package insert. 2011. Available at: [www.accessdata.fda.gov/drugsatfda\\_docs/label/2018/125377s0941bl.pdf](http://www.accessdata.fda.gov/drugsatfda_docs/label/2018/125377s0941bl.pdf). Accessed June 2021.
- Luppi P. How immune mechanisms are affected by pregnancy. *Vaccine*. 2003;21:3352–3357.
- Guleria I, Khosroshahi A, Ansari MJ, et al. A critical role for the programmed death ligand 1 in fetomaternal tolerance. *J Exp Med*. 2005;202:231–237.
- Guleria I, Sayegh MH. Maternal acceptance of the fetus: true human tolerance. *J Immunol*. 2007;178:3345–3351.
- Miko E, Meggyes M, Doba K, et al. Immune checkpoint molecules in reproductive immunology. *Front Immunol*. 2019;10:846.
- Poulet FM, Wolf JJ, Herzyk DJ, et al. An evaluation of the impact of PD-1 pathway blockade on reproductive safety of therapeutic PD-1 inhibitors. *Birth Defects Res B Dev Reprod Toxicol*. 2016;107:108–119.
- Kaufman KA, Bowen JA, Tsai AF, et al. The CTLA-4 gene is expressed in placental fibroblasts. *Mol Hum Reprod*. 1999;5:84–87.
- Keir ME, Butte MJ, Freeman GJ, et al. PD-1 and its ligand in tolerance and immunity. *Annu Rev Immunol*. 2008;26:677–708.
- Meggyes M, Szanto J, Lajko A, et al. The possible role of CD8<sup>+</sup>/V $\alpha$ 7.2+/CD161<sup>++</sup> T (MAIT) and CD8<sup>+</sup>/V $\alpha$ 7.2+/CD161<sup>lo</sup> T (MAIT-like) cells in the pathogenesis of early-onset pre-eclampsia. *Am J Reprod Immunol*. 2018;79:e12805.
- Chikuma S. Basics of PD-1 in self-tolerance, infection, and cancer immunity. *Int J Clin Oncol*. 2016;21:448–455.
- Taglauer ES, Trikhacheva AS, Sluser JG, et al. Expression and function of PDCD1 at the human maternal-fetal interface. *Biol Reprod*. 2008;79:562–569.
- Borzychowski AM, Croy BA, Chan WL, et al. Changes in systemic type 1 and type 2 immunity in normal pregnancy and pre-eclampsia may be mediated by natural killer cells. *Eur J Immunol*. 2005;35:3054–3063.
- Enninga EAL, Harrington SM, Creedon DJ, et al. Immune checkpoint molecules soluble program death ligand 1 and galectin-9 are increased in pregnancy. *Am J Reprod Immunol*. 2018;79:e12795.
- Baban B, Chandler P, McCool D, et al. Indoleamine 2, 3-dioxygenase expression is restricted to fetal trophoblast giant cells during murine gestation and is maternal genome specific. *J Reprod Immunol*. 2004;61:67–77.
- Chen W, Liang X, Peterson AJ, et al. The indoleamine 2, 3-dioxygenase pathway is essential for human plasmacytoid dendritic cell-induced adaptive T regulatory cell generation. *J Immunol*. 2008;181:5396–5404.
- Mellor AL, Munn DH. IDO expression by dendritic cells: tolerance and tryptophan catabolism. *Nat Rev Immunol*. 2004;4:762–774.
- Aluvihare VR, Kallikourdis M, et al. Regulatory T cells mediate maternal tolerance to the fetus. *Nat Immunol*. 2004;5:266–271.
- Zenclussen AC, Gerlof K, Zenclussen ML, et al. Abnormal T-cell reactivity against paternal antigens in spontaneous abortion: adoptive transfer of pregnancy-induced CD4<sup>+</sup> CD25<sup>+</sup> T regulatory cells prevents fetal rejection in a murine abortion model. *Am J Pathol*. 2005;166:811–822.
- Habicht A, Dada S, Jurewicz M, et al. A link between PDL1 and T regulatory cells in fetomaternal tolerance. *J Immunol*. 2007;179:5211–5219.
- Wafula PO, Teles A, Schumacher A, et al. PD-1 but not CTLA-4 blockade abrogates the protective effect of regulatory T cells in a pregnancy murine model. *Am J Reprod Immunol*. 2009;62:283–292.
- Saito S, Sasaki Y, Sakai M. CD4<sup>+</sup> CD25<sup>high</sup> regulatory T cells in human pregnancy. *J Reprod Immunol*. 2005;65:111–120.
- Walker LS. EFIS Lecture: Understanding the CTLA-4 checkpoint in the maintenance of immune homeostasis. *Immunol Lett*. 2017;184:43–50.
- Chambers CA, Kuhns MS, Egen JG, et al. CTLA-4-mediated inhibition in regulation of T cell responses: mechanisms and manipulation in tumor immunotherapy. *Annu Rev Immunol*. 2001;19:565–594.
- Walker LS, Sansom DM. Confusing signals: recent progress in CTLA-4 biology. *Trends Immunol*. 2015;36:63–70.
- Bianchi DW, Chudova D, Sehnert AJ, et al. Non-invasive prenatal testing and incidental detection of occult maternal malignancies. *JAMA*. 2015;314:162–169.