



Case Report

Gastric balloon: A rare cause of lumbar radiculopathy

Pierre Ferrer¹, Ana Sofía Álvarez², Sara Khalil²

¹Department of Neurosurgery, Gomez Ulla Central Defence Hospital, ²Department of Neurosurgery, Fundación Jiménez Díaz University Hospital, Madrid, Spain.

E-mail: *Pierre Ferrer - ferrer.pomares.p@gmail.com; Ana Sofía Álvarez - ana.aquintana@fdj.es; Sara Khalil - sara.khalil@quironsalud.es



*Corresponding author:

Pierre Ferrer,
Gomez Ulla Central Defence
Hospital, Madrid, Spain.

ferrer.pomares.p@gmail.com

Received : 30 June 2021

Accepted : 17 July 2021

Published : 09 August 2021

DOI

10.25259/SNI_656_2021

Quick Response Code:



ABSTRACT

Background: Factors that are known to cause lumbar epidural venous plexus (EVP) engorgement include inferior vena cava (IVC) obstruction, portal hypertension, vascular agenesis, morbid obesity, and/or hypercoagulable states. Here, we present a 32-year-old female admitted with the new onset of lumbar radiculopathy attributed to a gastric balloon causing compression of the IVC and engorgement of the EVP.

Case Description: A 32-year-old female was admitted with a left L5 radiculopathy. She had a history of morbid obesity and had undergone intragastric balloon insertion 4 months ago. The abdominal/pelvic CT documented an intragastric balloon producing a voluminous gastric mass with resultant compression of the IVC. The lumbar MRI showed the resultant marked multilevel engorgement of the lumbar EVP. Here, following balloon removal, the patient was immediately symptom free and remained asymptomatic over the next postoperative year.

Conclusion: An intragastric balloon can produce a voluminous gastric mass that can result in IVC occlusion and engorgement of the EVP, leading to lumbar radiculopathy. Removal of the balloon results in immediate and permanent resolution of the compressive symptoms.

Keywords: Epidural venous plexus, Gastric balloon, Inferior vena cava compression, Radiculopathy

INTRODUCTION

There are multiple causes of engorgement of the lumbar epidural venous plexus (EVP); including inferior vena cava (IVC) obstruction; portal hypertension, vascular agenesis, morbid obesity, pregnancy, intra-abdominal mass, Budd-Chiari syndrome, or hypercoagulable states.^[1,6]

Gastric balloons should now be added to the list, as they too can lead to marked gastric distention with resultant IVC compression and massive lumbar EVP engorgement resulting in radiculopathy.

CASE DESCRIPTION

A 32-year-old female with morbid obesity had undergone an intragastric balloon insertion 4 months ago. She is now presented with the left L5 distribution leg pain and dysesthesias/paresthesias of 3 months' duration, exacerbated in the supine position. On examination, she had 4/5 weakness involving the left L5/S1 distributions (i.e. extensor hallucis longus/dorsiflexors and plantar flexors).

This is an open-access article distributed under the terms of the Creative Commons Attribution-Non Commercial-Share Alike 4.0 License, which allows others to remix, tweak, and build upon the work non-commercially, as long as the author is credited and the new creations are licensed under the identical terms.

©2021 Published by Scientific Scholar on behalf of Surgical Neurology International

Diagnostic study

The abdominal CT scan and lumbar MRI showed a voluminous gastric mass attributed to the gastric balloon that compressed the IVC [Figures 1-3]. This resulted in massive engorgement of the lumbar EVP (i.e. Batson’s plexus with intracanalicular/foraminal extension).

Following urgent removal of the balloon, the patient was asymptomatic and remained symptoms free 1 year later.

DISCUSSION

Anatomy of Batson’s plexus

A gastric balloon resulting in marked gastric distention can produce IVC obstruction that can trigger engorgement of the EVP, causing root compression and radiculopathy. This is largely attributed to the fact that Batson’s EVP is a valveless network connected to the IVC, pelvic veins, and azygos system through multiple intersegmental branches traversing the intervertebral foramina adjacent to the spinal nerve roots.^[2,6]

Engorgement of the IVC results in Sciatica

IVC compression (caused by hypercoagulable states, vascular thrombosis, obesity, vascular agenesis, malignant intra-abdominal mass, or pregnancy) or thrombosed epidural varices can compress spinal nerve roots resulting in radiculopathy [Table 1].^[1-9] However, only rarely does IVC

obstruction result in engorgement of the EVP leading to symptoms/signs mimicking a lumbar disc herniation and/or spinal stenosis. In Paksoy and Gormus out of 9640 patients, the MRI showed that only 13 (0.13%) patients had epidural engorged veins due to IVC obstruction or occlusion leading to sciatica/radiculopathy.^[6,8]

Here, we reported a clear case of IVC obstruction leading to significant engorgement of the lumbar EVP resulting in neurological radiculopathy.

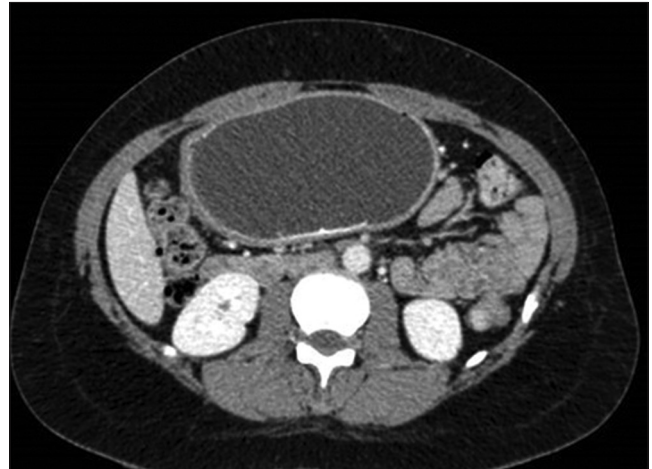


Figure 1: Axial CT scan shows large intra-abdominal mass corresponding to a gastric balloon compressing the inferior vena cava.

Table 1: Cases that exemplify different causes of engorgement of the EVP.

Cases	Gender	Age (years)	Symptoms	Cause of the engorgement of the EVP
Bozkurt <i>et al.</i> ^[1]	Female	27	Low back pain.	Budd-Chiari syndrome.
Bursali <i>et al.</i> ^[2]	Male	26	Low back pain. Radiculopathy.	Thrombosed epidural varix.
Dudeck <i>et al.</i> ^[3]	Male	26	Low back pain. Radiculopathy.	Agenesis of the infrarenal segment of the IVC.
Gormus <i>et al.</i> ^[4]	Female	20	Low back pain.	Pregnancy. IVC thrombosis.
Hallan <i>et al.</i> ^[5]	Female	50	Radiculopathy.	Systemic lupus erythematosus. Antiphospholipid syndrome.
	Female	60	Low back pain. Radiculopathy.	Klippel-Trenaunay syndrome.
Jeong <i>et al.</i> ^[6]	Male	15	Low back pain. Radiculopathy.	Obesity.
Lee <i>et al.</i> ^[7]	Female	72	Low back pain. Radiculopathy.	Epidural venous thrombolith.
Paksoy and Gormus ^[8]	13 cases	20–53 (mean of 30).	Low back pain. Radiculopathy.	10 cases present IVC thrombosis. 2 cases present pregnancy. 1 case of intra-abdominal mass (tumor).
Wong <i>et al.</i> ^[9]	Male	47	Radiculopathy. Urinary retention.	IVC thrombosis.

EVP: Epidural venous plexus, IVC: Inferior vena cava

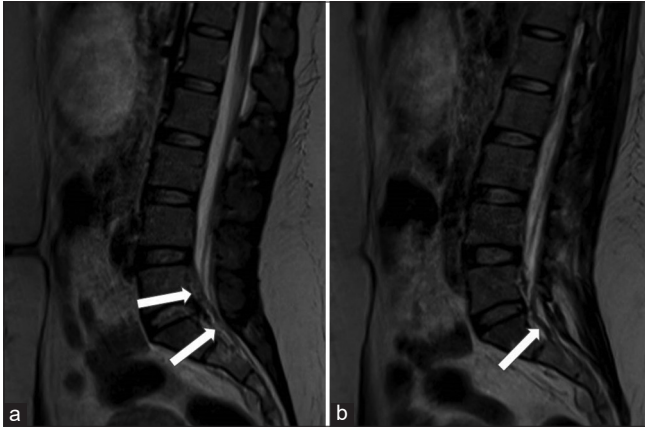


Figure 2: T2-weighted sagittal MRI (a and b) shows enlarged lumbar epidural plexus (white arrows).

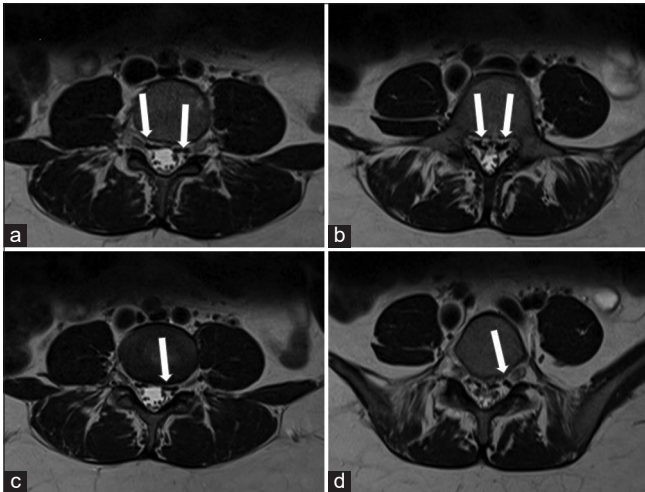


Figure 3: T2-weighted axial MRI (a-d) shows enlarged lumbar epidural plexus (white arrows) compressing the nerves roots through the foramina.

CONCLUSION

Here, we have described a unique iatrogenic complication of gastric balloon placement resulting in compression of the IVC and engorgement of the lumbar EVP responsible for lumbar radiculopathy.

Declaration of patient consent

Patient's consent not required as patients identity is not disclosed or compromised.

Financial support and sponsorship

Nil.

Conflicts of interest

There are no conflicts of interest.

REFERENCES

1. Bozkurt G, Cil B, Akbay A, Türk CC, Palaoglu S. Intractable radicular and low back pain secondary inferior vena cava stenosis associated with Budd-Chiari syndrome: Endovascular treatment with cava stenting: Case report and review of the literature. *Spine (Phila Pa 1976)* 2006;31:E383-6.
2. Bursalı A, Akyoldas G, Guvenal AB, Yaman O. Lumbar epidural varix mimicking disc herniation. *J Korean Neurosurg Soc* 2016;59:410-3.
3. Dudeck O, Zeile M, Poellinger A, Kluhs L, Ludwig WD, Hamm B. Epidural venous enlargements presenting with intractable lower back pain and sciatica in a patient with absence of the infrarenal inferior vena cava and bilateral deep venous thrombosis. *Spine (Phila Pa 1976)* 2007;32:E688-91.
4. Gormus N, Ustun ME, Paksoy Y, Ogun TC, Solak H. Acute thrombosis of inferior vena cava in a pregnant woman presenting with sciatica: A case report. *Ann Vasc Surg* 2005;19:120-2.
5. Hallan DR, McNutt S, Reiter GT, Thamburaj K, Specht CS, Knaub M. Dilated epidural venous plexus causing radiculopathy: A report of 2 cases and review of the literature. *World Neurosurg* 2020;144:231-7.
6. Jeong HJ, Sim WS, Park HJ, Lee SH, Oh MS, Cho MK, *et al.* Severe lumbar radiculopathy with epidural venous plexus engorgement in a morbidly obese pediatric patient: A case report. *Medicine (Baltimore)* 2019;98:e16842.
7. Lee YS, Choi ES, Kim JO, Ji JH. A rare calcified thrombosis of the dilated epidural venous plexus presenting with lumbar radiculopathy: A case report. *Spine J* 2011;11:e28-31.
8. Paksoy Y, Gormus N. Epidural venous plexus enlargements presenting with radiculopathy and back pain in patients with inferior vena cava obstruction or occlusion. *Spine (Phila Pa 1976)* 2004;29:2419-24.
9. Wong TW, Gridley DG, Feiz-Erfan I. Epidural venous plexus engorgement due to inferior vena cava thrombosis resulting in cauda equina syndrome: Case report and literature review. *Surg Neurol Int* 2018;9:129.

How to cite this article: Ferrer P, Álvarez AS, Khalil S. Gastric balloon: A rare cause of lumbar radiculopathy. *Surg Neurol Int* 2021;12:398.