


# 1% Tirbanibulin Ointment for the Treatment of Actinic Keratoses

Diem-Phuong D. Dao, BS<sup>1</sup>, Vikram Nath Sahni, BS<sup>2</sup>,  
Dev Ram Sahni, MD, MHA<sup>3</sup> , Esther A. Balogh, MD<sup>4</sup>,  
Ayman Grada, MD, MHA<sup>5</sup>, and Steven R. Feldman, MD, PhD<sup>4,6</sup>

Annals of Pharmacotherapy  
2022, Vol. 56(4) 494–500  
© The Author(s) 2021



Article reuse guidelines:  
sagepub.com/journals-permissions  
DOI: 10.1177/10600280211031329  
journals.sagepub.com/home/aop



## Abstract

**Objective:** Actinic keratoses (AKs) are cutaneous lesions that arise in sun-damaged skin. AKs may transform into squamous cell carcinoma in situ. Tirbanibulin 1% ointment is a new topical treatment for AKs, recently approved by the Food and Drug Administration. **Data Sources:** The PubMed database was searched for articles published from 1960 to March 31, 2021, using the keywords *tirbanibulin* and *Klisyri*. **Data Extraction:** Phase 2 and phase 3 clinical trials were reviewed. **Data Synthesis:** In phase 2 clinical trials, 43% of patients treated with tirbanibulin experienced complete clearance by day 57 (43% [95% CI = 32, 54]). Across two phase 3 clinical trials (pooled data), complete (100%) clearance occurred in 49% of patients in tirbanibulin groups and in only 9% of the vehicle groups (difference, 41% points; 95% CI = 35 to 47;  $P < 0.001$ ). Although no comparative studies are available, tirbanibulin is applied for a shorter duration (5 days) compared with diclofenac 3% gel, fluorouracil 5% cream, and imiquimod 3.75% cream. Adverse events were mild and included pruritus, application site pain, and local skin reactions. Systemic adverse events such as necrosis and angioedema, observed with other AK treatments such as fluorouracil and imiquimod, were not observed with tirbanibulin, thus giving tirbanibulin a favorable safety profile. **Relevance to Patient Care and Clinical Practice:** Tirbanibulin effectively reduces AK burden and recurrence and has a favorable safety profile with mild adverse events. In comparison, imiquimod, 5-fluorouracil, and diclofenac can result in necrosis, angioedema, and arthralgias. **Conclusion:** With a favorable safety profile and short regimen, tirbanibulin is an efficacious treatment for clinicians to utilize in their treatment toolbox when treating AKs on the face and scalp.

## Keywords

actinic keratoses, diclofenac, 5-fluorouracil, imiquimod, Klisyri, tirbanibulin, treatment

## Introduction

Actinic keratoses (AKs) are common precancerous cutaneous lesions that typically present on sun-exposed or ultraviolet damaged areas with gritty, scaly, and erythematous papules.<sup>1,2</sup> Histopathologically, they are identified through irregular hyperchromatic nuclei, epidermal keratinocyte crowding, and dysplastic keratinocytes.<sup>2,3</sup> AKs may progress to squamous cell carcinoma in situ (SCCs).<sup>4</sup> This progression is difficult to predict, and it is widely accepted that all forms of AKs should be treated in order to prevent progression to SCCs.<sup>1</sup>

AKs currently affect about 58 million individuals in the United States and have a predilection for elderly males and/or fair skinned individuals.<sup>1</sup> Both individual and environmental factors affect the pathogenesis of AKs. Important risk factors include male sex, older age, past history of cutaneous neoplasms, UV exposure, and Fitzpatrick phototypes I-III. Prolonged UV exposure is considered a major risk factor for AK development because of resultant modification

of cellular repair mechanisms.<sup>5</sup> AKs are protean morphologically and can occur as atrophic, pigmented, lichenoid, cheilitic, and hyperkeratotic forms. Recognition of these different subtypes alters management strategy because of preferential response of some AK subtypes to specific therapy.<sup>5</sup>

<sup>1</sup>Virginia Commonwealth University, School of Medicine, Richmond, VA, USA

<sup>2</sup>Drexel University, College of Medicine, Philadelphia, PA, USA

<sup>3</sup>University of Utah Health, Department of Dermatology, Salt Lake City, UT, USA

<sup>4</sup>Wake Forest School of Medicine, Department of Dermatology, Winston-Salem, NC, USA

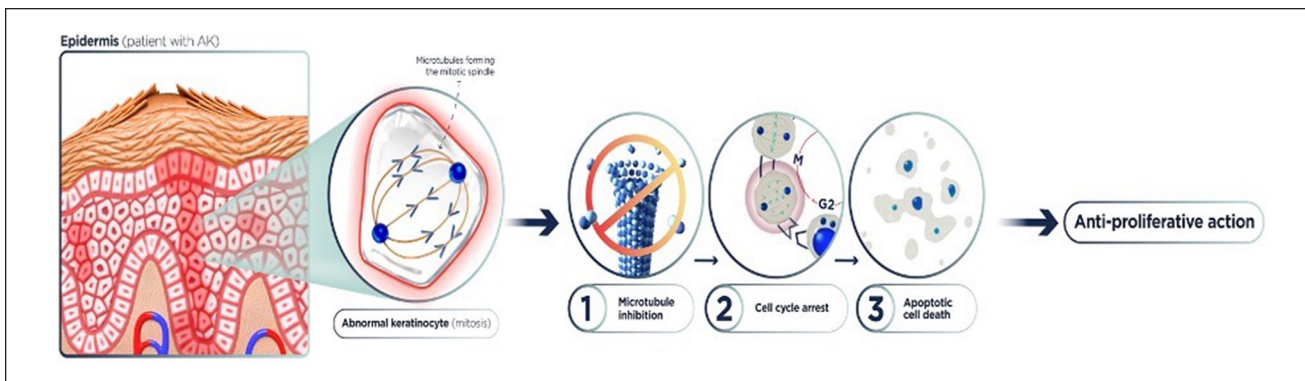
<sup>5</sup>R&D and Medical Affairs, Ammiral US, Exton, PA, USA

<sup>6</sup>University of Southern Denmark, Odense, Denmark

## Corresponding Author:

Dev Ram Sahni, Department of Dermatology, 30 N 1900 East, 4A330 SOM, Salt Lake City, UT 84132, USA.

Email: sahnidr@alumni.vcu.edu



**Figure 1.** Mechanism of action of tirbanibulin. Abbreviation: AK, actinic keratosis.

**Table 1.** PubMed Search Results Using the Keyword *Tirbanibulin*.

Article	Author
Phase 3 trials of tirbanibulin ointment for actinic keratosis	Blauvelt et al <sup>11</sup>
Actinic keratosis: where do we stand and where is the future going to take us?	Cramer and Stockfleth <sup>3</sup>
Tirbanibulin ointment 1% as a novel treatment for actinic keratosis: phase 1 and 2 results	Kempers et al <sup>11</sup>
Reversible binding of the anticancer drug KXOI (tirbanibulin) to the colchicine-binding site of $\beta$ -tubulin explains KCOI's low clinical toxicity	Lu et al <sup>9</sup>
Tirbanibulin <sup>a</sup>	No authors listed

<sup>a</sup> Denotes article not used.

Currently, several modalities exist for treatment of AKs and are driven by patient preference, provider familiarity, and clinical risk factors. Field cancerization treatment has the lowest rate of recurrence, whereas sole cryotherapy is often inefficacious at preventing recurrence.<sup>5</sup> Field-directed therapies are used for a conglomerate of lesions, large surface areas, and subclinical lesions. Lesion-directed or targeted therapy is preferred with localized and small disease burdens.<sup>1</sup> Surgical or destructive therapies for AKs include excision, dermabrasion, curettage or electrodesiccation, cryotherapy, photodynamic therapy, and laser resurfacing. Often, a combination of modalities will be utilized for treatment of AKs. Field-directed therapies can be utilized as single or adjunct therapy for AKs.

Field-directed therapies include tirbanibulin ointment, ingenol mebutate gel, diclofenac gel, imiquimod cream, and 5-fluorouracil cream.<sup>2,5</sup> Ingenol mebutate has been discontinued in the European, Canadian, and US markets because of its association with increased risk of nonmelanoma skin cancer (NMSC).<sup>6</sup> Diclofenac gel, imiquimod, ingenol mebutate, and 5-fluorouracil have similar efficacies in treating AKs.<sup>7</sup> Whereas treatment of AKs is prefaced on destruction of underlying precancerous cells, preventive measures can be utilized and include topical retinoids, chemical peels, and photoprotection.<sup>5</sup> Although current clinical treatments are effective biologically, adverse cutaneous events and recurrence rates can limit real-world adherence.<sup>1</sup>

Topical tirbanibulin ointment is a first-in-class antiproliferative agent for treatment of AKs. Tirbanibulin works by inhibiting tubulin polymerization and disrupting Src kinase signaling, 2 pathways often upregulated in AK and SCC (Figure 1). As of December 14, 2020, the US Food and Drug Administration (FDA) approved tirbanibulin for treatment of AKs on the face or scalp. This review will analyze the pharmacology, clinical trials, safety, and efficacy of tirbanibulin to treat AKs on the face or scalp.

## Methods

The PubMed database was reviewed for articles from 1960 to March 31, 2021, using the following keywords: tirbanibulin and Klisyri. The term *tirbanibulin* yielded 5 results, whereas the term *Klisyri* yielded 1 result (Table 1). FDA.gov was additionally searched for information on tirbanibulin drug trials and labels.

## Results

### Drug Pharmacology

Tirbanibulin is a topical ointment for use on the face and/or scalp containing 1% tirbanibulin by weight. Inactive ingredients include monoglycerides, diglycerides, and propylene glycol.<sup>8</sup> One packet of ointment (250 mg) contains 2.5 mg

**Table 2.** Efficacy and Adverse Events From All Tirbanibulin Clinical Trials.

Clinical trial phase	Efficacy	Adverse events (AEs)
Phase 1 <sup>1</sup>	By day 45, 25% of patients in cohort 1, 0% of patients in cohort 2, 50% of patients in cohort 3, and 12.5% of patients in cohort 4 experienced 100% clearance of AK lesions	There were no treatment-emergent AEs, serious AEs, or deaths. AEs consisted mostly of mild pruritus, stinging sensations, and burning sensations at the application site. Other reactions included erythema, flaking, and scaling
Phase 2 <sup>1</sup>	The 5-day cohort had a higher percentage of complete clearance (43% [95% CI = 32, 54]) when compared with the 3-day cohort (32% [95% CI = 22, 43]). Partial clearance was observed in higher rates in the 5-day cohort (56% [95% CI = 45, 67]) than in the 3-day cohort (52% [95% CI = 41, 63])	There were no serious AEs or deaths. AEs consisted of mild pruritus and pain at the application site, which was transient. Mild dizziness and headaches were reported less frequently. Other reactions included erythema, flaking, crusting, swelling, scaling, vesiculation or pustulation, and ulcerations or erosions
Phase 3 <sup>11</sup>	Tirbanibulin exhibited higher complete clearance levels (44% in trial 1 and 54% in trial 2) than control ointment clearance levels (5% in trial 1 and 13% in trial 2), with $P < 0.001$ for both trials; 68% and 76% ( $P < 0.001$ ) of patients achieved partial clearance ( $\geq 75\%$ reduction in the number of lesions) in trials 1 and 2 when compared with the control group	There were no serious AEs. AEs consisted of local skin reactions, with pain and pruritus at the site being the most common. Other reactions included erythema, flaking, crusting, swelling, scaling, vesiculation or pustulation, and ulcerations or erosions

(1%) of tirbanibulin. The medication is applied on the affected area of the face or scalp once a day for 5 days in a row. Each packet will cover up to 25 cm<sup>2</sup> on the face or scalp and is disposed of after its one-time use.<sup>8</sup>

**Mechanism of Action.** The chemical name of tirbanibulin is *N*-benzyl-2-(5-(4-(2-morpholinoethoxy)phenyl)pyridine-2-yl) acetamide. Tirbanibulin is a microtubule inhibitor.<sup>8</sup> Tirbanibulin additionally disrupts the proto-oncogenic Src tyrosine kinase signaling pathway as a non-ATP-competitive inhibitor.<sup>9</sup> Promotion of the G2/M arrest of growing cell populations, upregulating p53, and inducing apoptosis via caspase-3 stimulation and poly (ADP-ribose) polymerase cleavage also occur with tirbanibulin.<sup>1</sup>

**Pharmacokinetics.** The steady-state concentration of tirbanibulin was achieved in 72 hours with a mean  $\pm$  SD trough concentration of 0.11  $\pm$  0.08 ng/mL following application of an average daily dose of 138 mg for 5 consecutive days over a 25 cm<sup>2</sup> area of the face/scalp.<sup>8</sup> Systemic exposure to tirbanibulin was minimal, with a maximum day 5 plasma concentration ( $C_{\max}$ ) of 0.34  $\pm$  0.30 ng/mL and 0.18  $\pm$  0.10 ng/mL, and a mean under the plasma concentration from time  $t=0$  to  $t=24$  hours of 5.0  $\pm$  3.9 h ng/mL and 3.2  $\pm$  1.9 h ng/mL for individuals who received the face and scalp treatment, respectively. The median time ( $T_{\max}$ ) to reach  $C_{\max}$  was approximately 7 hours.<sup>8</sup>

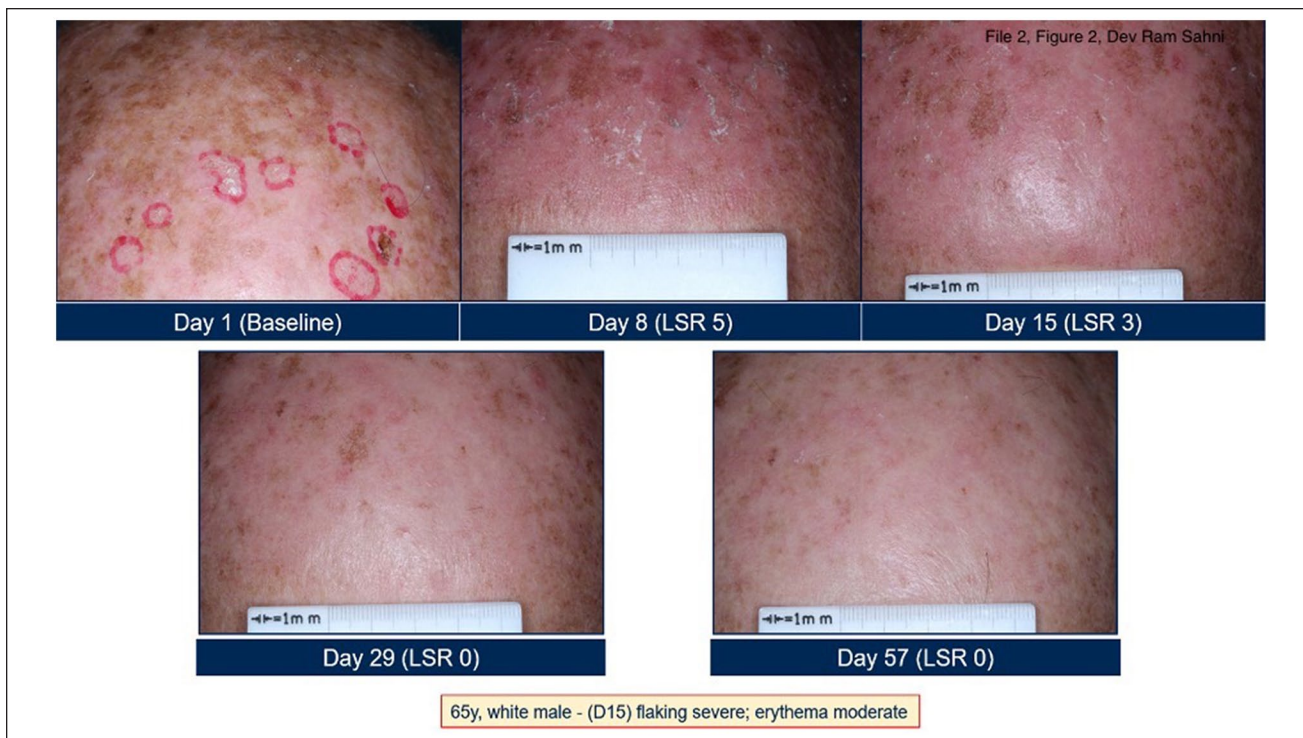Tirbanibulin contains a plasma protein binding of 88%, and binding is consistent from 0.01 to 10  $\mu$ g/mL. CYP3A4 and to a lesser extent, CYP2C8, metabolizes tirbanibulin in vitro, however, excretion of tirbanibulin has not been fully studied in humans. Tirbanibulin has no clinically meaningful effect on the pharmacokinetics of drugs metabolized by CYP 1A2, 2B6, 2C8, 2C9, 2C19, 2D6, or 3A4.<sup>8</sup>

### Summary of Phase 2 Clinical Trials for 1% Tirbanibulin Ointment

An uncontrolled, open-label, multicenter, dose regimen finding study (NCT02838628) was conducted in adults  $\geq 18$  years old with AKs on the face or scalp.<sup>1</sup> A total of 168 individuals were separated into 2 cohorts of 84 participants from 16 sites across the United States. No participant withdrew from the study. Cohorts were separated into 3- versus 5-day treatment durations. The majority of patients in this trial were  $>60$  years of age and Caucasian with Fitzpatrick skin types I to III.<sup>1</sup> Participants received 1% tirbanibulin ointment once daily for 3 or 5 days over a 25-cm<sup>2</sup> treatment area. These areas contained 4 to 8 AK lesions. On day 57, a response assessment was performed, and a recurrence follow-up period was conducted up to 12 months after the 57th day to observe patients who had 100% or complete clearance of AKs.<sup>1</sup>

On days 8, 15, 29, and 57, AK lesions were assessed and compared to day 1 baseline status. Complete response rates and CIs were calculated based on the number of patients who achieved complete clearance by day 57. Overall clearance of AKs on the face or scalp was significant in both cohorts. The 5-day cohort had a higher percentage of complete clearance (43% [95% CI = 32, 54]) when compared with the 3-day cohort (32% [95% CI = 22, 43]) and a sustained response at 12 months (43% for the 5-day cohort) compared with the 3-day cohort (30%; Table 2). With recurrence rates of 57% (95% CI = 41, 73) 12 months after day 57, the 5-day cohort was more successful than the 3-day cohort, with recurrence rates of 70% (95% CI = 51, 87). Furthermore, partial clearance was observed in higher rates in the 5-day cohort (56% [95% CI = 45, 67]) than in the 3-day cohort (52% [95% CI = 41, 63]; Table 2).<sup>1</sup>





**Figure 2.** Clinical clearance at days 1, 8, 15, 29, and 57 with use of tirbanibulin for actinic keratoses on the scalp.

Treatment-emergent adverse events (TEAEs) were used to assess safety as well as laboratory evaluation of hematology, urine analysis, and blood chemistry. Local skin reactions (LSRs) were graded on a 5-point scale as follows: 0, not present; 1, minimal; 2, mild; 3, moderate; or 4, severe. These reactions were assessed by viewing signs of LSRs and are mentioned in the adverse events section. Both the 3-day and 5-day dosing schedules were well tolerated in the cohorts. There were no discontinuations, deaths, or serious adverse events. However, grade 1/2 or minimal/mild LSRs were often observed, with grade 3 or moderate LSRs less frequently noted (Table 2).<sup>1</sup>

In this trial, a 5-day dosing regimen of 1% tirbanibulin ointment was more clinically efficacious than a 3-day dosing regimen. However, 1% tirbanibulin ointment was efficacious at reducing all AK lesions regardless of dosing regimen while having a favorable safety profile.

### Summary of Phase 3 Clinical Trials for 1% Tirbanibulin Ointment

Two double-blinded, multicenter, randomized, placebo-controlled, parallel-group, phase 3 trials—trial 1 (NCT0328547) and trial 2 (NCT03285490)—were conducted on 702 adult patients with AKs on the face or scalp at 62 sites across the United States. Inclusion criteria for participants were AKs on the scalp or face with 4 to 8 visible and discrete lesions in

a contiguous area of 25 cm<sup>2</sup>. In all, 68% of AK patients had lesions on the face and 32% of AK patients had lesions on the scalp. The average age of patients was 70 years, with a range of 45 to 96 years.<sup>8,10,11</sup>

Patients received a 5-day consecutive regimen of either tirbanibulin or the control ointment. They were assessed on day 57 for number of lesions. Patients treated with tirbanibulin experienced higher complete (100%) clearance levels (44% in trial 1 and 54% in trial 2) than those treated with control ointment (5% trial 1 and 13% trial 2;  $P < 0.001$  for both trials; Table 2, Figure 2).<sup>11</sup> In addition, 68% and 76% ( $P < 0.001$ ) of patients achieved partial clearance ( $\geq 75\%$  reduction in the number of lesions) in trials 1 and 2 when compared with the control group. Across 2 phase 3 clinical trials (pooled data), complete clearance occurred in 49% of patients in the tirbanibulin groups and in 9% of the vehicle groups (difference, 41% points; 95% CI = 35 to 47;  $P < 0.001$ ). Partial clearance occurred in 72% of patients in the tirbanibulin groups and in 18% of the vehicle groups (difference, 54% points; 95% CI = 48 to 60;  $P < 0.001$ ). In 47% of patients with complete clearance, lesions recurred at 1 year (Table 2).<sup>11</sup>

The median percentage reduction in lesion count as compared with baseline was 83% in the tirbanibulin group and 20% in the vehicle group in trial 1, and 100% (tirbanibulin) and 25% (vehicle) in trial 2. The pooled median percentage reduction in the AK lesion count on day 57 was greater with

tirbanibulin (87.5%) than with the vehicle (20%).<sup>12</sup> The median percentage reduction is a valuable metric because it is independent of the baseline number of lesions.<sup>11</sup>

The majority of participants in the clinical trials were Caucasian (99%) men (87%) with Fitzpatrick skin types I or II (72%); therefore, differences in treatment outcomes among race and sex could not be clearly determined.<sup>8,10</sup> However, patients younger than 65 years of age and older than 65 years of age experienced similar outcomes when using tirbanibulin.<sup>10</sup>

In all, 16% of patients using tirbanibulin experienced adverse reactions compared with 10% of patients using the control ointment. Pruritis and pain at the application site were the most common adverse reactions. LSRs occurred independently of adverse effects and included erythema, swelling, flaking, crusting, scaling, vesiculation or pustulation, and erosions or ulcerations (Table 2). These LSRs were graded as follows: 0, not present; 1, mild; 2, moderate; and 3, severe.<sup>8</sup> Severe LSRs were observed in <10% of patients.

None of the tirbanibulin-treated patients discontinued treatment for treatment-related adverse events out of 353 patients across 2 trials.<sup>11</sup>

**Adverse Events.** The most common adverse effects of tirbanibulin are pruritus and pain at the application site and LSRs.<sup>10</sup> LSR included erythema, swelling, crusting, flaking, scaling, vesiculation, pustulation, erosion, and ulceration. Tirbanibulin should not be used until the skin is fully healed from any surgeries, procedures, or previous drug reactions. Furthermore, tirbanibulin may cause ocular irritation.

The AK treatment population may include women of childbearing potential and lactating women. There has been no data on possible birth defects and/or adverse fetal/maternal outcomes during pregnancy with the use of tirbanibulin. Fetal deaths and skeletal, visceral, and external malformations were observed in pregnant rats at a dose of  $\geq 1.25$  mg/kg/d, which is 74 times the exposure of the maximum recommended human dose (MRHD). In rabbits, mean fetal weight and size were reduced at an exposure 159 times the MRHD. The possibility of lactational transfer of tirbanibulin through human or animal milk has not been investigated.<sup>8</sup>

Oral administration of tirbanibulin at 4 mg/kg/d negatively affects spermatogenesis in male rats, with decreased motility and sperm counts.<sup>8</sup> No effects on sperm were observed in male rats treated at 2 mg/kg/d (47 times the MRHD on an area under the curve comparison basis).

Tirbanibulin did not cause contact sensitization (261 individuals), phototoxic skin reactions (31 individuals), or photoallergic skin reactions (64 individuals) in clinical studies with healthy individuals.<sup>8</sup> There are no contraindications listed in the FDA-approved prescribing information.

## Discussion

Tirbanibulin ointment 1% is an FDA-approved 5-day treatment regimen for AKs on the face and scalp. Tirbanibulin is the first-in-class agent that inhibits tubular polymerization and inhibits the Src tyrosine kinase pathway as a non-ATP-competitive inhibitor, among several other effects.<sup>1,9</sup> Microtubule inhibition induces apoptosis in rapidly dividing cells with resultant cell death.<sup>13</sup> Following phase 3 clinical trials with a short treatment duration, tirbanibulin effectively and completely (100%) cleared AK lesions while demonstrating a favorable safety profile. Common cutaneous adverse events included pruritus, pain at the application site, and LSRs. In phase 3 clinical trials, a 5-day consecutive regimen of tirbanibulin was more effective than the control ointment in clearance and recurrence of AKs at 57 days and 12 months, respectively.<sup>11</sup>

Early and effective treatment of AKs is important to prevent progression to SCCis. However, several therapies require lengthy treatment duration, and the resulting severe cutaneous reactions may limit patient tolerability and medication adherence. Topical therapies with simpler and shorter treatment regimens have higher patient satisfaction and better adherence and improve overall quality of life.<sup>6</sup> Tirbanibulin may be an effective medication to circumvent these issues because patients do not have to apply tirbanibulin for prolonged periods of time, and observed LSRs are mostly mild.<sup>14</sup>

Tirbanibulin is currently approved for topical use only. Patients are advised to avoid applying tirbanibulin near the eyes, mouth, and lips. Tirbanibulin produces adverse ophthalmic reactions, and therefore, patients must be careful not to transfer the drug into the periocular area or eyes. Currently, tirbanibulin is only approved for treatment of AKs on the face and scalp. More data is needed on efficacy and tolerability for other photo-exposed regions.

## Relevance to Patient Care and Clinical Practice

As a topical ointment with a relatively short duration of use compared to other typical AK treatments, tirbanibulin has significant clinical potential (Table 3). Current topical treatments used for AKs, including fluorouracil and imiquimod, can cause severe LSRs (necrosis), prolonged patient discomfort, and systemic effects, which limit their real-world effectiveness.<sup>15</sup> Furthermore, diclofenac, fluorouracil, and imiquimod require a long duration of application from weeks to months.<sup>16-18</sup> Tirbanibulin is, therefore, favorable because of duration of treatment, safety profile, and ease of use. The one-time-use packets for a duration of 5 consecutive days may facilitate patient adherence and accountability. In addition, patient compliance rates may increase because the adverse events of tirbanibulin are relatively mild compared with those of other treatments for AKs (Table 3).

**Table 3.** Summary of Existing FDA-Approved Topical Treatment Modalities for Actinic Keratoses on the Face or Scalp.

Agent	Dose, route, duration	Mechanism of action	Adverse events	Efficacy	Contraindications
Diclofenac 3% gel (Solaraze) <sup>1,2,16,17,19</sup>	Topical BID 0.5 g on affected area (maximum 25 cm <sup>2</sup> ) for 60-90 days	Blocks cyclo-oxygenase activity and inhibition of UV-induced proinflammatory cytokines	Blistering, contact dermatitis, edema, erythema, inflammation, irritation, necrosis, and pruritus	47% of patients experienced complete clearance of lesions	Patients with diclofenac, polyethylene glycol monomethyl ether 350, benzyl alcohol, and/or hyaluronate sodium hypersensitivity
Fluorouracil 5% cream (Efudex) <sup>2,16-18,20</sup>	Topical BID on affected area (maximum area usage of 500 cm <sup>2</sup> ) for 2-4 weeks	Inhibits thymidylate synthase and 5-fluorouracil incorporation into RNA and DNA	Burning, dryness, edema, erosion, erythema, necrosis, pain, pruritus, and ulceration	Overall 80% reduction in lesions, 50% of patients experienced complete clearance of lesions	Pregnant women, patients with dihydropyrimidine dehydrogenase enzyme deficiency, and/or hypersensitivity to any components of cream
Imiquimod 3.75% cream (Aldara) <sup>1,2,16-18,21</sup>	Topical QD 25 g maximum on affected area (maximum area usage of 25 cm <sup>2</sup> ) for two 2-week cycles with a 2-week rest period in between	Agonist for toll-like receptor 7; enhances immune response by stimulating cytokines	Angioedema, arthralgia, crusting, dryness, erosion, erythema, fatigue, inflammation, myalgia, nausea, necrosis, and scabbing	34% of patients experienced complete clearance of lesions, and 54% of patients experienced partial clearance of lesions	None
Tirbanibulin 1% ointment (Klisyri) <sup>8,10</sup>	Topical QD 2.5 mg (maximum area use of 25 cm <sup>2</sup> ) for 5 consecutive days	Inhibits microtubule polymerization and disrupts Src tyrosine kinase signaling pathway	LSRs were mostly mild to moderate: erythema, scaling, crusting, flaking, erosion, ulceration, pain, and pruritus	83% to 100% median percentage reduction of lesions; 44%-54% of patients experienced complete clearance of lesions	None

Abbreviations: FDA, Food and Drug Administration; LSR, local skin reaction; QD, daily.

### Conclusion

AKs are common cutaneous skin lesions. Lesion and field-directed therapies are used to treat AKs to halt progression to SCCs. Currently, existing topical treatments for AKs are often limited because of patient tolerability, treatment duration, and adherence. The FDA-approved (2020) tirbanibulin 1% ointment is a promising option to manage visible AKs and address underlying field cancerization. Patient-reported outcomes in real-world settings will provide additional insights into the effectiveness of topical field therapies for AKs.

### Declaration of Conflicting Interests

The authors declared the following potential conflicts of interest with respect to the research, authorship, and/or publication of this article: Dr Steven Feldman has received research, speaking, and/or consulting support from a variety of companies, including Galderma, GSK/Stiefel, Almirall, Leo Pharma, Boehringer Ingelheim, Mylan, Celgene, Pfizer, Valeant, Abbvie, Samsung, Janssen, Lilly, Menlo, Merck, Novartis, Regeneron, Sanofi, Novan, Quriert, National Biological Corporation, Caremark, Advance Medical, Sun Pharma, Suncare Research, Informa, UpToDate, and

National Psoriasis Foundation. He is founder and majority owner of www.DrScore.com and founder and part owner of Causa Research, a company dedicated to enhancing patients' adherence to treatment. Dr Ayman Grada is the Head of R&D and Medical Affairs at Almirall, US. Dr Dev Sahni, Ms Diem-Phuong Dao, Mr Vikram Sahni, and Dr Esther Balogh have no conflicts to disclose.

### Funding

The authors received no financial support for the research, authorship, and/or publication of this article.

### ORCID iD

Dev Ram Sahni  <https://orcid.org/0000-0002-0979-9774>

### References

1. Kempers S, Dubois J, Forman S, et al. Tirbanibulin ointment 1% as a novel treatment for actinic keratosis: phase 1 and 2 results. *J Drugs Dermatol.* 2020;19:1093-1100. doi:10.36849/jdd.2020.5576
2. Fleming P, Zhou S, Bobotsis R, Lynde C. Comparison of the treatment guidelines for actinic keratosis: a critical appraisal and review. *J Cutan Med Surg.* 2017;21:408-417. doi:10.1177/1203475417708166

3. Cramer P, Stockfleth E. Actinic keratosis: where do we stand and where is the future going to take us? *Expert Opin Emerg Drugs*. 2020;25:49-58. doi:10.1080/14728214.2020.1730810
4. Reynolds KA, Schlessinger DI, Vasic J, et al. Core outcome set for actinic keratosis clinical trials. *JAMA Dermatol*. 2020;156:326-333. doi:10.1001/jamadermatol.2019.4212
5. Reinehr CPH, Bakos RM. Actinic keratoses: review of clinical, dermoscopic, and therapeutic aspects. *An Bras Dermatol*. 2019;94:637-657. doi:10.1016/j.abd.2019.10.004
6. Grada A, Feldman SR, Bragazzi NL, Damiani G. Patient-reported outcomes of topical therapies in actinic keratosis: a systematic review. *Dermatol Ther*. 2021;34:e14833. doi:10.1111/dth.14833
7. Dirschka T, Gupta G, Micali G, et al. Real-world approach to actinic keratosis management: practical treatment algorithm for office-based dermatology. *J Dermatol Treat*. 2017;28:431-442. doi:10.1080/09546634.2016.1254328
8. Klisyri ointment. Package insert. Almirall, LLC. Accessed February 2, 2021. [https://www.accessdata.fda.gov/drugsatfda\\_docs/label/2020/213189s000lbl.pdf](https://www.accessdata.fda.gov/drugsatfda_docs/label/2020/213189s000lbl.pdf)
9. Lu N, Yang J, Yan W, et al. Reversible binding of the anticancer drug KXO1 (tirbanibulin) to the colchicine-binding site of  $\beta$ -tubulin explains KXO1's low clinical toxicity. *J Biol Chem*. 2019;294:18099-18108. doi:10.1074/jbc.RA119.010732
10. US Food and Drug Administration. Drug trials snapshot: KLISYRI. Accessed June 26, 2021. <https://www.fda.gov/drugs/drug-approvals-and-databases/drug-trials-snapshot-klisyri>
11. Blauvelt A, Kempers S, Lain E, et al. Phase 3 trials of tirbanibulin ointment for actinic keratosis. *N Engl J Med*. 2021;384:512-520. doi:10.1056/nejmoa2024040
12. Blauvelt A, Kempers S, Schlesinger T, et al. Tirbanibulin ointment 1% for actinic keratosis (AK): pooled data from two phase 3 studies. *J Cutan Med*. 2020;4:s121. doi:10.25251/skin.4.suppl.121
13. Haanen C, Vermes I. Apoptosis and inflammation. *Mediators Inflamm*. 1995;4:5-15. doi:10.1155/s0962935195000020
14. Lebwohl M. Actinic keratosis. *JAMA*. 2016;315:1394-1395. doi:10.1001/jama.2016.3065
15. Emmerich VK, Cull D, Kelly KA, Feldman SR. Patient assessment of 5-fluorouracil and imiquimod for the treatment of actinic keratoses: a retrospective study of real-world effectiveness. *J Dermatolog Treat*. Published online May 5, 2021. doi:10.1080/09546634.2021.1917758
16. Dianzani C, Conforti C, Giuffrida R, et al. Current therapies for actinic keratosis. *Int J Dermatol*. 2020;59:677-684. doi:10.1111/ijd.14767
17. Chaplin S. Topical agents for preventing and treating actinic keratosis. *Prescriber*. 2016;27:32-40. doi:10.1002/psb.145
18. McIntyre W, Downs M, Bedwell S. Treatment options for actinic keratosis. *Am Fam Physician*. 2007;76:667-671.
19. Solaraze gel. Package insert. Almirall Hermal GmbH. Accessed March 12, 2021. [https://www.accessdata.fda.gov/drugsatfda\\_docs/label/2011/021005s013lbl.pdf](https://www.accessdata.fda.gov/drugsatfda_docs/label/2011/021005s013lbl.pdf)
20. Efudex. Package insert. Valeant Pharmaceuticals. Accessed March 12, 2021. [https://www.accessdata.fda.gov/drugsatfda\\_docs/label/2005/016831s049lbl.pdf](https://www.accessdata.fda.gov/drugsatfda_docs/label/2005/016831s049lbl.pdf)
21. Aldara cream, 5%. Prescribing information. 3M Health Care Limited. Accessed March 12, 2021. [https://www.accessdata.fda.gov/drugsatfda\\_docs/label/2010/020723s022lbl.pdf](https://www.accessdata.fda.gov/drugsatfda_docs/label/2010/020723s022lbl.pdf)