

# Case report: Mounier-Kuhn syndrome

Satish Kachhawa, ML Meena, Gaurav Jindal, Bharat Jain  
Department of Radiodiagnosis, Sardar Patel Medical College, Bikaner, India

**Correspondence:** Dr. Gaurav Jindal, Room Number 8, PG Hostel, Sardar Patel Medical College, Bikaner, India.  
E-mail: gauravjindal11@hotmail.com

## Abstract

Tracheobronchomegaly or Mounier-Kuhn syndrome is a rare disorder characterized by marked dilatation of the trachea and main bronchi, bronchiectasis, and recurrent respiratory tract infections. The etiology of this disorder is uncertain and the clinical presentation is variable. The diagnosis is usually made on the basis of the characteristic CT scan findings. We report a case in a 21-year-old man presenting with recurrent lower respiratory tract infections.

**Key words:** Mounier-Kuhn syndrome; tracheobronchomegaly; congenital

Mounier-Kuhn syndrome or tracheobronchomegaly is a rare clinical and radiological entity characterized by marked dilatation of the trachea and bronchi and recurrent lower respiratory tract infections. Diagnosis is usually made on CT scan. The condition is known by a number of different names, e.g., trachiectasis, tracheobronchopathia malacia, tracheomegaly, and multiple tracheal diverticula.

## Case Report

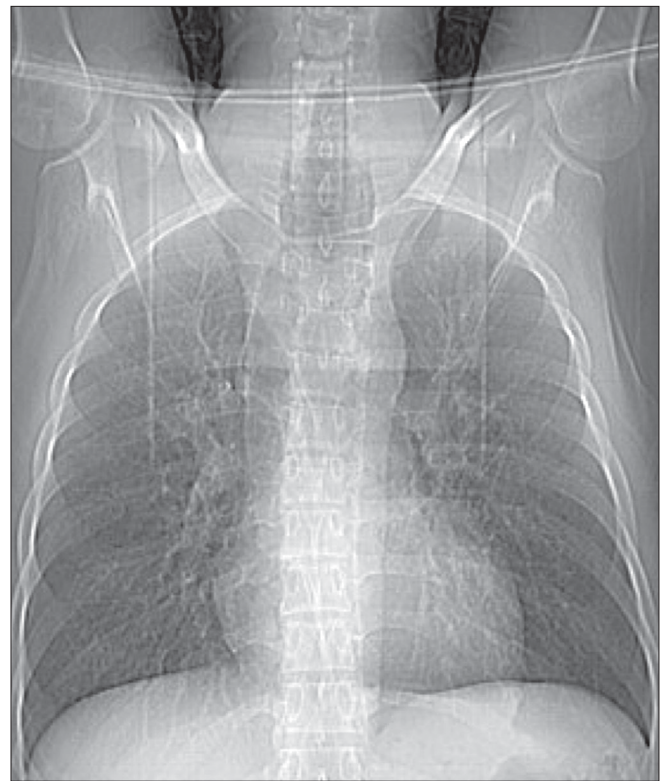
A 21-year-old man was admitted to our institute with complaints of recurrent lower respiratory tract infections since childhood, presenting as episodes of productive cough with fever. He was asymptomatic in between these episodes. The patient was a nonsmoker and there was no family history of a similar illness. The chest radiograph showed enlargement of the trachea and bronchi and bilateral bronchiectasis.

CT scan of the chest was performed. The scannogram [Figure 1] showed tracheobronchomegaly. The trachea was grossly dilated, with a diameter of 4.1 cm [Figures 2A and B], while the right and left main bronchi had diameters of 2.6 and 2.9 cm [Figure 2C], respectively. Multiple diverticula and areas of scalloping were seen between the cartilaginous rings in the trachea and right and left main bronchi [Figures 2A and B]. Cystic bronchiectasis was seen in the lung parenchyma bilaterally [Figure 2D].

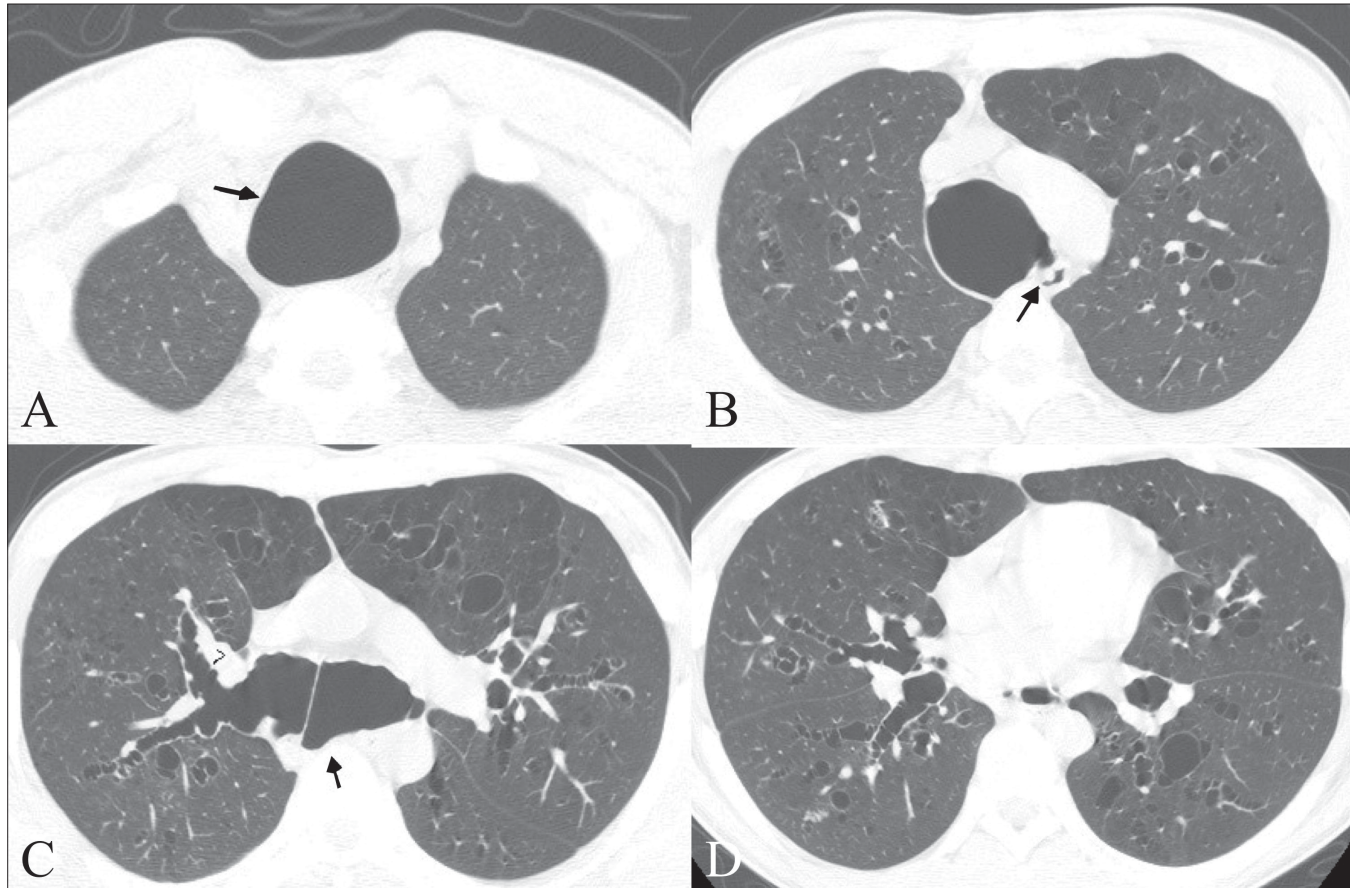
Fiberoptic bronchoscopy revealed a dilated trachea with prominent tracheal rings and widening of the bronchial tree bilaterally; mucopurulent secretion was seen at places.

## Discussion

Congenital tracheobronchomegaly, or the Mounier-Kuhn syndrome, is a rare clinical and radiological entity described by Mounier and Kuhn for the first time in 1932.<sup>[1]</sup> The syndrome is characterized by marked tracheobronchial dilatation.<sup>[1-8]</sup> Most cases present in the third or later decades



**Figure 1:** CT scannogram shows enlargement of the trachea and bronchi and bilateral bronchiectasis



**Figure 2 (A–D):** Axial high-resolution CT images show marked dilatation of the trachea (arrow in A), posterior tracheal diverticula (arrow in B), dilatation of the main bronchi (arrows in C), multiple diverticula (arrowheads in C), and bilateral cystic bronchiectasis (D)

with recurrent respiratory tract infections.<sup>[6]</sup> Although the etiology is uncertain, it is believed to be due to the lack of smooth muscle and elastic connective tissue in the trachea and main bronchi, leading to sacculations and the formation of diverticula between the cartilaginous rings.<sup>[9,10]</sup>

Disorders such as sarcoidosis, usual interstitial pneumonia, and cystic fibrosis, which cause severe fibrosis of the upper lobes, may also exert sufficient tracheal traction to result in tracheal enlargement.<sup>[9]</sup> Certain other conditions such as Marfan syndrome, Ehlers-Danlos syndrome, Kenny-Caffey syndrome, ataxia-telangiectasia, connective tissue diseases, Brachmann-de Lange syndrome, Bruton-type agammaglobulinemia, ankylosing spondylitis, cutis laxa, and light chain deposition disease are also associated with secondary tracheobronchial enlargement.<sup>[11]</sup> Most cases, however, are sporadic and show no evidence of associated connective tissue disease,<sup>[2,11]</sup> as was the case in our patient also.

On CT scan, the diagnosis is made when the transverse diameter of the trachea measures greater than 3 cm and that of the right and left main bronchi exceeds 2.4 cm and 2.3 cm, respectively.<sup>[7]</sup> The diameters in the present case were 4.1, 2.6, and 2.9 cm, respectively. Apart from the

tracheobronchial enlargement, diverticula are also seen between the cartilaginous rings. Recurrent episodes of pneumonia usually lead to bronchiectasis, as was seen in our case.

As tracheobronchomegaly can be overlooked on plain films, patients who have chronic respiratory infections should have a CT scan done in to rule out underlying predisposing conditions such as this.

## References

1. Mounier-Kuhn P. Dilatation de la trachee: Constatations radiographiques et bronchoscopiques. *Lyon Medical* 1932;150:106-9.
2. Bateson EM, Woo-Ming M. Tracheo-bronchomegaly. *Clin Radiol* 1973;24:354-8.
3. Himalstein MR, Gallagher JC. Tracheobronchomegaly. *Ann Otol Rhinol laryngol* 1973;82:223-7.
4. Aaby GV, Blake HA. Tracheobronchomegaly. *Ann Thorac Surg* 1966;2:64-70.
5. Al-Mubarak HF, Husain SA. Tracheobronchomegaly-Mounier-Kuhn syndrome. *Saudi Med J* 2004;25:798-801.
6. Marques A, Félix M, Barata F, Pires J, Estêvão MH. Mounier kuhn syndrome: a rare etiology of recurrent respiratory tract infections. *Rev Port Pneumol* 2007;13:721-7.
7. Lee JK. Computed body tomography with MRI correlation. 2006;1:408-9.

8. Fortuna FP, Irion K, Wink C, Boemo JL. Mounier Kuhn syndrome. *J Bras Pneumol* 2006;32:180-3.
9. Marom EM, Goodman PC, McAdams HP. Diffuse abnormalities of the trachea and main bronchi. *AJR Am J Roentgenol* 2001;176:713-7.
10. Ghanei M, Peyman M, Aslani J, Zamel N. Mounier-Kuhn syndrome: A rare cause of severe bronchial dilatation with normal pulmonary function test: A case report. *Respir Med* 2007;101:1836-9.
11. Lazzarini-de-Oliveira LC, Costa de Barros Franco CA, Gomes de Salles CL, de Oliveira AC Jr. A 38-year-old man with tracheomegaly, tracheal diverticulosis, and bronchiectasis. *Chest* 2001;120:1018-20.

**Source of Support:** Nil, **Conflict of Interest:** None declared.