



Research paper

Hepatitis E virus infection in acute non-traumatic neuropathy: A large prospective case-control study in China



Yijin Wang^{a,***,1}, Shan Wang^{a,1}, Jian Wu^{b,c,1}, Yiyun Jiang^{a,c,1}, Haiying Zhang^d, Shujuan Li^e, Hongyang Liu^{a,c}, Changshuang Yang^a, Haijun Tang^a, Naizhou Guo^b, Maikel P. Peppelenbosch^c, Lai Wei^d, Qiuwei Pan^{c,**}, Jingmin Zhao^{a,*}

^a Department of Pathology and Hepatology, Beijing 302 Hospital, Beijing, China

^b Department of Laboratory Medicine, The First People's Hospital of Yancheng City, Yancheng, Jiangsu, China

^c Department of Gastroenterology and Hepatology, Erasmus MC-University Medical Center, Rotterdam, The Netherlands

^d Peking University People's Hospital, Peking University Hepatology Institute, Beijing Key Laboratory for Hepatitis C and Immunotherapy for Liver Disease, Beijing, China

^e Department of Nephrology, The First People's Hospital of Yancheng City, Yancheng, Jiangsu, China

ARTICLE INFO

Article history:

Received 16 July 2018

Received in revised form 27 August 2018

Accepted 27 August 2018

Available online 3 September 2018

Keywords:

Hepatitis E virus (HEV)

Neurological disorder

Genotypes

Viral encephalitis

ABSTRACT

Neurological manifestations are potentially associated with hepatitis E virus (HEV) infection in Europe, mainly attributed to genotype (GT) 3 HEV infection. In this study, we determined the frequency and causal relationship of HEV in patients with non-traumatic neurological disorders in China, where GT4 HEV is prevalent. 1117 consecutive patients diagnosed with neurological illnesses in a hospital of eastern China and 1475 healthy controls who took routine examination in the same hospital were tested for HEV by serology and molecular methods. Anti-HEV IgM antibodies were detectable in 6 (0.54%) of the patients and 10 (0.68%) of the healthy controls ($P = 0.651$). Serum HEV RNA was detected in all of the 16 individuals with positive anti-HEV IgM. The six patients with HEV infection included two viral encephalitis, two posterior circulation ischemia, one peripheral neuropathy and one Guillain-Barré syndrome. They had no symptoms of acute viral hepatitis except two patients of viral encephalitis that showed mildly transaminitis. Additionally, 39.51% patients and 35.63% controls without acute HEV infection were positive for anti-HEV IgG ($P = 0.144$). Anti-HEV IgG positivity was more frequent in male and elderly in both the patients and control groups, but unrelated to the incidence of any non-traumatic neurological illness, hospital stay or treatment outcome, except linking to better outcome of hemorrhagic stroke disease. These data demonstrated that HEV appears not to contribute to acute neurological disorders in China. Nevertheless, we cannot exclude a possible causative role, suggesting that testing HEV in this population, especially in situations of unexplained deregulated liver function would be warranted.

© 2018 The Author(s). Published by Elsevier B.V. This is an open access article under the CC BY-NC-ND license (<http://creativecommons.org/licenses/by-nc-nd/4.0/>).

1. Introduction

Hepatitis E virus (HEV) is the most common cause of acute viral hepatitis worldwide [1]. At least four main genotypes of HEV have been

identified. Genotype (GT) 1 and GT2 HEV are restricted to human beings and transmitted via contaminated water sources, which are prevalent in developing countries. GT3 and GT4 HEV are zoonotic and commonly spread through consumption of undercooked pork or game products, which are endemic in both developing and developed countries [2]. Although HEV infection is asymptomatic in approximately 95% cases, it may result in wide-range clinical events, including hepatitis, acute pancreatitis, renal injury, neurological disorders and other immune-mediated manifestations [3–6].

As the most common extra-hepatic complication, >150 cases of HEV-associated neurological syndromes have been reported in developing and developed countries, mostly as case reports or small cohort series. The most frequently reported HEV-related neurologic syndromes include Guillain-Barré syndrome (GBS), neuralgic amyotrophy (NA),

* Correspondence to: Jingmin Zhao, Department of Pathology and Hepatology, Beijing 302 Hospital, Xisihuan Middle Road NO.100, 100039 Beijing, China.

** Correspondence to: Qiuwei Pan, Department of Gastroenterology and Hepatology, Erasmus MC, Room Na-617, 's-Gravendijkwal 230, NL-3015 CE Rotterdam, The Netherlands.

*** Correspondence to: Yijin Wang: Department of Pathology and Hepatology, Beijing 302 Hospital, Room 515, Xisihuan Middle Road NO.100, 100039 Beijing, China.

E-mail addresses: yijinwang927015@163.com (Y. Wang), q.pan@erasmusmc.nl (Q. Pan), jmzhao302@163.com (J. Zhao).

¹ These authors contributed equally to this work.

Research in context

Evidence before this study

Although hepatitis E virus (HEV) infection is asymptomatic in approximately 95% cases, it may result in wide-range clinical events, and neurological injury is the most common extra-hepatic manifestation in patients with HEV infection. >150 cases of HEV-associated neurological syndromes have been reported in developing and developed countries, mostly as case reports or small cohort series and mainly attributed to genotype (GT) 3 HEV infection. China is considered an HEV-endemic region, where GT4 is prevalent. However, the roles of GT4 HEV in neurological diseases remain largely unknown due to lack of large case-control cohort study in endemic area.

Added value of this study

The current study is the first large case-control cohort study to investigate the association of HEV infection with acute non-traumatic neurological diseases in China, where GT4 HEV is predominant. In this study, six of 1117 (0.54%) non-traumatic neuropathy injury patients and ten of 1475 (0.68%) controls had evidence of HEV infection ($P = 0.651$). This result is in contrast to all the cohort studies performed in Europe that the prevalence of HEV viraemia in neurological patients are at least 10 times higher than that documented in local blood donors. The six patients with HEV infection included two viral encephalitis, two posterior circulation ischemia, one peripheral neuropathy and one Guillian-Barré syndrome. They had no symptoms of acute viral hepatitis except two patients of viral encephalitis that showed mildly transaminitis. Anti-HEV IgG positivity was more frequent in male and elderly in both the patients and control groups, but unrelated to the incidence of any non-traumatic neurological illness, hospital stay or treatment outcome, except linking to better outcome of hemorrhagic stroke disease.

Implications of all the available evidence

These data demonstrated that HEV appears not to contribute to acute neurological disorders in China. Nevertheless, we cannot exclude a possible causative role, suggesting that testing HEV in this population, especially in situations of unexplained deregulated liver function would be warranted.

encephalitis/myelitis, central nervous system (CNS) infection, mononeuritis multiplex and Bell palsy [6]. The relationship between HEV and other neurological diseases were also documented but the causality is less clear. The prevalence of HEV related neurological illness vary between 2.4% to 11% from different cohort studies based on UK, France, Netherlands, and Bangladesh [7–10]. This is much higher than that reported in general population in the same countries. Most of these cohort studies were performed in dedicated neurological populations, such as GBS or NA. There is only one cohort study evaluating in full range of neurological diseases, which demonstrated a likely causal association as well [9].

Cases of HEV-associated neurological injury have been mainly reported in Europe and Asia, where GT3 and GT1 HEV are predominant, respectively [2,11]. To date, only two small cohort studies from China, where GT4 HEV is predominant, have found a possible link of myasthenia gravis (MG), but not GBS/encephalitis, to HEV infection [12,13]. Thus, the roles of GT4 HEV in neurologic diseases remain largely

unknown due to lack of large case-control cohort study in endemic area. China is considered an HEV-endemic region where approximately 1.09% of acute HEV infection with detectable anti-HEV immunoglobulin (Ig) M has been reported in blood donors [14]. In this study, we performed a large prospective cohort study to determine the frequency of HEV-associated neurological injury in Chinese patients with full range of non-traumatic neurological disorders, as compared with healthy controls.

2. Patients and methods

2.1. Patients and controls

From September through November 2017, consecutive patients diagnosed with acute non-traumatic neurological illnesses in the First People's Hospital of Yancheng City, Jiangsu Province, China, were enrolled in the study. All patients were evaluated and managed by experienced clinical neurologists. Serum samples were obtained onset of diagnosis in the acute phase of disease before treatment. Serums from consecutive individuals visiting the physical examination center of this hospital within the same period for routine examination were collected as healthy controls. All samples were stored at -80°C before testing.

2.2. Ethics

The standard protocol, ethical approvals and registrations of this study were approved by ethical standards committee of The First People's Hospital of Yancheng City and all patients provided informed consent that allow future testing of archived bio-samples. The protocol number of the study is [2018]-(K020).

2.3. HEV serological test

All serum samples were tested for the presence of anti-HEV IgM and IgG antibodies using commercially available HEV ELISA Kit (Wantai, Beijing, China) according to manufacturer's instructions. Samples with signal-to-noise ratio (S/N ratio) > 1.0 were considered positive.

2.4. HEV molecular test

Serums with positive anti-HEV IgM were subjected to HEV RNA detection and identification. Total RNA was extracted using QIAamp Viral RNA Mini Kit (QIAGEN, Germany) according to the manufacturer's instruction. Next, total RNA was tested for HEV RNA by means of a Diagnostic Kit for Hepatitis E Virus RNA (Jinhao, Beijing, China) according to the manufacturer's instruction. Specifically, according to the principle of real-time fluorescence quantitative polymerase chain reaction (qPCR) detection, the conserved region of open reading frame (ORF) 3 was identified by HEV-specific Taqman probe. The viral load of each sample was estimated by qPCR according to series diluted artificial pseudovirus as standards. For genotype identification, nest-PCR was performed to produce a 348-nucleotide amplicon from HEV ORF2 for sequencing as previously described [15].

2.5. Statistical analysis

Differences in proportions were tested using Chi-squared or Fisher exact test; differences in continuous variables of normal distribution were tested using the Student's t -test, and the data with skewed distribution were compared using the Mann-Whitney U test. Logistic regression was performed to determine odds ratios (ORs). A two-sided P value < 0.05 was considered to be statistically significant. Statistical analysis was performed using SPSS version 23.0.

3. Result

3.1. Study population

Between September and November 2017, 1117 patients including 626 men and 491 women were diagnosed with acute non-traumatic neurological injury and enrolled in this study. The mean age was 67 years (range 14–94 years). The wide range of neurological illnesses were divided into different clinical categories based on onset position and pathogenesis. Detailed categories were summarized in Table 1. 1475 healthy controls were enrolled, including 1005 men and 470 women with the mean age of 41 years (range 0–95 years).

3.2. HEV infection in patients with neurological injury

Anti-HEV IgM antibodies were positive in 6 (0.54%) of the non-traumatic neuropathy injury patients, compared with 10 (0.68%) of the healthy controls (Fig. 1, Table 2). The OR after adjustment for age and sex showed a similar result (Table 2). The incidence of HEV infection and S/N ratio of positive anti-HEV IgM showed no significant difference between cases and controls (Fig. 2). HEV RNA was detected in all of the 16 subjects with positive anti-HEV IgM, and the viral loads ranged from 3.68×10^3 to 2.58×10^5 copies/mL. One sample with the highest viral load was successfully sequenced and confirmed as GT4 strain. All the 6 patients and six out of 10 health controls with HEV infection were also showed positive anti-HEV IgG.

3.3. Neurological presentations

The mean age of the 6 neurological patients with HEV infection was 53 years (range 27–86 years) compared to 65 years (range 14–94 years) in the remaining 1111 patients with negative anti-HEV IgM ($P = 0.038$). Of the six patients that had evidence of HEV infection, two had viral encephalitis, two had posterior circulation ischemia, one had peripheral neuropathy and one had GBS. None of the patients presented with jaundice. Only two patients with viral encephalitis presented with a modestly raised alanine aminotransferase (ALT) level. Five patients were eventually recovered from neurological syndrome. Only one patient was well-followed up and found symptoms relief along with HEV IgM seronegative conversation. An overview of the clinical characteristics and therapeutic regimens of the 6 patients with HEV infection was summarized in Table 3, and specific descriptions are as below.

3.3.1. Case 1

A 46-year-old woman had undergone surgery to remove a mammary gland fibroma 6 month previously. The patient presented with a 5-day history of fever associated with headache and nausea. Initial treatment with mannitol, cefuroxime, ribavirin, and dexamethasone was unsuccessful. Her limbs had a Medical Research Council (MRC) score of 5, and her tendon reflexes were normal. Liver function tests (LFTs) showed slightly elevated serum ALT and aspartate aminotransferase (AST). Routine blood examination showed an increased level of C-reactive protein (CRP), implying an acute inflammatory reaction. Magnetic resonance imaging (MRI) of the brain revealed abnormal strengthening signals in the bilateral hippocampal region. The color of the cerebrospinal fluid (CSF) was transparent without bacteria, and the levels of glucose and chloride were normal with significant increase of monocytes. The final diagnosis was viral encephalitis based on an examination of the CSF. Tests for hepatitis C virus (HCV) and herpes simplex virus (HSV) were negative. The patient received antiviral treatment with ganciclovir. She was also administered piracetam to protect her nerves and glutathione to improve liver function. Her neurological symptoms and signs partially improved after treatment.

3.3.2. Case 2

A 42-year-old woman presented with a 2-month history of numbness in her left upper extremities without apparent cause. Physical examination showed that the patient was anicteric and that she had normal superficial lymph nodes and tendon reflexes. Serological testing showed slightly increased levels of γ -glutamyltranspeptidase (GGT) and uric acid. Cerebral MRI revealed point ischemia nidus in the pallium. However, medullar MRI found no obvious abnormality in the cervical brachial plexus nerve. Electromyography showed normal peripheral nerves throughout the body. The cervical vertebrae C4/5 and C5/6 showed intervertebral disc herniation, while C3/4 showed intervertebral disc bulging. Neither Brudzinski's sign nor Murphy's sign were present. The patient's limbs had an MRC score of 5. Final diagnosis was peripheral neuropathy that caused by spinal degeneration. The symptom of numbness gradually improved without treatment, and the patient showed seronegative conversion of anti-HEV IgM after 1 week.

3.3.3. Case 3

An 87-year-old man presented with 1 month history of intermittent dizziness repeatedly. Physical examination revealed that he was anicteric, that he had no hemorrhage dots in the systemic skin, and that his superficial lymph nodes were normal. LFTs showed normal serum ALT and AST, with a slightly elevated total bilirubin (TBil). The serum level of uric acid was increased and the tendon reflexes were maintained. B-ultrasonography showed sclerosis with plaque formation at several sites in the bilateral carotid arteries and in the intervertebral disc section of the vertebral artery, as well as blood supply shortage to the right side of the vertebral artery and left carotid artery. Brain computed tomography showed lacunar infarction in the basal ganglia, and the final diagnosis was posterior circulation ischemia. The patient was treated with alprostadil and vinpocetine to improve blood circulation, and his symptoms of dizziness resolved after treatment.

3.3.4. Case 4

A 42-year-old man presented with sense of rotation, nausea and vomiting, as well as aggravating dizziness. However, tinnitus and deafness were not present. The patient had previously experienced the same symptoms repeatedly for 2 months. Cerebral MRI showed point ischemia nidus in the bilateral centrum semiovale. The patient's limbs had an MRC score of 5 and the tendon reflexes were normal. Both LFTs and routine blood examination showed normal parameters. There were no pathological signs in either limb, and deep/shallow feelings were symmetrical. The patient was diagnosed with posterior circulation ischemia and treated with gastrodin and vinpocetine to improve blood circulation. He recovered after treatment.

3.3.5. Case 5

A 27-year-old man presented with headache that had lasted >10 days, after which it was accompanied by blurred vision. His symptoms improved when mannitol and dexamethasone were administered, but relapsed when treatment were withdrawn. The patient had a history of hypertension, but had not used his medications as directed. His serum ALT and GGT were mildly increased, while those of AST and TBil were normal, as well as his level of CRP. Cerebral MRI showed bilateral ventricular point ischemia nidus. Cervical vertebra MRI revealed physiological curvature and herniated disk at 4/5, 5/6 and 6/7. The abducens nerve was mildly limited on both sides, and an electrocardiogram (ECG) indicated T wave change and sinus rhythm. The CSF was transparent, but contained mildly elevated numbers of monocytes that had normalized after 3 weeks. Tests for hepatitis B virus (HBV), HCV, human immunodeficiency virus (HIV), HSV and *trypomonas pallidum* (TP) were all negative. Thus, the overall clinical picture suggested viral encephalitis, and the patient recovered after antiviral treatment with ganciclovir. He was also administered oxiracetam to protect the nerves.

Table 1

Patients with neurological event tested for HEV.

	Median age (range)	67 (14–94 years)	
	Sex (male: female)	626:491	
	Type of acute neurological event	Number Tested(n=)	Anti-IgM positive number (%)
Ischemia stroke	Vertebrobasilar insufficiency	191	0 (0%)
	Posterior circulation ischemia	145	2 (1.38%)
	Transient ischaemic attack	22	0 (0%)
	Cerebral venous sinus thrombosis	2	0 (0%)
	Ischemia stroke	15	0 (0%)
	Hemorrhagic cerebral infarction	6	0 (0%)
	Massive hemispheric infarction	9	0 (0%)
	Brainstem infarction	5	0 (0%)
	Multiple infarction	2	0 (0%)
	Cerebral infarction	225	0 (0%)
	Cerebellar infarction	5	0 (0%)
	Lacunar infarction	7	0 (0%)
	Basal ganglia infarction	1	0 (0%)
	Hemorrhagic stroke	Subdural hemorrhage	1
Hypertension ventricular hemorrhage		1	0 (0%)
Basal ganglia hemorrhage		18	0 (0%)
Cerebral hemorrhage		14	0 (0%)
Brainstem hemorrhage		12	0 (0%)
Intracranial hemorrhage		33	0 (0%)
Cerebellar hemorrhage		7	0 (0%)
Thalamic hemorrhage		6	0 (0%)
lobar hemorrhage		5	0 (0%)
Subarachnoid hemorrhage		30	0 (0%)
Intraventricular hemorrhage		4	0 (0%)
Posterior circulation hemorrhage		4	0 (0%)
hemorrhagic stroke		5	0 (0%)
Neurodegenerative disease		Guillain-Barre syndrome	3
	Alzheimer disease	2	0 (0%)
	Myasthenia	6	0 (0%)
	Peripheral neuropathy	12	1 (8.33%)
	Ischialgia	3	0 (0%)
	Neuralgia	1	0 (0%)
	Migraine/headaches	32	0 (0%)
	Dementia	2	0 (0%)
	Dizziness/vertigo	28	0 (0%)
	Parkinson's disease	22	0 (0%)
	Neurosis	13	0 (0%)
	Cranial/facial nerve palsies	7	0 (0%)
	Dyssomnia	3	0 (0%)
	Epilepsy	8	0 (0%)
	Convulsions	3	0 (0%)
	limbs numbness	2	0 (0%)
	Myelopathy	5	0 (0%)
	Multiple system atrophy	2	0 (0%)
	Trigeminal Nerve Diseases	1	0 (0%)
	Oculomotor nerve injury	2	0 (0%)
	Hashimoto encephalopathy	1	0 (0%)
	Paraneoplastic syndrome	1	0 (0%)
	Hepatolenticular degeneration	1	0 (0%)
	Sensorineural deafness	1	0 (0%)
	Excessive shock response	1	0 (0%)
	Hunter's syndrome	1	0 (0%)
Leukoencephalopathy	1	0 (0%)	
Central nervous system infections	Subacute associated lesions	1	0 (0%)
	Unknown encephalitis	2	0 (0%)
	Toxicencephalitis	1	0 (0%)
	Viral encephalitis	26	2 (7.69%)
Others	Myelitis	3	0 (0%)
	Bacterial encephalitis	8	0 (0%)
	Toxic encephalopathy	2	0 (0%)
	Subdural haematoma	3	0 (0%)
	Sequelae of cerebral infarction	57	0 (0%)
	Sequela of cerebral hemorrhage	8	0 (0%)
	Sequelae of cerebral apoplexy	4	0 (0%)
	Brain post-traumatic syndrome	7	0 (0%)
	Acute cerebrovascular disease	5	0 (0%)
	Intracranial space occupying lesion	3	0 (0%)
	Vertebro-basilar artery syndrome	2	0 (0%)
	Arterial aneurysm	6	0 (0%)
	Arteriosclerotic encephalopathy	5	0 (0%)
	Focal cerebral ischemia	2	0 (0%)
Other ^a	33	0 (0%)	

^a Other: rare diseases and unknown cause.

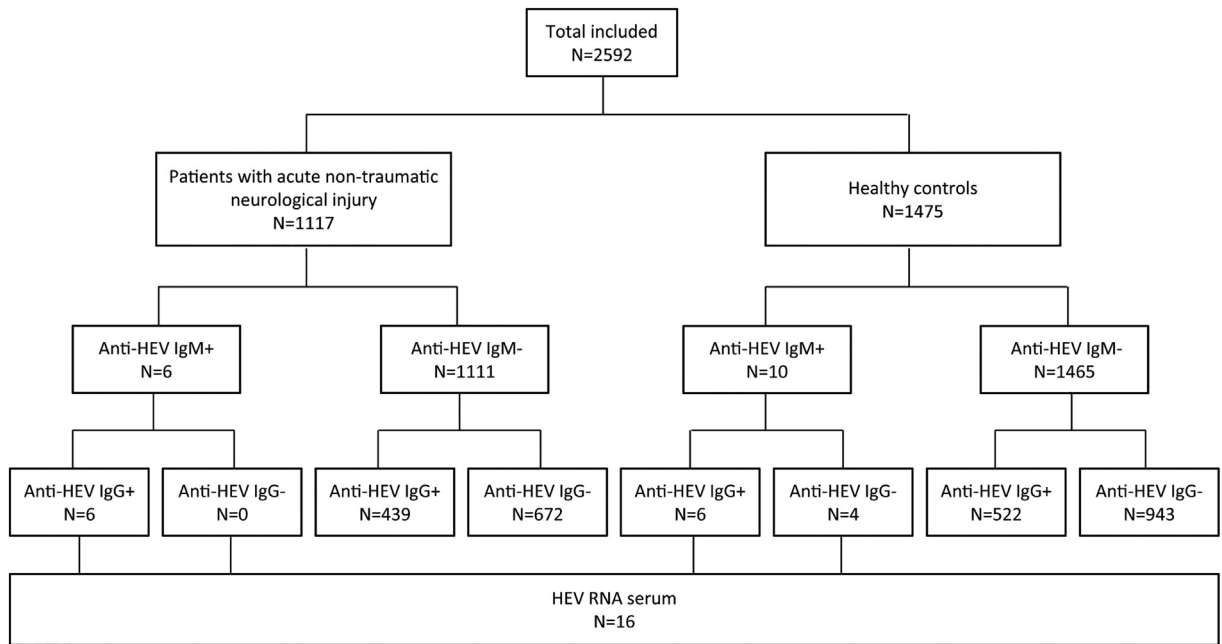


Fig. 1. Flowchart of patients and healthy controls at enrollment.

Table 2
Frequency of anti-HEV IgM and IgG antibodies in patients with neurological injury and healthy controls.

	Neurological injury (n = 1117)	Healthy controls (n = 1475)	OR (95% CI)	P value	Adjusted OR (95% CI)	Adjusted P value
Anti-HEV IgM positive	6 (0.54)	10 (0.68)	0.791 (0.287–2.183)	0.651	1.396 (0.429–4.544)	0.579
Anti-HEV IgG positive	439 (39.51)	522 (35.63)	1.180 (1.005–1.864)	0.044	0.861 (0.705–1.053)	0.144

3.3.6. Case 6

A 71-year-old man presented with weakness of the left limb associated with slurred speech 3 days prior. He was initially admitted to the intensive care unit with a diagnosis of severe hypokalaemia and was then transferred to the neurology department when his symptoms had improved. He had previously undergone a gastric perforation operation. Physical examination revealed that the patient was anicteric, that he had no hemorrhage dot in the systemic skin, and that his superficial

lymph nodes were normal. Furthermore, he maintained deep tendon reflexes. The patient’s serum levels of ALT and AST were normal, and his TBil was slightly elevated. His left and right limbs had MRC scores of 4 and 5, respectively. His CSF was transparent, but contained significantly elevated levels of monocytes, glucose, and CSF protein. Chloride level of was normal. The result of the Pany test was positive, confirming the increased levels of CSF protein. The overall clinical picture suggested

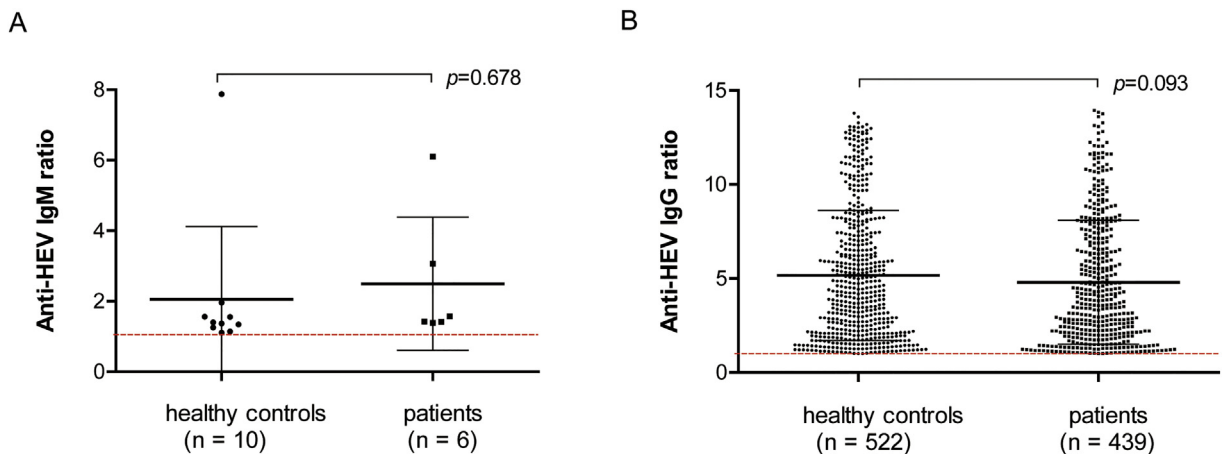


Fig. 2. Anti-HEV IgM and IgG S/N ratios for patients with neurological injury and healthy controls. S/N ratios of in subjects with positive anti-HEV IgM (A) and IgG (B). Red dotted lines represent the cutoff ratio (1.0). The P values are calculated by t-test comparing S/N ratio of positives. HEV = hepatitis E virus; Ig = immunoglobulin; S/N = signal-to-noise.

Table 3
Demographic, clinical, and diagnostic features of neurological patients potentially associated with HEV infection.

	Case 1	Case 2	Case 3	Case 4	Case 5	Case 6
Demographic characteristics						
Age,y	46	42	87	42	27	71
Sex	F	F	M	M	M	M
Liver function test						
Alanine aminotransferase (ALT), 5–40 U/L	76	30.1	11.3	18.1	142.6	28
Aspartate aminotransferase (AST), 8–40 U/L	54	29.3	17.9	23.3	47	20
γ-glutamyltranspeptidase (GGT), 3–50 U/L	37	51.2	38.2	56.8	88.5	17
Alkaline phosphatase (ALP), 40–110 U/L	NT	88.3	74.5	93.5	78.3	NT
Total bilirubin (TBIL), 1.71–17.1 μmol/L	9.6	6.68	24.07	23.69	7.32	28.6
Serum tumor/inflammation makers						
Carbohydrate antigen (CA) 19–9, 0–37 U/ml	NT	4.45	NT	NT	NT	0.732
CA-125, 0–35 U/ml	16.7	11.55	NT	NT	NT	14.91
CY-211, 0–3.3 U/ml	NT	3.17	NT	NT	NT	1.93
CA72–4, 0–8.2 U/ml	0.673	7.78	NT	NT	NT	1.24
CA15–3, 0–25 U/ml	NT	6.69	NT	NT	NT	NT
Neuron-specific enolase (NSE), 0–17 ng/ml	10.03	9.63	NT	NT	NT	7.36
C reactive protein (CRP), ≤10 mg/L	40.7	NT	NT	NT	1.96	NT
Viral serological testing						
Hepatitis B virus surface antigen (HBsAg)	–	NT	NT	–	–	NT
Hepatitis B virus surface antibody (HBsAb)	+	NT	NT	–	–	NT
HBeAg	–	NT	NT	–	–	NT
HBeAb	–	NT	NT	–	–	NT
Hepatitis B core antibody (HBcAb)	+	NT	NT	–	–	NT
Hepatitis C virus (HCV)	–	NT	NT	–	–	NT
Anti-HEV IgM S/N ratio	6.1	1.39	1.57	3.07	1.41	1.42
Anti-HEV IgG S/N ratio	9.01	4.25	3.53	2.83	3.28	1.37
Human immunodeficiency virus [HIV(1 + 2)]	–	NT	NT	–	–	NT
Treponema pallidum antibodies (TPAB)	–	NT	NT	–	–	NT
Toxoplasma (Tox)-IgM	–	–	–	–	–	–
Tox-IgG	–	–	–	–	–	–
Cytomegalovirus (CMV)-IgM	–	–	–	–	–	–
CMV-IgG	+	+	+	+	+	+
Herpes simplex virus (HSV)-IgM	–	–	–	–	–	–
HSV-IgG	+	+	+	+	+	+
Rubella virus (RV)-IgM	+	+	–	+	+	–
RV-IgG	+	+	+	–	+	+
Cerebrospinal fluid (CSF) testing						
CSF protein (CSF-PR), 0.15–0.45 g/L	0.2	NT	NT	NT	0.36	1.11
CSF-Cl, 120–132 mmol/L	125.9	NT	NT	NT	125.7	123.1
CSF-GLU, 2.5–4.5 mmol/L	4.49	NT	NT	NT	4.41	5.32
CSF-karyocyte count, (0–8) × 10 ⁶ /L	12	NT	NT	NT	12	23
C-TMD	transparent	NT	NT	NT	transparent	transparent
C-Pandy	–	NT	NT	NT	–	+

(continued on next page)

Table 3 (continued)

	Case 1	Case 2	Case 3	Case 4	Case 5	Case 6
Immune status and past medical history						
Immunocompetent	Yes	Yes	Yes	Yes	Yes	Yes
Past medical history	Mammary gland fibroma	No	No	No	Hypertension	Gastric perforation
Diagnosis, treatment and outcome						
Neurological diagnosis	Viral encephalitis	Peripheral neuropathy	Posterior circulation ischemia	Posterior circulation ischemia	Viral encephalitis	GBS
Treatment	Prednisolone, ganciclovir, pantoprazole, piracetam, glutathione, mannitol	No treatment	Alprostadil, oxiracetam, mecobalamin, vinpocetine	Gastrodin, vinpocetine, dimenhydrinate	Ganciclovir, mecobalamin, oxiracetam, mannitol, dexamethasone	Prednisolone, pantoprazole, sodium, aceglutamide, ceftazidime
Outcome	Recovery	Residual left arm numbness	Recovery	Recovery	Recovery	Recovery

NT: no tested.

Table 4 Seroprevalence of IgG in patients of different types of acute neurological event.

	Anti-HEV IgG + (n = 439)	Anti-HEV IgG-(n = 672)	t	χ^2	P
Age, years	64 ± 14	63 ± 15	3.94		<0.001
Sex				6.88	0.009
Male	60.82%	52.83%			
Female	39.18%	47.17%			
Ischemia stroke	59.68%	55.21%		2.167	0.141
Hemorrhagic stroke	12.30%	12.80%		0.060	0.807
Neurodegenerative disease	13.44%	15.48%		0.880	0.348
Central nervous system infections	2.96%	4.02%		0.854	0.355
Others	11.62%	12.50%		0.194	0.660

GBS, and adequate relief of symptoms was achieved after antibiotic treatment with ceftazidime.

3.4. Seroprevalence of past HEV infection

In the rest of patients without acute HEV infection, anti-HEV IgG antibodies were found in 439 (39.51%) patients, compared with 522 (35.63%) healthy controls ($P < 0.001$) (Fig. 1 and Table 2). After adjustment for age and sex, there was no difference of anti-HEV IgG seroprevalence between patients and controls (Table 2). S/N ratio of positive anti-HEV IgG was similar in the two groups (Fig. 2). Anti-HEV IgG positivity was more frequent in male and elderly in both groups, but unrelated to the incidence of any non-traumatic neurological illness (Table 4, S1), hospital stay or treatment outcome, except linking to better outcome of hemorrhagic stroke disease (Table 5).

4. Discussion

The current study is the first large case-control cohort study to investigate the association of HEV infection with acute non-traumatic

Table 5 Hospital stay and therapeutic outcomes of neurological injury patients with detectable versus undetectable anti-HEV IgG^a.

Type of neurological event	Anti-HEV IgG+N (%)	Anti-HEV IgG-N (%)	P
Ischemia stroke	262	371	
Recovery/improvement	249 (95.04%)	350 (94.34%)	0.407
Treatment failure	1 (0.38%)	0 (0%)	
Others	12 (4.58%)	21 (5.66%)	
Hospital stay (average, d)	10.69	10.75	0.935
Hemorrhagic stroke ^b	54	86	
Recovery/improvement	52 (96.30%)	72 (83.72%)	0.023
Others	2 (3.70%)	14 (16.28%)	
Hospital stay (median, d)	14 (10–29)	14 (7.75–25)	0.451
Neurodegenerative disease ^b	59	104	
Recovery/improvement	58 (98.31%)	100 (96.15%)	0.44
Others	1 (1.69%)	4 (3.85%)	
Hospital stay (average, d)	10.31	9.18	0.376
CNS infections ^b	13	27	
Recovery/improvement	13 (100%)	26 (96.30%)	1
Others	0 (0%)	1 (3.70%)	
Hospital stay (median, d)	15 (9.5–25.5)	14 (8–19)	0.470
Others	51	84	
Recovery/improvement	46 (90.20%)	76 (90.48%)	0.854
Treatment failure	0 (0%)	1 (1.19%)	
Others	5 (9.80%)	7 (8.33%)	
Hospital stay (average, d)	9.94	13.02	0.114

^a Student t-test for normally distributed continuous variables whereas other continuous variables were expressed in median (interquartile range [IQR]); the data with skewed distribution were compared using the Mann-Whitney U test; Chi-squared or the Fisher's exact test for categorical variables with expected cell sizes less than five were used.

^b There is no treatment failure patient in both anti-HEV IgG positive and negative cohorts.

neurological diseases in China, where GT4 HEV is predominant. We showed that six of 1117 (0.54%) non-traumatic neuropathy injury patients and ten of 1475 (0.68%) controls had HEV infection ($P = 0.651$). This result is in contrast to all the cohort studies performed in Europe that the prevalence of HEV viraemia in neurological patients are at least 10 times higher than that documented in local blood donors [8–10]. Of note, in the present study, HEV viraemia was observed in all patients and controls who had positive anti-HEV IgM antibodies. The 6 patients had no jaundice and only two presented mildly elevated ALT.

In the past decade, HEV associated neurological syndromes have been described in developing and developed countries, most of which are related to GT3 or GT1 HEV [6]. The discrepancy between our study and the European studies is likely due to the genotype differences. Despite an outbreak of 1989 was caused by GT1 HEV in Xinjiang province, China, the predominant circulating genotype in China has shifted towards GT4 over the decades, with occasional GT1 cases [16–20]. Several sporadic cases of neurological injury that possibly linked to HEV infection have been documented in China [12,21–23]. However, these cases were either coinfecting with other pathogens, such as hepatitis B virus and cytomegalovirus [21], or only positive for anti-HEV IgM [12,22,23]. Although there was one case of GT4 HEV related bilateral peripheral facial palsy reported in Japan [24], the causation with HEV infection is uncertain. Moreover, a small cohort study performed in China composed of 64 GBS patients and 21 encephalitis patients found one patient with possible acute HEV infection (only anti-HEV IgM was positive) and none of the encephalitis patients tested positive for anti-HEV IgM, and no HEV RNA was detected in serum and CSF [12]. Interestingly, a very recent Chinese study indicated that HEV viraemia was detected in 2.1% (4/188) MG patients and the all isolates were GT4 HEV [13]. Further studies are required to clarify the causality of GT4 HEV infection in neurological diseases.

GBS and NA have been identified as the most frequent HEV associated neurological disorders. Two previous reports conducted in the Netherlands and Bangladesh, where GT3 and GT1 HEV predominate, respectively, revealed that 5% and 11% of GBS patients had positive anti-HEV IgM [7,8]. More recently, a study conducted in Belgium found that 8% of the GBS cases were possibly associated with a recent HEV infection [25]. However, no confirmed GBS or NA attributing to GT4 HEV has been documented among the approximately 70 HEV-related GBS or NA cases [6]. In our study, one of the three GBS cases appeared to be associated with GT4 HEV. Nevertheless, the causal relationship remains to be established with larger GBS population.

The rates of anti-HEV IgM positivity and HEV viraemia showed no significant difference between the patients and controls. However, whether HEV is an etiology of the six non-traumatic neuropathy injury patients reported in the present study requires further investigation. The striking observation is that two of the 26 patients with viral encephalitis tested positive for HEV, and only these two patients among all patients with HEV showed abnormal LFTs. This is consistent with other studies involving GT3 HEV-associated encephalitis, in which the only two documented cases showed elevated ALT [26,27]. This observation indicates that viral encephalitis, unlike other HEV-related neurological illnesses, appears to present symptomatic acute hepatitis. Encephalitis/myelitis is one of the most common HEV-associated neurological disorders after GBS and NA, but all had confirmed GT3 HEV infections. Recently, an experimental study in gerbils confirmed that HEV can break through the blood-brain barrier and replicate in the central nervous system [28]. However, one cohort study performed in China enrolled 21 patients with encephalitis found no positive anti-HEV IgM or detectable HEV RNA in the serum or CSF [12], probably because of geographical heterogeneity or small size of cohort. The present large cohort study indicated a causal relationship between HEV and viral encephalitis.

Patient 2 presented with a 2-month history of numbness in the left upper extremities and was diagnosed with peripheral neuropathy. She was positive for both anti-HEV IgM and IgG. The numbness of the left

upper limb resolved without any treatment upon anti-HEV IgM seronegative conversion, suggesting a potential causal association. In a previous study, viral status was shown to be associated with peripheral neuropathy in two cases of chronic HEV infection. In one case, neurological symptoms completely resolved, with successful HEV clearance, after treatment with a combination of Peg-IFN alpha and ribavirin [29]. In contrast, the other case, who failed to achieve viral clearance by Peg-IFN alpha treatment and reduction of immunosuppressants, had no improvement in symptoms and ultimately dying [30].

The relationship between HEV and ischemic neuropathy remains less clear. In our study, involving 635 patients with posterior circulation ischemia (PCI)/transient ischemic attack (TIA)/vertebrobasilar insufficiency (VBI)/stroke, two patients showed evidence of HEV infection. Similar cases were reported in a recent study, whereby four of 238 patients who suffered stroke/TIA presented positive HEV IgM and two of them had HEV viraemia [9]. The rate of HEV infection in ischemic neuropathy patients was even lower than that in the healthy population in the current study. There is no evidence to support a causal relationship between HEV and this neurological pattern.

Of note, HEV viraemia was observed in all the patients and controls who had positive anti-HEV IgM antibodies, among which only one sample was successfully sequenced. We found the viral loads in most of the 16 samples were close to the detection threshold and the sample of successful sequencing had the highest viral load. Thus, the failure in sequencing of the other 15 HEV viraemic individuals is likely due to low viral load. The kit for HEV RNA detection used in the study is highly sensitive and specific [31,32] with detection limit of 1.42×10^3 copies/mL, which explains the high rate of HEV RNA detection and the low rate of successful sequencing.

Since >70 neurological conditions were included in the current study, it could be argued that the heterogeneity of the studied population may lead to involvement of potential confounding factors, which probably contribute to no more detected HEV infections in the cases group as compared to the controlled one. However, as an exploratory study, we incipiently desired to know the full range and frequency of GT4 HEV-associated neurological injury, in addition to foregone HEV associated neurological syndromes, just as an pilot Europe study reported in 2017 that explored the role of HEV in a wide range of neurological pathologies of various aetiologies [9]. The provisional findings in our study have provided a hint of like or unlike causality between specific neurological conditions and HEV infection. Nevertheless, further studies focusing on the defined neurological populations that HEV is likely a contributor are deserved in China to precisely address the relationship between GT4 HEV infection and specific neurological disorders.

Besides the lacking of the definite confirmation of HEV genotype for all the patients and heterogeneity of the studied population, there are some other limitations in our current study. First, the sex and age were not well-matched between the patient and control groups. Secondly, CSF samples were not collected for HEV RNA tests, thus lacking of a direct proof in some patients. Thirdly, the follow-up data of HEV status in most cases were missed, leading to a question whether the alleviation of symptoms is the result from recovery of HEV infection.

In conclusion, this is the first large cohort study of HEV infection in a wide spectrum of neurological diseases in China, where GT4 is prevalent. We have demonstrated that 0.54% patients with acute non-traumatic neurological injury had HEV infection. The overall incidence of HEV infection was not significantly different between patients and healthy controls. Nevertheless, we cannot exclude a possible causative role, suggesting that testing HEV in this population, especially in situations of unexplained deregulated liver function would be warranted. Multicenter studies are warranted to further clarify the role of HEV infection in neurological diseases in GT4 prevalent regions.

Conflicts of interest

The authors have declared that no competing interests exist.

Authors contributions

Y.W. contributed to study concept and design, obtained funding, supervision of the study, literature search and writing of the manuscript; S.W. contributed to acquisition and analysis of data, making tables and figures, and drafting of the manuscript; J.W. and N.G. contributed to patients' sample and medical information collection; Y.J. contributed to acquisition and analysis of data; Y.Z. and L.W. contributed to acquisition of data; S.L. and H.L. contributed to statistical analysis. C.Y. and H.T. contributed to statistical analysis; M.P.P. contributed to study concept; Q.P. contributed to study concept and critical revision of the manuscript; J.Z. contributed to study concept and study supervision.

Conflicts of interest

This study was supported by National Natural Science Foundation of China (No. 31770186, 81802020) (to Y. Wang).

Disclaimer

Supplementary data to this article can be found online at <https://doi.org/10.1016/j.ebiom.2018.08.053>.

References

- [1] Kamar N, Dalton HR, Abravanel F, Izopet J. Hepatitis E virus infection. *Clin Microbiol Rev* 2014;27:116–38.
- [2] Kamar N, Bendall R, Legrand-Abravanel F, Xia NS, Ijaz S, Izopet J, et al. Hepatitis E. *Lancet* 2012;379:2477–88.
- [3] Pischke S, Hartl J, Pas SD, Lohse AW, Jacobs BC, Van der Eijk AA. Hepatitis E virus: Infection beyond the liver. *J Hepatol* 2017;66:1082–95.
- [4] Nayak HK, Kamble NL, Raizada N, Garg S, Daga MK. Acute pancreatitis complicating acute hepatitis E virus infection: a case report and review. *Case Rep Hepatol* 2013;2013:531235.
- [5] Guinault D, Ribes D, Delas A, Milongo D, Abravanel F, Puissant-Lubrano B, et al. Hepatitis E virus-induced cryoglobulinemic glomerulonephritis in a nonimmunocompromised person. *Am J Kidney Dis* 2016;67:660–3.
- [6] Dalton HR, Kamar N, van Eijk JJ, McLean BN, Cintas P, Bendall RP, et al. Hepatitis E virus and neurological injury. *Nat Rev Neurol* 2016;12:77–85.
- [7] Geurtsvankessel CH, Islam Z, Mohammad QD, Jacobs BC, Endtz HP, Osterhaus AD. Hepatitis E and Guillain-Barre syndrome. *Clin Infect Dis* 2013;57:1369–70.
- [8] van den Berg B, van der Eijk AA, Pas SD, Hunter JG, Madden RG, Tio-Gillen AP, et al. Guillain-Barre syndrome associated with preceding hepatitis E virus infection. *Neurology* 2014;82:491–7.
- [9] Dalton HR, van Eijk JJ, Cintas P, Madden RG, Jones C, Webb GW, et al. Hepatitis E virus infection and acute non-traumatic neurological injury: a prospective multicentre study. *J Hepatol* 2017;67:925–32.
- [10] van Eijk JJ, Madden RG, van der Eijk AA, Hunter JG, Reimerink JH, Bendall RP, et al. Neuralgic amyotrophy and hepatitis E virus infection. *Neurology* 2014;82:498–503.
- [11] Perez-Gracia MT, Suay B, Mateos-Lindemann ML. Hepatitis E: an emerging disease. *Infect Genet Evol* 2014;22:40–59.
- [12] Wang L, Wen J, Gao F, Hao H, Wang L. Hepatitis E virus-associated neurological injury in China. *J Infect Dis* 2017;215:1340–1.
- [13] Wang L, Gao F, Lin G, Yuan Y, Huang Y, Hao H, et al. Association of hepatitis E virus infection and myasthenia gravis: a pilot study. *J Hepatol* 2018;68:1318–20.
- [14] Zhang L, Jiao S, Yang Z, Xu L, Liu L, Feng Q, et al. Prevalence of hepatitis E virus infection among blood donors in mainland China: a meta-analysis. *Transfusion* 2017;57:248–57.
- [15] Liu P, Bu QN, Wang L, Han J, Du RJ, Lei YX, et al. Transmission of hepatitis E virus from rabbits to cynomolgus macaques. *Emerg Infect Dis* 2013;19:559–65.
- [16] Zhuang H, Cao XY, Liu CB, Wang GM. Epidemiology of hepatitis E in China. *Gastroenterol Jpn* 1991;26(Suppl. 3):135–8.
- [17] Yu Y, Sun J, Liu M, Xia L, Zhao C, Harrison TJ, et al. Seroepidemiology and genetic characterization of hepatitis E virus in the northeast of China. *Infect Genet Evol* 2009;9:554–61.
- [18] Ma Z, Feng R, Zhao C, Harrison TJ, Li M, Qiao Z, et al. Seroprevalence and distribution of hepatitis E virus in various ethnic groups in Gansu province, China. *Infect Genet Evol* 2010;10:614–9.
- [19] Dai X, Dong C, Zhou Z, Liang J, Dong M, Yang Y, et al. Hepatitis E virus genotype 4, Nanjing, China, 2001–2011. *Emerg Infect Dis* 2013;19:1528–30.
- [20] Sridhar S, Lo SK, Xing F, Yang J, Ye H, Chan JF, et al. Clinical characteristics and molecular epidemiology of hepatitis E in Shenzhen, China: a shift toward foodborne transmission of hepatitis E virus infection. *Emerg Microbes Infect* 2017;6:e115.
- [21] Lei JH, Tian Y, Luo HY, Chen Z, Peng F. Guillain-Barre syndrome following acute co-super-infection of hepatitis E virus and cytomegalovirus in a chronic hepatitis B virus carrier. *J Med Virol* 2017;89:368–72.
- [22] Chen XD, Zhou YT, Zhou JJ, Wang YW, Tong DM. Guillain-Barre syndrome and encephalitis/encephalopathy of a rare case of Northern China acute severe hepatitis E infection. *Neurol Sci* 2014;35:1461–3.
- [23] Tse AC, Cheung RT, Ho SL, Chan KH. Guillain-Barre syndrome associated with acute hepatitis E infection. *J Clin Neurosci* 2012;19:607–8.
- [24] Yazaki Y, Sugawara K, Honda M, Ohnishi H, Nagashima S, Takahashi M, et al. Characteristics of 20 patients with autochthonous acute hepatitis E in Hokkaido, Japan: first report of bilateral facial palsy following the infection with genotype 4 hepatitis E virus. *Tohoku J Exp Med* 2015;236:263–71.
- [25] Stevens O, Claeys KG, Poesen K, Saegeman V, Van Damme P. Diagnostic challenges and clinical characteristics of hepatitis E virus-associated Guillain-Barre syndrome. *JAMA Neurol* 2017;74:26–33.
- [26] Deroux A, Brion JP, Hyerle L, Belbezier A, Vaillant M, Mosnier E, et al. Association between hepatitis E and neurological disorders: two case studies and literature review. *J Clin Virol* 2014;60:60–2.
- [27] Kamar N, Bendall RP, Peron JM, Cintas P, Prudhomme L, Mansuy JM, et al. Hepatitis E virus and neurologic disorders. *Emerg Infect Dis* 2011;17:173–9.
- [28] Shi R, Soomro MH, She R, Yang Y, Wang T, Wu Q, et al. Evidence of Hepatitis E virus breaking through the blood-brain barrier and replicating in the central nervous system. *J Viral Hepat* 2016;23:930–9.
- [29] Woolson KL, Forbes A, Vine L, Beynon L, McElhinney L, Panayi V, et al. Extra-hepatic manifestations of autochthonous hepatitis E infection. *Aliment Pharmacol Ther* 2014;40:1282–91.
- [30] Maddukuri VC, Russo MW, Ahrens WA, Emerson SU, Engle RE, Purcell RH, et al. Chronic hepatitis E with neurologic manifestations and rapid progression of liver fibrosis in a liver transplant recipient. *Dig Dis Sci* 2013;58:2413–6.
- [31] Zhao C, Geng Y, Harrison TJ, Huang W, Song A, Wang Y. Evaluation of an antigen-capture EIA for the diagnosis of hepatitis E virus infection. *J Viral Hepat* 2015;22:957–63.
- [32] Zhang H, Rao H, Wang Y, Wang J, Kong X, Ji Y, et al. Evaluation of an antigen assay for diagnosing acute and chronic hepatitis E genotype 4 infection. *J Gastroenterol Hepatol* 2018.