

Management of Asymptomatic Terminal Ileitis

Jean A. Donet, MD,* Aline Charabaty, MD,[†] and Alan C. Moss, MD[‡]

Ileal intubation is often performed during screening colonoscopies. This had led to the recognition of mild ileitis in many asymptomatic patients. The natural history and clinical significance of this finding are not well established, and there are no guidelines on whether these patients merit further work-up or an interval surveillance colonoscopy. This conundrum was presented and discussed on @MondayNightIBD. In this article, we review the specific literature on the topic and make reference to the informed opinions of the convo participants. We propose an #IBDAAlgorithm for management of asymptomatic ileitis.

Lay Summary

Mild inflammation in the small bowel (ileum) is sometimes found on routine colonoscopy in patients with no digestive symptoms or history of Crohn disease. These patients have a low risk of developing Crohn disease, and no further testing is recommended.

Key Words: asymptomatic ileitis, colonoscopy, Crohn disease

CASE SCENARIO¹

Asymptomatic ileitis (a few ulcers) are found during colorectal cancer (CRC) screening colonoscopy in a healthy, asymptomatic 50-year-old patient. Biopsies show chronic ileitis. No history of nonsteroidal anti-inflammatory drugs (NSAIDs) use. What do you do?

1. Repeat colonoscopy in 1 year
2. Start mesalamine
3. Start anti-tumor necrosis factor (TNF)
4. Start Vedolizumab

DISCUSSION

Endoscopic ileitis comprehends a wide spectrum of severity and can be the result of different and multiple conditions.¹ Mild ileitis consists of a few aphthous ulcers with

normal intervening mucosa and can be found incidentally on routine CRC screening. Often, mild ileitis does not have an obvious cause (ie, NSAIDs use or recent history of infectious enteritis) and remains indeterminate despite ileal biopsies.² In a US prospective cohort, the prevalence of a new ileitis diagnosis from ileoscopy was 2.7% in asymptomatic patients undergoing surveillance colonoscopy.³ The clinical debate is whether these patients, or a subgroup of them, may have unrecognized or early Crohn disease (CD) or are at risk of developing symptomatic CD in the future and hence would need appropriate care and follow-up. On the other hand, it is as important not to mislabel benign, nonspecific ileitis of no clinical significance as CD, with all the implications that a chronic diagnosis and (unwarranted) therapies and follow-ups will have on a patient's life.

Currently, there are no societal guidelines for what the course of action should be in patients with incidental mild ileitis on routine colonoscopy. Our #MondayNightIBD discussion revealed that clinical practice varies in this scenario. Many convo participants recommended further evaluation with an exhaustive clinical interrogation, checking inflammatory biomarkers level and proceeding with small bowel imaging to risk stratify these patients; many others recommended performing a repeat colonoscopy in 1 year; and others recommended no further work-up.

The key to decide the best course of action for these patients is to know the natural history of asymptomatic mild terminal ileitis. Although the rate of disease progression and predictive factors of disabling or severe CD have been studied in patients with established CD, similar studies in asymptomatic patients with mild ileitis are lacking.

Based on limited retrospective data, the rate of progression from asymptomatic mild terminal ileitis to clinically impactful CD appears to be low. In a Korean retrospective study, 93 asymptomatic patients with isolated terminal ileal ulcerations found during routine colonoscopy were followed

This is an Open Access article distributed under the terms of the Creative Commons Attribution Non-Commercial License (<http://creativecommons.org/licenses/by-nc/4.0/>), which permits non-commercial re-use, distribution, and repro-

Received for publications July 8, 2020; Editorial Decision July 8, 2020.

*Division of Gastroenterology, University of California San Francisco-Fresno, Fresno, California, USA; [†]Division of Gastroenterology, Johns Hopkins School of Medicine, Sibley Memorial Hospital, Washington, District of Columbia, USA; [‡]Division of Gastroenterology, Boston University Medical Center, Boston, Massachusetts, USA

Address correspondence to: Jean A. Donet, MD, Division of Gastroenterology, University of California San Francisco-Fresno, 2615 E. Clinton Ave, Fresno, CA 93703 (jdonet@fresno.ucsf.edu).

Twitter: @jeandonet, @DCharabaty, @moss_md

Conflicts of interest: Jean A. Donet: none. Alan C. Moss: consultant for Janssen, Pfizer, Gilead, and TechLab. Aline Charabaty: educational grant from Pfizer and Takeda for @MondayNightIBD. Consulting and/or advisory board for Janssen, Abbvie, and Pfizer.

© The Author(s) 2020. Published by Oxford University Press on behalf of Crohn's & Colitis Foundation.

duction in any medium, provided the original work is properly cited. For commercial re-use, please contact journals.permissions@oup.com
doi: 10.1093/crocol/otaa065
Published online 12 October 2020

for a mean duration of 29.9 months. Follow-up colonoscopy showed persistent ileal ulcers in 31 patients, only 1 of whom developed CD.⁴ This study has several limitations, some of which are related to its retrospective design.⁵

The need for ileal biopsies as well as the diagnostic and prognostic yield of pathology were discussed. From a pathology perspective, a diagnosis of chronic ileitis can be made with confidence, but is not necessarily diagnostic or prognostic of symptomatic CD.⁶ In a US retrospective study, 29 patients with isolated terminal ileitis were followed for a duration ranging from 2.2 to 12.6 years. Fourteen of these 29 patients were asymptomatic when they completed their colonoscopy. Despite the presence of 1 or more features of chronicity in 11/14 asymptomatic patients and of focal active ileitis in the 3 others, none of them developed CD on follow-up.⁷

Clinicians highlighted the need to ensure patients are truly asymptomatic through a detailed and thorough clinical interrogation, since the presence of any intestinal, extraintestinal, constitutional symptoms, or anemia may be a signal of underlying CD and can determine the management of these patients. In the same US retrospective study previously cited, 8 of 10

(80%) of symptomatic patients with features of chronicity on ileal biopsies progressed to a diagnosis of CD on follow-up.⁷ An Italian prospective study followed for 6 years, 51 patients with nonspecific indeterminate ileitis found on diagnostic colonoscopy (most common indications were overt or occult bleeding, diarrhea, and constitutional symptoms); 26 (51%) patients had chronic inflammation on pathology and a total of 10 (19.6%) of the 51 symptomatic patients were eventually diagnosed with CD.⁸

In a French study, 1123 newly diagnosed CD patients were retrospectively assessed to identify factors at diagnosis that would predict a disabling disease course within the next 5 years. Disabling disease course was defined as a requirement of more than 2 steroid courses/steroid dependence, or further CD-related hospitalizations, or chronic CD-related symptoms, or need of immunosuppressive therapy, or CD-related surgery. The rate of progression to disabling CD was 85.2%. Initial requirement for steroids [odds ratio (OR) 3.1, 95% confidence interval (CI) 2.2–4.4], presence of perianal disease (OR 1.8, 95% CI 1.2–2.8), and age below 40 years (OR 2.1, 95% CI 1.3–3.6) were found to be independent factors present at diagnosis and

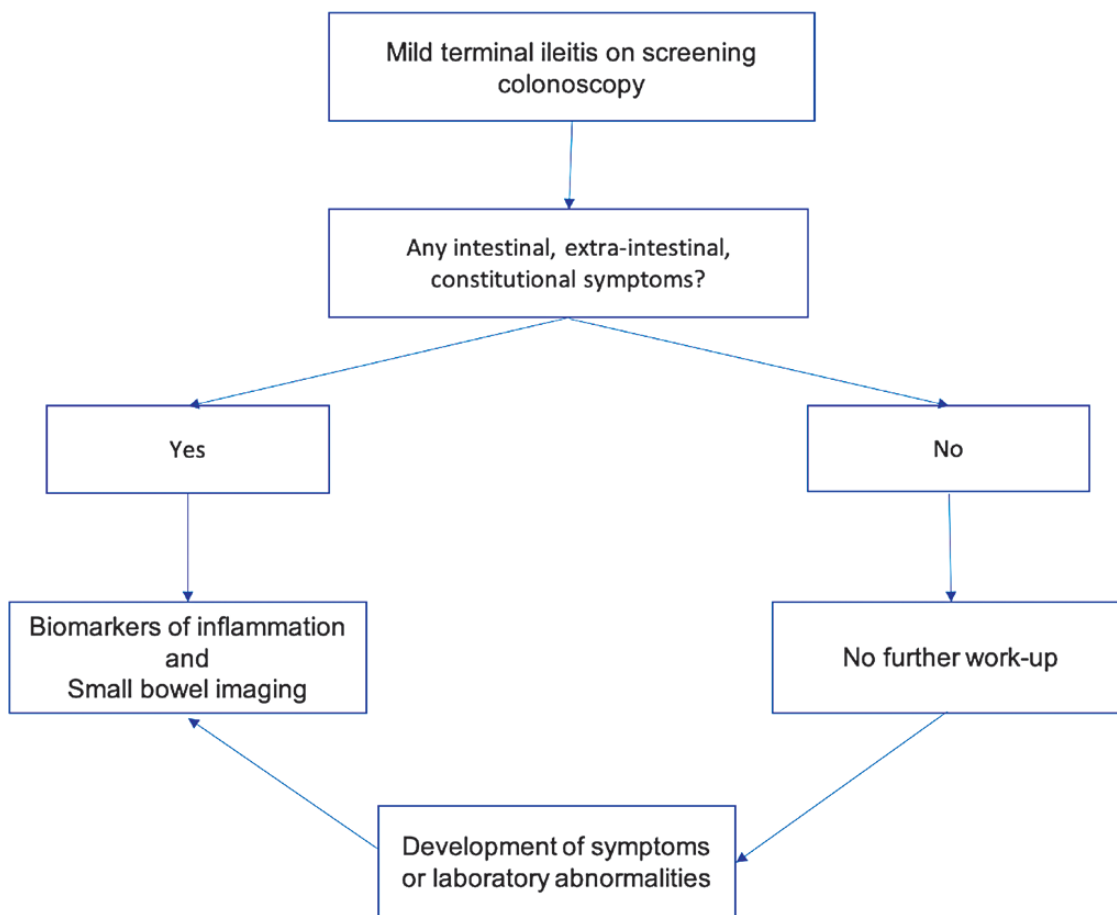


FIGURE 1. #IBDAAlgorithm for the management of asymptomatic mild terminal ileitis.

significantly associated to a subsequent disabling CD course. A smaller prospective cohort in this same study confirmed these findings.⁹ In a different, Belgian study, 361 patients with CD with a follow-up of longer than 5 years were retrospectively assessed to identify at diagnosis factors predictive of a disabling, or severe disease course. Disabling disease was defined similar to the previously cited French study. 57.9% developed disabling disease within 5 years after diagnosis. Perianal lesions (OR 2.6, 95% CI 1.4–5.1), need for steroids to treat the first flare (OR 1.7, 95% CI 1.02–2.7), ileocolonic location (OR 1.74, 95% CI 1.06–2.8), but not age below 40 years were associated with the development of disabling CD. Severe CD was defined by the development of complex perianal disease, or needing any colonic resection, or 2 or more small bowel resection, or a single small bowel resection >50 cm in length, or a construction of a definite stoma. 37.4% of patients developed severe CD over the course of their illness. Strictureing behavior at diagnosis [hazard ratio (HR) 2.11, 95% CI 1.39–3.2] and weight loss >5 kg at diagnosis (HR 1.67, 95% CI 1.14–2.45) were independently associated with development of severe CD.¹⁰

Another important matter raised during the discussion was whether an elevated biomarker of inflammation [ie, CRP or fecal calprotectin (FCP)] would change the management and prognosis of asymptomatic mild ileitis. Although it is reasonable to think they could play such a role, there are currently no published studies evaluating the impact of these biomarkers in this specific subset of asymptomatic patients. Prospective US studies have shown that asymptomatic CD patients with elevated CRP are at increased risk for bowel damage and hospitalization over the following years compared to asymptomatic CD patients with normal CRP.^{11,12} A recent retrospective British study (abstract) has shown that normalization of FCP within 12 months of CD diagnosis is associated with a reduction in long-term CD progression over a median follow-up of 5.3 years. Disease progression was defined as a composite of progression in disease behavior, hospitalization for CD, and surgery for CD.¹³ A different British, retrospective study (abstract) evaluated 74 patients with isolated terminal ileitis diagnosed via any colonoscopy (diagnostic and nondiagnostic) over a 4-year period. 60 (81.1%) patients had ulcers in the terminal ileum. A total of 38 (51.4%) patients had a FCP performed, of which 27 (71.1%) came back elevated (defined as fecal calprotectin >150 µg/mg). A subsequent diagnosis of CD was made in 15 (20.3%) of the 74 patients. Almost 90% of these new cases of CD had an elevated FCP. The authors concluded that patients with terminal ileum ulcers in combination with an elevated FCP increased the likelihood of a new CD diagnosis, with an OR of 1.28 ($P = 0.016$, CI 0.45–0.047) compared to those without terminal ileum ulcers and normal FCP (<150 µg/mg). The number of new CD cases or the proportion of patients with elevated FCP, stratified by type of colonoscopy (diagnostic

vs nondiagnostic) or procedure indication is not mentioned in the abstract.¹⁴

Finally, based on limited available data, the rate of progression of asymptomatic mild ileitis to CD is low. While most respondents in the poll would repeat colonoscopy in 1 year to reassess for ileitis, expert opinion consensus was that this healthy and asymptomatic 50-year-old male with few ulcers in the terminal ileum found during CRC screening colonoscopy, does not need further work-up, repeat colonoscopy or treatment; instead, clinical follow-up and monitoring of symptoms were recommended (Fig. 1). Prospective studies with long-term follow-up of asymptomatic patients with mild terminal ileitis are needed to better define the natural history and long-term clinical implications of this finding.

RESULTS OF THE POLL (% OF ALL RESPONDENTS): TOTAL OF 67 VOTES

1. Repeat colonoscopy in 1 year 92.5%
2. Start mesalamines 4.5%
3. Start anti-TNF 0%
4. Start Vedolizumab 3%

#MondayNightIBD #MedTwitter Teaching Points

1. Mild terminal ileitis is a common finding in asymptomatic patients undergoing screening colonoscopy.
2. The rate of progression of mild terminal ileitis to CD in asymptomatic patients appears to be low (~1%).
3. No further work-up is recommended for patients with mild terminal ileitis in the absence of symptoms or laboratory abnormalities.
4. Prospective studies are needed to better define the natural history of asymptomatic mild terminal ileitis.

DATA AVAILABILITY

No data were created or analyzed.

REFERENCES

1. Bojic D, Markovic S. Terminal ileitis is not always Crohn's disease. *Ann Gastroenterol.* 2011;24:271–275. <https://twitter.com/i/events/1147978201311973378?s=20>
2. Watanabe T, Fujiwara Y, Chan FKL. Current knowledge on non-steroidal anti-inflammatory drug-induced small-bowel damage: a comprehensive review. *J Gastroenterol.* 2020;55:481–495.
3. Zwas FR, Bonheim NA, Berken CA, et al. Diagnostic yield of routine ileoscopy. *Am J Gastroenterol.* 1995;90:1441–1443.
4. Chang HS, Lee D, Kim JC, et al. Isolated terminal ileal ulcerations in asymptomatic individuals: natural course and clinical significance. *Gastrointest Endosc.* 2010;72:1226–1232.
5. Cappell MS. Isolated terminal ileal ulcer in asymptomatic patients: a call for prospective studies with long-term follow-up to determine the need for surveillance colonoscopy. *Gastrointest Endosc.* 2011;73:1331–1332.
6. Cuvelier C, Demetter P, Mielants H, et al. Interpretation of ileal biopsies: morphological features in normal and diseased mucosa. *Histopathology.* 2001; 38:1–12.
7. Courville EL, Siegel CA, Vay T, et al. Isolated asymptomatic ileitis does not progress to overt Crohn disease on long-term follow-up despite features of chronicity in ileal biopsies. *Am J Surg Pathol.* 2009;33:1341–1347.

8. Bezzio C, Arena I, Devani M, et al. Aspecific ileitis: Crohn's disease or not Crohn's disease? A prospective study. *Int J Colorectal Dis.* 2017;32:1025–1028.
9. Beaugerie L, Seksik P, Nion-Larmurier I, et al. Predictors of Crohn's disease. *Gastroenterology.* 2006;130:650–656.
10. Loly C, Belaiche J, Louis E. Predictors of severe Crohn's disease. *Scand J Gastroenterol.* 2008;43:948–954.
11. Bhattacharya A, Rao BB, Koutroubakis IE, et al. Silent Crohn's disease predicts increased bowel damage during multiyear follow-up: the consequences of under-reporting active inflammation. *Inflamm Bowel Dis.* 2016;22:2665–2671.
12. Click B, Vargas EJ, Anderson AM, et al. Silent Crohn's disease: asymptomatic patients with elevated C-reactive protein are at risk for subsequent hospitalization. *Inflamm Bowel Dis.* 2015;21:2254–2261.
13. Plevris NFJ, Jenkinson P, Siakavellas S, et al. Normalization of fecal calprotectin within 12 months of diagnosis is associated with a reduced risk of disease progression in Crohn's disease. *Gastroenterology.* 2020;158:S-74.
14. Patel R, Ang K, Moledina S, et al. Isolated terminal ileitis at colonoscopy—what factors predict a new diagnosis of Crohn's disease. *Gastroenterology.* 2020;158:S23.