



Contents lists available at ScienceDirect

## International Journal of Surgery Case Reports

journal homepage: [www.casereports.com](http://www.casereports.com)

# Laparotomy-assisted transcatheter variceal embolization for bleeding jejunal varices formed at the site of choledochojejunostomy: Report of a case and review of the literature

Masaki Wakasugi<sup>a,\*</sup>, Masanori Tsujie<sup>a</sup>, Seiichi Goda<sup>b</sup>, Kohsaku Ohnishi<sup>c</sup>, Chikato Koga<sup>a</sup>, Mitsuyoshi Tei<sup>a</sup>, Ryohei Kawabata<sup>a</sup>, Junichi Hasegawa<sup>a</sup>

<sup>a</sup> Department of Surgery, Osaka Rosai Hospital, Japan

<sup>b</sup> Department of Diagnostic and Interventional Radiology, Osaka Rosai Hospital, Japan

<sup>c</sup> Department of Gastroenterology, Osaka Rosai Hospital, 1179-3 Nagasone-cho, Kita-ku, Sakai, Osaka, 591-8025, Japan

## ARTICLE INFO

## Article history:

Received 14 October 2020

Received in revised form

16 November 2020

Accepted 16 November 2020

Available online 20 November 2020

## Keywords:

Bilioenteric anastomosis

Case report

Choledochojejunostomy

Jejunal varices

Laparotomy-assisted transcatheter variceal embolization

Pancreaticoduodenectomy

Portal vein hypertension

## ABSTRACT

**INTRODUCTION:** Bleeding from jejunal varices formed at the site of a bilioenteric anastomosis due to portal vein hypertension is relatively rare and difficult to treat.

**PRESENTATION OF CASE:** An 80-year-old man with melena, slight fever, and abdominal pain was referred to our hospital. He had undergone subtotal stomach-preserving pancreaticoduodenectomy for cancer of the ampulla of Vater six years earlier. Follow-up computed tomography (CT) three years earlier showed occlusion of the extrahepatic portal vein and the growth of collateral flow into the lateral segment of the liver, but there were no signs of recurrence of the cancer of the ampulla of Vater. The patient underwent prophylactic endoscopic variceal ligation for esophageal varices one year earlier. On admission, blood tests showed anemia and elevated liver enzyme and bilirubin levels. Esophagogastroduodenoscopy and colonoscopy failed to identify the site of bleeding. Double-balloon endoscopy showed the dilated blood vessels around the stenotic anastomosis of the choledochojejunostomy. A CT scan was consistent with total occlusion of the portal vein and varices around the choledochojejunostomy site. With a diagnosis of jejunal varices, laparotomy-assisted transcatheter variceal embolization was performed. Double-balloon endoscopy performed one month after laparotomy-assisted transcatheter variceal embolization showed no varices, and dilation of the stenotic anastomosis of the choledochojejunostomy was performed safely.

**CONCLUSION:** Jejunal varices should be included in the differential diagnosis of melena in patients with a previous history of surgery with a bilioenteric anastomosis and portal vein hypertension. Laparotomy-assisted transcatheter variceal embolization is one of the options for the treatment of jejunal varices.

© 2020 The Authors. Published by Elsevier Ltd on behalf of IJS Publishing Group Ltd. This is an open access article under the CC BY-NC-ND license (<http://creativecommons.org/licenses/by-nc-nd/4.0/>).

## 1. Introduction

Bleeding from varices in the jejunal loop after a bilioenteric anastomosis is relatively rare. The incidence of jejunal varices and bleeding jejunal varices is still unknown. Portal vein hypertension due to extrahepatic portal vein stenosis or obstruction results in the formation of hepatopetal collaterals through the anastomosis, thus creating varices in the afferent loop that can rupture and bleed [1,2]. However, treatment of patients with ectopic varices at a bilioenteric anastomosis could be challenging and requires a multidisciplinary approach. This report presents the case of a patient with bleeding from jejunal varices successfully treated by laparotomy-assisted

embolization. This work has been reported in line with the SCARE criteria [3].

## 2. Presentation of case

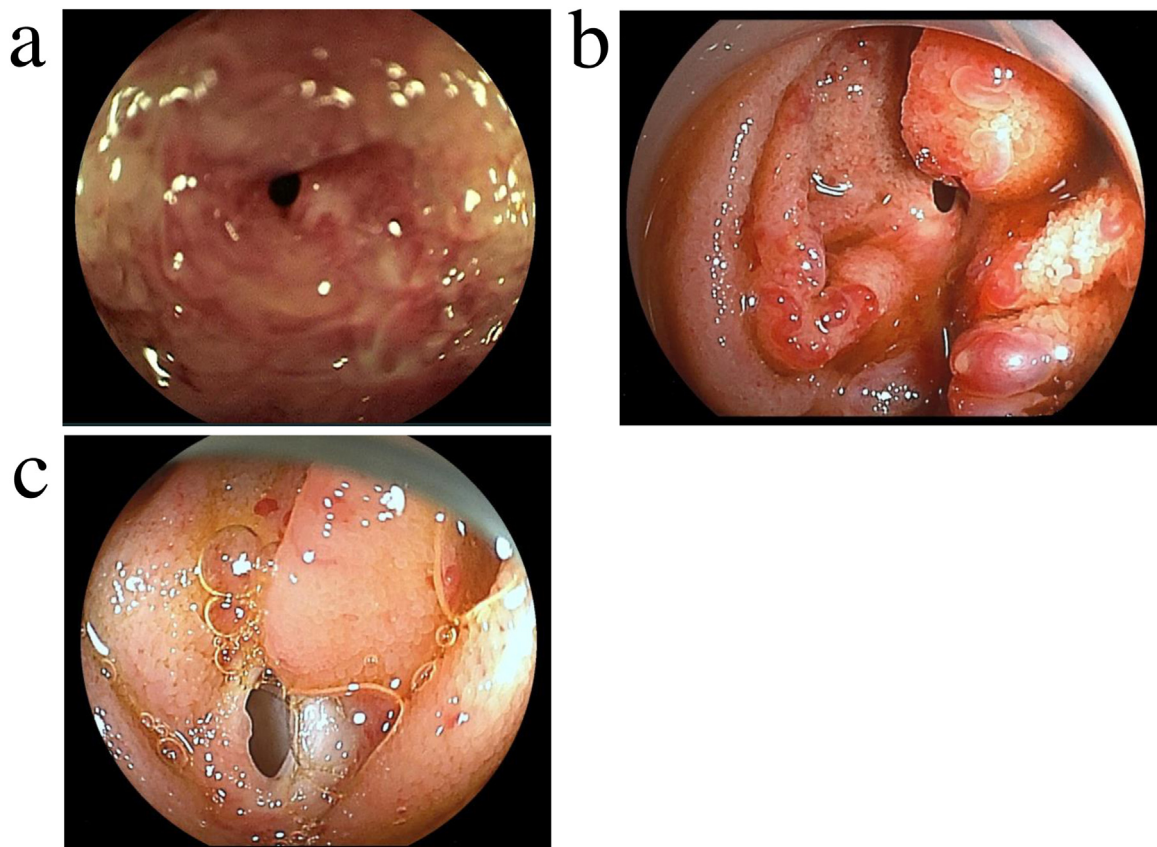
### 2.1. Patient

An 80-year-old man with a fever of 37.5 degrees celsius, melena, and abdominal pain was referred to our hospital. His blood pressure was 108/56 mmHg on admission. Blood examinations showed anemia (Hb 8.0 g/dl). Routine laboratory tests demonstrated total bilirubin (T-Bil) of 1.5 mg/dL (normal 0.4–1.4 mg/dL), aspartate aminotransferase (AST) of 50 IU/L (normal 10–33 IU/L), and alanine aminotransferase (ALT) of 47 IU/L (normal 6–35 IU/L). His serum albumin was 2.9 g/dl (normal 3.8–5.2 g/dl) and prothrombin activity was 93.0% (normal 80.0–100.0%).

He had undergone subtotal stomach-preserving pancreaticoduodenectomy (SSPPD) with a diagnosis of cancer of the ampulla

\* Corresponding author at: Department of Surgery, Osaka Rosai Hospital, 1179-3 Nagasone-cho, Kita-ku, Sakai, Osaka, 591-8025, Japan.

E-mail address: [wakasugimasaki@gmail.com](mailto:wakasugimasaki@gmail.com) (M. Wakasugi).



**Fig. 1.** a. No varices at the site of choledochojejunostomy were detected three years after subtotal stomach-preserving pancreaticoduodenectomy. b. Double-balloon endoscopy showed dilated blood vessels around the stenotic anastomosis of the choledochojejunostomy. c. Double-balloon endoscopy performed one month after laparotomy-assisted transcatheter variceal embolization showed no varices at the site of choledochojejunostomy.

of Vater six years earlier. Coil embolization to the common hepatic artery was performed to control the bleeding from the rupture of the aneurysm at the stump of the gastroduodenal artery due to a pancreatic fistula on postoperative day 25 after SSPPD. The ampullary cancer was diagnosed as T1aN0M0, Stage I according to the eighth edition of the TNM classification [4]. The patient developed cholangitis due to intrahepatic stones, and he was successfully treated by double-balloon endoscopy (DBE) three years earlier. No varices at the site of choledochojejunostomy were detected at that time (Fig. 1a). Follow-up computed tomography (CT) showed occlusion of the extrahepatic portal vein and the growth of collateral flow into the lateral segment of the liver, although there were no signs of recurrence of the cancer of the ampulla of Vater. Follow-up esophagogastroduodenoscopy detected the esophageal varices one year earlier, and the prophylactic endoscopic variceal ligation (EVL) was performed for esophageal varices. Serum levels of carcinoembryonic antigen and carbohydrate antigen 19-9 were within normal limits throughout the course.

## 2.2. Course after admission

The patient was managed initially with blood transfusion and antibiotics for progressive anemia and obstructive cholangitis. Esophagogastroduodenoscopy and colonoscopy failed to identify the site of bleeding. DBE showed dilated blood vessels around the stenotic anastomosis of the choledochojejunostomy (Fig. 1b). CT and portography were consistent with total occlusion of the portal vein with varices around the choledochojejunostomy site (Fig. 2). The multidisciplinary meeting with surgeons, interventional radiologists, and endoscopists concluded that jejunal varices should be treated before dilation of the stenotic anastomosis

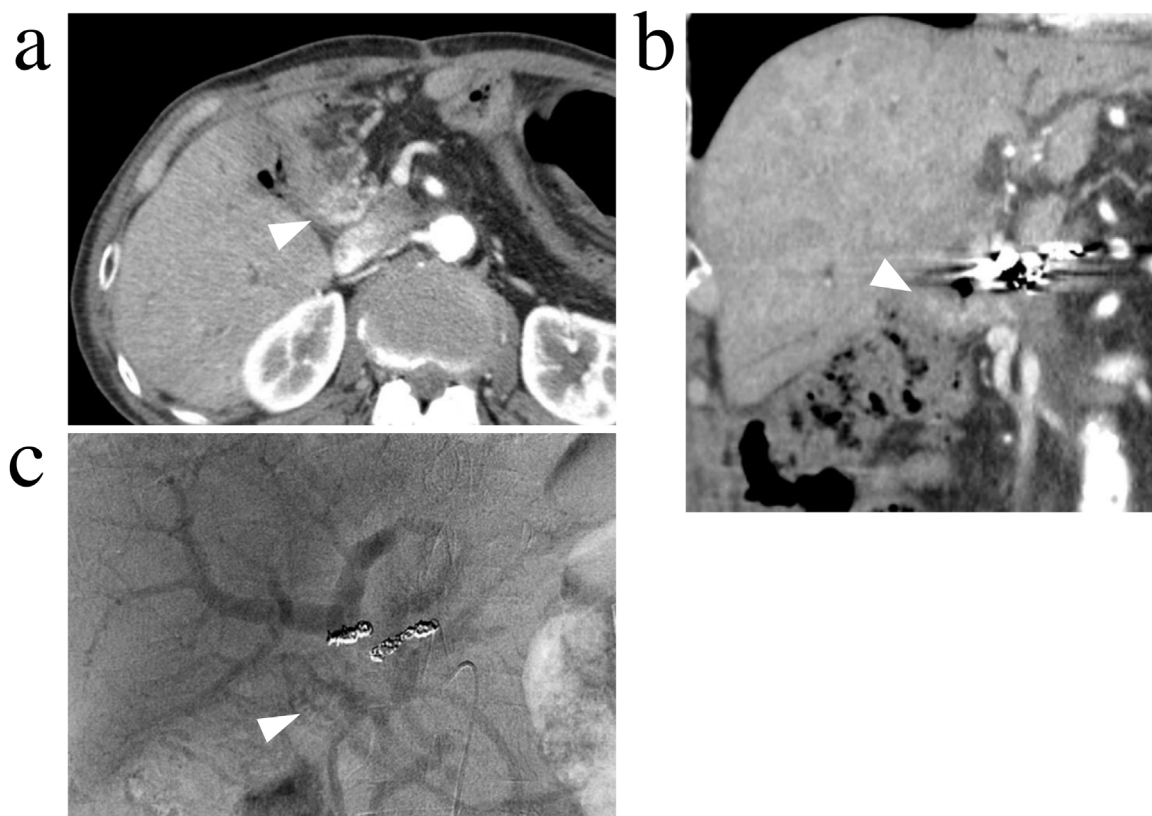
of choledochojejunostomy. Laparotomy-assisted transcatheter variceal embolization was planned on the 13th day after admission. Although the vital signs of the patient were stable before treatment, he received a total of 10 packs (about 2,800 mL) of red blood cells.

## 2.3. Laparotomy-assisted transcatheter variceal embolization

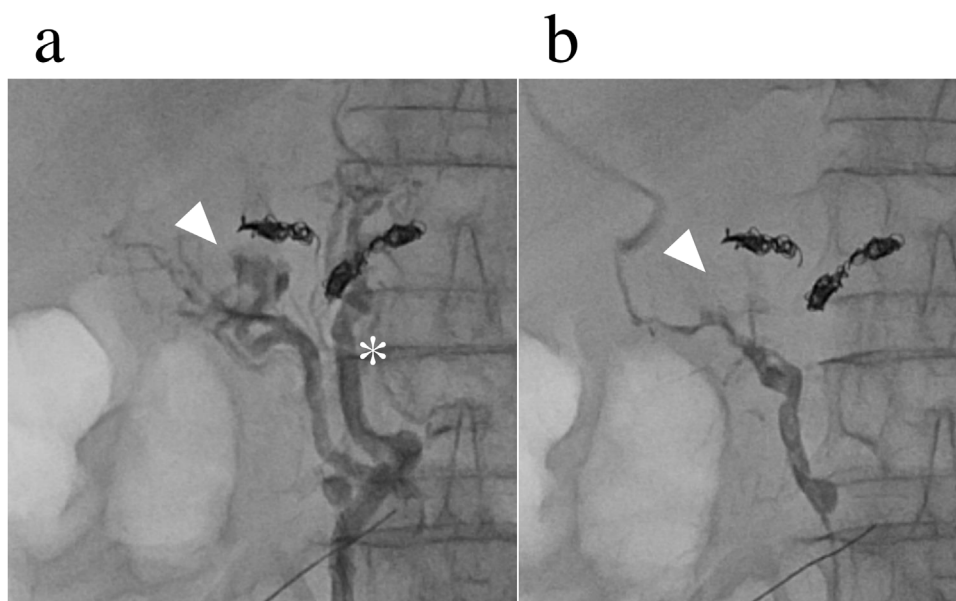
Under general anesthesia, a lower abdominal incision was made, and the adhesion under the incision was dissected carefully. The cecum and ascending colon were mobilized to show the small bowel mesentery. The terminal ileal vein was exposed, and a 6-Fr. sheath was inserted through a guidewire. The portal vein had been totally occluded, and the main hepatopetal flow proved to be a collateral route toward the lateral segment of the liver. The vein that flowed into the varices at the site of the choledochojejunostomy branched off the main hepatopetal route (Fig. 3a). Under balloon occlusion, embolization was performed using 5% ethanolamine oleate with iopamidol (EOI) (Fig. 3b). The varices disappeared after embolization, though the intrahepatic portal vein remained clear.

## 2.4. Postoperative course

DBE performed one month after laparotomy-assisted transcatheter variceal embolization showed no varices at the afferent jejunal loop (Fig. 1c), and dilation of the stenotic anastomosis of choledochojejunostomy was safely performed. The patient has been asymptomatic with a stable hemoglobin, free from cholangitis and without any signs of recurrence of the cancer of the ampulla of Vater for 8 months after this treatment at the time of writing.



**Fig. 2.** Computed tomography and portography are consistent with varices around the choledochojejunostomy site (arrow head).  
 a. Transverse view.  
 b. Coronal view.  
 c. Portography.



**Fig. 3.** Laparotomy-assisted transcatheter variceal embolization.  
 a. Portography in the jejunal branch shows jejunal varices (arrowhead) at the choledochojejunostomy.  
 \*main hepatopetal route that flows into the lateral segment of the liver.  
 b. The varices have disappeared after embolization.

**3. Discussion**

In this case, there were two important clinical observations: (1) jejunal varices should be included in the differential diagnosis of

melena in patients with a previous history of bilioenteric anastomosis and portal venous hypertension, (2) laparotomy-assisted transcatheter variceal embolization is one of the options for the treatment of bleeding jejunal varices.

**Table 1**  
Treatment of jejunal varices at the site of bilioenteric anastomosis as reported in the English literature.

Author [reference]	Year	Age/Sex	Primary disease	Previous operation	Duration from previous operation to admission	Treatment
Ito [5]	1997	66/M	Intrahepatic stones	CJ and lateral segmentectomy	5 years	Endoscopic sclerotherapy
Johnson [6]	1997	39/M	Chronic pancreatitis	CJ and cystoduodenostomy	–	PV stenting
Ishida [7]	1998	75/F	GBC	hepaticojejunostomy	7 years	Resection of the jejunum
Hiraoka [8]	2001	66/F	PC	PD	1 year	PV stenting
		44/F	Gallbladder stone	CJ and cholecystectomy	17 years	Shunt operation (first), PV stenting (second)
Sato [9]	2003	79/F	GBC	CJ and partial liver resection	7 years 9 years	Resection of the jejunum (first) Laparotomy-assisted embolization (second)
Sakai [10]	2005	54/F	BDC	PD	16 months	PV stenting
Ota [11]	2005	64/F	CPV	PD	8 years	PV stenting
Smith [12]	2005	42/F	Chronic pancreatitis	CJ and gastrojejunostomy cholecystectomy	18 months	Ligation of dilated jejunal vein
Taniguchi [13]	2008	64/F	BDC	Right hepatectomy and caudate lobectomy left hepatojejunostomy	5 years	Repair of CJ Reconstruction of hepatojejunostomy (first) Splenectomy (second)
Rezende-Neto [14]	2008	64/F	Acute cholecystitis	CJ and cholecystectomy	10 years 15 years	Subtotal splenectomy and shunt operation
Sasamoto [1]	2010	42/M	Intrahepatic and gallbladder stones	CJ and cholecystectomy	1 year	Cholangiographic sclerotherapy (first) Laparotomy-assisted embolization (second)
Saeki [2]	2011	59/M	Osteoclastic giant cell tumor of the duodenum	PD	3 years	Laparotomy-assisted embolization
	2011	79/F	BDC	Right hepatectomy and caudate lobectomy left hepaticojejunostomy	13 years	Endoscopic sclerotherapy (first) Shunt operation (second)
Sakurai [15]	2014	67/M	PC	PD	9 months	Laparotomy-assisted embolization
Sone [16]	2014	74/M	Chronic pancreatitis	CJ and cholecystectomy	–	PV stenting Extra-anatomic splenoportal shunt (first) Transjugular intrahepatic portosystemic shunt (second) Laparotomy-assisted embolization (third)
Kitagawa [17]	2015	82/F	CPV	PD	6 years	Endoscopic sclerotherapy
Yoshimatsu [18]	2016	19/M	Congenital atresia of the biliary tract	Reconstruction of the bile duct	19 years	Laparotomy-assisted embolization
		65/M	PC	PD	1 year	Laparotomy-assisted embolization
		47/M	BDC	CJ and left hepatectomy	6 years	Embolization
Kohli [19]	2017	54/M	Primary sclerosing cholangitis	Liver transplantation recipient with CJ	–	Laparotomy-assisted endoscopic sclerotherapy
Ali [20]	2017	55/M	Neuroendocrine tumor	PD	10 years	Endoscopic sclerotherapy
Wong [21]	2018	45/M	Serous cyst adenoma	PD	7 years	PV stenting
Heiberger [22]	2019	78/F	PC	PD	4 years	PV stenting
Abdalla [23]	2019	77/F	PC	PD	3 years	PV stenting
Present case	2020	81/M	CPV	PD	6 years	Laparotomy-assisted embolization

PV: portal vein, GC: gallbladder cancer, PC: pancreatic cancer, BDC: bile duct cancer, CPV: cancer of the papilla of Vater. CJ: choledochojejunostomy, PD: pancreaticoduodenectomy.

Firstly, jejunal varices should be considered in the differential diagnosis of melena in patients with a previous history of bilioenteric anastomosis and portal venous hypertension. Although the number of long-term survival cases after surgery has recently increased, only 26 cases with jejunal varices at the site of bilioenteric anastomosis have so far been reported in the English literature according to a PubMed search (Table 1). In the present patient who underwent pancreaticoduodenectomy, formation of hepatopetal collaterals was precluded by lymph node dissection,

and varices formed in the jejunum at the bilioenteric anastomosis. In the present case, the occlusion of the extrahepatic portal vein and the growth of collateral flow into the lateral segment of the liver were detected three years before treatment, and prophylactic EVL for the esophageal varices was performed one year earlier. These episodes were compatible with portal venous hypertension and ectopic bleeding from the varices at the site of choledochojejunostomy, although it is difficult to diagnose.



Secondary, laparotomy-assisted transcatheter variceal embolization is an effective treatment option for bleeding jejunal varices. Two treatment options are available for varices at the bilioenteric anastomosis: obliteration of the varices (by endoscopic sclerotherapy or ligation, embolization, surgical re-anastomosis) and portal decompression [by portal venous dilatation and stenting, splenectomy, and shunt operation (surgical shunt or transjugular intrahepatic portosystemic shunt)] [2]. Table 1 shows the various treatments for jejunal varices at the site of bilioenteric anastomosis [1,2,5–23]. Portal vein stenting was performed for 9 cases, and laparotomy-assisted embolization was performed for 8 cases. Six cases required additional treatment because bleeding recurred after the first treatment [1,2,8,9,13,16]. In this case with stenotic anastomosis, double-balloon endoscopic sclerotherapy was avoided because controlling the bleeding during treatment was difficult, and sclerotherapy could worsen the stenosis. There were no percutaneous routes for embolization, and portal vein stenting seemed to be difficult because of total occlusion. Therefore, laparotomy-assisted embolization was selected and safely performed.

A multidisciplinary approach with the cooperation of surgeons, interventional radiologists, and endoscopists is critical for timely management of the unstable patient with bleeding jejunal varices. Previous reports showed that patients with bleeding from the varices at the site of a bilioenteric anastomosis sometimes developed shock and required multiple blood transfusions before treatment [14,23]. Treatment could be selected from various options according to the condition depending on the doctors' skill and the equipment available in the institution. In addition, second or third treatment must be taken into consideration, because controlling the bleeding from jejunal varices is sometimes difficult. The present case could undergo elective laparotomy-assisted transcatheter variceal embolization with stable vital signs after the discussion at the multidisciplinary meeting.

#### 4. Conclusions

Jejunal varices should be included in the differential diagnosis in patients with a previous history of bilioenteric anastomosis and portal vein hypertension. Laparotomy-assisted transcatheter variceal embolization is one of the options for the treatment of bleeding from jejunal varices. A multidisciplinary approach with the cooperation coordination of surgeons, interventional radiologists, and endoscopists is critical for the management for bleeding from jejunal varices.

#### Declaration of competing interest

The authors report no declarations of interest.

#### Funding

None.

#### Ethical approval

A case report is exempt from ethical approval in our institution.

#### Consent

Written informed consent was obtained from the patient for publication of this case report and accompanying images. A copy of the written consent is available for review by the Editor-in-Chief of this journal on request.

#### Author contribution

Laparotomy: MW, MT  
 Transcatheter variceal embolization: SG  
 Endoscopic therapy: KO  
 Perioperative management: All authors  
 Paper writing: MW, MT  
 Review: MT, JH

#### Registration of research studies

N/A.

#### Guarantor

Masaki Wakasugi, M. D.

#### Provenance and peer review

Not commissioned, externally peer reviewed.

#### References

- [1] A. Sasamoto, J. Kamiya, Y. Nimura, M. Nagino, Successful embolization therapy for bleeding from jejunal varices after choledochojejunostomy: report of a case, *Surg. Today* 40 (2010) 788–791.
- [2] Y. Saeki, K. Ide, H. Kakizawa, M. Ishikawa, H. Tashiro, H. Ohdan, Controlling the bleeding of jejunal varices formed at the site of choledochojejunostomy: report of 2 cases and a review of the literature, *Surg. Today* 43 (2013) 550–555.
- [3] R.A. Agha, M.R. Borrelli, R. Farwana, K. Koshy, A. Fowler, D.P. Orgill, For the SCARE Group, The SCARE 2018 statement: updating consensus surgical CARE REport (SCARE) guidelines, *Int. J. Surg.* 60 (2018) 132–136.
- [4] J.D. Brierley, M.K. Gospodarowicz, C. Wittekind (Eds.), *TNM Classification of Malignant Tumours*, 8th ed., JOHN WILEY & SONS, LTD, 2017.
- [5] T. Ito, T. Segawa, T. Kanematsu, Successful endoscopic injection sclerotherapy for bleeding from bile duct varices, *Surg. Today* 27 (1997) 174–176.
- [6] D.B. Stafford Johnson, D. Narasimhan, Case report: successful treatment of bleeding jejunal varices using mesoportal recanalization and stent placement: report of a case and review of the literature, *Clin. Radiol.* 52 (1997) 562–565.
- [7] H. Ishida, K. Konno, Y. Hamashima, T. Komatsuda, H. Naganuma, Y. Asanuma, et al., Small bowel varices: report of two cases, *Abdom. Imaging* 23 (1998) 354–357.
- [8] K. Hiraoka, S. Kondo, Y. Ambo, S. Hirano, M. Omi, S. Okushiba, et al., Portal venous dilatation and stenting for bleeding jejunal varices: report of two cases, *Surg. Today* 31 (2001) 1008–1011.
- [9] T. Sato, O. Yasui, T. Kurokawa, M. Hashimoto, Y. Asanuma, K. Koyama, Jejunal varix with extrahepatic portal obstruction treated by embolization using interventional radiology: report of a case, *Surg. Today* 33 (2003) 131–134.
- [10] M. Sakai, A. Nakao, T. Kaneko, S. Takeda, S. Inoue, Y. Yagi, et al., Transhepatic portal venous angioplasty with stenting for bleeding jejunal varices, *Hepatogastroenterology* 52 (2005) 749–752.
- [11] S. Ota, S. Suzuki, H. Mitsuoka, N. Unno, S. Inagawa, Y. Takehara, et al., Effect of a portal venous stent for gastrointestinal hemorrhage from jejunal varices caused by portal hypertension after pancreaticoduodenectomy, *J. Hepatobiliary. Surg.* 12 (2005) 88–92.
- [12] A.M. Smith, R.M. Walsh, J.M. Henderson, Novel bile duct repair for bleeding biliary anastomotic varices: case report and literature review, *J. Gastrointest. Surg.* 9 (2005) 832–836.
- [13] H. Taniguchi, M. Moriguchi, H. Amaike, N. Fuji, Y. Murayama, T. Kosuga, Hemorrhage from varices in hepaticojejunostomy in the fifth and tenth year after surgery for hepatic hilar bile duct cancer: a case report, *Cases J.* 1 (2008) 59.
- [14] J.B. Rezende-Neto, A. Petroianu, S.K. Santana, Subtotal splenectomy and central splenorenal shunt for treatment of bleeding from Roux en Y jejunal loop varices secondary to portal hypertension, *Dig. Dis. Sci.* 53 (2008) 539–543.
- [15] K. Sakurai, R. Amano, A. Yamamoto, N. Nishida, S. Matsutani, K. Hirata, et al., Portal vein stenting to treat portal vein stenosis in a patient with malignant tumor and gastrointestinal bleeding, *Int. Surg.* 99 (2014) 91–95.
- [16] M. Sone, Y. Arai, S. Morita, H. Tomimatsu, S. Sugawara, H. Ishii, Y. Takeuchi, Percutaneous creation of an extraanatomic splenoportal shunt in a patient with bleeding ectopic varices, *J. Vasc. Interv. Radiol.* 25 (2014) 1301–1303.
- [17] S. Kitagawa, T. Sato, M. Kimura, Endoscopic sclerotherapy with a high concentration of n-butyl-2-cyanoacrylate for anastomotic varices after choledochojejunostomy, *Endoscopy* 47 (Suppl 1) (2015), UCTN:E321-2.
- [18] R. Yoshimatsu, T. Yamagami, M. Ishikawa, K. Kajiwara, H. Kakizawa, E. Hiyama, et al., Embolization therapy for bleeding from jejunal loop varices

- due to extrahepatic portal vein obstruction, *Minim. Invasive Ther. Allied Technol.* 25 (2016) 57–61.
- [19] D.R. Kohli, M.F. Levy, G.B. Smallfield, Laparotomy-assisted endoscopic injection of jejunal varices for overt small bowel bleeding, *ACG Case Rep. J.* 4 (2017) e79.
- [20] S. Ali, Asad Ur Rahman, U. Navaneethan, An unusual cause of recurrent gastrointestinal bleeding after Whipple's surgery, *Gastroenterology* 153 (2017) e1–e2.
- [21] Y.J. Wong, F.G. Irani, M. Tan, M. Teo, Massive upper gastrointestinal bleeding post-Whipple's surgery from anastomotic varices due to mesenteric hypertension, *Endoscopy* 50 (2018) E159–62.
- [22] C.J. Heiberger, T.I. Mehta, D. Yim, Jejunal varices: an unconsidered cause of recurrent gastrointestinal haemorrhage, *BMJ Case Rep.* 12 (2019), e228680.
- [23] A.O. Abdalla, M.A. Abdallah, L.A. Calvo, Successful treatment of a case of ectopic jejunal varices with portal venous stenting, *Am. J. Case Rep.* 20 (2019) 948–952.

#### Open Access

This article is published Open Access at [sciencedirect.com](https://www.sciencedirect.com). It is distributed under the [IJSCR Supplemental terms and conditions](#), which permits unrestricted non commercial use, distribution, and reproduction in any medium, provided the original authors and source are credited.