

# Laparoscopic Single Site Adrenalectomy Using a Conventional Laparoscope and Instrumentation

Modesto J Colon, MD, Patrick LeMasters, MD, Phillipa Newell, MD, Celia Divino, MD, Kaare J. Weber, MD, Edward H. Chin, MD

## ABSTRACT

**Background and Objectives:** We present a case of Laparoendoscopic Single Site Surgery (LESS) left adrenalectomy performed with a conventional laparoscope and instruments.

**Methods:** A 45-year-old male was diagnosed with hyperaldosteronism. Computed tomography detected a left adrenal nodule. Bilateral adrenal vein sampling was consistent with a left-sided source for hyperaldosteronism.

**Results:** Total operative time for LESS left adrenalectomy was 120 minutes. The surgery was performed with conventional instruments, a standard 5-mm laparoscope, and a SILS port, with no additional incisions or trocars needed. No complications occurred, and the patient reported an uneventful recovery.

**Conclusions:** LESS adrenalectomy is a feasible procedure. Although articulating instruments and laparoscopes may offer advantages, LESS adrenalectomy can be done without these.

**Key Words:** Laparoscopic adrenalectomy, Laparoendoscopic single site surgery (LESS), Single site surgery.

## INTRODUCTION

In recent years, laparoendoscopic single site surgery (LESS) has become an accepted advance in minimally invasive surgery. This has stimulated the development of roticulating instruments, multi-trocar ports, flexible laparoscopes, and intracorporeal retractors, leading to the perception that specialized equipment is necessary to perform LESS procedures, especially for more difficult operations. We present a case report of LESS adrenalectomy performed with a conventional laparoscope and instruments.

## CASE REPORT

A 45-year-old man with diabetes mellitus and hypertension was diagnosed with hyperaldosteronism. Computed tomography detected a small left adrenal nodule (**Figure 1**). Bilateral adrenal vein sampling was consistent with a left-sided source for hyperaldosteronism, and the patient was referred for left adrenalectomy. The patient's body mass index (BMI) was 26kg/m<sup>2</sup>, and he had no prior surgical history. He was considered an appropriate candidate for minimally invasive adrenalectomy, and specifically LESS adrenalectomy.

## Procedure

The patient was placed in a right lateral decubitus position. A 2.5-cm vertical incision was made within the umbilical ring, through which a SILS (Covidien, Norwalk CT) port was inserted. A standard 5-mm, 30-degree laparoscope was used throughout the procedure in addition to standard 5-mm instruments. Visualization of the left upper quadrant from the umbilical location was adequate. Positioning in a steep reverse Trendelenburg and full lateral tilt was essential to provide exposure and retraction of the left colon and small bowel.

A Harmonic scalpel was used to mobilize the splenic flexure, splenic attachments, and the pancreatic tail. The left renal vein was exposed, followed by dissection of the adrenal vein (**Figure 2**). The vein was secured using locking, polymer clips, and then divided. Once the adrenal gland was completely separated from the upper pole of the kidney and retroperitoneum, it was removed within

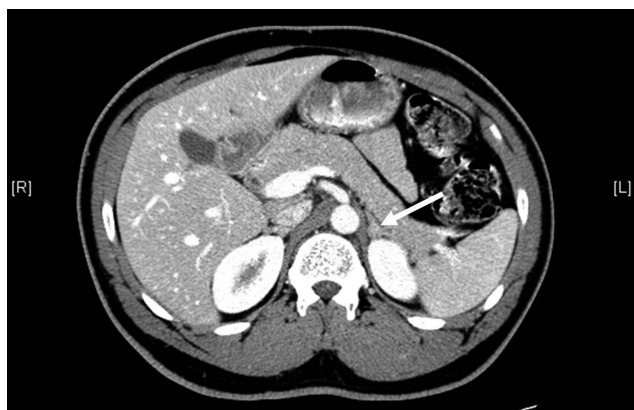Department of Surgery, Mount Sinai School of Medicine, New York, New York, USA (all authors).

Modesto J. Colon attests to full access of all information in the study and takes responsibility for the integrity of the data.

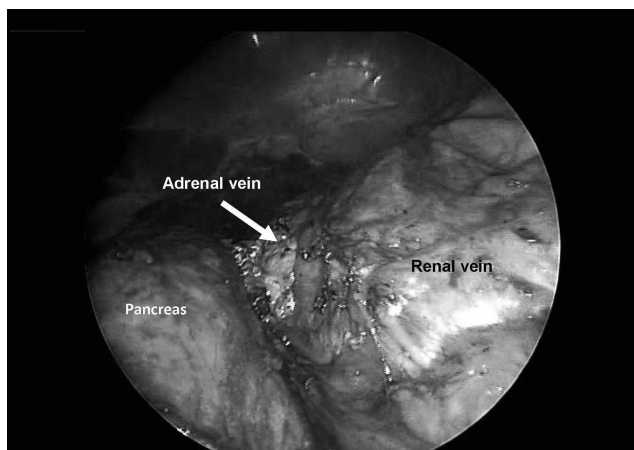
Address correspondence to: Edward H. Chin, MD, FACS, Assistant Professor of Surgery, The Mount Sinai School of Medicine, 5 E. 98th St, Box 1259, New York, New York 10029, USA. Telephone: (212) 241-2115, Fax: (212) 241-5979, E-mail: Edward.chin@mssm.edu

DOI: 10.4293/108680811X13071180407195

© 2011 by JSL, *Journal of the Society of Laparoendoscopic Surgeons*. Published by the Society of Laparoendoscopic Surgeons, Inc.



**Figure 1.** Adrenal mass.



**Figure 2.** Exposure of adrenal and renal veins.

a specimen retrieval bag. Total surgery time was 120 minutes. The patient had an uneventful postoperative course, and was well recovered several weeks later.

## DISCUSSION

Laparoscopic adrenalectomy was first described in 1992 by Gagner et al<sup>1</sup> and has become the preferred treatment option for benign adrenal disorders.<sup>2,3</sup> Significant benefits have been demonstrated for decreased morbidity, length of stay, and recovery compared with open adrenalectomy.<sup>3-6</sup>

Since the introduction of LESS, increasingly difficult procedures are being performed by single-incision laparoscopy. After gaining substantial experience with LESS appendectomy, cholecystectomy, and splenectomy, we embarked on LESS left adrenalectomy. Our prior success with LESS splenectomy, which involves an identical operative field, technical steps, and exposure, made LESS left

adrenalectomy seem feasible. An umbilical location for the laparoscope is quite different from the location used in standard laparoscopic adrenalectomy. While the view is improved by a subcostal location for the laparoscope, the umbilical view is still adequate for adrenalectomy. A supraumbilical placement of the SILS port would improve upon the angle of view, but certainly compromise the ultimate cosmetic outcome. Because our patient was quite short in stature at 5'3", this was not an issue, but for taller patients, the umbilical view may not be adequate.

Cindolo et al<sup>7</sup> reported their initial experience with single-port laparoscopic adrenalectomy, which required an additional port for retraction, and was performed using articulating instruments. In our case, steep reverse Trendelenburg positioning and full lateral tilt were essential to keep the left colon and bowel out of the field. Patients with significant obesity may require an additional port to retract the viscera, but we did not require one.

LESS adrenalectomy was also reported by Jeong et al<sup>8</sup> who used articulating instruments, a flexible laparoscope, and a multi-trocar port. This specialized equipment is not accessible to many surgeons, and we sought a technique where additional instrumentation was kept to a minimum compared to instrumentation used with conventional laparoscopic adrenalectomy.<sup>5</sup>

Our operative time was comparable to published results of LESS adrenalectomy, suggesting that the absence of articulating instruments and laparoscopes was not a significant disadvantage. Our operative time also compares favorably to that in large series of conventional laparoscopic adrenalectomy.<sup>5</sup>

An additional port would likely be required for liver retraction during LESS right adrenalectomy.<sup>7</sup> Intracorporeal retractors are now in development and likely will eliminate the need for an additional port to provide liver retraction.

## CONCLUSION

LESS adrenalectomy can be performed without articulating instruments or flexible laparoscopes.

## References:

1. Gagner M, Lacroix A, Bolte E. Laparoscopic adrenalectomy in Cushing's syndrome and pheochromocytoma. *N Engl J Med.* 1992;327(14):1033.
2. Brunt LM, Doherty GM, Norton JA, et al. Laparoscopic adrenalectomy compared to open adrenalectomy for benign adrenal neoplasms. *J Am Coll Surg.* 1996;183(1):1-10.

3. Ishikawa T, Inaba M, Nishiguchi Y, et al. Laparoscopic adrenalectomy for benign adrenal tumors. *Biomed Pharmacother.* 2000;54 Suppl 1:183s–186s.
4. Lev-Chelouche D, Sagie B, Keidar A, et al. Laparoscopic adrenalectomy: indications, technique, complications and follow-up. *Isr Med Assoc J.* 2003;5(2):101–104.
5. Poulou BK, Holzman MD, Lao OB, et al. Laparoscopic adrenalectomy: 100 resections with clinical long-term follow-up. *Surg Endosc.* 2005;19(3):379–385.
6. Lee J, El-Tamer M, Schiffner T, et al. Open and laparoscopic adrenalectomy: analysis of the National Surgical Quality Improvement Program. *J Am Coll Surg.* 206(5):953–959, 2008; discussion 959–961.
7. Cindolo L, Gidaro S, Neri F, Tamburro FR, Schips L. Assessing feasibility and safety of laparoendoscopic single-site surgery adrenalectomy: initial experience. *J Endourol.* 2010;24:977–980.
8. Jeong BC, Park YH, Han DH, Kim HH. Laparoendoscopic single-site and conventional laparoscopic adrenalectomy: a matched case-control study. *J Endourol.* 2009;23(12):1957–1960.