

Funding source

The authors have no financial obligations or conflict of interest to declare.

A. Mohta,^{1,*} S. K. Jain,² R. D. Mehta,¹ A. Arora¹

¹Department of Dermatology, Venereology and Leprosy, Sardar Patel Medical College, Bikaner, Rajasthan, India, ²Department of Dermatology, Venereology and Leprosy, Government Medical College, Kota, Rajasthan, India

*Correspondence: A. Mohta. E-mail: dralpanamohta10@gmail.com

References

- 1 Kaur SP, Gupta V. COVID-19 vaccine: a comprehensive status report. *Virus Res* 2020; **288**: 198114.
- 2 WHO. Draft Landscape of COVID-19 Candidate Vaccines. (2020). Updated as on 30 April 2021. Available online at: <https://www.WHO.int/publications/m/item/draft-landscape-of-covid-19-candidate-vaccines> [last accessed on May 3, 2021].
- 3 National Co-Win Statistics. Total Vaccination Doses. (2021). Updated as on 3 May 2021. Available online at: <https://dashboard.cowin.gov.in/> [Last accessed on May 3, 2021].
- 4 Cherry JD, Bobinski JE, Horvath FL, Comerci GD. Acute hemangioma-like lesions associated with ECHO viral infections. *Pediatrics* 1969; **44**: 498–502.
- 5 Chopra D, Sharma A, Kaur S, Singh R. Eruptive pseudoangiomatosis - cherry angiomas with perilesional halo. *Indian J Dermatol Venereol Leprol* 2018; **84**: 424–430.
- 6 Provini A, Cacciaguerra MG, Pedicelli C, Annessi G, Palmeri G, Paradisi M. Eruptive pseudoangiomatosis subsequent to vaccination. *Eur J Pediatric Dermatol* 2003; **13**: 141–144.
- 7 Chaniotakis I, Nomikos K, Gamvroulia C, Zioga A, Stergiopoulou C, Basukas ID. Eruptive pseudoangiomatosis: report of an adult case and unifying hypothesis of the pathogenesis of paediatric and adult cases. *Dermatology* 2007; **215**: 59–62.

DOI: 10.1111/jdv.17499

Pernio-like skin lesions after the second dose of Pfizer-BioNTech COVID-19 vaccine

Dear Editor,

We present the case of a 60-year-old patient who reported the onset of pernio-like lesions on both hands, approximately 14 days after the administration of the second dose of the Pfizer-BioNTech vaccine. Local and systemic symptoms such as pain at the injection site, asthenia and headache of mild-to-moderate severity also appeared following the administration of the first and second doses and resolved within 2 days. Physical examination showed erythematous-violaceous patches and swelling on the fingers, accompanied by itching and burning sensation (Fig. 1). The occasional appearance of livedo reticularis-like manifestations on the lower limbs was also referred.

Laboratory tests (complete blood count, antinuclear antibodies, antiphospholipid antibodies, C-reactive protein, erythrocyte sedimentation rate, serum protein electrophoresis and serum cryoglobulins) were normal, excluding the presence of concomitant systemic diseases.

Given the association between the new onset of pernio-like manifestations and COVID-19 infection,¹ a polymerase chain reaction test for COVID-19 was performed with a negative result.

Pernio or chilblains is an inflammatory condition, frequently affecting women, characterized by erythema and swelling that commonly occur in response to cold on acral regions.

Pernio lesions are generally idiopathic and, in some cases, secondary to other diseases such as systemic lupus erythematosus. Skin biopsy is generally not performed as this clinical condition is not characterized by specific histopathology. In fact, in the reported case no skin biopsy was performed and the diagnosis was clinical. Raynaud's phenomenon, cryoglobulinemia, acrocyanosis and cold panniculitis should be considered in the differential diagnosis.²

Management of pernio skin lesions consists of avoiding exposure to cold and the use of corticosteroids and vasodilatory agents such as nifedipine.³

During the COVID-19 pandemic, an increase in the occurrence of pernio-like acral lesions was highlighted,⁴ and therefore, a correlation between COVID-19 infection and this cutaneous eruption has been hypothesized.⁵

A large international registry-based case series of 318 patients with pernio-like lesions and confirmed or suspected COVID-19 infection showed that skin manifestations were only on the feet in 84% of patients and only on the hands in 5.1% of patients.⁶

The pathogenetic mechanisms that have been proposed to explain the association between COVID-19 and pernio-like eruptions suggest an increase in vasospasm, and pro-inflammatory and prothrombotic activity of the angiotensin II pathway, triggered by cellular infection; furthermore, a massive release of type I interferon could be involved.³

In the reported case, the pernio-like manifestations occurred 2 weeks after the administration of the second dose of the Pfizer-BioNTech vaccine. The patient had never experienced chilblain-like eruptions before; therefore, it cannot be excluded that these manifestations were related to the vaccine.

Pfizer-BioNTech vaccine, administered intramuscularly in two injections 21 days apart, is a nucleoside-modified RNA encoding the SARS-CoV-2 spike protein, which stimulates the production of SARS-CoV-2 neutralizing antibodies and an immune response mediated by antigen-specific Th1-type CD4⁺ T cells and CD8⁺ T cells.^{7–9} The main cutaneous reactions reported in patients who received the mRNA COVID-19 vaccines were reactions at the injection site, urticaria and morbilliform eruption; more rarely have been observed cosmetic filler reactions, zoster and herpes simplex flares, pityriasis rosea-like reactions and pernio eruptions.¹⁰

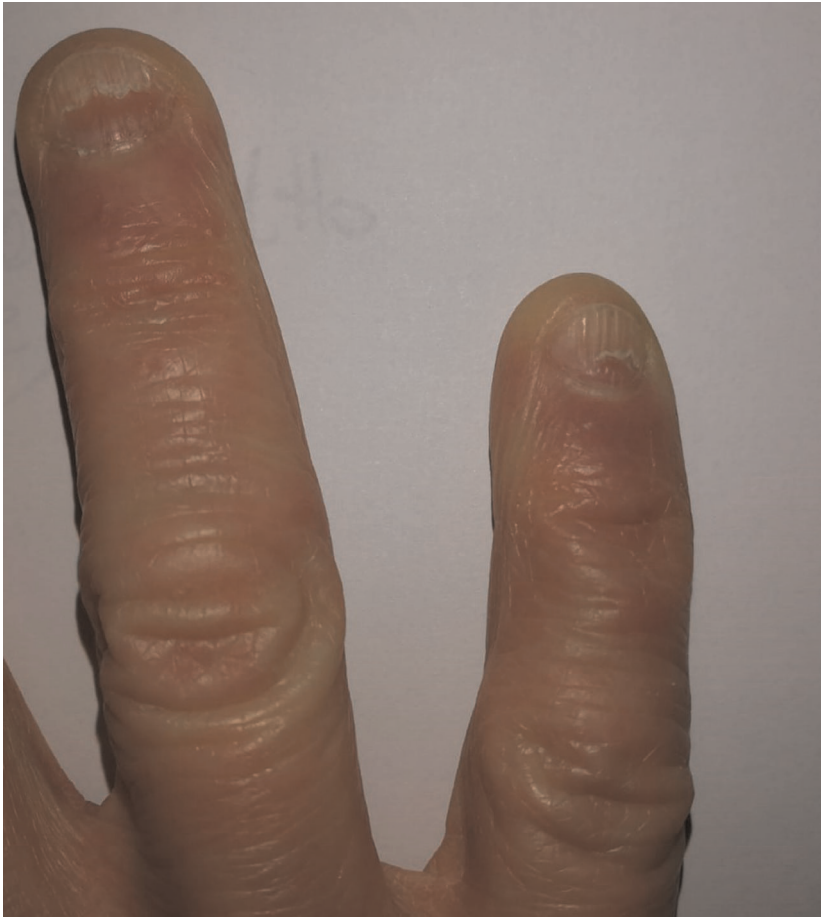

Figure 1 Pernio-like lesions on the fingers of right hand after the second dose of Pfizer-BioNTech vaccine.

At the present, only a few cases of pernio-like skin lesions induced by mRNA COVID-19 vaccines have been reported and, in particular, five cases have been observed after the Pfizer-BioNTech vaccine.¹⁰ This case, together with those already reported in the literature, raises the question of whether the vaccine-elicited immune response could be involved in the development of pernio-like manifestations, as it has been described following COVID-19 infection.



It is important for the dermatologist to recognize such clinical findings in order to provide a proper diagnosis and therapeutic management.

Conflicts of interest

None to declare.

Acknowledgement

The patient in this manuscript has given written informed consent to the publication of her case details.

N. Cameli,¹ M. Silvestri,² M. Mariano,^{1,*}  S.P. Nisticò,²
A. Cristaudo¹ 

¹San Gallicano Dermatological Institute - IRCCS, Rome, Italy,

²Department of Health Sciences, Unit of Dermatology, Magna Graecia University, Catanzaro, Italy

*Correspondence: M. Mariano. E-mail: maria.mariano@ifg.gov.it

References

- Piccolo V, Neri I, Filippeschi C *et al*. Chilblain-like lesions during COVID-19 epidemic: a preliminary study on 63 patients. *J Eur Acad Dermatol Venereol* 2020; **34**: e291–e293.
- Whitman PA, Crane JS. Pernio. In: StatPearls [Internet]. StatPearls Publishing, Treasure Island, FL, 2021.
- Cappel JA, Wetter DA. Clinical characteristics, etiologic associations, laboratory findings, treatment, and proposal of diagnostic criteria of pernio (chilblains) in a series of 104 patients at Mayo Clinic, 2000 to 2011. *Mayo Clin Proc* 2014; **89**: 207–215.
- Piccolo V, Bassi A, Russo T *et al*. Chilblain-like lesions and COVID-19: second wave, second outbreak. *J Eur Acad Dermatol Venereol* 2021; **35**: e316–e318.
- Genovese G, Moltrasio C, Berti E, Marzano AV. Skin manifestations associated with COVID-19: current knowledge and future perspectives. *Dermatology* 2021; **237**: 1–12.
- Freeman EE, McMahon DE, Lipoff JB *et al*. Pernio-like skin lesions associated with COVID-19: a case series of 318 patients from 8 countries. *J Am Acad Dermatol* 2020; **83**: 486–492.

- 7 Rubin EJ, Longo DL. SARS-CoV-2 vaccination - an ounce (actually, much less) of prevention. *N Engl J Med* 2020; **383**: 2677–2678.
- 8 Sahin U, Muik A, Vogler I *et al.* BNT162b2 induces SARS-CoV-2-neutralising antibodies and T cells in humans, 2020. URL <https://www.medrxiv.org/content/10.1101/2020.12.09.20245175v1>. preprint.
- 9 Polack FP, Thomas SJ, Kitchin N *et al.* Safety and efficacy of the BNT162b2 mRNA Covid-19 vaccine. *N Engl J Med* 2020; **383**: 2603–2615.
- 10 McMahon DE, Amerson E, Rosenbach M *et al.* Cutaneous reactions reported after Moderna and Pfizer COVID-19 vaccination: a registry-based study of 414 cases. *J Am Acad Dermatol* 2021; **85**: 46–55.

DOI: 10.1111/jdv.17500

New onset of remitting seronegative symmetrical synovitis with pitting oedema and palmoplantar psoriasis flare-up after Sars-Cov-2 vaccination

Dear Editor,

An 83-year-old woman referred to the dermatology division of our hospital because of recent acute onset of stiffness with limitation in basic activities of daily living and pain, swelling and palmar skin eruption of both hands. All symptoms showed up 48 h after the second administration of BNT162b2 Pfizer/BioNTech® Sars-Cov-2 vaccine.

The patient presented with a history of palmoplantar psoriasis since 1996, in long-standing remission with methotrexate (MTX) 10 mg every 10 days. She took also anti-hypertensive and oral antidiabetic medications. She had no history of rheumatic or allergic diseases.

At physical examination, both hands on palmar side showed psoriasis with erythematous, scaly plaques, while on dorsum and wrist joints, painful oedema was present. Dactylitis was also detected in all fingers associated with severe functional impairment (Fig. 1a,b). Musculoskeletal ultrasound (MSUS) revealed tenosynovitis of the digital extensor tendon and the carpal extensor tendon of wrists based on the presence of hypoechoic signals around the tendon sheath with power Doppler signal both in transverse and in longitudinal planes (Fig. 2a,b). Acute phase reactants were elevated, rheumatoid factor was negative, and X-rays revealed no joint erosions. The scenario indicated a flare-up of palmar psoriasis associated with the onset of psoriatic arthritis with remitting seronegative symmetrical synovitis with pitting oedema (RS3PE). The patient started oral prednisone (25 mg once daily) and increased MTX dosage (10 mg weekly), with a rapid clinical improvement.

New onset or exacerbation of psoriatic disease following vaccinations, though rare, is reported in literature. To date, the

cases of psoriasis flare-up have been described with influenza, pneumococcal polysaccharide, Bacillus Calmette–Guerin (BCG) and tetanus–diphtheria vaccines.^{1–3}

In this case, the close temporal link between Sars-Cov-2 vaccination and the onset of psoriasis flare-up associated with joint involvement suggests a possible causal association between the two events.

It is known that vaccination itself triggers an IFN-gamma and TNF- α release from Th1 cells,⁴ which could represent a possible mechanism for vaccination-induced psoriatic disease.

Polyethylene glycol (PEG) – one of the compounds of BNT162b2 – could also have been the cause for the systemic reaction observed, acting as the antigen that activated the immune pathway as reported in other cases.⁵

RS3PE syndrome is characterized by symmetrical synovitis and swelling of both the upper and lower extremities. RS3PE syndrome may overlap several rheumatic disorders such as polymyalgia rheumatica, rheumatoid or psoriatic arthritis,

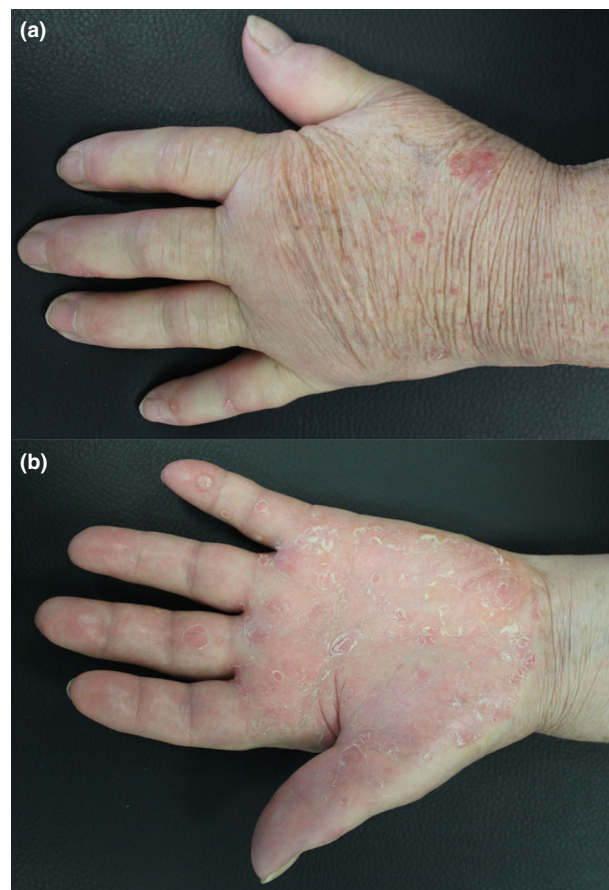

Figure 1 (a) Erythema and desquamation on the palm of left hand. (b) Oedema on the back of left hand and wrist joint.