

Symptomatic cerebral vasospasm following posterior fossa hemangioblastoma resection: illustrative case

Abhiram D. Hiwase,¹ Kaviya Kalyanasundaram,¹ Vi-Seth Bak,¹ Stephanie M. Laden,¹ Christopher D. Oviden, MBBS,² and Adam J. Wells, MBBS Hons, PhD, FRACS²

¹Adelaide Medical School, University of Adelaide, Adelaide, South Australia, Australia; and ²Department of Neurosurgery, Royal Adelaide Hospital, Adelaide, South Australia, Australia

BACKGROUND Symptomatic cerebral vasospasm following posterior fossa intra-axial tumor resection is a rare phenomenon with only seven cases previously reported in the literature. The condition appears distinct to vasospasm following supratentorial tumor resection and extra-axial tumor resection of the posterior fossa. It shares, however, similarities with vasospasm following aneurysmal subarachnoid hemorrhage.

OBSERVATIONS The authors describe their experience with a 23-year-old female who developed delayed symptomatic vasospasm following resection of a left paraventricular cerebellar hemangioblastoma. Tumor resection was complicated by rupture of a fragile arterialized vein, resulting in significant hemorrhage. The patient developed several episodes of focal and variably reversible neurological deficit. These clinical signs corresponded with angiographically confirmed vasospasm, which responded to standard therapies for vasospasm post aneurysmal subarachnoid hemorrhage.

LESSONS This case and literature review highlight that symptomatic vasospasm is a rare, potentially highly morbid complication of posterior fossa intra-axial tumor resection. This phenomenon may be related to significant intraoperative or postoperative hemorrhage. Postoperative radiological findings such as high risk modified Fisher scale hemorrhage could alert clinicians to this condition.

<https://thejns.org/doi/abs/10.3171/CASE21492>

KEYWORDS cerebral vasospasm; tumor; posterior cranial fossa; neurosurgery

Although a well-known and highly morbid complication of aneurysmal subarachnoid hemorrhage (aSAH), cerebral vasospasm has been reported as a rare complication of intracranial tumor resection, with 40 cases identified in a 2013 systematic review.¹ Since this time a greater appreciation for this phenomenon has occurred, and further cases have been reported. Our literature review sourcing English articles from PubMed until December 3, 2021 has identified 19 cases^{2–17} of symptomatic vasospasm following posterior fossa tumor resection, as well as two case series of asymptomatic vasospasm documenting a total of 70 cases.^{18,19} Overall, a minority of these cases occur following resection of intra-axial posterior fossa tumors, with only seven cases reported.^{2–8} The characteristics of vasospasm observed in cases of intra-axial posterior fossa tumor

resection differs from those seen in tumor resection at other sites. All cases were symptomatic, and vasospasm occurred bilaterally and involved vascular territories remote to the surgical resection. This remote and diffuse distribution of vasospasm is less commonly observed in vasospasm associated with extra-axial and supratentorial tumor resections.¹ Moreover, factors such as hypothalamic dysfunction²⁰ and intraoperative vessel manipulation,^{21,22} which are associated with vasospasm following supratentorial and extra-axial tumor resection, were not described in the intra-axial posterior fossa cases. The unique manifestations and rarity of vasospasm following intra-axial posterior fossa tumor resection lends to delays in recognition, which may be associated with worse outcomes.¹² We describe our experience with an additional case, in which a patient

ABBREVIATIONS aSAH = aneurysmal subarachnoid hemorrhage; CT = computed tomography; CTA = computed tomography angiogram; DSA = digital subtraction angiography; ICU = intensive care unit; MCA = middle cerebral artery; mFS = modified Fisher scale; MRI = magnetic resonance imaging; MRS = modified Rankin scale; SAH = subarachnoid hemorrhage.

INCLUDE WHEN CITING Published March 28, 2022; DOI: 10.3171/CASE21492.

SUBMITTED August 29, 2021. **ACCEPTED** January 27, 2022.

© 2022 The authors, CC BY-NC-ND 4.0 (<http://creativecommons.org/licenses/by-nc-nd/4.0/>).

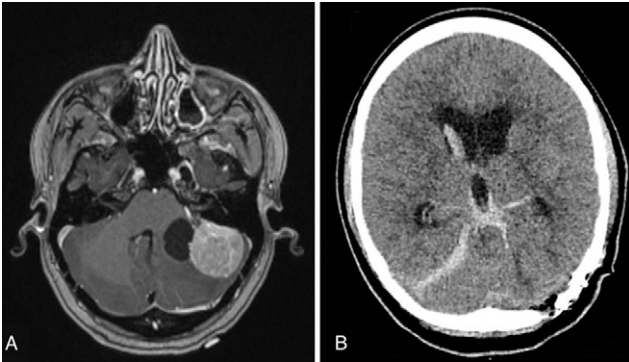


FIG. 1. A: Preoperative magnetic resonance axial section demonstrating tumor enhancement adjacent to a well-circumscribed void region. **B:** Immediate postoperative computed tomography axial section demonstrating mFS 4 hemorrhage.

developed delayed and aggressive cerebral vasospasm following resection of a posterior fossa hemangioblastoma.

Illustrative Case

An independent 23-year-old female with unremarkable medical history presented with a 12-month history of progressive headaches. Magnetic resonance imaging (MRI) scan identified a large left paravertebra cerebellar lesion with a contrast enhancing mural nodule and a smaller medially located cyst consistent with a hemangioblastoma (Fig. 1A). There were no other lesions identified on imaging her whole neuraxis. The tumor was approached via a left retrosigmoid craniotomy. The tumor was highly vascular with multiple draining arterialized veins; all peripheral arterial feeders were systematically obliterated, and the tumor was resected en bloc. Following tumor removal, a large fragile arterialized superior petrosal vein ruptured, producing significant arterial hemorrhage, with hemostasis ultimately achieved with packing and hemostatic agents. There were no further intraoperative complications.

An immediate postoperative noncontrast computed tomography (CT) scan was performed that demonstrated acute blood within her basal cisterns, ventricular system, and a midline hematoma adjacent to the superior cerebellar vermis (Fig. 1B). Upon extubation

she was oriented and obeying commands but demonstrated a left upper limb monoparesis and partial left sixth nerve palsy.

On postoperative day 6 the patient had a decline in conscious state. Computed tomography angiogram (CTA) demonstrated vasospasm of the left middle cerebral artery (MCA) territory (Fig. 2A). The patient was readmitted to the intensive care unit (ICU) for hypertensive therapy with return of consciousness.

Over the coming days the patient experienced fluctuating neurological function, with several episodes of acute neurological deterioration attributed to angiographically confirmed vasospasm in bilateral anterior and posterior circulation territories (Fig. 2B and C). Nimodipine delivered via nasogastric tube, direct injection of intra-arterial verapamil with invasive angiography, and microcatheter angioplasty were used with varying success to manage the episodes of vasospasm. Noradrenaline and saline infusion were used to maintain a mean arterial pressure of >100 mm Hg in the ICU. The patient ultimately demonstrated gradual clinical improvement and was transferred to a general ward on postoperative day 23. The patient was discharged to a rehabilitation facility on day 38 with modified Rankin scale (mRS) 4 graded disability. Outpatient follow-up at 3 months identified a stable level of disability.

Discussion

Cerebral vasospasm following tumor resection is a rare phenomenon. Nineteen cases of symptomatic cerebral artery vasospasm have been detected from tumor resection in the posterior fossa (Tables 1 and 2). Seven of these cases follow the resection of intra-axial tumors. There are several proposed mechanisms for this phenomenon. High arterial blood load in the subarachnoid space,²³ hypothalamic dysfunction, and vessel injury or manipulation¹² are suggested in the literature. Vascular encasement and manipulation are believed to be more relevant to extra-axial tumor resection, and hypothalamic insult is considered to have a greater role in vasospasm following suprasellar and middle cranial fossa resection.¹ Vasospasm following posterior fossa intra-axial tumor resection appears to be related to high-volume arterial subarachnoid hemorrhage, drawing similarities with vasospasm following aSAH. In aSAH, the release of vasoactive arterial blood products into the cerebrospinal fluid is thought to irritate both local and distant vasculature.²⁴ Complex interactions then promote vasospasm²⁵ that largely manifests 3 to 14 days following aSAH.²⁶ The presence of

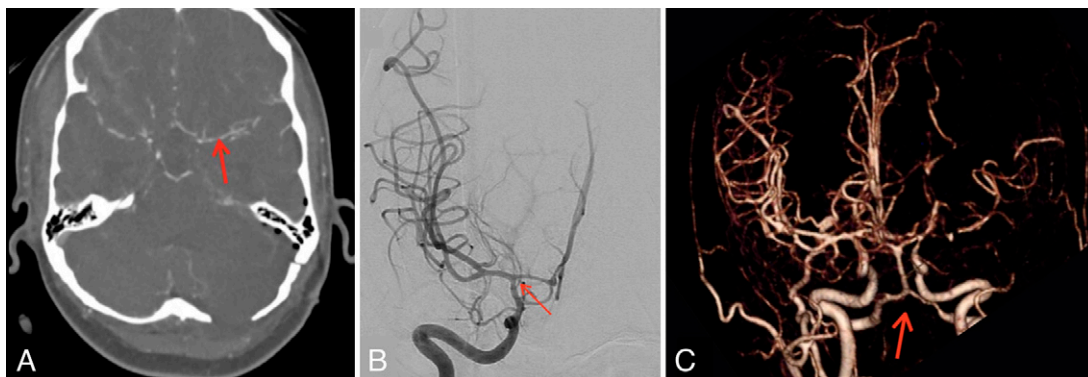


FIG. 2. A: Day 6 computed tomography angiogram with focal area of proximal left middle cerebral artery stenosis (red arrow). **B:** Day 9 digital subtraction angiography showing minor vasospasm of the right carotid (red arrow). **C:** Day 7 angiographic reconstruction demonstrating mild bilateral intracranial vertebral and basilar artery vasospasm (red arrow).

TABLE 1. Symptomatic vasospasm characteristics following intra-axial posterior fossa tumor resection

Authors & Year	Tumor Type	Sex	Age	Postoperative Day at Vasospasm Diagnosis*	Intraoperative or Early Postoperative Bleeding as Evidenced by Postoperative CT Imaging	Relative Morbidity at Last FU†
Brau et al., 1986 ²	Posterior fossa epidermoid tumor	F	57 yrs	15	None evident	Disability
Dalvi et al., 2014 ³	Grade IV medulloblastoma	M	17 yrs	16	Insufficient information to comment	Recovery
Gocmen et al., 2021 ⁴	Vermis & fourth ventricle medulloblastoma	F	9 yrs	13	Insufficient information to comment	Recovery
Jacob et al., 2011 ⁵	Grade II ependymoma	M	23 yrs	12	mFS 4	Recovery
Kinoshita et al., 2020 ⁶	Hemangioblastoma	F	62 yrs	1	None evident	Disability
Lee et al., 1998 ⁷	Primitive neuroectodermal tumor (PNET) with epithelioid & neuronal differentiation	F	15 mos	17	Insufficient information to comment	Death
Prontera et al., 2014 ⁸	Hemangioblastoma (VHL)	F	35 yrs	12	mFS 4	Disability
Present case	Hemangioblastoma	F	23 yrs	6	mFS 4	Disability

CT = computed tomography; FU = follow-up.

* Defined as day of angiographic confirmation of vasospasm.

† Compared to status preceding the first diagnosed episode of vasospasm.

vasospasm in vascular territories remote to the site of tumor resection, the time delay from surgery, and the high perioperative blood load observed in some cases following intra-axial posterior fossa tumor resection echoes vasospasm post-aSAH. Recognizing this association may allow management strategies already utilized for aSAH to be applied in select patients post-tumor resection.

Observations

Vasospasm was found to be bilateral in all seven previously reported cases of vasospasm post intra-axial tumor resection, and in the case we encountered. A comparatively smaller proportion of vasospasm post extra-axial tumor resection occurred bilaterally, with five^{9,13,14,16,17} of 12 cases demonstrating this. To the best of our knowledge, neither direct vessel manipulation nor hypothalamic injury occurred in these eight cases of vasospasm post intra-axial tumor resection. Rather, three of these total eight cases identified notable perioperative hemorrhage, each graded as equivalent to modified Fisher scale (mFS) 4 by two members of our team (Table 1).^{5,8} There is a 40% risk of clinical vasospasm in aSAH with mFS 4 hemorrhage,²⁷ and it is possible that the same degree of perioperative hemorrhage following posterior fossa tumor resection carries similar vasospasm risk. Of the three cases with mFS 4 equivalent hemorrhage, two had hemangioblastoma related intraoperative bleeding, and in the other case hemorrhage occurred on postoperative day 2. Hemorrhage preceded recognition of vasospasm between 6 and 12 days in these cases, mirroring the interval between aSAH and subsequent vasospasm frequently described.²⁶

In the remaining five cases there was limited imaging-based evidence of intraoperative hemorrhage. The authors in one case stated that their

postoperative imaging was potentially too late to detect subarachnoid blood,² and another described 100 mL of intraoperative bleeding related to tumor resection.⁴ In both instances, the authors recognized hemorrhage as a potential etiology of vasospasm, and vasospasm was diagnosed at postoperative day 15 and 13, respectively. In the remaining three cases, the authors denied the presence of significant perioperative hemorrhage,^{3,6,7} instead proposing a potential paraneoplastic etiology in one,⁷ and the release of tumor cyst products in another.⁶

In the 12 cases of symptomatic vasospasm following extra-axial posterior fossa tumor resection (Table 2), there were five cases in which significant perioperative hemorrhage was noted.^{10,13,15,17} In three of these cases vasospasm occurred contralateral to the site of the tumor resection,^{10,13,17} possibly supporting the mechanism of vasoactive product release producing distant vasospasm. Furthermore, the interval between vasospasm and hemorrhage ranged between three and 14 days, echoing aSAH-related vasospasm. Notably, vessel manipulation occurred in one of these cases, and may be responsible for the early vasospasm seen on day 3.¹⁷ In the remaining eight cases in which the presence of perioperative hemorrhage was not explicit, only two gave evidence for a lack of hemorrhage. One stated that there was minimal intraoperative bleeding,⁹ and the other provided a postoperative MRI demonstrating minimal hemorrhage.¹⁶ Despite no specific mention of perioperative hemorrhage occurring in three individual cases reported within one case series,¹² the authors noted that intraoperative hemorrhage was marked in many of their cases. These authors also observed that preoperative embolization was a statistically significant risk factor for vasospasm and hypothesized that this may result from a selection bias and predisposition to intraoperative hemorrhage in cases in which preoperative embolization is utilized.¹²

TABLE 2. Symptomatic vasospasm characteristics following extra-axial posterior fossa tumor resection

Authors & Year	Total No. of Cases	Tumor Location & Type	Age (yrs), Sex	Postoperative Day at Vasospasm Diagnosis	Location of Vasospasm as Identified by Angiogram (unless otherwise specified)	Vascular Manipulation or Tumor Encasement of Vessels Found to Undergo Vasospasm	Intraoperative or Early Postoperative Bleeding as Evidenced by Postoperative CT Imaging or Author Report	Relative Morbidity at Last FU*
Afshari et al., 2014 ⁹	1	Lt hypoglossal schwannoma	9, F	8	Bilateral ICA, MCA, & ACA.	Authors denied manipulation.	Intraoperative bleeding reported to be minimal.	Recovery
Almeida et al., 1985 ¹⁰	1	Rt acoustic neuroma	26, M	14	Lt ICA, ACA, & MCA.	Authors denied manipulation.	Significant intraoperative blood loss. No further distinction provided by authors.	Disability
Aw et al., 2010 ¹¹	1	Lt CPA epidermoid cyst	43, M	14	Rt MCA, ICA, & VA.	No comment made by authors.	Insufficient information to comment.	Disability
Bejjani et al., 1999 ¹²	3	Lt foramen magnum meningioma	65, F	15	Rt VA & BA.	VBA encased by tumor.	Insufficient information to comment.	Disability
Cervoni et al., 1996 ¹³	1	Lt anterior, middle & posterior fossae meningioma	57, M	1	Rt MCA (M1 segment).	Tumor encased ICA & VBA bilaterally. ICA narrowing bilaterally.	Insufficient information to comment.	Insufficient information to comment.
LeRoux et al., 1991 ¹⁴	1	Lt CPA acoustic neuroma	69, M	7	Bilateral VA, BA, & Rt ICA. Identified by TCD.	No comment made by authors.	Copious intraoperative blood loss from cavernous sinus. No further distinction provided by authors.	Disability
Pan et al., 2021 ¹⁵	2	Rt cavernous sinus, middle & posterior cranial fossae chondrosarcoma	63, M	10	BA.	No comment made by authors.	Postoperative CT indicated subdural & subarachnoid hemorrhage, attributed to bleeding vein.	Disability
Rao et al., 2013 ¹⁶	1	Rt CPA anaplastic medulloblastoma	10, F	10	Bilateral PCA & MCA. Lt ACA.	No comment made by authors.	Insufficient information to comment.	Recovery
Qi et al., 2015 ¹⁷	1	Lt ventral medulla oblongata schwannoma	16, M	3	Bilateral siphon segment of ICA & BA.	Authors suggested direct mechanical trauma may have been responsible for vasospasm.	Intraoperative ACA perforator bleed requiring clipping. 2 cm hematoma removed intraoperatively.	Insufficient information to comment.

ACA = anterior cerebral artery; BA = basilar artery; CT = computed tomography; ICA = internal carotid artery; VA = vertebral artery.

* Compared to status preceding the first diagnosed episode of vasospasm.

TABLE 3. Asymptomatic vasospasm characteristics following extra-axial posterior fossa tumor resection

Authors & Year	Total No. of Cases	Tumor Location & Type	Sex (no.); Average Age (yrs)	Postoperative Day at Vasospasm Diagnosis	Location of Vasospasm as Identified by Angiogram (unless otherwise specified)	Vascular Manipulation or Tumor Encasement of Vessels Found to Undergo Vasospasm	Intraoperative or Early Postoperative Bleeding as Evidenced by Postoperative CT Imaging or Author Report
Tao et al., 2016 ¹⁸	27	Foramen magnum in location; 15 meningioma, 8 schwannomas, 2 neurenteric cysts, 2 not specified	12 M, 15 F; 44.5	Average interval of 3.5 days	Vertebrobasilar vasospasm in all cases, 23 cases identified by TCD alone, 4 cases confirmed w/ CTA	Vessel encasement apparent in 12 cases	4 (14.8%) cases described as having severe (>600 mL) intraoperative blood loss
Qi et al., 2015 ¹⁹	43	Acoustic neuroma (laterality not specified)	15 M, 28 F; 43.5	Median day of detection not specified	ICA, MCA, or ACA in all patients, identified by TCD	No comment made by author	Authors note that blood loss was <400 mL in all patients; patients w/ evidence of postoperative bleeding on CT were excluded from analysis

ACA = anterior cerebral artery; CT = computed tomography; ICA = internal carotid artery; TCD = transcranial Doppler.

Despite a potential role of hemorrhage in symptomatic vasospasm, this is not clearly evident in two case series of asymptomatic vasospasm post-posterior fossa tumor resection (Table 3).^{18,19} Together, the two series reported 70 cases, and identified younger patient age, large tumor size, vessel encasement, and adhesion to the brainstem or trigeminal nerve as risk factors for vasospasm.^{18,19} In one series (n = 27), the role of hemorrhage was found to have poor correlation with subsequent risk of vasospasm.¹⁸ In the other study (n = 43), cases with postoperative imaging demonstrating hemorrhage were excluded from reporting.¹⁹

The experience from our case and the available literature suggests that high-volume arterial blood within the subarachnoid space may contribute to symptomatic vasospasm post-posterior fossa tumor resection. In potential support of this are the observed similarities with vasospasm following aSAH, such as the presence and extent of bleeding prior to vasospasm and the time to onset and distribution of vasospasm. Recognizing this connection may increase efforts to mitigate perioperative hemorrhage. In instances in which hemangioblastoma is suspected, preoperative embolization may be considered to limit intraoperative hemorrhage. Preoperative embolization has well-recognized risks, with one meta-analysis concluding that routine preoperative embolization is not recommended for hemangioblastoma,²⁸ however, benefit may be seen in large tumors and those with targetable feeding vessels.²⁹ Additionally, preoperative endocrinological assessment may be indicated where there is suspicion of Von Hippel-Lindau syndrome, as the presence of associated pheochromocytoma without appropriate precautions may precipitate intraoperative hypertensive crisis and greater risk of intraoperative hemorrhage. Furthermore, routine strategies in the prediction and management of post aSAH vasospasm could be used in select cases of tumor resection in which large-volume perioperative hemorrhage is observed.

Lessons

Vasospasm is a rare, potentially highly morbid complication of posterior fossa intra-axial tumor resection. It is possibly related to significant perioperative hemorrhage with high arterial blood load.

Copious subarachnoid blood may alert clinicians to vasospasm following intra-axial posterior fossa tumor resection. Methods used in the management of vasospasm post-aSAH may also be used to recognize and manage this condition.

Acknowledgments

Adam James Wells is the Neurosurgical Research Foundation Abbie Simpson Clinical Fellow (2019–2021).

References

- Alotaibi NM, Lanzino G. Cerebral vasospasm following tumor resection. *J Neurointerv Surg*. 2013;5(5):413–418.
- Brau RH, Lameiro J, Llaguno AV, Rifkinson N. Metamorphopsia and permanent cortical blindness after a posterior fossa tumor. *Neurosurgery*. 1986;19(2):263–266.
- Dalvi N, Jacob C, Karkare S. PT-03: prolonged vasospasm following posterior fossa tumor resection: a case report. *Neuro Oncol*. 2014;16(Suppl 5):v175.
- Gocmen S, Acka G, Karaman K, Kahraman S. Cerebral vasospasm after posterior fossa tumor surgery: a case report and literature review. *Pediatr Neurosurg*. 2020;55(6):393–398.
- Jacob JT, Hunt CH, Wijdicks EF, Rabinstein AA, Cloft H, Link MJ. Diffuse cerebral vasospasm after resection of a posterior fossa ependymoma. *Neurocrit Care*. 2011;14(1):86–90.
- Kinoshita Y, Sato K, Ito T, Nakamura H. Diffuse cerebral vasospasm after removal of a posterior fossa hemangioblastoma in a 62-year-old woman. *World Neurosurg*. 2020;143:97–101.
- Lee TT, Ragheb J, Bruce JC, Altman N, Morrison G. Diffuse cerebral vasospasm with ischemia after resection of a cerebellopontine angle primitive neuroectodermal tumor in a child. *Pediatr Neurosurg*. 1998;29(6):300–303.
- Prontera A, Puzzolante A, Carpeggiani P, Pavesi G. Symptomatic anterior cerebral artery vasospasm after brainstem hemangioblastoma resection. A case report. *Neuroradiol J*. 2014;27(2):186–190.
- Afshari FT, Fitzgerald JJ, Higgins JN, Garnett MR, Fernandes HM, Santarius T. Diffuse cerebral vasospasm following resection of a hypoglossal schwannoma in a child. *Br J Neurosurg*. 2014;28(4):541–543.

10. de Almeida GM, Bianco E, Souza AS. Vasospasm after acoustic neuroma removal. *Surg Neurol.* 1985;23(1):38–40.
11. Aw D, Aldwaik MA, Taylor TR, Gaynor C. Intracranial vasospasm with delayed ischaemic deficit following epidermoid cyst resection. *Br J Radiol.* 2010;83(991):e135–e137.
12. Bejjani GK, Sekhar LN, Yost AM, Bank WO, Wright DC. Vasospasm after cranial base tumor resection: pathogenesis, diagnosis, and therapy. *Surg Neurol.* 1999;52(6):577–584.
13. Cervoni L, Salvati M, Santoro A. Vasospasm following tumor removal: report of 5 cases. *Ital J Neurol Sci.* 1996;17(4):291–294.
14. LeRoux PD, Haglund MM, Mayberg MR, Winn HR. Symptomatic cerebral vasospasm following tumor resection: report of two cases. *Surg Neurol.* 1991;36(1):25–31.
15. Pan J, Levitt MR, Ferreira M Jr, Sekhar LN. Symptomatic cerebral vasospasm following resection of skull base tumors: case report and literature review. *Clin Neurol Neurosurg.* 2021;202:106482.
16. Rao VK, Haridas A, Nguyen TT, Lulla R, Wainwright MS, Goldstein JL. Symptomatic cerebral vasospasm following resection of a medulloblastoma in a child. *Neurocrit Care.* 2013;18(1):84–88.
17. Qi J, Zhang L, Jia W, Zhang J, Wu Z. Diffuse cerebral vasospasm after resection of schwannoma: a case report. *Neuropsychiatr Dis Treat.* 2015;11:317–320.
18. Tao C, Wang J, Zhang Y, Qi S, Liu F, You C. Predictors of acute vertebrobasilar vasospasm following tumor resection in the foramen magnum region. *PLoS One.* 2016;11(9):e0163908.
19. Qi J, Jia W, Zhang L, Zhang J, Wu Z. risk factors for postoperative cerebral vasospasm after surgical resection of acoustic neuroma. *World Neurosurg.* 2015;84(6):1686–1690.
20. Wilkins RH. Hypothalamic dysfunction and intracranial arterial spasms. *Surg Neurol.* 1975;4(5):472–480.
21. Sindou MP, Alaywan M. Most intracranial meningiomas are not cleavable tumors: anatomic-surgical evidence and angiographic predictability. *Neurosurgery.* 1998;42(3):476–480.
22. Chang SD, Yap OW, Adler JR Jr. Symptomatic vasospasm after resection of a suprasellar pilocytic astrocytoma: case report and possible pathogenesis. *Surg Neurol.* 1999;51(5):527.
23. Fisher CM, Kistler JP, Davis JM. Relation of cerebral vasospasm to subarachnoid hemorrhage visualized by computerized tomographic scanning. *Neurosurgery.* 1980;6(1):1–9.
24. Allen GS, Gross CJ, French LA, Chou SN. Cerebral arterial spasm. Part 5: in vitro contractile activity of vasoactive agents including human CSF on human basilar and anterior cerebral arteries. *J Neurosurg.* 1976;44(5):594–600.
25. Dodd WS, Laurent D, Dumont AS, et al. Pathophysiology of delayed cerebral ischemia after subarachnoid hemorrhage: a review. *J Am Heart Assoc.* 2021;10(15):e021845.
26. Weir B, Grace M, Hansen J, Rothberg C. Time course of vasospasm in man. *J Neurosurg.* 1978;48(2):173–178.
27. Frontera JA, Claassen J, Schmidt JM, et al. Prediction of symptomatic vasospasm after subarachnoid hemorrhage: the modified Fisher scale. *Neurosurgery.* 2006;59(1):21–27.
28. Ampie L, Choy W, Lamano JB, et al. Safety and outcomes of preoperative embolization of intracranial hemangioblastomas: a systematic review. *Clin Neurol Neurosurg.* 2016;150:143–151.
29. Sultan A, Hassan T, Aboul-Enein H, Mansour O, Ibrahim T. The value of preoperative embolization in large and giant solid cerebellar hemangioblastomas. *Interv Neuroradiol.* 2016;22(4):482–488.

Disclosures

The authors report no conflict of interest concerning the materials or methods used in this study or the findings specified in this paper.

Author Contributions

Conception and design: Hiwase, Ovenden, Wells. Acquisition of data: Hiwase, Kalyanasundaram, Bak, Laden, Wells. Analysis and interpretation of data: Hiwase, Ovenden, Wells. Drafting the article: Hiwase, Laden, Ovenden. Critically revising the article: Hiwase, Laden, Ovenden, Wells. Reviewed submitted version of manuscript: Hiwase, Bak, Laden, Ovenden, Wells. Approved the final version of the manuscript on behalf of all authors: Hiwase. Administrative/technical/material support: Hiwase, Kalyanasundaram, Wells. Study supervision: Wells.

Correspondence

Abhiram Hiwase: Adelaide Medical School, University of Adelaide, Adelaide, SA, Australia. abhiram.hiwase@student.adelaide.edu.au.