


What is the Prognosis of Triple Arthrodesis in the Treatment of Adult Acquired Flatfoot Deformity (AAFD)?*

Qual o prognóstico da artrodese tríplice quando utilizada no tratamento do pé plano adquirido do adulto (PPAA)?

Daiana Kerry Picanço Gobbo¹ Nilson Roberto Severino¹ Ricardo Cardenuto Ferreira¹

¹ Orthopedics and Traumatology Department, Santa Casa de São Paulo, São Paulo, SP, Brazil

Rev Bras Ortop 2019;54:275–281.

Address for correspondence Daiana Kerry Picanço Gobbo, MD, Departamento de Ortopedia e Traumatologia, Santa Casa de São Paulo, Rua Barata Ribeiro, 380 – Cj 64 – sexto andar - Bela Vista, São Paulo, SP, 01308-000, Brazil (e-mail: daianagobbo@yahoo.com.br).

Abstract

Objective The present study aims to evaluate the ability of triple arthrodesis in eliminating the main complaints presented by patients with adult acquired flatfoot deformity (AAFD): 1) disabling hindfoot pain; 2) major deformities, such as medial arch collapse, valgus, abduction, and supination.

Methods A total of 17 patients (20 feet) with advanced AAFD who underwent surgical correction by triple arthrodesis were evaluated after a mean follow-up period of 43 months (range: 18–84 months). The average age of the patients at surgery was 62 years old (range: 38–79 years old). The visual analogue scale (VAS) for pain and the American Orthopaedic Foot and Ankle Society (AOFAS) hindfoot score were used to assess the final results.


Results According to the VAS, the average residual pain was 3 points; the AOFAS hindfoot score points increased 23% after the surgery; and the correction of deformities was considered satisfactory in 10 out of 20 feet; partially satisfactory in 4 out of 20 feet; partially unsatisfactory in 5 out of 20 feet; and unsatisfactory in 1 out of 20 feet.

Conclusion Despite the high index of bone fusion after triple arthrodesis, which is the gold standard treatment in advanced AAFD, the incomplete correction of major deformities and the persistence of residual pain contributed to a high disappointment rate of the patients with the surgical results.

Keywords

- ▶ flatfoot/etiology
- ▶ flatfoot/surgery
- ▶ arthrodesis
- ▶ acquired foot deformities

* The present work was developed at the Foot and Ankle Surgery Group, Department of Orthopedics and Traumatology, Santa Casa de São Paulo, São Paulo, SP, Brazil.

 Daiana Kerry Picanço Gobbo's ORCID is <https://orcid.org/0000-0001-7552-6590>.



Resumo

Objetivo Avaliar a capacidade da artrodese tríplice de aliviar as principais queixas dos pacientes que apresentam pé plano adquirido do adulto (PPAA): 1) dor incapacitante localizada no médio e retropé; 2) deformidades marcadas pelo colapso do arco medial, valgo, abdução e supinação.

Método Avaliamos 17 pacientes (20 pés) portadores de PPAA em estado avançado e que foram submetidos à correção cirúrgica pela artrodese tríplice modelante. A média de idade dos pacientes no momento da cirurgia foi de 62 anos (variação de 38 a 79 anos), e o tempo médio de seguimento foi de 43 meses (variação de 18 a 84 meses). Utilizamos critérios clínicos empregando a escala visual analógica da dor (EVAD) e a escala funcional da American Orthopaedic Foot and Ankle Society (AOFAS, na sigla em inglês) do retropé para avaliar a eficácia da cirurgia.

Resultados A dor residual mensurada pela EVAD foi de três pontos, em média. Observamos incremento médio de 23% nos valores da escala AOFAS do retropé após o tratamento cirúrgico. A correção das deformidades foi satisfatória em 10 de 20 pés; parcialmente satisfatória em 4 de 20 pés; parcialmente insatisfatória em 5 de 20 pés; e insatisfatória em 1 de 20 pés.

Conclusão Apesar da artrodese tríplice modelante indicada no tratamento do PPAA em estágio avançado apresentar alto índice de consolidação óssea, a correção incompleta das deformidades pré-existentes e a persistência de dor residual contribuíram para a elevada taxa de decepção dos pacientes com o resultado da cirurgia.

Palavras-chave

- ▶ pé chato/etiologia
- ▶ pé chato/cirurgia
- ▶ artrodese
- ▶ deformidades adquiridas do pé

Introduction

Triple modeling arthrodesis is the standard surgical treatment for advanced stages of adult acquired flatfoot deformity (AAFD), as in stage III lesions. In this situation, joint stiffness is frequently associated with diffuse hindfoot arthrosis and is accompanied by typical deformities, including: 1) medial arch collapse; 2) hindfoot valgus; 3) forefoot abduction and supination.¹⁻⁸ Triple arthrodesis is also indicated for older or overweight patients even when the evolutionary stage of AAFD is still intermediate (stage II), in which surgeries preserving some degree of joint movement would be performed.⁸⁻¹³ In obese patients, corrective surgeries involving osteotomies associated with musculotendinous transfers present a greater chance of failure with recurrences.^{8,12} Similarly, patients who are older and present low functional demand may also be good candidates for triple arthrodesis, since this surgery would theoretically contribute to alleviate the painful symptoms and is associated with a low risk of recurrence of deformities, thus avoiding a possible reoperation.⁸⁻¹⁶

The present study aims to evaluate the ability of modeling triple arthrodesis in relieving AAFD-related painful symptoms and deformities. Our hypothesis is that this surgery is capable of providing substantial improvement in pain intensity and in the alignment of deformed extremities.

Casistry and Method

From January to March 2015, all of the patients registered at our hospital database with a diagnosis of AAFD who were submitted to surgical treatment with triple modeling arthrodesis were called. Patients diagnosed with associated

rheumatologic diseases and those whose minimum postoperative follow-up time was < 12 months were excluded. A total of 17 patients (15 females and 2 males) answered our call. The surgery was bilateral in 3 patients, totaling 20 operated feet. At the time of the surgery, the average age of the patients was 62 years old (ranging from 38 to 79 years old), and the mean body mass index (BMI) was 31 (ranging from 23 to 42). All of the patients underwent conventional surgery under spinal anesthesia, using a pneumatic tourniquet at the thigh, near the groin area, with a pressure of 300 mm Hg. The surgical access route was double, one lateral and one medial. After planar dissection, the subtalar, talonavicular, and calcaneal cuboid joints were identified, and, then, proper-sized bone wedges were removed from the joint surfaces to allow an adequate coaptation concurrent to the correction of the essential AAFD-related deformities. All of the cases were internally fixed with screws. Immobilization with a plastered boot was maintained for 12 weeks. Loading on the operated limb was allowed from the 7th week on. After the removal of the plaster, immobilization with a walking boot was indicated for an additional 4 weeks, during which time the patients started physical therapy sessions.

During the postoperative follow-up period, minor complications were identified in five feet, including operative wound dehiscence and partial cutaneous necrosis at the edges of the surgical incision. The treatment of these lesions consisted of local debridement associated with oral systemic antibiotic therapy, resulting in complete healing without major complications.

To evaluate the clinical-functional outcome of the treatment, we used the corrected American Orthopaedic Foot and

Ankle Society (AOFAS) scale for the hindfoot^{17,18} (preoperative variation, 0 to 100; and postoperative variation, 0 to 94); the visual analogue scale (VAS) for pain¹⁹; and the degree of patient satisfaction with the outcome of the treatment (completely satisfied/satisfied with minimal restrictions/satisfied with major restrictions/unsatisfied).

To assess the surgical correction of the major AAFD-related clinical deformities, an independent examiner measured and compared preoperative photographic images of the feet of the patients with the clinical data from the postoperative evaluation. Variation in the degree of arch collapse, hindfoot valgus, and abduction and supination of the middle foot and forefoot were carefully analyzed and their correction was classified by the examiner as: 1) completely satisfactory, when the four deformities were adequately corrected according to normal clinical parameters; 2) partially satisfactory, when at least three of the four deformities were considered adequately corrected; 3) partially unsatisfactory, when only two of the four deformities

were considered adequately corrected; and 4) completely unsatisfactory, when only one or no deformity among the four deformities was adequately corrected (→ Fig. 1).

In addition to the clinical criteria, radiographic criteria were also used to evaluate the ability of triple modeling arthrodesis in correcting the main AAFD-related deformities.^{20,21} In simple radiographic images performed with support in dorsoplantar, lateral, and axial leg-foot views, the pre- and postoperative difference of the following parameters was measured: 1) medial longitudinal plantar arch height; 2) hindfoot valgus inclination; 3) forefoot abduction inclination (→ Fig. 2).

The present study was approved by our institution under the number CAAE 43134015.0.0000.5479.

Results

Complete bone consolidation, marked by bone trabeculae crossing the arthrodesis site on radiographic images, was

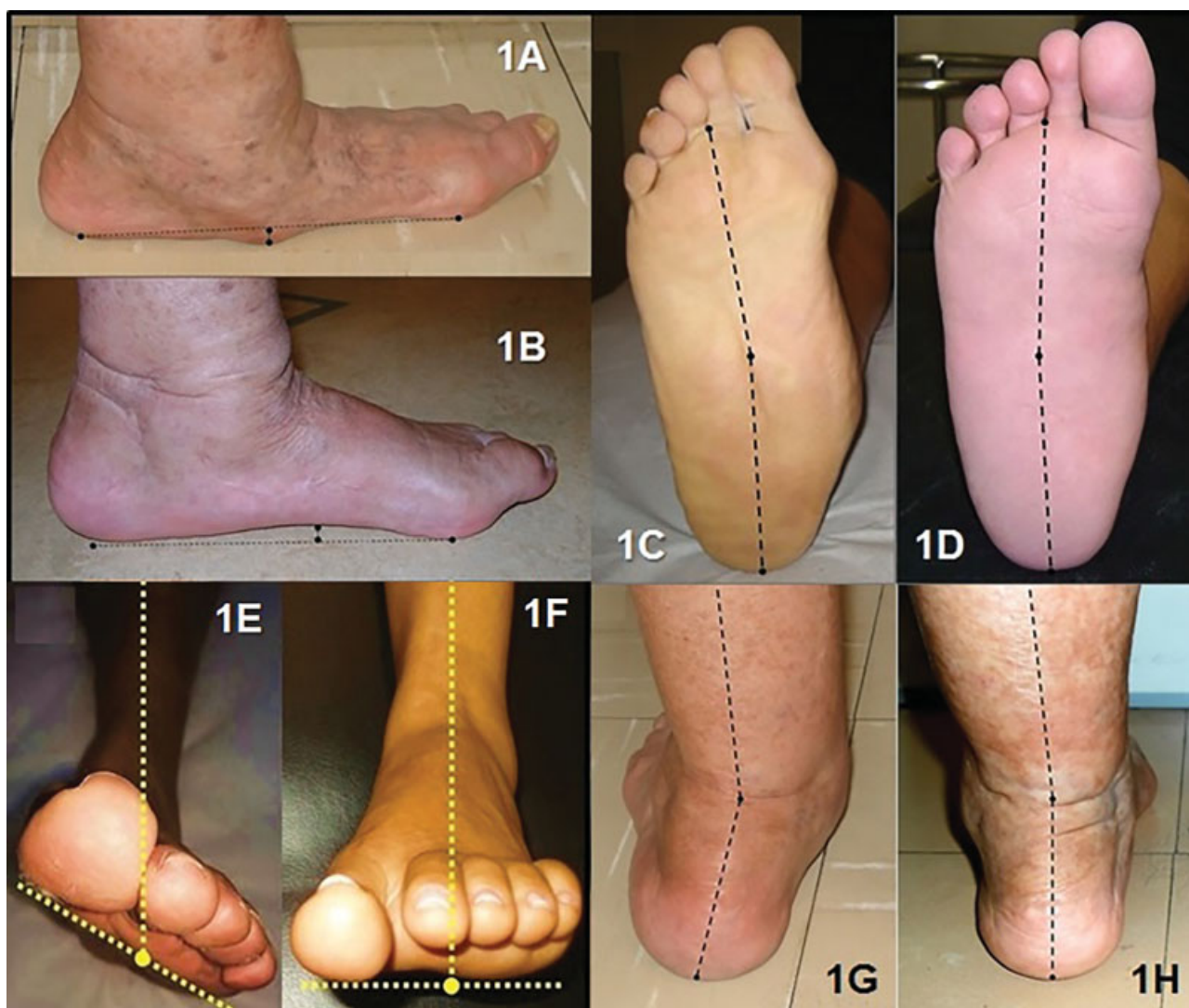


Fig. 1 Medial view of the left foot, showing the medial plantar arch collapse (1A), which was corrected after the surgery (1B). Plantar view of the right foot, showing abduction (1C), which was corrected after the surgery (1D). Frontal view of the right foot, showing a severe supination deformity (1E), which was corrected after the surgery (1F). Posterior view of the hindfoot, showing the marked valgus deformity (1G), which was corrected after the surgery (1H).

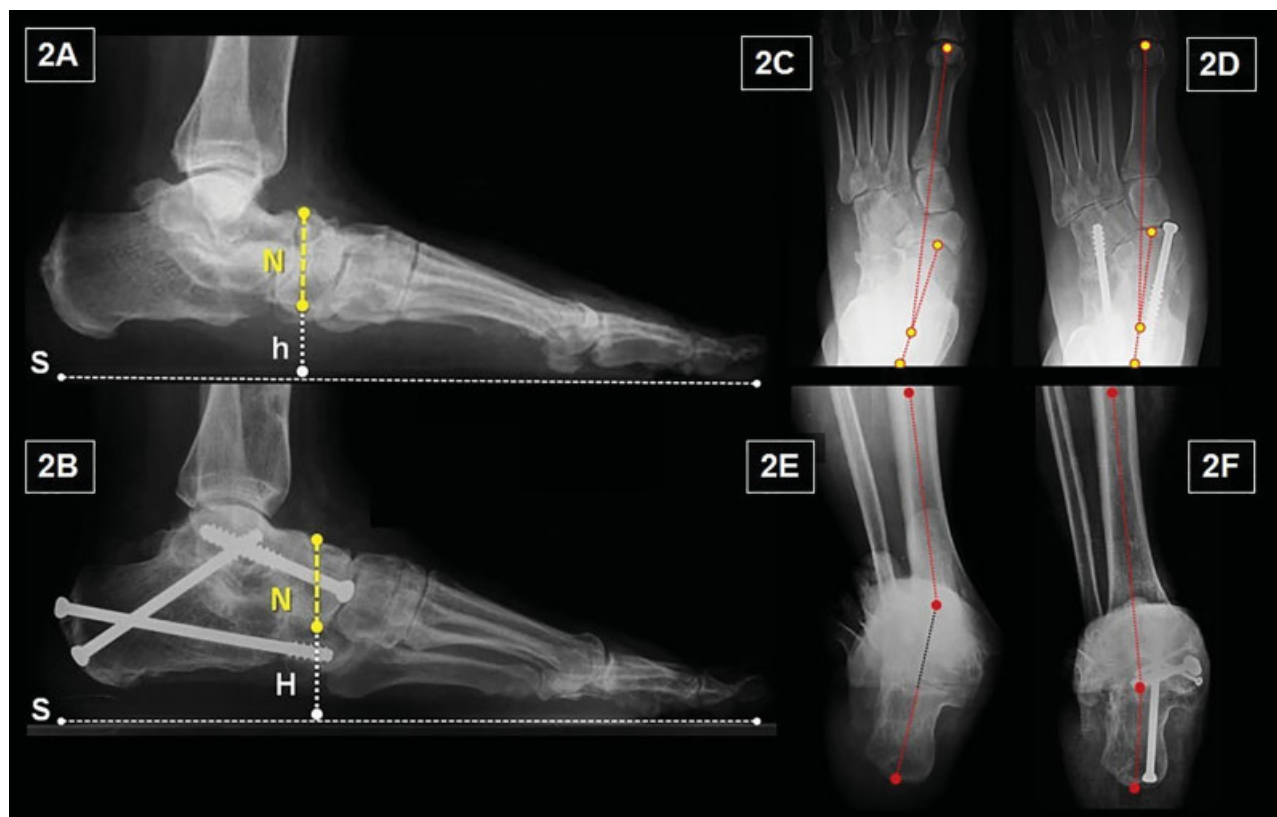


Fig. 2 Radiographic lateral image of the foot and ankle showing collapse of the medial arch (2A), which was corrected after the surgery (2B). The arch height in both pre- (h) and postoperative (H) images is determined by the distance of the lower margin of the navicular axis (N) towards the ground (S). Anteroposterior radiographic image of the foot, showing abduction before (2C) and after surgical correction (2D). Axial-to-foot radiographic image showing valgus deformity (2E) corrected with surgery (2F).

observed in 19 of the 20 operated feet (95%). Despite the high consolidation rate, the surgery did not guarantee total elimination of the pain. The results of the VAS evaluation showed residual pain in an intensity of 3 out of 10 points (range: 0–6). Regarding the clinical-functional result, determined with the AOFAS hindfoot scale, an average increase of 18 points occurred after the surgery. The mean preoperative score increased from 56 out of 100 points (rang: 43–69) to 74 out of 94 points (range: 55–90). This proportional increase in the score corresponded to the proportional improvement of ~ 23% in the parameters measured by the AOFAS scale from the preoperative to the postoperative condition. Considering the satisfaction of the patients with the surgical result, complete satisfaction was reported in 7 feet (35%); satisfaction with minimal restrictions in 5 feet (25%); and satisfaction with major restrictions in 8 feet (40%). No patient was unsatisfied with the final result of the treatment (– **Table 1**).

According to the clinical evaluation of the examiner regarding the surgical correction of the main AAFD-related deformities, the results were completely satisfactory in 10 out of 20 feet (50%), partially satisfactory in 4 out of 20 feet (20%), partially unsatisfactory in 5 out of 20 feet (25%), and completely unsatisfactory in 1 out of 20 feet (5%) (– **Table 1**).

In the radiographic evaluation of the surgical correction of the main AAFD-related deformities, the results were: 1) the average percentage increase in the medial longitudinal plantar arch height after the surgery was of 34%; 2) the mean

percentage hindfoot valgus decrease was of 27% (from the preoperative mean angulation of 11° to the postoperative value of 8°); 3) the mean percentage forefoot abduction inclination decrease was of 80% (from the preoperative mean angulation of 15° to the postoperative value of 3°).

Discussion

The incidence of AAFD is high; the condition affects patients in the 4th and 5th decades of life, who are overweight and poorly active, and is predominant in females.^{22–27} The main complaint of these patients is disabling pain, while the deformities that accompany AAFD appear as secondary complaints, mainly related to the difficulty in accommodating the foot inside conventional shoes, in addition to their excessive wear due to the support at its medial sole. The principle of surgical treatment considers that the improvement of the clinical symptoms depends on the correction of the deformities and on the restoration of the inverting force of the foot. In recent years, a number of publications involving studies with a series of clinical cases (level IV of scientific evidence) have highlighted the importance of replacing the degenerated posterior tibial tendon and correcting the typical AAFD deformities by multiple corrective osteotomies, provided that there is still sufficient mobility to allow the proper alignment of the foot, as observed in stage II lesions.^{22–26} The basic reasoning of this trend is to spare

Table 1 Distribution of the 17 patients (20 feet) according to epidemiological features, postoperative complications, follow-up time, and clinical-functional results

Case	Gender, age, side	Classification GRADE II or III	BMI	Immediate/Late Complications	Follow-up time	AOFAS PRE/POST	VAS	Personal satisfaction	Deformity correction
1	F, 52, R/L	II	31.1/24.8	no	48 and 18 months	67 to 72 and 73	5 and 5	Minor restriction	Partial satisfaction/ Total satisfaction
2	F, 54, L	II	39.6	no	24 months	52 to 73	4	Satisfied	Total satisfaction
3	F, 75, L	II	27.3	no	30 months	57 to 80	3	Satisfied	Total satisfaction
4	F, 47, L	II	31.8	no	47 months	55 to 81	2	Major restriction	Total satisfaction
5	F, 68, L	II	27.5	no	49 months	69 to 80	0	Satisfied	Total satisfaction
6	F, 63, R	II	22.9	no	84 months	62 to 83	3	Satisfied	Partial unsatisfaction
7	F, 49, L	III	41.9	no	12 months	56 to 75	2	Satisfied	Total satisfaction
8	F, 75, R	III	24.2	SWD	12 months	43 to 70	2	Satisfied	Partial unsatisfaction
9	F, 69, L	III	42.0	no	24 months	58 to 78	6	Major restriction	Total satisfaction
10	F, 70, R/L	III	38.7/38.7	no	24 and 48 months	55 to 85 and 52 to 90	4 and 4	Minor restriction	Total satisfaction/ Partial satisfaction
11	M, 79, R/L	III	25.0/25.0	no	26 and 72 months	58 to 81 and 51 to 80	3 and 3	Major restriction	Total satisfaction/ Partial satisfaction
12	F, 45, L	III	35.2	SWD	35 months	57 to 65	0	Major restriction	Total satisfaction
13	F, 70, L	III	33.2	no	43 months	44 to 55	3	Major restriction	Partial unsatisfaction
14	F, 70, R	III	30.1	SWD and pseudarthrosis	48 months	49 to 55	3	Minor restriction	Unsatisfactory
15	F, 61, L	III	31.0	no	60 months	46 to 76	2	Satisfied	Partial unsatisfaction
16	F, 58, R	III	26.5	SWD	75 months	66 to 73	3	Major restriction	Partial unsatisfaction
17	M, 38, L	III	24.0	no	90 months	54 to 62	5	Major restriction	Partial satisfaction

Abbreviations: AOFAS, numeric scale for clinical and functional hindfoot evaluation of the American Orthopedic Foot and Ankle Society; BMI, body mass index; F, female; L, left, M, male; R, right; SWD, surgical wound dehiscence; VAS, visual analog scale for pain.

the joints and to preserve the mobility of the hindfoot, in addition to avoiding late triple arthrodesis complications, mainly secondary arthrosis in adjacent joints, especially in the ankle and in the remaining midtarsal joints.^{22,23} The replacement of the degenerated and insufficient posterior tibial tendon by the flexor digitorum tendon is the preferred option.²² Unfortunately, the recurrence of AAFD deformities after multiple tarsal osteotomies and the replacement of the posterior tibial tendon with the flexor digitorum longus is not rare. This recurrence is particularly reported in patients with rheumatic conditions, who are overweight, or are of an older age, and triple arthrodesis must be considered an alternative surgical treatment when these risk factors are present.²²

Triple modeling arthrodesis is the standard surgical treatment for patients who do not respond to conservative AAFD treatment and who are already at a later stage of the disease, more specifically in stage III. Sometimes, it can also be indicated to a specific group of patients who have not yet developed rigid deformities accompanied by arthrosis (stage II), but who are older (> 65 years old) or obese (BMI > 30).^{8,12} Although numerous studies suggesting that obesity may have a negative impact on surgical outcomes in various joints,²⁸⁻³¹ there are few studies on its effect on orthopedic foot and ankle surgeries. Recently, Soukup et al³² did not identify significant outcome differences when comparing with normal body weight, overweight and obese patients. According to these authors, the treatment of

AAFD grade II through flexor digitorum tendon transfer and multiple osteotomies may also be indicated for patients with BMI > 25. However, the results of this study should be analyzed with caution because the average time of the postoperative follow-up was relatively short, of only 3 years.

Regarding the outcome of the surgical treatment of AAFD, it is worth noting that not all painful symptoms are completely eliminated by the procedure, either when it corrects deformities through multiple tarsal osteotomies or when the correction is accompanied by definitive tarsal stabilization through a triple arthrodesis.¹² Residual pain is a common cause of some degree of patient dissatisfaction with the outcome of the surgical treatment, regardless of whether osteotomies or arthrodeses were performed.^{33,34} It is worth mentioning that despite observing bone consolidation in 95% of the operated feet from our case series, residual pain persisted in a medium intensity level, of ~ 3 points in the VAS. This finding reinforces the need to inform the patient in advance that the surgery will not necessarily lead to the complete elimination of painful discomfort, even if bone healing is complete after the arthrodesis. The persistence of residual pain may have reflected directly the degree of personal satisfaction of our patients regarding the final surgical outcome. Of the 20 feet operated on, complete satisfaction was reported in only 7 (35%), while satisfaction with minor or major restrictions was reported in 13 feet (65%).

A possible explanation for the persistence of pain can be the fact that the surgery was not able to adequately correct

preexisting deformities. Since the postoperative clinical evaluation only considered half of the feet as completely corrected, the presence of residual deformities could be responsible for the persistence of pain. According to the radiographic evaluation, the mean percentage increase in the plantar arch height after the surgery was restricted to only ~34%; in addition, residual valgus persisted at an above average level, ~8°, even though the surgical treatment provided an average correction index of 27%. The only deformity that was substantially corrected in our case series was abduction, which virtually reached the average value within the normality range, that is, ~3°.

The retrospective nature of the present study and the small size of the sample group are the limitations of the present study. However, we believe that the information obtained may be useful to consider the limitations of triple modeling arthrodesis as a way to completely alleviate AAFD-related symptoms in a severe state. It is necessary to consider that this type of corrective surgery is not simple, and that its execution requires expert surgeons to achieve adequate foot positioning. The incomplete correction of severe deformities by the surgical treatment may be an important factor in the maintenance of residual pain, but its real importance is not yet fully known, and it cannot be identified in the present study.

Conclusion

Although triple modeling arthrodesis is indicated for the treatment of advanced AAFD, presenting a high bone consolidation index, the incomplete correction of preexisting deformities and the persistence of residual pain contributed to a high disappointment rate of the patients with the surgical results.

Conflicts of Interests

The authors have no conflicts of interests to declare.

References

- Kulowski J. Tendovaginitis (tenosynovitis), general discussion and report of one case involving the posterior tibial tendon. *J Miss State Med Assoc* 1936;33:135–137
- Lipscomb P. Non-suppurative tenosynovitis and paratendinitis. *Instr Course Lect* 1950;7:254
- Taylor R, Sammarco VJ. Minimizing the role of fusion in the rigid flatfoot. *Foot Ankle Clin* 2012;17(02):337–349
- Grunander TR, Thordarson DB. Results of calcaneocuboid distraction arthrodesis. *Foot Ankle Surg* 2012;18(01):15–18
- Lin JS, Myerson MS. The management of complications following the treatment of flatfoot deformity. *Instr Course Lect* 2011;60:321–334
- Johnson KA, Strom DE. Tibialis posterior tendon dysfunction. *Clin Orthop Relat Res* 1989;(239):196–206
- Myerson MS. Adult acquired flatfoot deformity: treatment of dysfunction of the posterior tibial tendon. *J Bone Joint Surg Am* 1996;78(05):780–792
- Hatic SO II, Philbin TM. Management of the recurrent deformity in a flexible foot following failure of tendon transfer: is arthrodesis necessary? *Foot Ankle Clin* 2012;17(02):299–307
- Gentchos CE, Anderson JG, Bohay DR. Management of the rigid arthritic flatfoot in the adults: alternatives to triple arthrodesis. *Foot Ankle Clin* 2012;17(02):323–335
- Mosier SM, Pomeroy G, Manoli A II. Pathoanatomy and etiology of posterior tibial tendon dysfunction. *Clin Orthop Relat Res* 1999;(365):12–22
- Schuh R, Salzberger F, Wanivenhaus AH, Funovics PT, Windhager R, Trnka HJ. Kinematic changes in patients with double arthrodesis of the hindfoot for realignment of planovalgus deformity. *J Orthop Res* 2013;31(04):517–524
- Ellington JK, Myerson MS. The use of arthrodesis to correct rigid flatfoot deformity. *Instr Course Lect* 2011;60:311–320
- Bluman EM, Title CI, Myerson MS. Posterior tibial tendon rupture: a refined classification system. *Foot Ankle Clin* 2007;12(02):233–249, v
- Raikin SM, Winters BS, Daniel JN. The RAM classification: a novel, systematic approach to the adult-acquired flatfoot. *Foot Ankle Clin* 2012;17(02):169–181
- Neville CG, Candidate MS, Houck JR. Science behind the use of orthotic devices to manage posterior tibial tendon dysfunction. *Tech Foot Ankle Surg* 2008;7(02):125–133
- Ryerson E. Arthrodesing operations on the feet. *J Bone Joint Surg Am* 1923;5:453–471
- Pinsker E, Daniels TR. AOFAS position statement regarding the future of the AOFAS Clinical Rating Systems. *Foot Ankle Int* 2011;32(09):841–842
- Kitaoka HB, Alexander IJ, Adelaar RS, Nunley JA, Myerson MS, Sanders M. Clinical rating systems for the ankle-hindfoot, mid-foot, hallux, and lesser toes. *Foot Ankle Int* 1994;15(07):349–353
- Gift AG. Visual analogue scales: measurement of subjective phenomena. *Nurs Res* 1989;38(05):286–288
- Saltzman CL, el-Khoury GY. The hindfoot alignment view. *Foot Ankle Int* 1995;16(09):572–576
- de Cesar Netto C, Schon LC, Thawait GK, da Fonseca LF, Chinanuvathana A, Zbijewski WB, et al. Flexible Adult Acquired Flatfoot Deformity: Comparison Between Weight-Bearing and Non-Weight-Bearing Measurements Using Cone-Beam Computed Tomography. *J Bone Joint Surg Am* 2017;99(18):e98
- Flemister AS Jr, Baumhauer JF, Digiovanni BF. Flexor digitorum longus to posterior tibialis transfer with lateral column lengthening for stage ii posterior tibial tendon dysfunction. *Tech Foot Ankle Surg* 2007;6(01):22–29
- Griend RV. Lateral column lengthening using a “Z” osteotomy of the calcaneus. *Tech Foot Ankle Surg* 2008;7(04):257–263
- Pomeroy GC, Manoli A II. A new operative approach for flatfoot secondary to posterior tibial tendon insufficiency: a preliminary report. *Foot Ankle Int* 1997;18(04):206–212
- Myerson MS, Corrigan J. Treatment of posterior tibial tendon dysfunction with flexor digitorum longus tendon transfer and calcaneal osteotomy. *Orthopedics* 1996;19(05):383–388
- Hirose CB, Johnson JE. Plantarflexion opening wedge medial cuneiform osteotomy for correction of fixed forefoot varus associated with flatfoot deformity. *Foot Ankle Int* 2004;25(08):568–574
- Holmes GB Jr, Mann RA. Possible epidemiological factors associated with rupture of the posterior tibial tendon. *Foot Ankle* 1992;13(02):70–79
- Kerkhoffs GM, Servien E, Dunn W, Dahm D, Bramer JA, Haverkamp D. The influence of obesity on the complication rate and outcome of total knee arthroplasty: a meta-analysis and systematic literature review. *J Bone Joint Surg Am* 2012;94(20):1839–1844
- Linberg CJ, Sperling JW, Schleck CD, Cofield RH. Shoulder arthroplasty in morbidly obese patients. *J Shoulder Elbow Surg* 2009;18(06):903–906
- Dowsey MM, Liew D, Stoney JD, Choong PF. The impact of obesity on weight change and outcomes at 12 months in patients undergoing total hip arthroplasty. *Med J Aust* 2010;193(01):17–21

- 31 Chan CL, Villar RN. Obesity and quality of life after primary hip arthroplasty. *J Bone Joint Surg Br* 1996;78(01):78-81
- 32 Soukup DS, MacMahon A, Burket JC, Yu JM, Ellis SJ, Deland JT. Effect of Obesity on Clinical and Radiographic Outcomes Following Reconstruction of Stage II Adult Acquired Flatfoot Deformity. *Foot Ankle Int* 2016;37(03):245-254
- 33 Barrôco R, Nery C, Netto AA. Pé plano adquirido por disfunção do tibial posterior: resultados cirúrgicos. *Rev Bras Ortop* 2002;37(06):211-218
- 34 Persaud S, Hentges MJ, Catanzariti AR. Occurrence of Lateral Ankle Ligament Disease With Stage 2 to 3 Adult-Acquired Flatfoot Deformity Confirmed via Magnetic Resonance Imaging: A Retrospective Study. *J Foot Ankle Surg* 2019;58(02):243-247