

Received: 2019.02.26
Accepted: 2019.04.01
Published: 2019.07.31

Prognostic Significance of Increased Expression of Annexin A10 (ANXA10) in Serous Epithelial Ovarian Cancer

Authors' Contribution:
Study Design A
Data Collection B
Statistical Analysis C
Data Interpretation D
Manuscript Preparation E
Literature Search F
Funds Collection G

CD 1 **Jing Wang**
B 1 **Shanshan Zhao**
AE 1 **Fangfang Wang**
F 1 **Jing Wang**
ABCDEFG 2 **Yuhua Zhang**

1 Department of Intensive Medicine, Yidu Central Hospital of Weifang, Weifang, Shandong, P.R. China
2 Department of Gynecology, Weihaiwei Peoples' Hospital, Weihai, Shandong, P.R. China

Corresponding Author: Yuhua Zhang, e-mail: zjwsmsm2019@163.com
Source of support: Departmental sources

Background: Epithelial ovarian cancer (EOC) is a gynecological malignancy that is associated with high mortality. Annexin A10 (ANXA10) is variably expressed in several types of human malignancy, but its role and clinical significance in EOC remain unknown. This study aimed to investigate the role of ANXA10 in EOC cells *in vitro* and to study the association between the protein expression levels of the ANXA10 in tumor tissue from patients with serous EOC and clinical outcome.





Material/Methods: The expression of ANXA10 was studied in 118 cases of serous EOC and in the ovarian cancer cell lines, SKOV-3, HO9810, HO8910PM, and OVCAR3 with immunohistochemistry and Western blot. Correlation between ANXA10 expression and clinicopathological variables and patient outcome were evaluated, including with Kaplan-Meier survival curves, univariate analysis with the log-rank test, and the multivariate analysis with the Cox-regression model.

Results: ANXA10 was expressed by cells in the ovarian cancer cell lines. Patients with low expression and high expression of ANXA10 were 61.86% (73/118) and 38.14% (45/118), respectively. High expression of ANXA10 was correlated with poor response to chemotherapy ($P=0.034$), the presence of lymphatic invasion ($P=0.043$), and the International Federation of Gynecology and Obstetrics (FIGO) advanced stage ($P=0.033$), which were all associated with lower survival rates of serous EOC. Increased expression of ANXA10 was identified as an independent prognostic biomarker of serous EOC (HR=1.73; 95% CI, 1.01–2.98; $P=0.046$).

Conclusions: Increased expression of ANXA10 was an independent prognostic marker in patients with serous EOC.

MeSH Keywords: **Annexins • Chemotherapy, Adjuvant • Neoplasm Invasiveness • Ovarian Neoplasms • Prognosis**

Full-text PDF: <https://www.medscimonit.com/abstract/index/idArt/915911>

 2370  4  2  24



Background

Epithelial ovarian cancer (EOC) is a gynecological malignancy that has a high mortality rate [1]. In China in 2015, there were approximately 52100 new cases and 22500 deaths from EOC in and in 2017 in the USA, there were 22440 new cases and 14080 deaths from EOC [2,3]. EOC includes several histological subtypes, including serous, endometrioid, clear cell, and mucinous ovarian carcinoma [4]. The different histological subtypes of EOC have distinct genomic signatures, epidemiologic risk factors, and clinical response to treatment [5]. Serous EOC is the most common and most aggressive histological subtype, accounting for 70% of newly diagnosed cases and 70–80% of ovarian cancer deaths [6].

During the past few decades, there have been developments in the methods of surgical treatment and adjuvant therapy for serous EOC, and the current standard treatment is radical surgery followed with platinum-based chemotherapy. However, most patients present clinically at an advanced stage and with tumor metastasis because there are usually no symptoms from early EOC. Therefore, the prognosis of serous EOC is poor, with a 5-year survival rate of less than 40% for non-metastatic malignancy, and the 5-year survival rate for patients with distant metastases is only 17% [7,8]. There have been promising developments in targeted therapy for advanced serous EOC that have been shown to prolong survival in patients with advanced-stage EOC for example, the poly ADP ribose polymerase (PARP) inhibitor, olaparib [1]. The identification of new target drugs includes the discovery of new predictive or prognostic biomarkers, which continue to be urgently required for patients with EOC.

Annexins are a family of calcium-binding and phospholipid-binding proteins that are involved in many cellular processes, including growth regulation, cell division, apoptosis, and cell differentiation [9]. Changes in the expression of Annexin and its subcellular localization have been shown to be associated with the development and progression of several types of human malignancy. The Annexin family has 12 members, including Annexin A10 (ANXA10) and a further 11 members. The aberrant expression of ANXA10 has been reported in types of human malignancy, including oral cancer, pancreatic cancer, hepatocellular carcinoma, and cholangiocarcinoma [10,11]. However, the expression pattern and subcellular location of ANXA10 in serous EOC remains unknown.

Therefore, this study aimed to investigate the role of ANXA10 in EOC cells *in vitro* and to study the association between the protein expression levels of the ANXA10 in tumor tissue from patients with serous EOC and clinical outcome.

Material and Methods

Patients and follow-up

This study was approved by the Ethics Committee of the Yidu Central Hospital and the Weihaiwei Peoples' Hospital. All specimens were obtained with written informed consent from the patients. From 2005 to 2015, a total of 428 patients in the original patient cohort underwent surgery for epithelial ovarian cancer (EOC). All cases were confirmed by histopathology performed at the Yidu Central Hospital and the Weihaiwei People's Hospital. The validation cohort was selected from the original cohort and included 118 patients with histologically diagnosed serous EOC. For the validation cohort, the inclusion criteria were a survival time >5 months, postoperative treatment with standard platinum-based chemotherapy, available follow-up, and availability of tumor tissue. The tumor staging system used was according to the International Federation of Gynecology and Obstetrics (FIGO). The optimal cytoreduction status was defined as a residual tumor of no more than 1 cm in diameter.

Cell culture and agents

Ovarian cancer cell lines, SKOV-3, HO9810, HO8910PM, and OVCAR3 were purchased from the Cell Bank of the Chinese Academy of Sciences (Shanghai, China). Cell lines HO8910PM, HO9810, and OVCAR3 were cultured in RPMI-1640 culture medium, while SKOV-3 cells were cultured in McCoy's 5A modified medium (Sigma-Aldrich, St. Louis MO, USA). All culture media were supplemented with 10% fetal bovine serum (FBS), 100 U/ml penicillin, and 100 µg/ml of streptomycin.

Immunohistochemistry

The expression of Annexin A10 (ANXA10) in ovarian tissues was evaluated by immunohistochemistry with 4 µm sections of formalin-fixed, paraffin-embedded tissues. Briefly, the specimens were deparaffinized with xylene and rehydrated with alcohol. Citrate buffer at pH 6.0 was used for antigen retrieval, and the tissue sections were incubated in 3% H₂O₂ to inactivate endogenous peroxidase. Tissues were incubated in 5% bovine serum albumin (BSA) for 1 hour to block nonspecific antibody binding, and then in the primary antibody to ANXA10 (Abcam, Cambridge, MA, USA) overnight at 4°C. The tissue sections were incubated in secondary antibody (Beyotime, Shanghai, China) for 1 hour at room temperature after washing three times in PBS buffer. The tissue sections were finally incubated with 3,3'-diaminobenzidine (DAB) solution (Beyotime, Shanghai, China) and counterstained with hematoxylin, mounted and a glass coverslip was added before the immunostaining was evaluated by light microscopy.

Semi-quantitative scoring of the immunohistochemistry staining for ANXA10

The immunostaining scores for ANXA10 were evaluated independently by two pathologists who were unaware of the clinical data. The immunostaining score of ANXA10 was performed according to a previously published method [10]. The score was defined as the product of the score of the percentage of positive cells multiplied by the intensity score. The scores of the percentage of positive cells were: 0, no staining; 1, <10%; 2, 10–50%; 3, 51–80%; and 4, >80%. The intensity scores were: 0, negative; 1, weak; 2, moderate; and 3, strong. The cut-off of the validation cohort was set by the receiver operating characteristic (ROC) curve, and the specificity and sensitivity were identified, according to a previous study [12], which classified the validation cohort into two groups with low or high ANXA10 expression. In this study, the cut-off value was 5, which meant that cases with a score of 6, 8, 9, or 12 were defined as having high ANXA10 expression.

Western blot

The expression of ANXA10 in different cell lines was detected with immunoblot by the Western blot method. Briefly, cells were lysed in RIPA buffer and the total lysate was centrifuged at 10,000×g for 30 minutes and the supernatant was discarded. Equal amounts of protein was used for sodium dodecyl sulfate-polyacrylamide gel electrophoresis (SDS-PAGE), and then transferred to polyvinylidene fluoride (PVDF) membrane (Pall Co., Fort Washington, NY, USA). Nonspecific binding of the protein was blocked with 5% dried skimmed milk powder. The primary antibody to ANXA10 at a dilution of 1: 1000 and the secondary antibody at a dilution of 1: 10000 were used. Proteins were finally visualized using enhanced chemiluminescence (ECL) detection reagents (Thermo Fisher Scientific, Waltham, MA, USA).

Statistical analysis

All data were analyzed with SPSS software (IBM, Chicago, IL, USA). Correlation between clinicopathological variables and the expression of ANXA10 were calculated with Fisher's test. The log-rank test and the Kaplan–Meier method were used to evaluate the correlation between clinicopathological variables and patient survival rates. The Cox-regression hazard model was performed to identify independent prognostic factors. A P-value <0.05 was considered to be statistically significant.

Table 1. Clinicopathological characteristics in the patients with serous epithelial ovarian cancer (EOC) and Annexin A10 (ANXA10) expression.

Characteristic	Number	Percent
Age (years)		
<50	30	25.42%
≥50	88	74.58%
Lymph node metastasis		
No	75	63.56%
Yes	43	36.44%
Histological grade		
1	16	13.56%
2	45	38.14%
3	57	48.31%
Response to chemotherapy		
Good	78	66.10%
Poor	40	33.90%
Cytoreduction status		
Optimal	63	53.39%
Suboptimal	55	46.61%
FIGO stage		
I-II	58	49.15%
III-IV	60	50.85%
ANXA10		
Low	73	61.86%
High	45	38.14%

FIGO – International Federation of Gynecology and Obstetrics.

Results

Expression and localization of Annexin A10 (ANXA10) in epithelial ovarian cancer (EOC) tissues

The expression and intracellular location of ANXA10 were initially detected using immunohistochemistry, which divided the patients in the study cohort with serous epithelial ovarian cancer (EOC) into a group with a low expression of ANXA10, 61.86% (73/118), and high expression of ANXA10, 38.14% (45/118) (Table 1). The cellular location of the Annexins has previously been reported to be correlated with their role in carcinogenesis and cancer progression, and in this study, ANXA10 in serous EOC tissue was mainly expressed in the cell nuclei and cytoplasm (Figure 1A, 1B). In the 45 cases with high expression of ANXA10, 38 cases (84.44%) had ANXA10 expression in both the cytoplasm and cell nuclei, 5 (11.11%) had nuclear ANXA10 expression, and 2 cases (4.44%) had ANXA10 expressed in the cytoplasm alone. The expression of ANXA10 in the cell lines

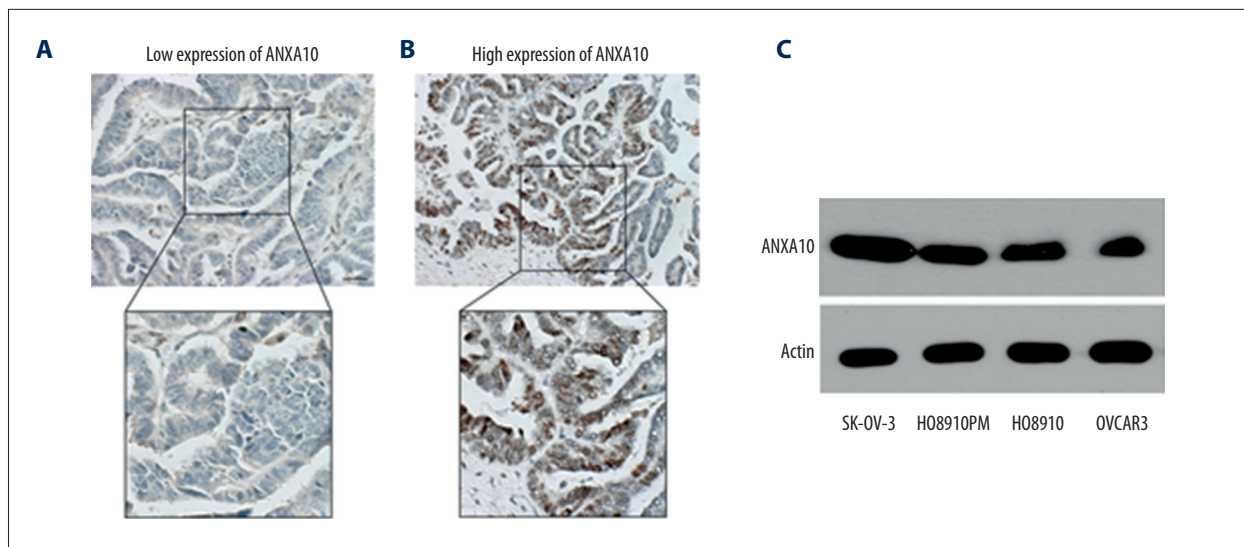


Figure 1. Expression of Annexin A10 (ANXA10) in tissue samples from patients with serous epithelial ovarian cancer (EOC) and ovarian cancer cell lines. **(A, B)** Photomicrographs of the light microscopy findings. Upper panel, the representative images of low expression **(A)** and high expression **(B)** of ANXA10. Lower panel, the magnified images of the corresponding figure. Scale bar: 100 μ m. The total score of **(A)** was staining score (1) \times positive score (2)=2, while the total score of **(B)** was staining score (3) \times positive score (4)=12. **(C)** The expressions of ANXA10 in different EOC cell lines SKOV-3, HO8910, HO8910PM and OVCAR3 were detected with Western blot.

SKOV-3, HO8910, HO8910PM, and OVCAR3 were detected with Western blot. ANXA10 was commonly expressed in these cell lines with varying degrees of expression. The SKOV-3 cell line had the highest level of ANXA10 expression (Figure 1C).

Correlation between ANXA10 expression and the clinicopathological variables

The correlation between ANXA10 and the main clinicopathological factors were evaluated by Fisher's test (Table 2). High expression levels of ANXA10 were correlated with poor response to chemotherapy ($P=0.034$), indicating that ANXA10 expression may increase tumor cell chemoresistance. Also, ANXA10 was associated with high histological grade, but this did not reach statistical significant ($P=0.067$).

Increased expression of ANXA10 was correlated with reduced prognosis in patients with serous EOC

The prognostic significance of ANXA10 was evaluated with univariate analysis (Table 3). High expression of ANXA10 was significantly associated with reduced survival in patients with serous EOC ($P=0.008$) (Figure 2A). This result indicated that ANXA10 was a prognostic biomarker for reduced prognosis in patients with serous EOC. Also, positive lymphatic invasion ($P=0.043$), poor response to chemotherapy ($P=0.004$) and advanced International Federation of Gynecology and Obstetrics (FIGO) stage ($P=0.033$) were also associated with poor prognosis in patients with serous EOC (Figure 2B–2D).

ANXA10 was an independent prognostic indicator in patients with serous EOC

Multivariate analysis was performed to identify the independent prognostic biomarkers of serous EOC (Table 4). All the variables were enrolled in the Cox-regression model for multivariate analysis, except the FIGO stage because of its interaction with other factors. In the study cohort, the high expression of ANXA10 was identified as an independent prognostic biomarker for serous EOC (HR=1.73; 95% CI, 1.01–2.98; $P=0.046$), indicating that ANXA10 expression might be predictive for patient prognosis in serous EOC. Also, poor response to chemotherapy (HR=2.50; 95% CI, 1.44–4.35; $P=0.001$), positive lymphatic invasion (HR=1.91; 95% CI, 1.16–3.12; $P=0.011$), and incomplete surgical resection (HR=2.47; 95% CI, 1.30–4.69; $P=0.006$) were all identified as independent negative prognostic factors in patients with serous EOC.

Discussion

Members of the Annexin family have similar structures and biochemical features, but different tissue specificities and diverse functions. Changes in the expression of the Annexins or localization may contribute to the pathogenesis of human diseases including diabetes, inflammatory diseases, blood clotting, and cancer [13,14]. The role of the Annexin family in tumorigenesis and cancer progression is controversial, as Annexin A1 (ANXA1), ANXA2, ANXA4, ANXA6, and ANXA11 have been

Table 2. Correlation between Annexin A10 (ANXA10) expression and clinicopathological characteristics in 118 patients with serous epithelial ovarian cancer (EOC).

Characteristic	ANXA10		P-value
	Low	High	
Age (years)			
<50	20	10	0.664
≥50	53	35	
Lymph node metastasis			
No	50	25	0.173
Yes	23	20	
Histological grade			
I	12	4	0.067
II	22	23	
III	39	18	
Response to chemotherapy			
Good	51	27	0.034
Poor	22	18	
Cytoreduction status			
Optimal	42	21	0.262
Suboptimal	31	24	
FIGO stage			
I+II	34	24	0.570
III+IV	39	21	

The p-value, calculated by Fisher’s test. FIGO – International Federation of Gynecology and Obstetrics.

shown to be down-regulated in hormone-refractory prostate cancer [15,16]. However, there have also been studies that have supported the oncogenic role of the Annexin family. For example, overexpression of ANXA2 was shown in several types of human malignancy, including cancer of the pancreas and breast, and malignant glioma of the brain [17].

In the Annexin family members, the roles of ANXA10 in tumorigenesis and tumor progression have been controversial. Both the oncogenic role and tumor suppressor role of ANXA10 have been supported by the findings from previous studies. Overexpression of ANXA10 was shown to inhibit proliferation, migration, and invasion of prostate cancer cells [18]. However, ANXA10 was shown to be highly expressed in pancreatic adenocarcinoma compared with normal pancreas, chronic pancreatitis, and benign intraductal mucinous adenoma [10]. Also, within the same malignancy, ANXA10 may have different expression patterns in tumor subtypes, as the findings from a previous study showed that ANXA10 was expressed more frequently in diffuse-type adenocarcinoma compared

Table 3. Correlation between clinicopathological characteristics and overall survival rates in 188 patients with serous epithelial ovarian cancer (EOC).

Characteristic	Univariate analysis	
	5-year survival rate (%)	P-value
Age (years)		
<50	56.2	0.570
≥50	48.6	
Lymph node metastasis		
No	57.5	0.043
Yes	40.2	
Histological grade		
1	77.8	0.305
2	39.1	
3	53.5	
Response to chemotherapy		
Good	58.8	0.004
Poor	30.8	
Cytoreduction status		
Optimal	66.2	0.275
Suboptimal	42.7	
FIGO stage		
I+II	59.5	0.033
III+IV	39.3	
ANXA10		
Low	64.1	0.008
High	38.1	

The p-value, calculated by the log-rank test. FIGO – International Federation of Gynecology and Obstetrics; ANXA10 – Annexin A10.

with intestinal-type adenocarcinoma [11]. It is possible that ANXA10 has dual roles in tumorigenesis and cancer progression, depending on its tissue specificity and subcellular localization. In the present study, serous epithelial ovarian cancer (EOC) was investigated because ovarian cancer is a heterogeneous malignancy that has different subtypes with diverse biological features. The findings showed that high expression levels of ANXA10 resulted in reduced prognosis in patients with serous EOC. These findings expand the understanding of the role of ANXA10 in cancer and indicate that this may be

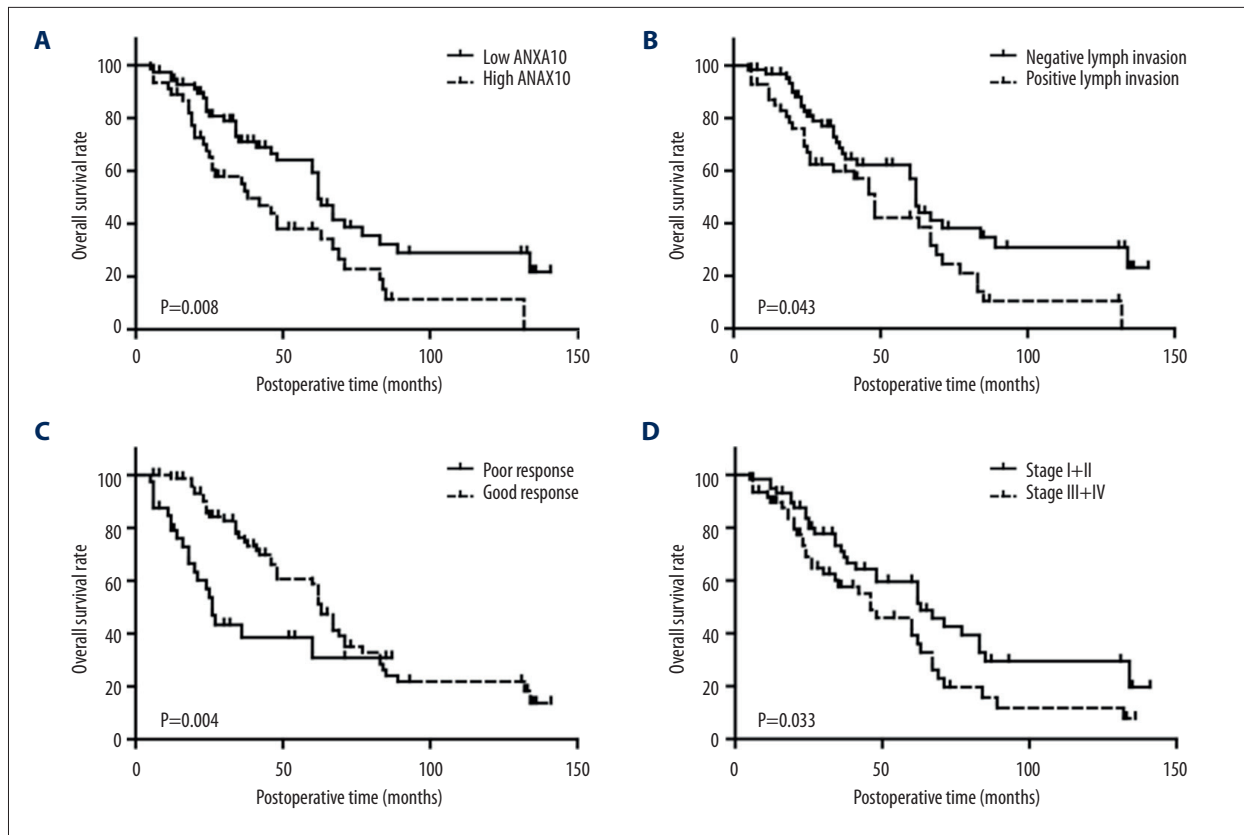


Figure 2. The prognostic roles of Annexin A10 (ANXA10), lymphatic invasion, response to chemotherapy, and the International Federation of Gynecology and Obstetrics (FIGO) stage in 118 patients with serous epithelial ovarian cancer (EOC). (A–D) The overall survival curves of patients with serous EOC were stratified with factors including ANXA10 (A), lymphatic invasion (B), response to chemotherapy (C) and FIGO stage (D). Patients with high expression levels of ANXA10, negative lymphatic invasion, poor response to chemotherapy and advanced FIGO stage had a worse prognosis and reduced overall survival.

Table 4. Prognostic factors in 118 patients with serous epithelial ovarian cancer (EOC).

Characteristic	Multivariate analysis		
	HR	95% CI	P-value
Age (years)			
<50	1		
≥50	0.858	0.48–1.54	0.607
Lymph node metastasis			
No	1		
Yes	1.91	1.16–3.12	0.011
Histological grade			
1	1		
2	1.02	0.46–2.26	0.969
3	1.48	0.66–3.23	0.355

Characteristic	Multivariate analysis		
	HR	95% CI	P-value
Response to chemotherapy			
Good	1		
Poor	2.5	1.44–4.35	0.001
Cytoreduction status			
Optimal	1		
Suboptimal	2.47	1.30–4.69	0.006
ANXA10			
Low	1		
High	1.73	1.01–2.98	0.046

P-value, calculated by the Cox-regression model. HR – hazard ratio; CI – confidence interval; FIGO – International Federation of Gynecology and Obstetrics; ANXA10 – Annexin A10.

a novel prognostic biomarker in serous EOC. However, this preliminary study requires support from further larger scale long-term controlled studies.

In the present study, the expression of ANXA10 was associated with response to chemotherapy and was correlated with histological grade. Similar findings for other Annexin family members have been previously reported. For example, expression of ANXA1 has been shown to be inversely correlated with the histological grade of head and neck squamous cell carcinoma, B-cell non-Hodgkin lymphoma, and esophageal squamous cell carcinoma [19–21]. Also, previous studies have shown that overexpression of ANXA1, ANXA4, and ANXA5 correlated with multiple drug resistance of several cell lines, including a breast cancer cell line, and the chicken DT40 B cell line [22,23]. However, compared with the other Annexin family members, there have been fewer studies on the role of ANXA10 in human cancer. The underlying molecular mechanism to explain the overexpression of ANXA10 in some tumor types and how ANXA10 might affect tumor progression and patient prognosis still remains unclear. Further studies are needed to determine the roles for ANXA10 human malignancy, and it is hoped that the findings from this preliminary study might generate interest in its further investigation of its biological and pathological functions.

Targeted therapy has become an area of interest in the treatment of advanced-stage cancers. The basis of targeted therapy relies on the discovery of new drug targets. For example, in ovarian cancer, the poly ADP ribose polymerase (PARP) inhibitor, olaparib, was

the first targeted therapy for ovarian cancer, which is used selectively for patients with BRCA1 and BRCA2 gene mutations [1]. However, the germline BRCA mutations are only found in up to 18% of patients with high-grade EOC [24]. Currently, other targeted therapies for EOC have been shown to be ineffective and so further studies on prognostic biomarkers are needed. In the present study, ANXA10 was shown to be an independent prognostic biomarker of serous EOC that might also be a novel drug target. However, further studies are required to investigate the roles for ANXA10 in serous and other subtypes of EOC.

Conclusions

The aim of this study was to investigate the role of Annexin A10 (ANXA10) in epithelial ovarian cancer (EOC) cells *in vitro* and to study the association between the protein expression levels of the ANXA10 in tumor tissue from patients with serous EOC and clinical outcome. The findings showed that increased expression of ANXA10 was an independent prognostic marker in patients with serous EOC. Further studies are needed to validate the potential prognostic role for ANXA10 in patients with this tumor subtype, as biomarkers that can stratify high-risk patients following surgery and biomarkers for targeted therapy are still needed for patients with ovarian cancer.

Conflict of interest

None.

References:

- Hoskins PJ, Gottlieb WH: Missed therapeutic and prevention opportunities in women with BRCA-mutated epithelial ovarian cancer and their families due to low referral rates for genetic counseling and BRCA testing: A review of the literature. *Cancer J Clin*, 2017; 67(6): 493–506
- Chen W, Zheng R, Baade PD et al: Cancer statistics in China, 2015. *Cancer J Clin*, 2016; 66(2): 115–32
- Siegel RL, Miller KD, Jemal A: Cancer Statistics, 2017. *Cancer J Clin*, 2017; 67(1): 7–30
- Natanzon Y, Goode EL, Cunningham JM: Epigenetics in ovarian cancer. *Semin Cancer Biol*, 2018; 51: 160–69
- Pearce CL, Templeman C, Rossing MA et al: Association between endometriosis and risk of histological subtypes of ovarian cancer: A pooled analysis of case-control studies. *Lancet Oncol*, 2012; 13(4): 385–94
- Bowtell DD, Bohm S, Ahmed AA et al: Rethinking ovarian cancer II: Reducing mortality from high-grade serous ovarian cancer. *Nature Rev Cancer*, 2015; 15(11): 668–79
- Carter JH, Deddens JA, Mueller G et al: Transcription factors WT1 and p53 combined: A prognostic biomarker in ovarian cancer. *Br J Cancer*, 2018; 119(4): 462–70
- Vaughan S, Coward JI, Bast RC Jr. et al: Rethinking ovarian cancer: Recommendations for improving outcomes. *Nature Rev Cancer*, 2011; 11(10): 719–25
- Mussunoor S, Murray GI: The role of annexins in tumour development and progression. *J Pathol*, 2008; 216(2): 131–40
- Zhu J, Wu J, Pei X, Tan Z et al: Annexin A10 is a candidate marker associated with the progression of pancreatic precursor lesions to adenocarcinoma. *PLoS One*, 2017; 12(4): e0175039
- Lu SH, Yuan RH, Chen YL et al: Annexin A10 is an immunohistochemical marker for adenocarcinoma of the upper gastrointestinal tract and pancreaticobiliary system. *Histopathology*, 2013; 63(5): 640–48
- Xu YF, Liu ZL, Pan C et al: HMGB1 correlates with angiogenesis and poor prognosis of perihilar cholangiocarcinoma via elevating VEGFR2 of vessel endothelium. *Oncogene*, 2019; 38(6): 868–80
- Wang HM, Xu YF, Ning SL et al: The catalytic region and PEST domain of PTPN18 distinctly regulate the HER2 phosphorylation and ubiquitination barcodes. *Cell Res*, 2014; 24(9): 1067–90
- Hayes MJ, Moss SE: Annexins and disease. *Biochem Biophys Res Commun*, 2004; 322(4): 1166–70
- Xin W, Rhodes DR, Ingold C et al: Dysregulation of the annexin family protein family is associated with prostate cancer progression. *Am J Pathol*, 2003; 162(1): 255–61
- Kang JS, Calvo BF, Maygarden SJ et al: Dysregulation of annexin I protein expression in high-grade prostatic intraepithelial neoplasia and prostate cancer. *Clin Cancer Res*, 2002; 8(1): 117–23
- Kirshner J, Schumann D, Shively JE: CEACAM1, a cell-cell adhesion molecule, directly associates with annexin II in a three-dimensional model of mammary morphogenesis. *J Biol Chem*, 2003; 278(50): 50338–45
- Miyazawa Y, Sekine Y, Kato H et al: Simvastatin up-regulates Annexin A10 that can inhibit the proliferation, migration, and invasion in androgen-independent human prostate cancer cells. *Prostate*, 2017; 77(4): 337–49

19. Garcia Pedrero JM, Fernandez MP, Morgan RO et al: Annexin A1 down-regulation in head and neck cancer is associated with epithelial differentiation status. *Am J Pathol*, 2004; 164(1): 73–79
20. Vishwanatha JK, Salazar E, Gopalakrishnan VK: Absence of annexin I expression in B-cell non-Hodgkin's lymphomas and cell lines. *BMC Cancer*, 2004; 4: 8
21. Xia SH, Hu LP, Hu H et al: Three isoforms of annexin I are preferentially expressed in normal esophageal epithelia but down-regulated in esophageal squamous cell carcinomas. *Oncogene*, 2002; 21(43): 6641–48
22. Han EK, Tahir SK, Cherian SP et al: Modulation of paclitaxel resistance by annexin IV in human cancer cell lines. *Br J Cancer*, 2000; 83(1): 83–88
23. Hawkins TE, Das D, Young B, Moss SE: DT40 cells lacking the Ca²⁺-binding protein annexin 5 are resistant to Ca²⁺-dependent apoptosis. *Proc Natl Acad Sci USA*, 2002; 99(12): 8054–59
24. Walsh T, Casadei S, Lee MK et al: Mutations in 12 genes for inherited ovarian, fallopian tube, and peritoneal carcinoma identified by massively parallel sequencing. *Proc Natl Acad Sci USA*, 2011; 108(44): 18032–37