

Case Report

Regorafenib beyond the Second Line in Relapsed Glioblastoma: A Case Report and Literature Review

Mario Pirozzi^a Marianna Caterino^a Sergio Facchini^a Alessia Zotta^a
Gaetana Messina^b Raffaele Rauso^c Antonello Sica^a Donato Sciano^d
Gaetano Facchini^e Michele Orditura^a Teresa Somma^f Francesco Maiuri^f
Paolo Cappabianca^f Fortunato Ciardiello^a Morena Fasano^a

^aDepartment of Precision Medicine, University of Campania “Luigi Vanvitelli,” Naples, Italy;

^bThoracic Surgery Unit, Università degli Studi della Campania “Luigi Vanvitelli,” Naples, Italy; ^cOral and Maxillofacial Surgery Unit, Multidisciplinary Department of Medical-Surgical and Dental Specialists, University of Campania “Luigi Vanvitelli,” Naples, Italy;

^dTrauma Center Unit, AORN Sant’Anna and San Sebastiano, Caserta, Italy; ^eASL NA2 NORD, Oncology Operative Unit, “Santa Maria delle Grazie” Hospital, Pozzuoli, Italy; ^fDivision of Neurosurgery, Department of Neurosciences, Reproductive and Odontostomatological Sciences, School of Medicine and Surgery, Federico II University of Naples, Naples, Italy

Keywords

Glioblastoma · Regorafenib · Advanced treatment lines · Long survival

Abstract

Glioblastoma multiforme (GBM) is one of the most frequent and aggressive primary tumors in the central nervous system, representing more than 60% of all brain tumors in adults. Primary GBM remains incurable with a poor prognosis both for limited therapeutic alternatives and for a high risk of progression or recurrence. In fact, at recurrence, the few treatment options available, and often characterized by limited effectiveness, have always been an Achilles’ heel. The recent approval of second line of regorafenib, a multikinase inhibitor, has given hope after several years of darkness for new therapies in the treatment of GBM. Indeed, in the REGOMA trial, a phase 2 study, regorafenib was the first drug to show a statistically significant improvement in median overall survival compared with lomustine group, usually used in the second-line treatment after temozolomide failure. We report a case of a 43-year-old patient affected by GBM in treatment with regorafenib in third line of therapy with good disease control and long PFS.

© 2022 The Author(s).
Published by S. Karger AG, Basel

Correspondence to:
Morena Fasano, morena.fasano@unicampania.it

Introduction

Glioblastoma multiforme (GBM) is the most common primary brain malignancy in adults, representing about 14.5% of all tumors [1]. In over 90% of cases, GBM occurs de novo, called primary GBM, without evidence of a less malignant precursor; usually grows more rapidly and has a worse prognosis than secondary GBM, which develops from lower grade astrocytoma or oligodendroglioma.

In newly diagnosed cases, the standard of care is maximally safe resection, concomitant chemoradiotherapy with temozolomide, and subsequent adjuvant temozolomide alone for 6 cycles [2]. This multimodal approach is associated with a median overall survival (mOS) of about 15 months, with a range of around 10–16 months and a 5-year survival rate of 10%.

At recurrence, treatment remains less defined: some patients may be offered re-irradiation, salvage surgery, rechallenge with temozolomide if a long interval has passed, nitrosoureas (e.g., CCNU), or antiangiogenic drugs such as bevacizumab [3]. Currently, there is no uniform consensus on standard treatment at progression. Lomustine, an alkylating agent, is usually used in the second line after temozolomide failure, with mOS range of 8.6–9.8 months, and median progression-free survival (mPFS) of 1.5–2.7 months [3]. Rationale for bevacizumab, an anti-VEGF IgG1 antibody, only approved in the USA based on two phase 2 trials, stands on the highly angiogenic nature of GBM but its limited efficacy is restricted to PFS [3, 4]. Consequently, there is a critical need for new therapies that can improve the prognosis for patients with GBM.

Regorafenib is an orally available tyrosine kinase inhibitor, targeting numerous pathways (angiogenesis, oncogenesis, tumor microenvironment, and immunity) and is approved for treatment in several tumor types. Following a 2018 phase 2 trial by Lombardi et al. [5], regorafenib has now been approved by Italian Medicines Agency (AIFA) for its use in recurrent GBM as of October 2019. Here, we report the results of treatment with regorafenib in one of our patients treated at the Oncology Department of the University L. Vanvitelli with a secondary glioblastoma, previously treated with unsatisfying results.

Regorafenib in the Central Nervous System Overview

At the time of this publication, regorafenib has been approved as anticancer drug by AIFA in the hepatocarcinoma, nonresectable or metastatic GIST, metastatic colorectal cancer, besides relapsing GBM. REGOMA (NCT02926222) was a multicentric, open-labeled, randomized, controlled, phase 2 trial in which 119 patients were randomized to receive either regorafenib, at 160 mg/day orally once a day for the first 3 weeks of a 4-week cycle or lomustine at 110 mg/sqm (up to 200 mg) orally on day 1 of every 6-week cycle. At the median follow-up of 15.4 months, OS, primary endpoint of the study, was greatly improved in the regorafenib group (7.4 vs. 5.6) [5]. One of the main limitations of the REGOMA trial, besides needing confirmation from a phase 3 trial, is the discrepancy of lomustine results compared to other trials: for example, lomustine mOS in EORTC 26101 trial [6] was around 9 months versus 5.6 months in the REGOMA study. According to aforementioned findings and despite requiring further investigation, AIFA proceeded to approve regorafenib in GBM as second line of treatment on 19 December 2019.

Regorafenib is first-choice treatment for recurrent GBM according to Italian Association of Medical Oncology guidelines, while bevacizumab, although approved by FDA, is not recommended by AIFA and EMA. The National Comprehensive Cancer Network guidelines also consider regorafenib as a valid option in recurrent GBM; nevertheless, the strongest suggestion is clinical trial enrollment. Regorafenib is conspicuously absent from the 2020

European Association of Neuro-Oncology guidelines, in which only nitrosoureas, temozolomide rechallenge, and bevacizumab emerge as therapeutic options. Regorafenib is not yet approved by EMA for use in relapsing GBM, although it has been granted in 2019 orphan drug designation.

Case Presentation

In 2007, a 28-year-old patient presented with a history of multiple seizures in the last few months. Accordingly, he practiced brain magnetic resonance imaging (MRI) with contrast agent which showed a mass in the left frontal lobe. He then underwent excision with histopathological examination compatible with grade 2 fibrillary astrocytoma. Subsequently, the patient has been treated with adjuvant radiotherapy (RT) (60 Gy) plus concomitant temozolomide and subsequent adjuvant therapy for six cycles. After more than 10 years, recurrence was highlighted in September 2018, with the appearance of a mass of 26 × 18 mm in the left frontal lobe. At the same time, the patient complained of headache, fatigue, and nervousness. In October 2018, a second surgical exeresis was deemed necessary. Histological examination was compatible with high-grade glial lesion, IDH wild-type, 1p19q non-codeleted, O-6-Methylguanine-DNA Methyltransferase (MGMT) methylated. Postsurgery gadolinium-enhanced brain MRI showed residual disease in surgical bed; therefore, the patient practiced a second course of RT (51 Gy) until January 2019 followed by concomitant temozolomide rechallenge.

Unfortunately, first brain MRI at 40 days after RT completion showed disease progression and progressive clinical deterioration: the patient reported intense headache, cognitive changes, and vomiting for about 3 episodes per day, despite intravenous therapy with antiemetics and steroids. Because of this, the patient started an off-label treatment with bevacizumab plus irinotecan for 12 cycles, overall well-tolerated. Best response was stable disease according to Response Assessment in Neuro-Oncology criteria. After a 12-month PFS, in May 2020, MRI showed cerebral progression with worsening of headache, personality change, motor deficits, and memory loss, therefore, after a mannitol course and steroid therapy, the patient underwent palliative RT (15 Gy in 3 fractions) and then, after a new MRI (Fig. 1, 2), an off-label third-line treatment with regorafenib 160 mg/day from day 1 to 21 every 28 days, for just over 8 months, from July 2020 to March 2021. Blood count and chemistry panel were obtained every 2 weeks for the first three cycles, neurological assessment and examination every 4 weeks. Best radiological response was stability according to Response Assessment in Neuro-Oncology criteria,

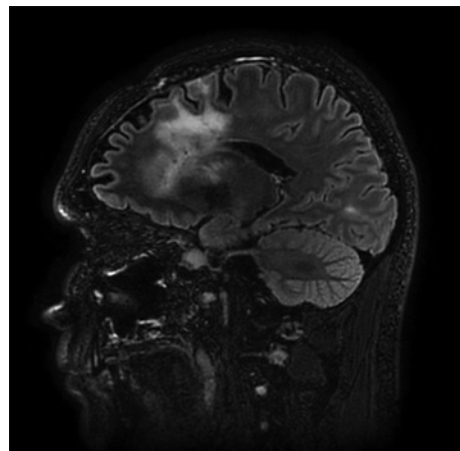


Fig. 1. July 2020 MRI sagittal 3DFLAIR, before starting regorafenib treatment.

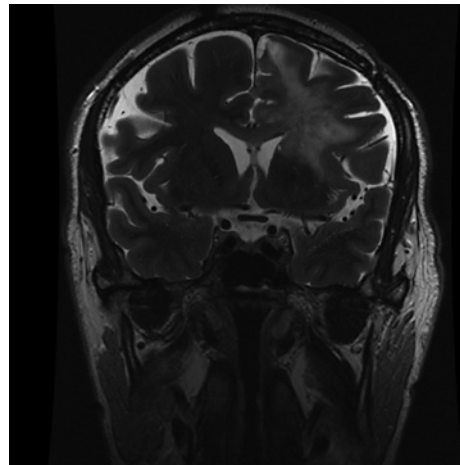


Fig. 2. July 2020, MRI coronal T2 FSE, before starting regorafenib treatment.

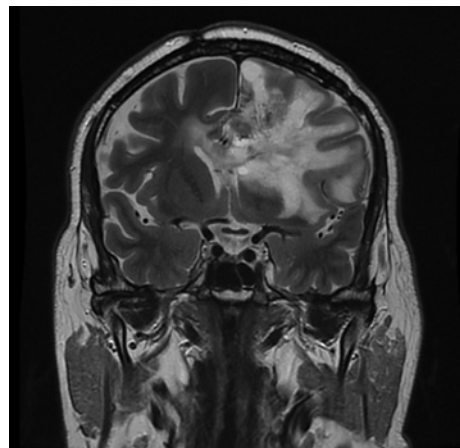


Fig. 3. August 2021, MRI coronal T2 FSE, progression disease.

with a PFS of 8 months. Overall, treatment was well-tolerated, except for grade 1 increase in alanine and aspartate aminotransferases and grade 1 hypertension, both described in REGOMA with an incidence $\leq 10\%$. Treatment was then reduced to 120 mg/day from the sixth cycle, and therapy with antioxidant supplement was prescribed.

The patient was monitored monthly and remained in good clinical conditions, with a Karnofsky performance status of 80% and improvement in headache and motor symptoms, until the last month of treatment, where ataxia and aphasia increased, affecting his daily activities, needing an increase in steroids use, the use of which was low during treatment with regorafenib. Following radiological disease progression and worsening of neurological symptoms (Fig. 3), the patient started fourth-line chemotherapy regimen with intravenous fotemustine

Discussion, Real-Life Data, and Future Perspectives

Following REGOMA, case series and retrospective studies were published, evaluating regorafenib in real-life settings. A retrospective bicentric analysis of a 24 patients' cohort [7] showed a mPFS superimposable to REGOMA's, with worse OS (4.1 months vs. 7.4 months), while another retrospective study [8] evaluating a total of 6 patients showed a

disease control rate of 0%, OS around 6 months, and with all but 1 patient reporting a grade 3 adverse event.

These results, significantly different from the landmark REGOMA trial, may be due to distinct patient characteristics: both included noteworthy heterogeneous populations both in prior recurrences (ranging from first to seventh) and in diagnosis including astrocytomas, oligodendrogliomas, and diffuse midline gliomas. A 2021 retrospective study [9], enrolling 54 patients treated with regorafenib showed similar mPFS (2.3 months) and OS (10.2 months) to the ones in the REGOMA trial.

In the clinical case described, we used regorafenib in a third-line setting for a secondary GBM, with outstanding results. Considering the long survival, in comparison to other patients, DNA sequencing on tumor tissue from 2018 surgery was performed, with mutations reported in CDKN2A/B and PIK3CA and no IDH mutation. For a long time, IDH mutations were considered an important prognostic factor typical of secondary GBM, associated with longer survival [10]. Nevertheless, only 2 patients in the REGOMA trial presented IDH mutation, and, according to the 2021 WHO classification, IDH mutant gliomas are now defined as astrocytomas, not amenable to regorafenib treatment.

A 2018 retrospective single-institution trial on third-line treatment reported mPFS of 2.9 months and mOS of 6.6 months, consistent with our experience [11]. Our patient's PFS reached 9 months, a result greatly exceeding mPFS from REGOMA, 2.0 months. Results from the 2021 retrospective analysis by Lombardi et al. [4] showed an mPFS of 2.3 months and a 6 m-PFS of 18%, indeed comparable to REGOMA. Both trials investigated exclusively the second-line setting. Unfortunately, predictive biomarkers of response to regorafenib are not yet available, although several studies highlighted potential biomarkers.

Based on preclinical studies showing activation of AMPK pathway during antiangiogenic treatment, phosphorylated acetyl-CoA carboxylase was identified as a valuable predictive factor regarding OS [12]. Elevated expression of HIF1a and CDKN1A mRNA and reduced expression of miR-93-5p, miR-3607-3p, and miR301a-3p can help distinguish a favorable subgroup of patients [13]. These findings, given the relatively small population and the study design, must be validated in larger and in prospective trials.

In IDH wild-type MGMT methylated high-grade gliomas, mOS is about 2 years, with mOS at 2 years of 49%. As a result, our patient survival has exceeded the literature median survival time, even in the absence of prognostic factors, reporting an excellent clinical response and radiological benefit, especially when compared with known response rates from clinical trials; in addition, treatment, on the whole well-tolerated, did not worsen the patient's clinical condition, allowing him to start a fourth-line chemotherapy treatment. Indeed, our clinical case could be considered as a starting point to evaluate the use of regorafenib also for later lines beyond the second one, also in settings different from REGOMA's, as regorafenib was used in this patient in secondary glioblastoma.

Statement of Ethics

Ethical approval is not required for this case report in accordance with local or national guidelines. Written informed consent was obtained from the patient for publication of this case report and any accompanying images.

Conflict of Interest Statement

Morena Fasano is part of the Advisory board MSD and Merck Serono S.p.A.

Funding Sources

No funding received.

Author Contributions

Provided study material: Morena Fasano, Michele Orditura, and Fortunato Ciardiello. Concept and design: Morena Fasano, Michele Orditura, Fortunato Ciardiello, Gaetana Messina, Raffaele Rauso, Antonello Sica, and Donato Sciano. Drafting of the manuscript: Morena Fasano, Mario Pirozzi, Marianna Caterino, Sergio Facchini, and Alessia Zotta. Modification of the manuscript: Morena Fasano, Gaetano Facchini, Michele Orditura, and Fortunato Ciardiello contributed equally. Paolo Cappabianca, Teresa Somma, and Francesco Maiuri contributed equally to the revision. All authors approved the final version of the manuscript.

Data Availability Statement

All data generated or analyzed during this study are included in this article. Further inquiries can be directed to the corresponding author.

References

- Ostrom QT, Patil N, Cioffi G, Waite K, Kruchko C, Barnholtz-Sloan JS. CBTRUS statistical report: primary brain and other central nervous system tumors diagnosed in the United States in 2013–2017. *Neuro Oncol*. 2020 Oct;22(12 Suppl 2):IV1–96.
- Stupp R, Mason WP, van den Bent MJ, Weller M, Fisher B, Taphoorn MJB, et al. Radiotherapy plus concomitant and adjuvant temozolomide for glioblastoma. *N Engl J Med*. 2005 Mar 10;352(10):987–96.
- Weller M, le Rhun E. How did lomustine become standard of care in recurrent glioblastoma? *Cancer Treat Rev*. 2020 Jul;87:102029.
- Lombardi G, Pambuku A, Bellu L, Farina M, della Puppa A, Denaro L, et al. Effectiveness of antiangiogenic drugs in glioblastoma patients: a systematic review and meta-analysis of randomized clinical trials. *Crit Rev Oncol Hematol*. 2017 Mar;111:94–102.
- Lombardi G, de Salvo GL, Brandes AA, Eoli M, Rudà R, Faedi M, et al. Regorafenib compared with lomustine in patients with relapsed glioblastoma (REGOMA): a multicentre, open-label, randomised, controlled, phase 2 trial. *Lancet Oncol*. 2019 Jan;20(1):110–9.
- van den Bent MJ, Gorlia T, Bendsuz M, Sahm F, Domont J, Idhahbi A, et al. EH1.3 EORTC 26101 phase III trial exploring the combination of bevacizumab and lomustine versus lomustine in patients with first progression of a glioblastoma. *Neuro Oncol*. 2016;18:1–84.
- Tzaridis T, Gefpner-Tuma I, Hirsch S, Skardelly M, Bender B, Paulsen F, et al. Regorafenib in advanced high-grade glioma: a retrospective bicentric analysis. *Neuro Oncol*. 2019 Jul;21(7):954–5.
- Kebir S, Rauschenbach L, Radbruch A, Lazaridis L, Schmidt T, Stoppek AK, et al. Regorafenib in patients with recurrent high-grade astrocytoma. *J Cancer Res Clin Oncol*. 2019 Apr;145(4):1037–42.
- Lombardi G, Caccese M, Padovan M, Cerretti G, Pintacuda G, Manara R, et al. Regorafenib in recurrent glioblastoma patients: a large and monocentric real-life study. *Cancers*. 2021 Sep;13(18):4731.
- Ohgaki H, Kleihues P. The definition of primary and secondary glioblastoma. *Clin Cancer Res*. 2013 Feb;19(4):764–72.
- Franceschi E, Lamberti G, Paccapelo A, di Battista M, Genestreti G, Minichillo S, et al. Third-line therapy in recurrent glioblastoma: is it another chance for bevacizumab? *J Neuro Oncol*. 2018 Sep;139(2):383–8.
- Indraccolo S, de Salvo GL, Verza M, Caccese M, Esposito G, Piga I, et al. Phosphorylated acetyl-coa carboxylase is associated with clinical benefit with regorafenib in relapsed glioblastoma: REGOMA trial biomarker analysis. *Clin Cancer Res*. 2020 Sep;26(17):4478–84.
- Santangelo A, Rossato M, Lombardi G, Benfatto S, Lavezzari D, de Salvo GL, et al. A Molecular signature associated with prolonged survival in Glioblastoma patients treated with Regorafenib. *Neuro Oncol*. 2021 Feb 25;23(2):264–76.