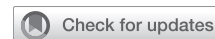

Innominate artery patency after direct cannulation in neonates



Perry S. Choi, MD,^a Teimour Nasirov, MD,^a Frank Hanley, MD,^a Lynn Peng, MD,^b Doff B. McElhinney, MD,^b and Michael Ma, MD^a

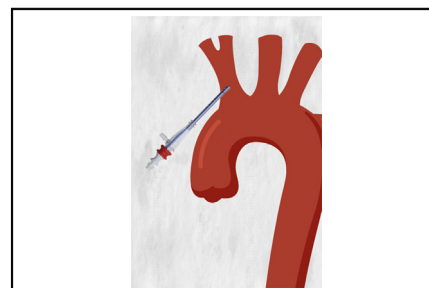
ABSTRACT

Objective: The study objective was to determine the short-term incidence of innominate artery stenosis for neonates who underwent direct innominate artery cannulation during the Norwood procedure.

Methods: This is a retrospective, single-institution review of 92 patients who underwent the Norwood procedure with direct innominate artery cannulation from 2006 to 2017. The primary outcome was angiographic evidence of patency at pre-Glenn cardiac catheterization. Patient characteristics, intraoperative surgical and hemodynamic measurements, and postoperative neurologic findings were recorded.

Results: At a median age of 5.0 days, 92 neonates underwent the Norwood procedure with direct innominate artery cannulation. These patients underwent cardiac catheterization at a median of 3.0 months after the index operation. In 5 of 92 patients with catheterization images available for review, there was angiographic evidence of mild innominate artery stenosis, and none had moderate or severe stenosis. Review of follow-up records did not reveal evidence of clinically significant stenosis or innominate artery reintervention.

Conclusions: In neonates undergoing the Norwood procedure with direct innominate cannulation, innominate artery stenosis was uncommon and clinically significant stenosis did not occur. (JTCVS Techniques 2022;14:171-6)



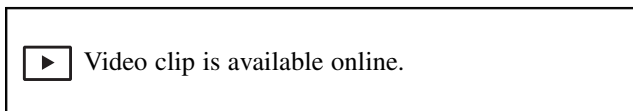
Representation of direct innominate artery cannulation.

CENTRAL MESSAGE

In neonates undergoing Norwood procedure with direct innominate cannulation, innominate artery stenosis was uncommon and clinically significant stenosis did not occur.

PERSPECTIVE

Ideal arterial cannulation strategy in complex arch reconstruction for neonates remains debated. This retrospective study was performed to radiographically assess short-term patency in neonates who underwent direct innominate artery cannulation and suggests high patency rates.



From the Departments of ^aCardiothoracic Surgery, and ^bCardiology, Lucile Packard Children’s Hospital, Stanford University, Palo Alto, Calif.
 Funding source: internally sponsored.
 Institutional Review Board: 61 (registration 4947, e-protocol 52170), approved 7-26-2021.

Received for publication Aug 4, 2021; revisions received Feb 14, 2022; accepted for publication May 17, 2022; available ahead of print June 9, 2022.

Address for reprints: Michael Ma, MD, Falk Research Bldg, Palo Alto, CA 94304 (E-mail: mma@stanford.edu).

2666-2507

Copyright © 2022 The Author(s). Published by Elsevier Inc. on behalf of The American Association for Thoracic Surgery. This is an open access article under the CC BY-NC-ND license (<http://creativecommons.org/licenses/by-nc-nd/4.0/>).

<https://doi.org/10.1016/j.xjtc.2022.06.001>

Strategies for cerebral protection during complex arch reconstruction in neonates have moved toward continuous cerebral perfusion over the past decades, with approximately 50% of surgeons routinely using continuous antegrade cerebral perfusion (ACP) during these operations.¹ However, the ideal arterial cannulation technique for ACP in neonates remains debated. Briefly, there are 3 common strategies: suturing a polytetrafluoroethylene “chimney graft” directly to the innominate artery, cannulating the aorta and repositioning into the innominate artery during ACP, and directly cannulating the innominate artery. The “chimney graft” approach is a familiar technique to many surgeons and may be favored particularly by those who use the modified Blalock–Taussig shunt, because the innominate chimney can be converted into the proximal

Abbreviations and Acronyms

ACP = antegrade cerebral perfusion
NIRS = near-infrared spectroscopy

end of the shunt. However, this technique often takes the longest and is prone to bleeding along the suture lines of the graft.^{2,3} Cannulating the aorta and repositioning the cannula into the innominate artery during ACP are limited to amenable anatomy (requires a sufficiently large ascending aorta), and manipulation of the aortic cannula may result in displacement or worse—periods of circulatory arrest or air embolization. For these reasons, our institution has favored direct innominate artery cannulation.

As described in previous studies,^{4,5} our institution has used direct innominate artery cannulation in both neonates and children with low operative mortality and complication rates (Video 1). However, a question often raised with this technique that has not been thoroughly assessed is the potential risk of postoperative stenosis of the innominate artery. In the present study, we used pre-Glenn cardiac catheterizations to radiographically assess short-term patency rates after direct innominate artery cannulation in patients who previously underwent the Norwood procedure.

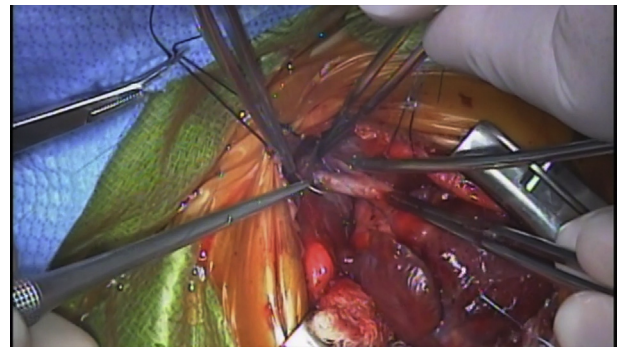
MATERIALS AND METHODS

Study Design

A retrospective, single institution review was performed for all neonates who underwent a Norwood procedure with direct cannulation of innominate artery between January 2007 and December 2017. Angiograms from the pre-Glenn cardiac catheterization were independently reviewed by 2 experienced pediatric interventional cardiologists to evaluate for stenosis, occlusion, or other abnormalities of the innominate artery. Patient characteristics at the time of surgery (age, sex, body surface area) were collected from hospital records, and intraoperative measurements (circuit pressure during ACP, ACP flow, upper-extremity pressures before and during ACP, continuous near-infrared spectroscopy (NIRS) before, during, and after ACP) were collected from perfusion records. Postoperative clinical outcomes (30-day mortality, 30-day neurologic status, innominate artery reinterventions, upper-extremity blood pressure differential) were collected from hospital records. Neurologic status was determined by documented physical examinations by the primary team attending physician. Upper-extremity blood pressure differential was documented for patients with angiographic signs of innominate artery stenosis, and a value of less than 5 mm Hg was considered insignificant. The study was approved by our Institutional Review Board. Statistical analysis was performed using R (version 4.0.4 GUI 1.74 Catalina Build 7936). Data were presented as number (%), mean \pm standard deviation, or median (25th, 75th percentiles). The Institutional Review Board of Stanford University approved the study protocol and publication of data (Institutional Review Board 61, registration 4947, e-protocol 52170; approval period 7/26/21, does not expire). The patients provided informed written consent for the publication of the study data.

Inclusion/Exclusion Criteria

A global search of “Norwood operation” from the internal database returned 126 potential patients. Of these, 7 patients underwent a Norwood variation not requiring Glenn palliation (ie, Norwood hybrid, Yasui/



VIDEO 1. An example of our technique for direct innominate cannulation. Video available at: [https://www.jtcvs.org/article/S2666-2507\(22\)00354-6/fulltext](https://www.jtcvs.org/article/S2666-2507(22)00354-6/fulltext).

Norelli) and therefore did not receive pre-Glenn catheterization. Of the remaining 119 patients who underwent the Norwood operation, 13 did not have appropriate catheterization imaging because of early death before the Glenn, catheterization images were unable to be obtained for 8 patients due to transfer of care or being lost to follow-up, and 6 patients had pre-Glenn catheterizations that did not adequately capture the innominate artery, leaving 92 total catheterizations. Of the 13 patients who died pre-Glenn catheterization, 11 were during initial hospitalization. Cause of death breakdown was as follows: 4 were unable to wean off immediate postoperative extracorporeal membrane oxygenator, 7 experienced cardiac arrest in the setting of intractable hypoxia during the postoperative period, and 2 died of unknown causes in the outpatient setting.

RESULTS

Patient and Valve Characteristics

Ninety-two neonates underwent direct innominate artery cannulation during the study period. No cases required conversion to alternative cannulation strategy. These patients underwent a Norwood procedure at a median age of 5.0 (3.6-8.0) days with a median body surface area of 0.21 (0.20-0.22) m², and median weight 3.20 (2.88-3.50) kg (Table 1). The mean (\pm standard deviation) cardiopulmonary bypass time was 148 \pm 36 minutes, mean crossclamp time was 72 \pm 26 minutes, and mean ACP time was 55 \pm 16 minutes. Approximately two-thirds of cases (48/73) used 40 mL/kg/min for ACP flow rate, 19 of 73 (26%) used 30 mL/kg/min, 6 of 73 (8.2%) used 20 mL/kg/min, and the remaining 19 patients did not have documented ACP flow rate. Line pressure during ACP was appropriately low at an average of 97 \pm 29 mm Hg. Continuous NIRS values were relatively unchanged both during and after ACP compared with the beginning of the case, with an average difference of 1.3% \pm 7.5% ($P = .14$, paired t test) and $-0.8\% \pm 6.5\%$ ($P = .28$, paired t test), respectively. The upper-extremity blood pressure during ACP averaged 23 \pm 14 mm Hg. After decannulation, all patients had normal arterial line measurements in the right radial or right brachial artery, suggesting a lack of immediate postoperative innominate artery stenosis.

TABLE 1. Patient and intraoperative characteristics (N = 92 patients)

No. of surgeries	100	ACP time, min	
		Mean ± SD	55 ± 16
		Median (25th, 75th)	54 (44, 63)
		Max, Min	20, 100
Age at surgery, d		ACP flow, mL/kg/min	
Mean ± SD	7.1 ± 7.4	Mean ± SD	38 ± 6
Median (25th, 75th)	5.0 (3.6, 8.0)	Median (25th, 75th)	40 (30, 40)
Max, Min	1, 49	Max, Min	30, 50
Body surface area, m ²		Line pressure on ACP, mm Hg	
Mean ± SD	0.21 ± 0.03	Mean ± SD	97 ± 29
Median (25th, 75th)	0.21 (0.20, 0.22)	Median (25th, 75th)	91 (79, 116)
Max, Min	0.12, 0.33	Max, Min	33, 203
Weight, kg		Change in NIRS on ACP, %	
Mean ± SD	3.23 ± 0.52	Mean ± SD	1.3 ± 7.5
Median (25th, 75th)	3.27 (2.88, 3.50)	Median (25th, 75th)	0 (-0.5, 0.5)
Max, Min	1.37, 4.60	Max, Min	-23, 33
Bypass time, min		Change in NIRS post-ACP, %	
Mean ± SD	148 ± 36	Mean ± SD	-0.8 ± 6.5
Median (25th, 75th)	144 (127, 165)	Median (25th, 75th)	0 (-0.5, 1)
Max, Min	60, 315	Max, Min	-18, 20
Cross-clamp time, min		Upper-extremity MAP on ACP, mm Hg	
Mean ± SD	72 ± 26	Mean ± SD	23 ± 14
Median (25th, 75th)	67 (55, 84)	Median (25th, 75th)	20 (11, 34)
Max, Min	21, 162	Max, Min	4, 60

The 25th and 75th denote percentiles. ACP, Antegrade cerebral perfusion; SD, standard deviation; NIRS, near-infrared spectroscopy; MAP, mean arterial pressure.

Pre-Glenn Catheterizations

In the 92 patients, cardiac catheterization was performed at a median of 3.0 (2.7-3.4) months after the Norwood operation (Figure 1). Five of 92 (5.4%) catheterizations were identified as having radiographic evidence of mild stenosis and no, moderate, or severe stenosis (Figure 2). Notably, there was no significant difference in the bi-extremity blood pressure differential for these 5 patients, there were no documented symptoms or signs suggestive of clinically significant stenosis, and there were no reinterventions documented. Retrospective chart review revealed there were no issues documented regarding cannulation, and

intraoperative line pressures (mean 103 ± 16 mm Hg) were not significantly than those from the overall population (97 ± 29 mm Hg). Five additional patients were noted to have mild innominate artery irregularities without significant stenosis (Figure 2).

Clinical Outcomes

For the 5 patients with an angiographic suggestion of mild stenosis, upper-extremity pulses and range of motion were symmetric, there were no signs of claudication or skin changes, and blood pressures on the right upper extremity were not significantly lower (>5 mm Hg) than those

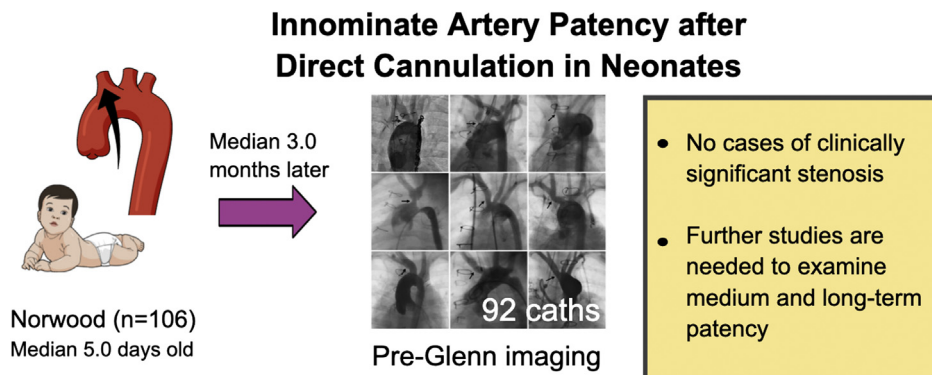


FIGURE 1. Ninety-two patients had cardiac catheterization at a median of 3.0 (2.7-3.4) months after the Norwood operation with direct innominate artery cannulation, and there were no cases of clinically significant stenosis.

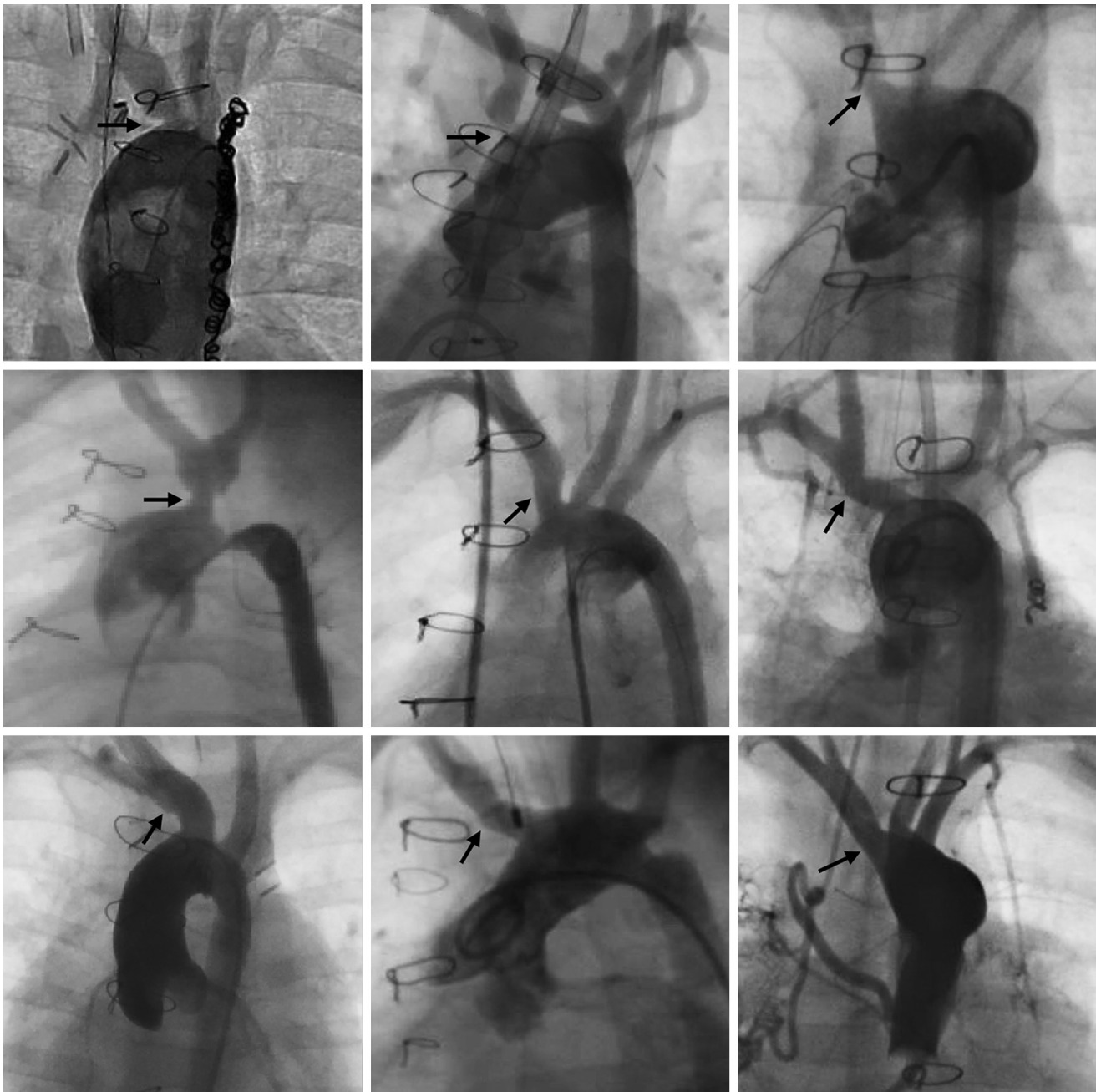

FIGURE 2. Composite image of innominate artery abnormalities. Aortic angiograms for pre-Glenn evaluation are shown in 9 patients with mild stenosis (first 4 panels) or mild distortion/irregularity without stenosis (arrows) of the innominate artery or common brachiocephalic trunk after innominate artery cannulation for ascending aortic and arch reconstruction.

of the left upper extremity at an average of 2.1 ± 1.3 years after the Norwood procedure. Moreover, none underwent transcatheter or surgical reintervention on the innominate artery.

Among the entire cohort, there were 3 deaths and no intraoperative deaths within 30 days of surgery. The 3 deaths occurred in the setting of myocardial dysfunction of

unknown etiology requiring inotropic support postoperatively and ultimately venoarterial extracorporeal membrane oxygenation. All 3 patients were unable to be weaned off extracorporeal membrane oxygenation because of persistent bradycardia and hypotension, and were transitioned to compassionate care. There were no strokes and no clinically evident neurologic deficits within 30 days of operation

based on clinical evaluation by the primary team per discharge documentation.

DISCUSSION

Since its description by Asou and colleagues,⁶ continuous cerebral perfusion via direct innominate cannulation has become a mainstay technique for cerebral protection during arch reconstruction in neonates. Although studies have yet to demonstrate a convincing superiority to traditional deep hypothermic circulatory arrest due to insufficient power,^{2,7-9} continuous cerebral perfusion has emerged as the predominant technique, and our institution has had success in particular with direct innominate artery cannulation.^{1,4,5} In our experience, there are no obvious contraindications, and for anatomic variants such as anomalous right subclavian artery, we will still cannulate the right carotid directly. As mentioned previously, there were zero intraoperative conversions to alternative cannulation strategy for this cohort. High line pressures were also rare, as shown in [Table 1](#). Although we use 8F cannulas in the majority of patients, for very small patients we opt for a 6F cannula and if necessary, can usually troubleshoot simply by placing slight tension on the cannula to take it off the back wall. Relatedly, there is no observed weight limitation for this cannulation technique, with the smallest patient in this cohort weighing 1.37 kg.

Despite the technical advantages in minimizing circulatory arrest, bleeding, and operative time, concerns about postoperative stenosis are often raised. To address this question, the present study examined our institution's Norwood experience and demonstrated through expert review of pre-Glenn cardiac catheterizations high short-term patency rates of the cannulated innominate artery. Intraoperative perfusion and anesthesia records confirmed immediate postoperative patency, as well as stable cerebral perfusion and adequate line pressures throughout the operation.³ The stability of short-term neurologic status, lack of significant upper-extremity blood pressure differences, and absence of clinical suggestions of stenosis or reintervention further support the safety and efficacy of this technique.

Study Limitations

As with all retrospective, observational studies, key limitations include potential selection bias and incomplete data from missing records or incomplete follow-up. Although the present study failed to find any evidence of clinically significant stenosis of the cannulated innominate artery, these results are relevant only to the perioperative and short-term period. Medium- and long-term patency rates cannot be extrapolated from these results and warrant further investigation. Excluding patients who experienced

early deaths that were primarily due to heart failure and intractable hypoxia (unlikely related to innominate artery stenosis), this study had an exclusion fraction of 14 of 106 patients (13.2%) in the final analysis due to lost follow-up and catheterizations that did not adequately capture the innominate artery. Although this is not an insignificant percentage, in the context of 0% clinically significant stenosis, these results remain relevant. It is also important to note that the present study does not compare direct innominate artery cannulation with alternative strategies, but rather focuses only on the safety and efficacy of direct innominate cannulation. This is intentional because of our institutional bias toward direct innominate cannulation and therefore poor comparator groups.

CONCLUSIONS

Direct innominate artery cannulation is a common method of providing cerebral protection during complex arch reconstruction in neonates. The present study confirms that this technique can be used with appropriately low line pressures and stable NIRS intraoperatively, in addition to no clinically significant innominate artery stenosis or neurologic complications in the perioperative and short-term period. Although patients with radiographic evidence of mild stenosis remained symptom free at 2 years from surgery, it will be important in future studies to investigate medium- and long-term patency rates of the cannulated innominate artery.

Conflict of Interest Statement

The authors reported no conflicts of interest.

The *Journal* policy requires editors and reviewers to disclose conflicts of interest and to decline handling or reviewing manuscripts for which they may have a conflict of interest. The editors and reviewers of this article have no conflicts of interest.

References

1. Ohye RG, Goldberg CS, Donohue J, Hirsch JC, Gaies M, Jacobs ML, et al. The quest to optimize neurodevelopmental outcomes in neonatal arch reconstruction: the perfusion techniques we use and why we believe in them. *J Thorac Cardiovasc Surg.* 2009;137:803-6.
2. Goldberg CS, Bove EL, Devaney EJ, Mollen E, Schwartz E, Tindall S, et al. A randomized clinical trial of regional cerebral perfusion versus deep hypothermic circulatory arrest: outcomes for infants with functional single ventricle. *J Thorac Cardiovasc Surg.* 2007;133:880-7.e1.
3. Amir G, Frenkel G, Shukrun G, Gogia O, Bachar O, Bruckheimer E, et al. Direct innominate artery cannulation for antegrade cerebral perfusion in neonates undergoing arch reconstruction. *Ann Thorac Surg.* 2013;95:956-61.
4. Malhotra SP, Hanley FL. Routine continuous perfusion for aortic arch reconstruction in the neonate. *Semin Thorac Cardiovasc Surg Pediatr Card Surg Annu.* 2008;11:57-60.
5. Nasirov T, Mainwaring RD, Reddy VM, Sleasman J, Margetson T, Hanley FL. Innominate artery cannulation and antegrade cerebral perfusion for aortic arch reconstruction in infants and children. *World J Pediatr Congenit Heart Surg.* 2013;4:356-61.

6. Asou T, Kado H, Imoto Y, Shiokawa Y, Tominaga R, Kawachi Y, et al. Selective cerebral perfusion technique during aortic arch repair in neonates. *Ann Thorac Surg.* 1996;61:1546-8.
7. Pigula FA, Nemoto EM, Griffith BP, Siewers RD. Regional low-flow perfusion provides cerebral circulatory support during neonatal aortic arch reconstruction. *J Thorac Cardiovasc Surg.* 2000;119:331-9.
8. Hanley FL. Religion, politics...deep hypothermic circulatory arrest. *J Thorac Cardiovasc Surg.* 2005;130:1236. e1-e8.
9. Visconti KJ, Rimmer D, Gauvreau K, Nido P del, Mayer JE, Hagino I, et al. Regional low-flow perfusion versus circulatory arrest in neonates: one-year neurodevelopmental outcome. *Ann Thorac Surg.* 2006;82:2207-13.

Key Words: aortic reconstruction, congenital, innominate cannulation, neonate, Norwood