



# Three-dimensional Nasolabial Morphologic Alterations Following Le Fort I

Christopher R. DeSesa,  
DMD\*  
Philip Metzler, DMD, MD†  
Rajendra Sawh-Martinez,  
MD‡  
Derek M. Steinbacher, MD,  
DMD†§

**Background:** Le Fort I osteotomy imparts significant changes to the nasolabial region. Past studies have relied on 2-dimensional data and have not delineated differences among various Le Fort I subtypes. The purpose of this study is to 3-dimensionally analyze Le Fort I–induced nasal and lip changes comparing advancement alone versus widening alone [surgically assisted maxillary expansion (SAME)] versus advancement and widening. We hypothesize that the combination of maxillary advancement with widening will result in the most profound changes.

**Methods:** A retrospective cohort study was performed. Included Le Fort I patients were grouped as: (1) nonsegmental straight advancement, (2) widening without advancement, and (3) segmental advancement and widening. Pre- and postoperative 3-dimensional photogrammetry (Canfield) were analyzed. Anthropometric landmarks were placed and measured by 2 independent observers. Statistics involved both paired and unpaired *t* tests (significance =  $P < 0.05$ ).

**Results:** One hundred eight photogrammetric data sets were analyzed, including 46 single-piece, 26 SAME, and 36 segmental. Significant postoperative nasal changes were observed within each intragroup analysis. The most dramatic changes were seen after segmental Le Fort I with advancement and widening, which included alar base width, alar width, nostril width, and soft triangle angle, all  $P < 0.05$ .

**Conclusions:** Le Fort I osteotomy results in significant alteration of the nasolabial morphology. This is the first study to 3-dimensionally analyze nasal changes that occur comparing maxillary advancement alone versus widening alone (SAME) versus advancement with widening. These objective data permit improved patient counseling and surgical planning. (*Plast Reconstr Surg Glob Open* 2016;4:e848; doi: 10.1097/GOX.0000000000000685; Published online 17 August 2016.)

The most significant soft tissue changes after maxillary orthognathic surgery occur within the nasolabial envelope. To effectively guide

treatment and direct patient expectations, it is critical to understand and predict these soft tissue changes. Previous literature has attempted to assess postsurgical soft tissue changes after orthognathic surgery through the use of 2-dimensional (2D) analysis with radiologic superimposition.<sup>1–19</sup> However, high resolution of the 3-dimensional (3D) nasolabial complexity was not permitted using 2D methods. Three-dimensional predictions were introduced in the 1990s.<sup>6–8,20,21</sup> However, these were based on computed tomography (CT) soft tissue, which proved inaccurate.<sup>20,21</sup> The recent advent of 3D photogram-

From the \*Division of Oral and Maxillofacial Surgery, †Division of Plastic and Craniomaxillofacial Surgery, and ‡Division of Plastic and Reconstructive Surgery, and §Yale University School of Medicine, Yale-New Haven Hospital, New Haven, Conn.

Received for publication June 14, 2015; accepted February 26, 2016.

Copyright © 2016 The Authors. Published by Wolters Kluwer Health, Inc. on behalf of The American Society of Plastic Surgeons. All rights reserved. This is an open-access article distributed under the terms of the Creative Commons Attribution-Non Commercial-No Derivatives License 4.0 (CCBY-NC-ND), where it is permissible to download and share the work provided it is properly cited. The work cannot be changed in any way or used commercially.

DOI: 10.1097/GOX.0000000000000685

**Disclosure:** The authors have no financial interest to declare in relation to the content of this article. The Article Processing Charge was paid for by Yale Department of Surgery, Charles Ohse grant.

metry has enabled objective soft tissue surface analysis.<sup>22</sup> Three-dimensional photogrammetric analysis has been recently applied to nasolabial changes after orthognathic surgery.<sup>23–25</sup> However, past studies have either examined small cohorts or emphasized changes after a single-piece Le Fort advancement alone. To our knowledge, there are no studies comparing nasolabial change after different subcategories of Le Fort I movements. In particular, the impact of maxillary advancement, maxillary widening, and a combination of advancement and widening has not been directly compared. The purpose of this study was to 3D describe the nasal changes after single-piece Le Fort I advancement, surgically assisted maxillary expansion (SAME) alone, and segmentally Le Fort I advancement with widening. We hypothesize that concurrent advancement with widening will have the most profound influence on the nasolabial region.

## MATERIALS AND METHODS

### Subjects

This retrospective analysis was performed in concordance with the Yale University Institutional Review Board (protocol number: HIC 1101007932). Patients who underwent single-piece Le Fort I advancement, SAME, and segmental Le Fort I with advancement and widening performed by a single surgeon were included. Exclusion criteria were superior or inferior positioning of the maxilla and previous nasolabial and palatal or midfacial surgery. Demographic information was tabulated, including patients' age and

sex, amount of maxillary advancement and expansion, and follow-up period were documented. Pre- and postoperatively, all subjects were assessed using a 3D photogrammetric imaging technique. The postoperative interval was at least 3 months to exclude any bias due to soft tissue swelling or hematoma.

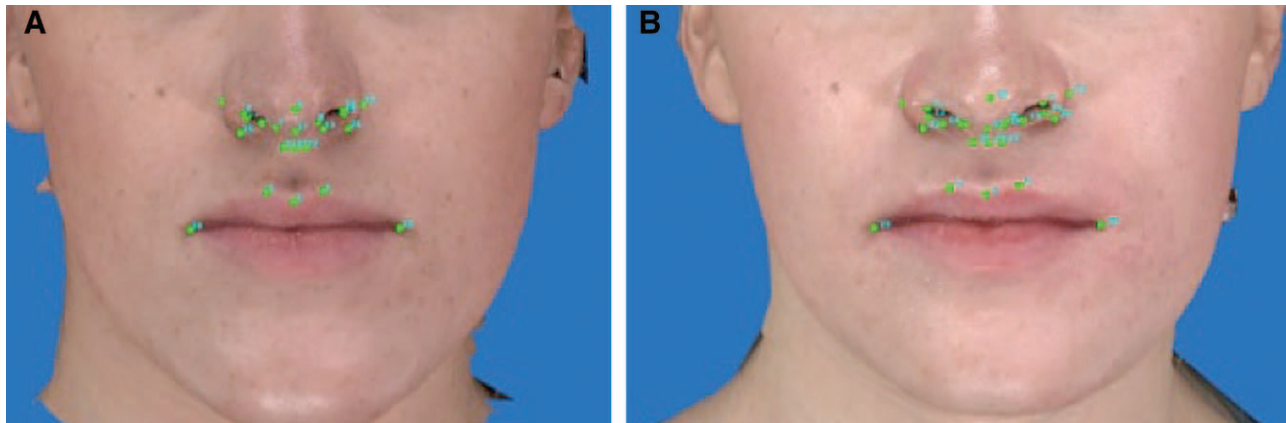
### Imaging and Data Processing

The 3D photogrammetric data were acquired under standard lighting using the 3D VECTRA photosystem (Canfield, Fairfield, N.J.). System calibration was performed before every capture process. Natural head position (Frankfurt horizontal line parallel to the floor) was chosen for data acquisition. Data sets were saved and calculated into a 3D model. Further data processing was performed using the imaging software (Mirror, Canfield, Fairfield, N.J.). Validity and reliability of the 3D photogrammetric tool for anthropometric measurements were confirmed in previous studies.<sup>23,24,26,27</sup>

Two blinded observers indicated the landmarks on each facial soft tissue image (Tables 1 and 2; Fig. 1). The zoom and rotation tools were used to correctly identify and set the landmarks on the 3D surface. It should be noted that there were no significant differences ( $P > 0.05$ ) between the left and the right side for any group for the sill width, nostril height, nostril width, soft tissue triangle, and lateral alar triangle; therefore, the average of both sides was used for comparing postoperative changes. To evaluate postoperative soft tissue changes, a paired 2-sample *t* test was used. An  $\alpha$ -level of  $\leq 0.05$  indicated a significant difference in values.

**Table 1. Landmarks Used for 3D Nasolabial Soft Tissue Assessment**

Landmark	Abbreviation	Definition
Glabella	G	Most anterior projected point of the forehead within the midsagittal plane
Nasion	N	Most depressed midline point superior to the nasal bridge
Alare	Al	Most lateral point of the nasal ala
Subalare	SA	Lowest point of the alar base where the ala meets the nose
Pronasion	Prn	Most anterior point of the nose
Columella peak	CP	Most superior point of the columella
Subnasale	Sn	Midpoint of the nasolabial angle
Medial nostril base	mN	Point on inner nostril where the columella meets the columellar crest
Lateral nostril base	LN	Point on inner nostril where the alar meets the sill
Lateral alar	LA	Most inferolateral point of the nostril
Soft triangle	ST	Most superior medial point of the nostril
Midcolumella	MC	Medial nostril point at midcolumella height level
Lateral crus	LC	Perpendicular to the columella through the MC on the lateral crus
Crista philtri superior	Cphs	Top of the philtral crest at the level of the subnasale
Labiale superius	Ls	Midpoint of the upper vermillion border
Crista philtri inferior	Cphi	Point of maximum vertical height of upper vermillion border (Cupid's bow)
Chelion	Che	Most lateral point of labial commissure
Tragus	Tr	Most anterior point of the tragus



**Fig. 1.** Overview of nasolabial landmarks for pre- (A) and postoperative (B) 3D photometric analysis.

**Table 2. Parameters (Direct Distances and Angles) Used for 3D Nasolabial Soft Tissue Assessment**

Measurement	Abbreviation	Definition
<b>Nose</b>		
Nasofrontal angle	NFA	Angle between G-N-Prn
Nasolabial angle	NLA	Angle between CP-Sn-Ls
Nasal tip projection	NP	Distance between Tr-Prn
Nasal tip prominence	rNP	Distance between Al-Prn
Alar base width	ABW	Distance between SA (l)-SA (r)
Alar width	AW	Distance between Al (l)-Al (r)
Sill width right	SWr	Distance between mNb-INb (r)
Sill width left	SWl	Distance between mNb-INb (l)
Nostril height right	NHr	Distance between LA-ST (r)
Nostril height left	NHl	Distance between LA-ST (l)
Nostril width right	Nwr	Distance between MC-LC (r)
Nostril width left	Nwl	Distance between MC-LC (l)
Soft triangle angle right	STAR	Angle between MC-ST-LC (r)
Soft triangle angle left	STAl	Angle between MC-ST-LC (l)
Lateral alar angle right	LAAr	Angle between INb-LA-LC (r)
Lateral alar angle left	LAAl	Angle between INb-LA-LC (l)
Columella width	CW	Distance between MC (r)-MC (l)
Columella height	CH	Distance between Sn-CP
Columella projection	CP	Distance between Tr-CP
<b>Lip</b>		
Subnasale projection	SnP	Distance between Tr-Sn
Lower philtrum width	LPW	Distance between Cphi (r)-Cphi (l)
Upper philtrum width	UPW	Distance between Cphs (r)-Cphs (l)
Philtrum height	PH	Distance between Ls-Sn
Lip width	LW	Distance between Che (r)-Che (l)
Labiale superius projection	LSP	Distance between Tr-Ls

Al, alare; Che, chelion; CP, columella peak; Cphi, crista philtri inferior; Cphs, crista philtri superior; G, glabella; LA, lateral alar; LC, lateral crus; IN, lateral nostril base; Ls, labiale superius; MC, midcolumella; mN, medial nostril base; N, nasion; Prn, pronasion; SA, subalare; Sn, subnasale; ST, soft triangle; Tr, tragus.

## RESULTS

One hundred eight 3D photogrammetric data sets were included (54 pre- and postoperative 3D photogrammetric analysis). Male/female ratio was 1.0, with a mean age of 23.5 years. No significant difference was found between male/female ratio and mean age among the groups. Also, no significant changes existed among the groups with regard to soft tissue closure, as a standard alar cinch and V-Y closure was performed for each patient to control the alar base and the upper lip respectfully. Postoperative images were analyzed from an average of 8.7

months postoperatively. Mean maxillary advancement for the single-piece Le Fort group was 5.8 ( $\pm 1.8$ ) mm. Mean maxillary advancement and mean transverse expansion for the segmental groups were 5.6 ( $\pm 2.3$ ) mm and 5 ( $\pm 1.2$ ) mm, respectively. Mean transverse expansion for the SAME group was 7 ( $\pm 2.1$ ) mm. There was no statistically significant difference in the amount of advancement between the single-piece and segmental groups, but there was a statistically significant difference in the amount of expansion between the segmental and the SAME group, with more expansion after SAME (Table 3).

**Table 3. Demographics**

Patients	Age (y)	Male/Female	Advancement in Single-piece Group (mm)	Advancement in Segmental Group (mm)	Expansion in Segmental Group (mm)	Expansion in SAME Group (mm)	Follow-up (mo)
T: 54	23.5	27/27	5.8	5.6	5	7	8.7
SP: 23	(range, 16–62)		(range, 3–10)	(range, 2–10)	(range, 3–8)	(range, 6–12)	(range, 5–14)
S: 18							
SM: 13							

S, segmental group; SM, surgically assisted maxillary expansion group; SP, single-piece group; T, total.

**Table 4. Anthropometric Evaluation Before and After Single-piece Maxillary Advancement (n = 23)**

Measurement	T1	T2	Δ T2 – T1	CI	P Value
<b>Nose</b>					
Nasofrontal angle	145.0±5.5	141.5±6.0	-3.5±1.8	-4.1 to -2.7	0.047*
Nasolabial angle	111.3±12.9	116.1±13.8	5.1±11.0	5.0 to 2.6	0.030*
Nasal tip projection	126.5±15.2	128.6±16.2	1.9±2.3	1.0 to 2.8	0.655
Nasal tip prominence	29.7±2.9	30.0±3.5	0.3±3.1	-0.9 to 1.5	0.731
Alar base width	29.1±3.0	31.6±3.7	2.5±1.6	1.9 to 3.1	0.014*
Alar width	34.1±2.6	36.9±3.2	2.8±1.6	2.2 to 3.5	0.002*
Sill width	7.1±1.5	6.8±1.7	-0.3±0.9	-0.7 to 0.1	0.480
Nostril height	13.9±2.3	12.7±1.9	-1.3±1.2	-1.7 to -0.7	0.048*
Nostril width	10.7±1.9	12.0±2.5	1.2±1.2	0.7 to 1.7	0.048*
Soft triangle angle	71.7±12.4	80.0±11.7	7.8±4.9	5.8 to 9.8	0.033*
Lateral alar angle	109.7±14.7	101.0±13.3	-8.7±5.3	-10.9 to -6.5	0.041*
Columella width	6.7±1.2	6.5±0.8	-0.2±1.1	-0.6 to 0.3	0.577
Columella height	11.2±1.5	10.1±2.1	-0.9±1.1	-1.0 to -0.2	0.001*
Columella projection	122.8±15.0	124.6±16.0	1.8±2.2	1.0 to 2.8	0.686
<b>Lip</b>					
Subnasale projection	114.3±14.5	115.6±15.3	1.3±1.8	0.6 to 2.0	0.772
Lower philtrum width	11.6±1.8	12.7±1.9	1.0±0.8	0.7 to 1.3	0.076
Upper philtrum width	7.5±2.1	8.2±2.4	0.7±1.3	0.2 to 1.2	0.288
Philtrum height	14.9±3.1	15.2±3.0	0.3±1.4	-0.3 to 0.8	0.756
Mouth width	49.5±2.4	50.5±3.6	0.9±2.5	-0.1 to 1.9	0.314
Labiale superius projection	115.9±15.2	119.2±16.4	3.3±2.1	2.4 to 4.2	0.001*

\**P* < 0.05.

CI, confidence interval; Δ, difference; T1, preoperative; T2, postoperative.

Pre- and postoperative measurements for all 3 groups were recorded for all nasolabial parameters along with *P* values obtained using a 2-sample paired *t* test for each parameter (Tables 4–6). Figures 2, 3, and 4 show the postoperative nasolabial changes for all 3 groups using a mesh 3D photometric overlay.

The nasolabial response after single-piece Le Fort I with advancement only showed a statistically significant decrease in nasofrontal angle, nostril height, columella height, and lateral alar angle. However, the following nasolabial parameters increased after single-piece Le Fort I advancement: nasolabial angle, nasal tip prominence, alar base width, alar width, nostril width, soft triangle angle, columella projection, and upper lip projection (labiale superius projection) (Table 4).

After SAME (widening only) group, the only statistically significant nasolabial change was seen with an increase in alar base width (Table 5). The nasolabial response after segmental Le Fort I with advancement and widening showed a statistically significant decrease in nostril height, columella height, and lateral alar angle. However, the following nasolabial

parameters increased after segmental Le Fort I with advancement and widening: nasolabial angle, nasal tip prominence, alar base width, alar width, nostril width, soft triangle angle, columella projection, upper philtrum width, and upper lip projection (labiale superius projection) (Table 6).

Cross-group analysis using a 2-sample unpaired *t* test was performed for parameters in which more than 1 group showed statistically significant changes. This analysis revealed most significant (*P* < 0.05) changes in alar base width, alar width, nostril width, and soft tissue triangle in the segmental Le Fort group (alar base width: Δ3.9±1.6, alar width: Δ4.5±1.4, nostril height: Δ-2.0±1.4, nostril width: Δ1.6±0.7, soft triangle angle: Δ11.2±5.0). Cross-group analysis also revealed most significant (*P* < 0.05) changes in the lateral alar angle to be in single-piece Le Fort I advancement (Δ-8.7±5.3).

## DISCUSSION

Treatment objectives for orthognathic surgery include both creation of a functional occlusion and

**Table 5. Anthropometric Evaluation Before and After Surgically Assisted Maxillary Expansion**

Measurement	T1	T2	$\Delta$ T2 – T1	CI	P Value
Nose					
Nasofrontal angle	146.7±9.0	144.1±9.1	-2.7±2.2	-3.9 to -1.5	0.460
Nasolabial angle	131.5±13.5	129.4±14.0	-2.0±4.3	-4.3 to 0.3	0.709
Nasal tip projection	102.0±18.3	102.8±18.6	0.9±0.6	0.5 to 1.3	0.927
Nasal tip prominence	20.2±19.6	19.6±2.1	-0.6±1.1	-1.3 to 0.0	0.555
Alar base width	25.2±4.2	30.8±6.1	3.5±3.6	1.3 to 5.7	0.047*
Alar width	32.3±4.4	34.1±4.5	1.7±1.6	-0.8 to 2.6	0.330
Sill width	8.8±1.7	9.3±1.8	0.5±0.4	0.3 to 0.7	0.523
Nostril height	13.2±0.7	13.4±0.5	0.0±0.6	-0.4 to 0.4	0.479
Nostril width	8.5±1.8	9.3±1.3	0.7±0.9	0.2 to 1.3	0.261
Soft triangle angle	76.6±10.3	74.3±11.6	-2.2±8.5	-7.5 to 3.1	0.636
Lateral alar angle	91.3±15.5	86.6±12.8	-4.7±10.7	-11.3 to 1.9	0.418
Columella width	6.5±0.7	6.5±0.5	0.0±0.4	-0.2 to 0.2	0.950
Columella height	10.6±2.3	11.1±2.4	0.5±2.0	-0.6 to 1.6	0.604
Columella projection	94.6±18.1	95.9±18.0	1.2±0.9	0.7 to 1.7	0.866
Lip					
Subnasale projection	93.3±19.0	94.4±18.7	0.9±0.6	0.5 to 1.3	0.899
Lower philtrum width	12.4±2.3	12.6±1.7	0.2±0.9	-0.3 to 0.7	0.776
Upper philtrum width	9.2±1.2	9.6±1.3	0.4±1.3	-0.3 to 1.1	0.444
Philtrum height	15.9±2.6	16.2±2.5	0.2±0.9	-0.2 to 0.7	0.815
Mouth width	49.1±4.6	50.3±6.0	1.2±3.2	-0.5 to 2.9	0.562
Labiale superius projection	95.1±16.6	95.8±16.2	0.7±0.9	0.2 to 1.3	0.918

\* $P < 0.05$ .CI, confidence interval;  $\Delta$ , difference; T1, preoperative; T2, postoperative.**Table 6. Anthropometric Evaluation Before and After Segmental Maxillary Advancement and Widening**

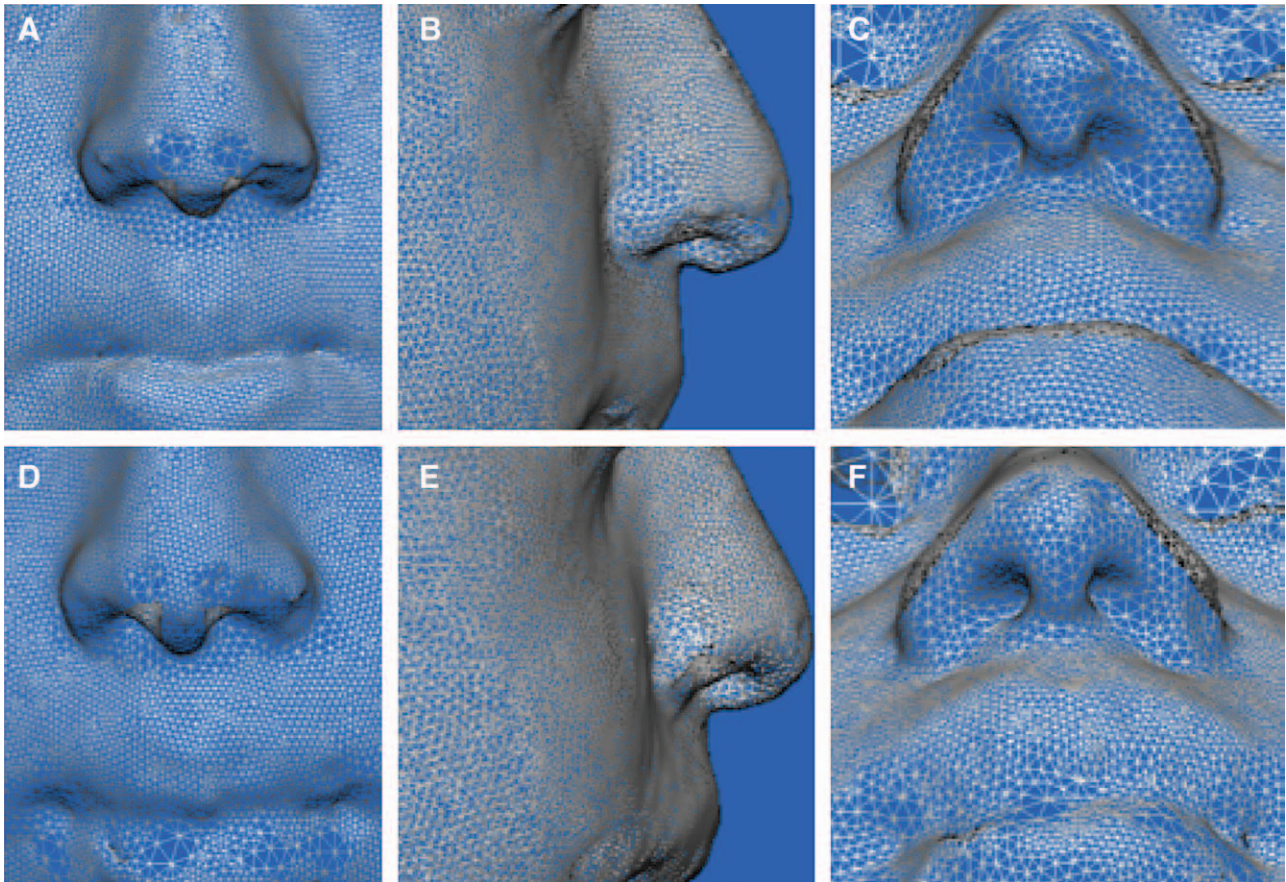
Measurement	T1	T2	$\Delta$ T2 – T1	CI	P Value
Nose					
Nasofrontal angle	147.0±8.6	143.7±9.4	-3.3±1.8	-4.1 to -2.5	0.280
Nasolabial angle	110.6±15.7	117.8±10.0	7.1±12.7	3.9 to 2.7	0.029*
Nasal tip projection	130.5±11.8	132.1±11.9	1.6±1.0	1.1 to 2.1	0.690
Nasal tip prominence	28.8±3.4	31.0±3.8	2.1±4.3	-0.5 to 1.7	0.049*
Alar base width	30.1±1.5	34.1±1.6	3.9±1.6	3.2 to 4.6	0.001*
Alar width	31.6±1.5	36.1±1.9	4.5±1.4	3.9 to 5.2	0.001*
Sill width	6.5±2.0	6.1±1.9	-0.5±0.5	5.2 to 7.0	0.480
Nostril height	13.7±2.0	11.8±1.8	-2.0±1.4	-2.7 to -1.4	0.004*
Nostril width	10.2±2.0	11.8±1.7	1.6±0.7	1.2 to 2.0	0.011*
Soft triangle angle	70.1±9.0	81.2±10.5	11.2±5.0	8.9 to 13.5	0.002*
Lateral alar angle	113.2±7.9	105.2±8.5	-8.0±7.4	-11.4 to -4.6	0.006*
Columella width	6.3±0.6	6.2±0.6	-2.6±7.0	-0.2 to 0.0	0.770
Columella height	12.0±2.0	10.6±2.0	-1.3±1.0	-1.0 to 0.3	0.001*
Columella projection	127.4±11.2	129.1±11.0	1.7±0.9	1.3 to 2.1	0.654
Lip					
Subnasale projection	118.6±15.7	121.0±15.6	2.5±1.2	-2.0 to 3.1	0.639
Lower philtrum width	12.3±2.1	12.9±2.0	0.6±1.5	-0.1 to 1.3	0.352
Upper philtrum width	8.0±1.7	9.2±1.8	1.2±1.1	0.7 to 1.7	0.047*
Philtrum height	14.6±3.4	14.5±3.1	-0.1±1.1	-0.6 to 0.4	0.947
Mouth width	48.9±4.3	51.1±5.0	2.2±2.5	1.1 to 3.4	0.171
Labiale superius projection	120.5±14.8	123.6±14.7	3.1±2.1	2.1 to 4.1	0.001*

\* $P < 0.05$ .CI, confidence interval;  $\Delta$ , difference; T1, preoperative; T2, postoperative.

optimizing facial aesthetics. Traditional emphasis has been placed on skeletal jaw movements to establish a proper occlusion, with requisite soft tissue changes being a secondary benefit. It is widely recognized, however, that maxillary repositioning alters the form and position of the upper lip and nose. In some instances, these morphologic changes are favorable and desirable. However, the nose and lip can be made less aesthetic after Le Fort I.<sup>1,2</sup> To optimally

use nasal changes after Le Fort I to enhance aesthetics, these predictable patterns of change should be objectively elucidated. Such understanding also will permit counseling and advance warning to the patient when detrimental nasolabial alterations are anticipated.

Most current understanding of Le Fort I-induced nasolabial changes is based on reports using 2D radiologic shadows, hindering complete



**Fig. 2.** Overview of nasolabial landmarks for pre- (A, B, C) and postoperative (D, E, F) 3D photometric analysis (mesh) for single-piece maxillary advancement.

morphometric understanding.<sup>1,2,9-12</sup> In addition, a delineation of nasal changes following different subtypes or magnitudes of Le Fort I has not been performed. Three-dimensional photogrammetry has proven accurate in assessing nasal soft tissue morphology for single-piece Le Fort I.<sup>25</sup> However, comparison of upper lip and nasal changes after multipiece segmental Le Fort I is not present in the literature. We know that both advancement and widening of the maxilla produce the requisite changes to the nose. The relative influence of each type of movement has not been compared. The aim of this study was to then (1) describe Le Fort 3D nasolabial changes, and (2) compare the impact of maxillary widening, advancement, and combination advancement/widening on the nose and upper lip position. Given the combination of advancement and widening, we expected the most profound nasal change in this group.

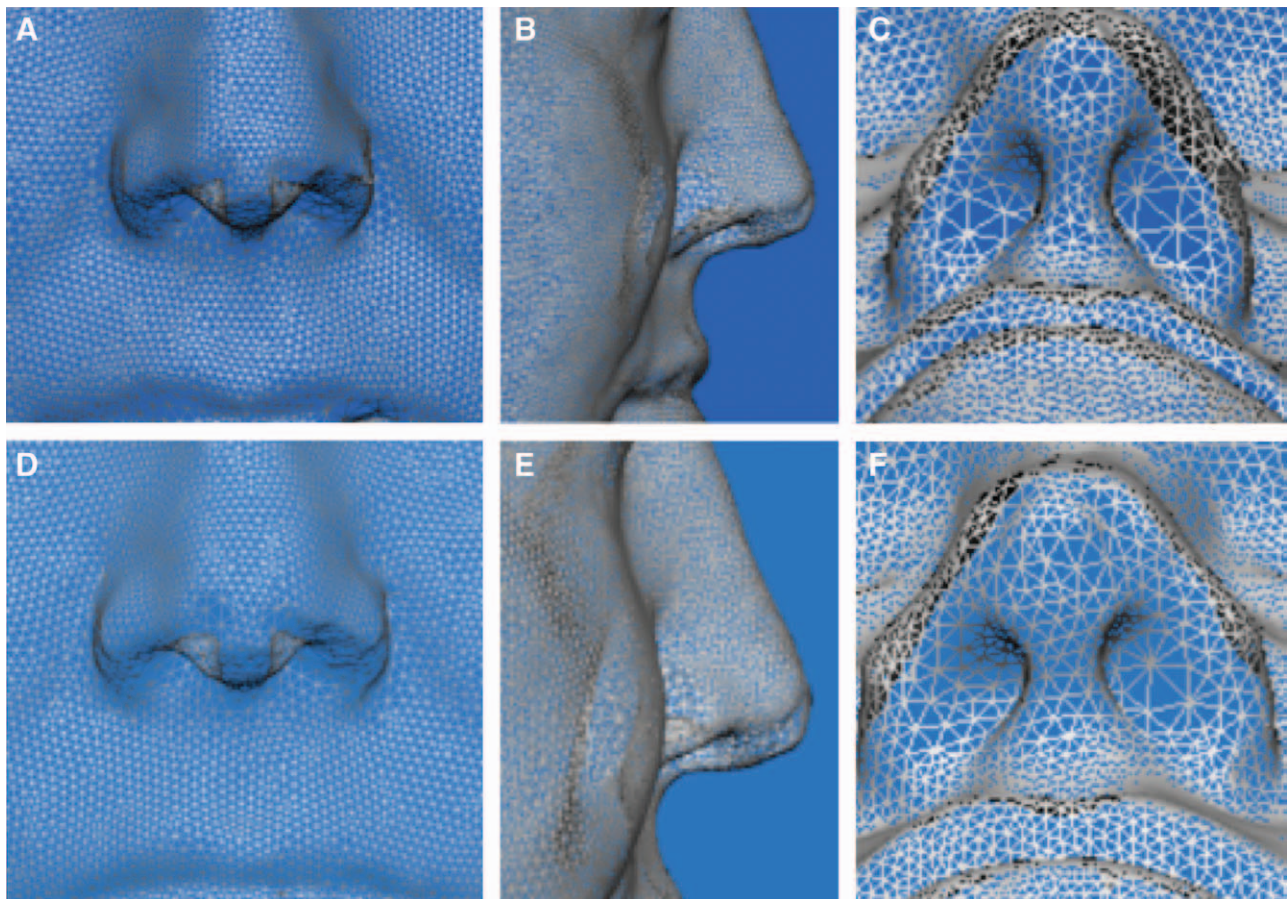
The data showed a significantly decreased nasofrontal angle, between 2 and 5 degrees, after a single-piece Le Fort I advancement, with no significant changes to the nasofrontal angle observed after segmental Le Fort I advancement or SAME. Nasofrontal

angle changes seem to be independent of skeletal movements and have been shown to occur mainly as a result of freeing of the nasal septum during soft tissue degloving.<sup>28</sup>

We hypothesized that the greatest nasolabial changes in the frontal horizontal dimension would occur in the expansion groups (ie, SAME and segmental Le Fort I). A significant increase in alar base width was observed in all 3 groups. Nevertheless, the greatest postoperative increases in alar base width and alar width were observed after a segmental Le Fort I advancement.

Changes in nostril dimensions (including nostril height and nostril width) and in shape (including soft triangle angle and lateral alar angle) after segmental Le Fort I advancement seemed to display similar patterns as those of the single-piece Le Fort I advancement.

After both advancement alone and advancement with widening, the nostrils took on a more rounded shape, showing a height reduction and width increase, becoming more horizontal from the submental view. Nostril morphology after SAME also widened but more inconsistently. Perhaps this

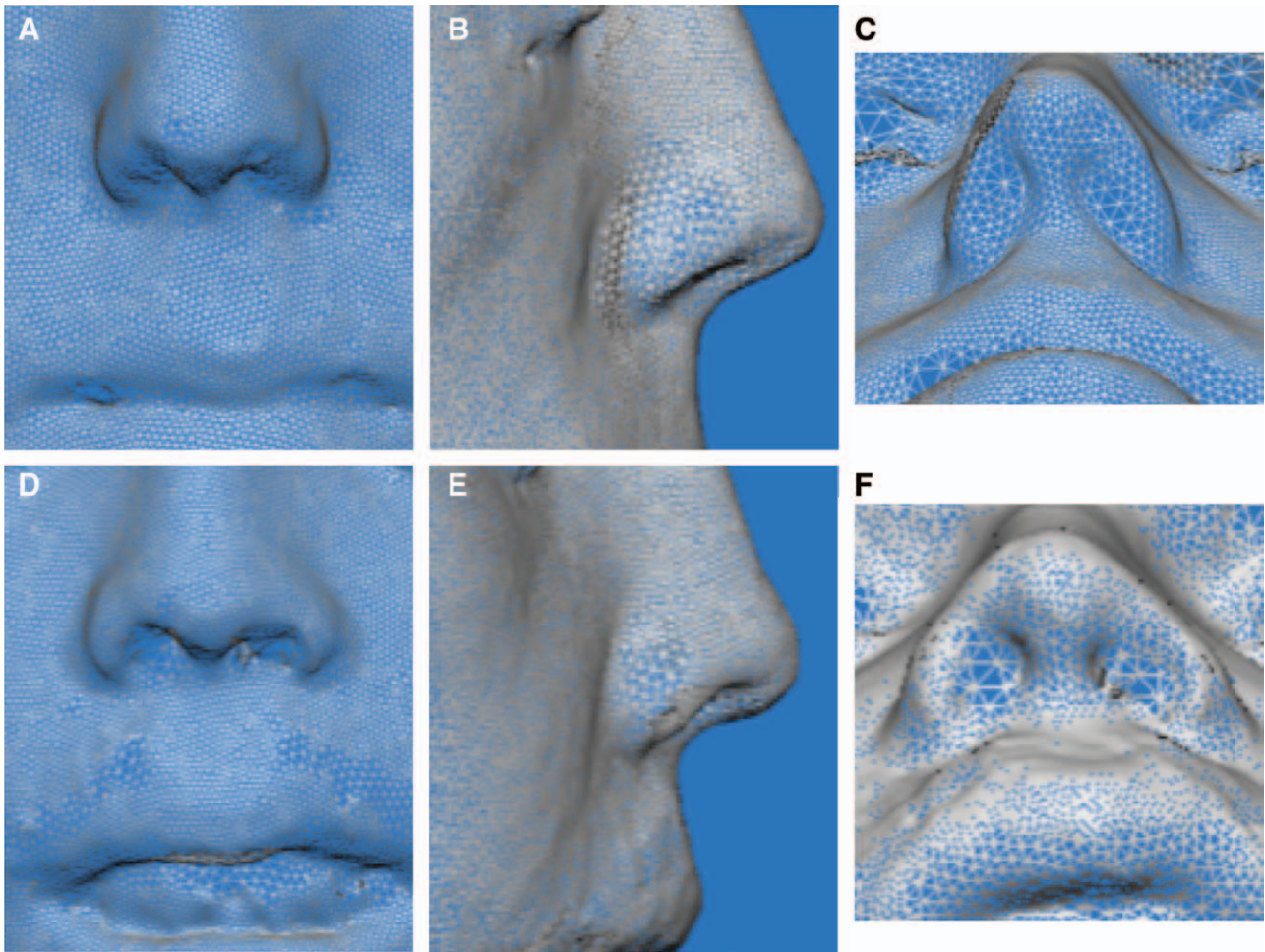


**Fig. 3.** Overview of nasolabial landmarks for pre- (A, B, C) and postoperative (D, E, F) 3D photometric analysis (mesh) for surgically assisted maxillary expansion.

is related to unequal expansion from one side to the other. However, the greatest changes in all the aforementioned parameters occurred in the segmental Le Fort I advancement with widening group (ie, decrease in nostril height, increase in nostril width, decrease in soft triangle angle, and decrease in lateral alar angle). Although columella width remained relatively unchanged among all groups, columella height decreased among the single-piece and segmental groups, whereas columella projection increased in both groups. The nasolabial angle and nasal tip prominence increased within the single-piece and segmental groups. Increase in the upper philtrum width was only observed within the segmental group, whereas upper lip projection occurred within both the single-piece and the segmental groups. It should be noted, however, that while our data measured nasal tip projection relative to the measured distance from the tragus to pronasale, changes to the absolute value can be implied from the data we obtained regarding changes to the columella. The absolute change in nasal tip projection (from subnasale to pronasale) decreases after ad-

vancement and advancement with widening, which is supported by the fact that the columella height decreases and columella projection increases, thus leading to a “buckling” effect of the columella resulting in an absolute shortening of the nasal tip projection in relation to the upper lip.

In summary, our current study reveals that maxillary advancement has a significantly greater impact on postoperative nasolabial projection and transverse nasolabial dimensions than does maxillary widening alone. Combining both advancement and widening (segmental Le Fort) was shown to have the greatest impact on the nasolabial region. The sagittal advancement contributes greatest to these changes as SAME (which involves the largest magnitude of maxillary expansion only with no advancement) showed the least amount of nasolabial alteration postoperatively. It appears then that continuous widening seems to significantly reduce soft tissue adverse effects, whereas advancement seems to play a larger role in nasolabial changes than does widening. This is especially interesting given that the maxillary widening using SAME procedure is more



**Fig. 4.** Overview of nasolabial landmarks for pre- (A, B, C) and postoperative (D, E, F) 3D photometric analysis (mesh) for segmental maxillary advancement and widening.

pronounced within the anterior maxilla directly abutting the overlying soft tissues compared with the segmental maxillary osteotomy, which preferentially widens the posterior maxilla. It is for this reason, we believe, that single-piece Le Fort I advancement and multipiece Le Fort I advancement/widening have a similar overall effect on the nasolabial soft tissues. We hypothesize that the continuous, yet, large degree of distraction, especially within the anterior maxillary region, in combination with a stable columella width, is responsible for this phenomenon.

However, our current findings only represent a fraction of the wide variety of soft tissue changes resulting from orthognathic maxilla surgery. Individual anatomic structural differences and the variability in surgical osteotomies—including ramped versus parallel to the maxillary plane, with or without fracture of the lateral nasal wall or pterygomaxillary junction, 2 or multiple pieces, and more—considerably influence the 3D skeletal movements and the corresponding overlying soft tissues. In addition,

soft tissue closure techniques (such as V-Y, alar base suture, and their various modifications) play an important role in the establishment or reconstruction of aesthetic facial proportions and dimensions after skeletal movement. More attention should be paid to that in the daily routine.

Only an in-depth understanding of the impact of orthognathic procedures on 3D nasal morphology allows an individually tailored treatment plan to achieve the best aesthetic results. Patient counseling and postoperative prediction planning will be considerably more reliable today and in the future by utilizing 3D analytical tools.

Given what we now know about postoperative nasolabial morphology after Le Fort I, we recommend placing special consideration on patients who present with unfavorable preoperative nasolabial parameters, such as an obtuse nasolabial angle, a prominent nasal tip, columella projection, and upper lip projection; a wide alar width, alar base, nostril width, and upper philtrum width; a narrow



alar angle; and a short nostril height, upper lip length, and columella height. If such abnormalities exist preoperatively, it can be expected that they will change more dramatically after maxillary advancement or advancement with widening and may need to be addressed concurrently or later. The morphologic prediction and understanding gained from our 3D results allow proper counseling regarding the potential for improvement or worsening of the nasolabial form, with attention to individual LeFort procedure subtypes.

## CONCLUSIONS

Maxillary advancement with or without widening significantly influences nasolabial morphology greater than maxillary widening alone. Segmental LeFort I with advancement and widening exhibits the greatest nasolabial change, whereas SAME has the least effect. These expected nasolabial alterations should be considered in treatment planning.

**Derek M. Steinbacher, MD, DMD**

Division of Plastic and Craniomaxillofacial Surgery  
Yale University School of Medicine  
New Haven, CT  
E-mail: derek.steinbacher@yale.edu

## REFERENCES

- Obwegeser HL. Principles in treatment planning of facial skeletal anomalies. *Clin Plast Surg*. 2007;34:585–587.
- Obwegeser HL, Marentette LJ. Profile planning based on alterations in the positions of the bases of the facial thirds. *J Oral Maxillofac Surg*. 1986;44:302–311.
- Kahnberg KE. Transverse expansion of the maxilla using a multisegmentation technique. *Scand J Plast Reconstr Surg Hand Surg*. 2007;41:103–108.
- Kahnberg KE, Hagberg C. The approach to dentofacial skeletal deformities using a multisegmentation technique. *Clin Plast Surg*. 2007;34:477–484.
- Vasudavan S, Jayaratne YSN, Padwa BL. Nasolabial soft tissue changes after LeFort I advancement. *J Oral Maxillofac Surg*. 2012;70:e270–e277.
- Dann JJ III, Fonseca RJ, Bell WH. Soft tissue changes associated with total maxillary advancement: a preliminary study. *J Oral Surg*. 1976;34:19–23.
- Lines PA, Steinhauser WW. Soft tissue changes in relationship of movement of hard structures in orthognathic surgery. *J Oral Surg*. 1974;32:891.
- Burstone CJ, James RB, Legan H, et al. Cephalometrics for orthognathic surgery. *J Oral Surg*. 1978;36:269–277.
- Rosen HM. Lip-nasal Is following LeFort I osteotomy. *Plast Reconstr Surg*. 1988;81:171–182.
- Schendel SA, Williamson LW. Muscle reorientation following superior repositioning of the maxilla. *J Oral Maxillofac Surg*. 1983;41:235–240.
- Carlotti AE Jr, Aschaffenburg PH, Schendel SA. Facial changes associated with surgical advancement of the lip and maxilla. *J Oral Maxillofac Surg*. 1986;44:593–596.
- Mommaerts MY, Lippens F, Abeloos JV, et al. Nasal profile changes after maxillary impaction and advancement surgery. *J Oral Maxillofac Surg*. 2000;58:470–475; discussion 475–476.
- Hack GA, de Mol van Otterloo JJ, Nanda R. Long-term stability and prediction of soft tissue changes after LeFort I surgery. *Am J Orthod Dentofacial Orthop*. 1993;104:544–555.
- Mansour S, Burstone C, Legan H. An evaluation of soft-tissue changes resulting from LeFort I maxillary surgery. *Am J Orthod*. 1983;84:37–47.
- Jensen AC, Sinclair PM, Wolford LM. Soft tissue changes associated with double jaw surgery. *Am J Orthod Dentofacial Orthop*. 1992;101:266–275.
- Legan HL, Burstone CJ. Soft tissue cephalometric analysis for orthognathic surgery. *J Oral Surg*. 1980;38:744–751.
- Pospisil OA. Reliability and feasibility of prediction tracing in orthognathic surgery. *J Craniomaxillofac Surg*. 1987;15:79–83.
- Carlotti AE Jr, Aschaffenburg PH, Schendel SA. Facial changes associated with surgical advancement of the lip and maxilla. *J Oral Maxillofac Surg*. 1986;44:593–596.
- Stella JP, Streater MR, Epker BN, et al. Predictability of upper soft tissue changes with maxillary advancement. *J Oral Maxillofac Surg*. 1989;47:697.
- Altobelli DE, Kikinis R, Mulliken JB, et al. Computer-assisted three-dimensional planning in craniofacial surgery. *Plast Reconstr Surg*. 1993;92:576–585; discussion 586.
- McCance AM, Moss JP, Fright WR, et al. A three dimensional analysis of soft and hard tissue changes following bimaxillary orthognathic surgery in skeletal III patients. *Br J Oral Maxillofac Surg*. 1992;30:305.
- 3dMDface System*. Available at: www.3dmd.com. Accessed November 6, 2007.
- Metzler P, Geiger EJ, Chang CC, et al. Surgically assisted maxillary expansion imparts three-dimensional nasal change. *J Oral Maxillofac Surg*. 2014;72:2005–2014.
- Metzler P, Geiger EJ, Chang CC, et al. Assessment of three-dimensional nasolabial response to LeFort I advancement. *J Plast Reconstr Aesthet Surg*. 2014;67:756–763.
- Yamada T, Mishima K, Moritani N, et al. Nasolabial morphologic changes after a LeFort I osteotomy: a three-dimensional anthropometric study. *J Craniofac Surg*. 2010;21:1089–1095.
- Metzler P, Bruegger LS, Kruse Gujer AL, et al. Craniofacial landmarks in young children: how reliable are measurements based on 3-dimensional imaging? *J Craniofac Surg*. 2012;23:1790–1795.
- Metzler P, Sun Y, Zemann W, et al. Validity of the 3D VECTRA photogrammetric surface imaging system for cranio-maxillofacial anthropometric measurements. *Oral Maxillofac Surg*. 2014;18:297–304.
- McFarlane RB, Frydman WL, McCabe SB, et al. Identification of nasal morphologic features that indicate susceptibility to nasal tip deflection with the LeFort I osteotomy. *Am J Orthod Dentofacial Orthop*. 1995;107:259–267.