




CASE REPORT

**REVISED** Case Report: Synchronous primary malignancy including the breast and endometrium [version 3; referees: 2 approved]

Elham Sadat Banimostafavi<sup>1</sup>, Sepideh Tayebi<sup>2</sup>, Maryam Tayebi <sup>1</sup>, Fatemeh Montazer<sup>3</sup>

<sup>1</sup>Radiology Department, Mazandaran University of Medical Sciences, Sari, Iran

<sup>2</sup>Medical School, Tehran University of Medical Sciences, Tehran, Iran

<sup>3</sup>Department of Pathology, Gastrointestinal Cancer Research Center, Imam Khomeini Hospital, Mazandaran university of Medical Sciences, Sari, Iran

**v3** First published: 17 Aug 2017, 6:1502 (doi: [10.12688/f1000research.11971.1](https://doi.org/10.12688/f1000research.11971.1))  
 Second version: 14 Dec 2017, 6:1502 (doi: [10.12688/f1000research.11971.2](https://doi.org/10.12688/f1000research.11971.2))  
 Latest published: 04 Jul 2018, 6:1502 (doi: [10.12688/f1000research.11971.3](https://doi.org/10.12688/f1000research.11971.3))

**Abstract**



Breast and endometrial cancer are the most common types of female cancers, but the incidence of both of these malignancies in a single patient is a rare event. Multiple primary malignancy has been increasingly reported over the past decade, and double primary cancer is considered as the most common type. In this study, we present a 53-year-old woman with synchronous primary malignancy of breast and endometrium. This patient had a history of breast and endometrial cancer in her family. Mammography and chest CT of the patient revealed a mass in the right breast and left supraclavicular region. However, the patient did not want to initiate treatment. Subsequently, the patient returned with a chief complaint of persistent abnormal vaginal bleeding. Abdominopelvic CT scan of the patient revealed a huge soft tissue mass in the pelvic cavity. She underwent hysterectomy, and pathology revealed endometrioid carcinoma, which had invaded the full thickness of uterine wall. Since this type of malignancy is rare and several risk factors are associated with it, it is worth being considered by clinicians when making decisions about screening or strategy for prevention.

**Keywords**

Breast, Endometrium, Cancer, Multiple Primary Malignancy

**Open Peer Review**

Referee Status: 

	Invited Referees	
	1	2
<b>REVISED</b> version 3 published 04 Jul 2018		
<b>REVISED</b> version 2 published 14 Dec 2017		 report
version 1 published 17 Aug 2017	 report	  report

<sup>1</sup> **Weibo Yu**, University of California, Los Angeles, USA

**Dylan Wan**, University of California, Los Angeles, USA

<sup>2</sup> **Minas Sakellakis**, University of Texas MD Anderson Cancer Center, USA

**Discuss this article**

Comments (0)

**Corresponding author:** Elham Sadat Banimostafavi ([razavi109@yahoo.com](mailto:razavi109@yahoo.com))

**Author roles:** **Banimostafavi ES:** Supervision, Writing – Review & Editing; **Tayebi S:** Writing – Original Draft Preparation; **Tayebi M:** Investigation, Methodology, Writing – Original Draft Preparation; **Montazer F:** Writing – Review & Editing

**Competing interests:** No competing interests were disclosed.

**How to cite this article:** Banimostafavi ES, Tayebi S, Tayebi M and Montazer F. **Case Report: Synchronous primary malignancy including the breast and endometrium [version 3; referees: 2 approved]** *F1000Research* 2018, **6**:1502 (doi: [10.12688/f1000research.11971.3](https://doi.org/10.12688/f1000research.11971.3))

**Copyright:** © 2018 Banimostafavi ES *et al.* This is an open access article distributed under the terms of the [Creative Commons Attribution Licence](#), which permits unrestricted use, distribution, and reproduction in any medium, provided the original work is properly cited. Data associated with the article are available under the terms of the [Creative Commons Zero "No rights reserved" data waiver](#) (CC0 1.0 Public domain dedication).

**Grant information:** The author(s) declared that no grants were involved in supporting this work.

**First published:** 17 Aug 2017, **6**:1502 (doi: [10.12688/f1000research.11971.1](https://doi.org/10.12688/f1000research.11971.1))

**REVISED Amendments from Version 2**

Author Elham-Sadat Bani-Mostafavi's name has been corrected to "Elham Sadat Banimostafavi", and author Fatemeh Montazer's affiliation has been corrected to "Department of Pathology, Gastrointestinal Cancer Research Center, Imam Khomeini Hospital Mazandaran university of Medical Sciences Sari Iran", in this version 3. Nothing else has been amended.

See referee reports

**Introduction**

Breast cancer (BC) is the most frequently diagnosed malignancy worldwide and is the first cause of cancer death in women<sup>1</sup>. The common metastatic sites of breast cancer are the lungs, bones, liver and brain. Endometrial cancer (EC) is considered as the commonest type of gynecological cancer that mostly affecting post-menopausal women<sup>2</sup>.

Multiple primary malignancy (MPM) has increased over the past decade. It is a term defined as occurring of the primary malignancy with different histology to two or more parts of the body distinct from each other. In addition to being distinct, these tumours must have definite featured of malignancy, and the possibility that one is the metastasis of the other must be ruled out<sup>3,4</sup>. Double primary cancers are the most common types of MPM.

Multiple mechanisms such as hereditary, immune and environmental factors, e.g. chemical, viruses and chemotherapeutic regimens, are considered as the pathogenesis of MPM<sup>5</sup>. Tumours that are diagnosed simultaneously or within six months are known as synchronous; a longer interval time and the tumours are metachronous.

We present a patient with two primary malignant tumours, including BC (invasive ductal carcinoma) and EC (endometrioid cell type), which can be considered as synchronous MPM.

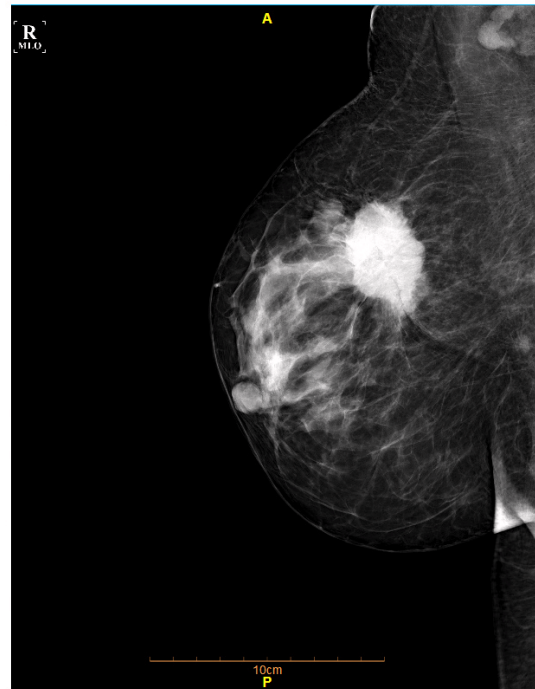
**Case report**

The following case is a 53-year-old woman who was referred to hospital from a local doctor in December 2016 with a palpable mass in her left supraclavicular region. She was a post-menopausal woman with BMI of 29. Mammography and chest CT scan revealed no suspicious mass in the left breast, the presence of a speculated mass 3.8×3.7 cm in the right breast (Figure 1), and additionally a soft tissue mass 5.8×5.1 cm in the left supraclavicular region (Figure 2).

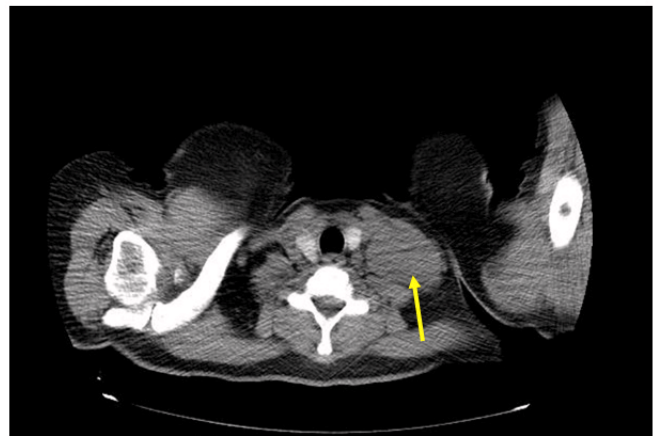
Core needle biopsy (CNB) for the right breast mass was preformed, and invasive ductal carcinoma (grade II) with involvement of axillary and supraclavicular lymph nodes was confirmed. On histopathology study, infiltrative cord and nest of neoplastic cells with moderate nuclear pleomorphism (score 2), scattered mitosis (score 1) and few tubular formation (score 3) were noted (Figure 3).

Immunohistochemistry result for breast mass showed strongly positive staining for ER and PR in most tumor cells (3+5), 3+ staining for HER2new and 10% positive Ki67 in tumor cells. Although the mass was diagnosed as BC, the patient personally refused to get any treatment. She has a positive family history of breast cancer and uterine cancer in her sister.

One month later, the patient returned with a chief complaint of persistent abnormal vaginal bleeding. She had the history of bleeding 4 years ago and it had worsened over the previous



**Figure 1. Breast mammography.** An irregular speculated hyperdensity mass in the right breast upper outer quadrant.

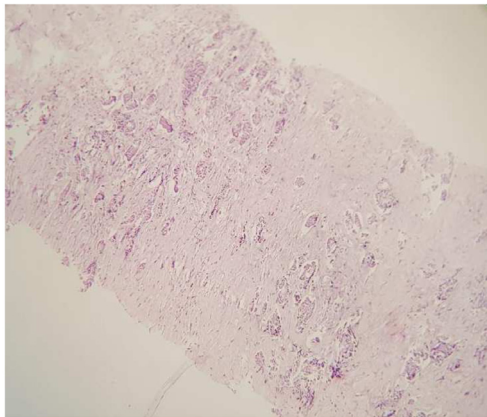


**Figure 2. Chest CT scan.** A soft tissue mass in the left supraclavicular region consistent with metastatic lymph node (yellow arrow).

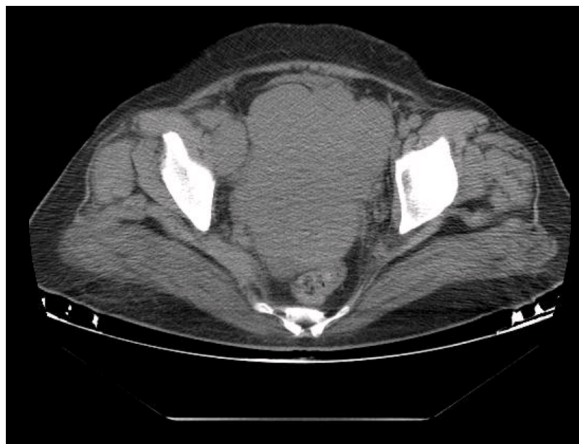
7 months. Abdominopelvic CT scan of the patient revealed a huge soft tissue mass 14×11 cm in the pelvic cavity with right external iliac and para-aortic lymphadenopathy and dilatation of renal calyces and ureters on both sides (Figure 4).

In January 2017, a total abdominal hysterectomy was performed with no complication, and the pathology revealed EC (stage IIIB, grade II). Pathology report showed sheets and cords of atypical cells with pleomorphism vesicular nuclei and visible nucleoli as well as frequent mitotic figure (Figure 5). Extensive coagulative necrosis was also seen. Tumor cell had invaded the full thickness of the uterine wall. Pelvic wall mass resection and cervix excision revealed the invasion of the tumor, but peritoneal fluid cytology was negative for malignancy. No metastatic tumors have been found in this patient.

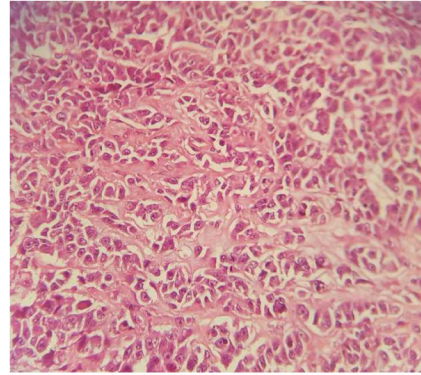
After two days she discharged from hospital with relative improvement. We could not follow up the patient because she moved to another city for further treatment; this is one limitation of our study. At the final follow-up, the patient



**Figure 3. Breast invasive ductal carcinoma, CNB, H and E X100.**



**Figure 4. Abdominopelvic CT.** A soft tissue mass in the pelvic cavity with right external iliac and para-aortic lymphadenopathy.



**Figure 5. Endometrial carcinoma, H and E X400.**

was referred to the oncology department in a different hospital to initiate chemotherapy.

### Discussion

The diagnosis of synchronous primary cancers in an individual is rare and difficult<sup>6</sup>. In the present case, clinicopathological criteria was used to distinguish the two similar cancers.

The risk of a new primary cancer in cancer survivors is 20% higher than in the general population<sup>7</sup>. In addition, it has been shown that the risk of developing a new malignancy is 1.29 times more than those who have never been diagnosed<sup>8</sup>. The possibility of synchronous BC and EC in one person is extremely low and might be only a coincidence, as reported in one study the diagnosis of EC within one year after the diagnosis of primary BC is less than 0.05%.

The coexistence of breast and endometrial cancer reflects the fact that there are many environmental and hormonal risk factors that may predispose the patient to both BC and EC, such as genetics, hormonal, environmental or treatment-related factors, and obesity (i.e. high BMI)<sup>9,10</sup>. Some of these factors are controversial. For instance, high BMI increases the risk of BC in postmenopausal women; however, it has opposite effect on premenopausal women<sup>11,12</sup>. By contrast, high BMI increases the risk of EC in both pre and postmenopausal women<sup>13,14</sup>.

There are many other situations that are correlated with an increasing risk of EC, such as age (i.e. more common in older patients), postmenstrual period<sup>15,16</sup>, nulliparous, and a positive history of irregular menstrual cycle<sup>13</sup>. Our case had some of these risk factors, such as being postmenopausal and having a high BMI(=29).

Besides these factors, hormonal status has an important role in endometrial carcinogenesis. Lower exposure to estrogen and higher exposure to progesterone reduce the risk of EC<sup>17</sup>. The conversion of adrenal hormones into estrogen may be done by fat cells in obese women, so obesity may increase the risk of EC in this way<sup>18</sup>. Obesity, nullipara and irregular menstrual cycle may represent less progesterone exposure, so they may contribute to EC development. In addition, EC may develop in association with tamoxifen treatment for BC, particularly in the case of long-term administration and high cumulative doses of tamoxifen<sup>19–21</sup>.

The patient in our study did not have any risk factors related to treatment because she did not start BC radio or chemotherapy before presentation of EC symptoms; therefore, we cannot consider the effects of tamoxifen usage in BC as a risk factor of EC in this patient.

Genetic and/or epigenetic changes and other plausible molecular mechanisms might be important in patients with synchronous double cancers<sup>22</sup>. The present case had a family history of breast and uterine cancer, so heredity could be counted as one of the strongest risk factors for this patient.

In addition to many similar environmental and hormonal risk factors, the same embryological origin of the endometrium and breast can constitute as an additional factor<sup>5,23</sup>. MPMs can generally be categorized into three major groups depending on the main etiologic factor. The first group are treatment-related neoplasms, the second group are syndromic cases (like Cowden syndrome), and the third group are neoplasms that may share common etiologic factors, such as genetic predisposition or the same environmental factors<sup>24</sup>. According to this classification, our patient can be categorized in the third group.

To conclude, finding a patient with simultaneous presentation of endometrial and breast cancer is rare; however both of these primary malignancies are considered as the most common cancers in females. Several associated risk factors to this event have been described above. In our case, a high BMI, postmenopausal status and hereditary are probably the most relevant risk factors. Hence, all these factors should be taken into account by clinicians when making a decision concerning screening or strategy for prevention.

## Consent

Written informed consent for the publication of the patient's clinical details and images was obtained from the patient.

## Competing interests

No competing interests were disclosed.

## Grant information

The author(s) declared that no grants were involved in supporting this work.

## References

1. Fast Stats: **Most frequent cancers: both sexes** [Internet]. WHO. 2012; [cited 2017]. [Reference Source](#)
2. Torre LA, Bray F, Siegel RL, et al.: **Global cancer statistics, 2012**. *CA Cancer J Clin*. 2015; **65**(2): 87–108. [PubMed Abstract](#) | [Publisher Full Text](#)
3. Aydiner A, Karadeniz A, Uygun K, et al.: **Multiple primary neoplasms at a single institution: differences between synchronous and metachronous neoplasms**. *Am J Clin Oncol*. 2000; **23**(4): 364–70. [PubMed Abstract](#)
4. Derwinger K, Gustavsson B: **A study of aspects on gender and prognosis in synchronous colorectal cancer**. *Clin Med Insights Oncol*. 2011; **5**: 259–64. [PubMed Abstract](#) | [Publisher Full Text](#) | [Free Full Text](#)
5. Sakellakis M, Peroukides S, Iconomou G, et al.: **Multiple primary malignancies: a report of two cases**. *Chin J Cancer Res*. 2014; **26**(2): 215–8. [PubMed Abstract](#) | [Publisher Full Text](#) | [Free Full Text](#)
6. Yeh CC, Wang PH, Lai CR, et al.: **Synchronous breast invasive ductal carcinoma and endometrial endometrioid adenocarcinoma: case report**. *J Obstet Gynaecol Res*. 2011; **37**(9): 1246–9. [PubMed Abstract](#) | [Publisher Full Text](#)
7. Travis LB, Hill D, Dores GM, et al.: **Cumulative absolute breast cancer risk for young women treated for Hodgkin lymphoma**. *J Natl Cancer Inst*. 2005; **97**(19): 1428–37. [PubMed Abstract](#) | [Publisher Full Text](#)
8. Schoenberg BS: **Multiple primary malignant neoplasms. The Connecticut experience, 1935–1964**. *Recent Results Cancer Res*. 1977; **58**: 1–173. [PubMed Abstract](#) | [Publisher Full Text](#)
9. Mellemkjaer L, Friis S, Olsen JH, et al.: **Risk of second cancer among women with breast cancer**. *Int J Cancer*. 2006; **118**(9): 2285–92. [PubMed Abstract](#) | [Publisher Full Text](#)
10. Amir E, Freedman OC, Seruga B, et al.: **Assessing women at high risk of breast cancer: a review of risk assessment models**. *J Natl Cancer Inst*. 2010; **102**(10): 680–91. [PubMed Abstract](#) | [Publisher Full Text](#)
11. Iatrakis G, Zervoudis S, Saviolakis A, et al.: **Women younger than 50 years with endometrial cancer**. *Eur J Gynaecol Oncol*. 2006; **27**(4): 399–400. [PubMed Abstract](#)
12. Ballard-Barbash R, Swanson CA: **Body weight: estimation of risk for breast and endometrial cancers**. *Am J Clin Nutr*. 1996; **63**(3 Suppl): 437S–41S. [PubMed Abstract](#) | [Publisher Full Text](#)
13. Soliman PT, Oh JC, Schmeler KM, et al.: **Risk factors for young premenopausal women with endometrial cancer**. *Obstet Gynecol*. 2005; **105**(3): 575–80. [PubMed Abstract](#) | [Publisher Full Text](#)
14. Bianchini F, Kaaks R, Vainio H: **Overweight, obesity, and cancer risk**. *Lancet Oncol*. 2002; **3**(9): 565–74. [PubMed Abstract](#) | [Publisher Full Text](#)
15. Saadat M, Truong PT, Kader HA, et al.: **Outcomes in patients with primary breast cancer and a subsequent diagnosis of endometrial cancer: comparison of cohorts treated with and without tamoxifen**. *Cancer*. 2007; **110**(1): 31–7. [PubMed Abstract](#) | [Publisher Full Text](#)
16. Burke TW, Fowler WC Jr, Morrow CP: **Clinical aspects of risk in women with endometrial carcinoma**. *J Cell Biochem Suppl*. 1995; **59**(S23): 131–6. [PubMed Abstract](#) | [Publisher Full Text](#)
17. Dossus L, Allen N, Kaaks R, et al.: **Reproductive risk factors and endometrial cancer: the European Prospective Investigation into Cancer and Nutrition**. *Int J Cancer*. 2010; **127**(2): 442–51. [PubMed Abstract](#) | [Publisher Full Text](#)
18. Siiteri PK: **Adipose tissue as a source of hormones**. *Am J Clin Nutr*. 1987; **45**(1 Suppl): 277–82. [PubMed Abstract](#) | [Publisher Full Text](#)
19. van Leeuwen FE, Benraadt J, Coebergh JW, et al.: **Risk of endometrial cancer after tamoxifen treatment of breast cancer**. *Lancet*. 1994; **343**(8895): 448–52. [PubMed Abstract](#) | [Publisher Full Text](#)
20. Bergman L, Beelen ML, Gallee MP, et al.: **Risk and prognosis of endometrial cancer after tamoxifen for breast cancer. Comprehensive Cancer Centres' ALERT Group. Assessment of Liver and Endometrial cancer Risk following Tamoxifen**. *Lancet*. 2000; **356**(9233): 881–7. [PubMed Abstract](#) | [Publisher Full Text](#)
21. Wang PH, Chao HT: **A reconsideration of tamoxifen use for breast cancer**. *Taiwan J Obstet Gynecol*. 2007; **46**(2): 93–5. [PubMed Abstract](#) | [Publisher Full Text](#)
22. Fletcher O, Houlston RS: **Architecture of inherited susceptibility to common cancer**. *Nat Rev Cancer*. 2010; **10**(5): 353–61. [PubMed Abstract](#) | [Publisher Full Text](#)
23. Hemminki K, Aaltonen L, Li X: **Subsequent primary malignancies after endometrial carcinoma and ovarian carcinoma**. *Cancer*. 2003; **97**(10): 2432–9. [PubMed Abstract](#) | [Publisher Full Text](#)
24. Takalkar U, Asegaonkar BN, Kodlikeri P, et al.: **An elderly woman with triple primary metachronous malignancy: A case report and review of literature**. *Int J Surg Case Rep*. 2013; **4**(7): 593–6. [PubMed Abstract](#) | [Publisher Full Text](#) | [Free Full Text](#)

# Open Peer Review

Current Referee Status:  

---

## Version 2

Referee Report 04 January 2018

doi:10.5256/f1000research.14507.r29030



**Minas Sakellakis**

University of Texas MD Anderson Cancer Center, Houston, TX, USA

The diagnosis of synchronous breast and endometrial cancers might be challenging. The authors made an effort to address most of the the reviewers concerns. I think that the corrections now made the paper of acceptable quality and will be of value to clinicians.

**Competing Interests:** No competing interests were disclosed.

**I have read this submission. I believe that I have an appropriate level of expertise to confirm that it is of an acceptable scientific standard.**

---

## Version 1

Referee Report 16 November 2017

doi:10.5256/f1000research.12943.r25974



**Minas Sakellakis**

University of Texas MD Anderson Cancer Center, Houston, TX, USA

This article needs to be significantly improved before it gets accepted for publication. Here are my suggestions to improve this article:

### COMMENTS ON INTRODUCTION:

- “Metastases to the gynecologic and gastrointestinal tract are rare<sup>2,3</sup>; endometrial cancer (EC) is considered as the most frequent of this type.”  
Please correct: Endometrial cancer is not a metastasis.
- “Multiple primary malignancy (MPM) has increased over the past decade. It is a term defined as spreading of the primary malignancy to two or more parts of the body distinct from each other. In addition to being distinct, these tumours must have definite featured of malignancy, and the possibility that one is the metastasis of the other must be ruled out”

Please correct: Multiple primary malignancy is not spreading of the primary malignancy to two or more parts. The term refers to separate cancers.

- “Multiple mechanisms such as hereditary, immune and environmental factors, e.g. chemical, viruses and chemotherapeutic regimens, are considered as the pathogenesis of MPM”  
Many times (if not most times) MPM are the result of pure chance. For instance if a disease A has a prevalence of e.g. 3% and disease B has a prevalence of e.g. 2%, then a small number of patients will have both diseases only as a matter of chance. The same thing implies here for BC and EC.

#### COMMENTS ON CASE PRESENTATION:

- Additional information should be given regarding the tumor stage. There is no information regarding the lymph node status in the right axilla. Does the text imply that the disease was spread directly to the left supra-clavicular lymph nodes. Did the authors rule out a second tumor in the left breast? Did they detect metastatic disease elsewhere?
- The authors don't mention the status of estrogen and progesterone receptors, nor do they report the HER2/NEU status.
- Pathology images should be added.

#### COMMENTS ON DISCUSSION:

- Language editing is strongly advised before the authors submit a revision of this manuscript. For instance the phrase: "The diagnosis of synchronous primary cancers in an individual is rare and difficult, especially in the case of finding the same type of cancer. In the present case, clinicopathological criteria was used to distinguish the two similar cancer" needs to be rephrased completely.
- Discuss that the coexistence of BC and EC in this patient might be only a coincidence.
- Information regarding menopausal status and BMI should be given in the case presentation section.
- What are the treatment implications?

#### **Is the background of the case's history and progression described in sufficient detail?**

Partly

#### **Are enough details provided of any physical examination and diagnostic tests, treatment given and outcomes?**

Partly

#### **Is sufficient discussion included of the importance of the findings and their relevance to future understanding of disease processes, diagnosis or treatment?**

Partly

#### **Is the case presented with sufficient detail to be useful for other practitioners?**

No

**Competing Interests:** No competing interests were disclosed.

**I have read this submission. I believe that I have an appropriate level of expertise to confirm that it is of an acceptable scientific standard, however I have significant reservations, as outlined above.**

Referee Report 12 October 2017

doi:10.5256/f1000research.12943.r26730



**Weibo Yu , Dylan Wan**

Department of Pathology and Laboratory Medicine, University of California, Los Angeles, Los Angeles, CA, USA

Breast cancer and endometrial cancer are two most frequent hormone-related cancers among women. The authors presented a rare case with synchronous primary malignancy of breast and endometrium. This is a well-written case report. It clearly described a particular individual's history with a disease presentation and progress.

1. One limitation is the patient lost to follow up.
2. It is advised to add pathology images demonstrating their findings.
3. Patients with germline mutations in BRCA1 and BRCA2 genes are highly susceptible to breast cancer. These mutations are also related to an increased risk of developing endometrial cancer. Do author consider to perform an investigation in genetic level? It would be adequate to add more discussion in this point.

**Is the background of the case's history and progression described in sufficient detail?**

Yes

**Are enough details provided of any physical examination and diagnostic tests, treatment given and outcomes?**

Partly

**Is sufficient discussion included of the importance of the findings and their relevance to future understanding of disease processes, diagnosis or treatment?**

Yes

**Is the case presented with sufficient detail to be useful for other practitioners?**

Yes

**Competing Interests:** No competing interests were disclosed.

**We have read this submission. We believe that we have an appropriate level of expertise to confirm that it is of an acceptable scientific standard.**



The benefits of publishing with F1000Research:

- Your article is published within days, with no editorial bias
- You can publish traditional articles, null/negative results, case reports, data notes and more
- The peer review process is transparent and collaborative
- Your article is indexed in PubMed after passing peer review
- Dedicated customer support at every stage

For pre-submission enquiries, contact [research@f1000.com](mailto:research@f1000.com)

**F1000Research**