

The Modified M-plasty Approach to Mastectomy: Avoiding the Lateral Dog-ear

Farid Meybodi, MD, FRACS
My Pham MD, MS
Negin Sedaghat MD, FRACS
Elisabeth Elder MD, FRACS
James French MD, FRACS

Summary: Postmastectomy “dog-ears” are cosmetically displeasing, can contribute to a poorly fitting bra, and may cause discomfort for patients. They occur most commonly in patients with high body mass index and/or large breasts and can be challenging to manage. To avoid the lateral dog-ear following simple mastectomy, we describe the M-plasty with the addition of a lipodermal flap. We demonstrate that the addition of a lipodermal flap not only flattens the lateral contour of the chest wall but also facilitates a tension-free closure. This helps reduce wound-healing issues in high-risk patients with multiple comorbidities, high body mass index, and large breast size. (*Plast Reconstr Surg Glob Open* 2022;10:e4116; doi: [10.1097/GOX.0000000000004116](https://doi.org/10.1097/GOX.0000000000004116); Published online 18 February 2022.)

INTRODUCTION

There is an increased risk of residual excess tissue lateral to a mastectomy scar, resulting in a so-called dog-ear, when a mastectomy is performed in overweight or obese patients with excess tissue in the lateral chest wall. A common surgical technique reported to avoid the lateral dog-ear utilizes a fish-tail approach made from lengthening the mastectomy scar and then moving the lateral apex of the wound medially to close in a “Y fashion.”¹ This technique may result in tension at the Y-junction of the wound, which predisposes to complications such as wound dehiscence and necrosis.^{2,3} Although the overall incidence of wound complications after mastectomy without reconstruction is low, with reported rates between 1% and 4%,⁴ wound management may be challenging, especially in high-risk patients with multiple comorbidities and high body mass index. Furthermore, complications risk delaying the start of adjuvant therapies and may cause aesthetic and functional issues once healing is complete with associated psychological morbidity.⁴ Therefore, to avoid the lateral dog-ear whilst also maintaining a tension-free closure to the wound, we describe a modified M-plasty approach to mastectomy, a technique not described previously in the literature.

From the Westmead Breast Cancer Institute, New South Wales, Australia.

Received for publication September 23, 2021; accepted December 14, 2021.

Copyright © 2022 The Authors. Published by Wolters Kluwer Health, Inc. on behalf of The American Society of Plastic Surgeons. This is an open-access article distributed under the terms of the [Creative Commons Attribution-Non Commercial-No Derivatives License 4.0 \(CCBY-NC-ND\)](https://creativecommons.org/licenses/by-nc-nd/4.0/), where it is permissible to download and share the work provided it is properly cited. The work cannot be changed in any way or used commercially without permission from the journal.

DOI: [10.1097/GOX.0000000000004116](https://doi.org/10.1097/GOX.0000000000004116)

MODIFIED M-PLASTY: OPERATIVE TECHNIQUE

Markings

The markings are completed on-table with the arm abducted at 90 degrees. The inframammary fold (IMF) of the breast and superior border of the mastectomy are marked, commencing medially from the parasternal border, and extended to the mid-axillary line, laterally. (See [Video 1 \[online\]](#), which displays the M-plasty approach to mastectomy.) The mid-axillary line is marked between the superior and IMF markings, laterally. The M-plasty marking consists of an equilateral triangle based on this line. From the mid-portion of each medial side of the triangle, a square extension is marked ([Fig. 1](#)). This is the addition of a lipodermal flap component to the M-plasty. The flap area is variable and depends on the length of the base of the triangle.

Incision Pattern and Preparation of the Lipodermal Flap

After infiltration with local anesthetic along the markings, the incision pattern of the M-plasty is made to dermis only, while sparing the mid-axillary line marking (ie, the base to the equilateral triangle). The lipodermal flap component of the M-plasty is then de-epithelialized to its borders ([Fig. 1](#)).

Completion of Mastectomy

Routine mastectomy is completed. As this is an IMF-based mastectomy, the superior flap is raised in the anatomical mastectomy plane just superficial to the anterior mammary fascia (diathermy or sharp dissection technique

Disclosure: The authors have no financial interest to declare in relation to the content of this article.

Related Digital Media are available in the full-text version of the article on www.PRSGlobalOpen.com.

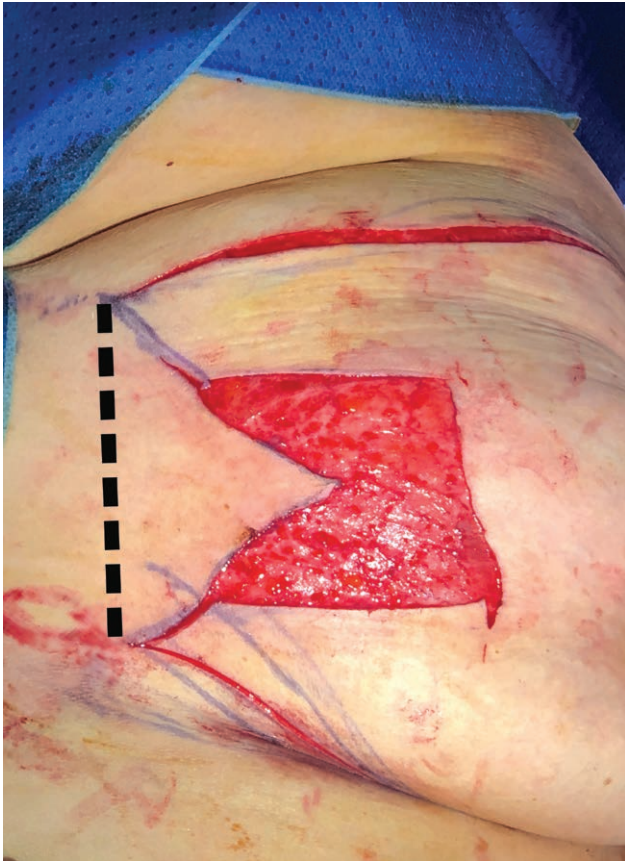

Fig. 1. Modified M-plasty: Marking and de-epithelialization of lipodermal flap component of the right breast. The mid-axillary line is marked by the dotted line.

may be used according to surgeon preference). The inferior marking includes the IMF which is excised. Laterally, the lipodermal flap is incised at its borders and deepened to the anatomical mastectomy plane. This is effectively the lateral flap of the mastectomy. Therefore, the lateral flap is raised in the anatomical mastectomy plane. The breast is mobilized off the pectoralis fascia to complete the mastectomy.

Takeaways

Question: How to avoid the mastectomy dog-ear?

Findings: The modified M-plasty flap is a tension-free flap that can be applied easily to produce a reliable, cosmetically pleasing result.

Meaning: The modified M-plasty approach to mastectomy is presented here for consideration in patients who are at high risk for lateral dog-ear formation.

Fixation of the Lipodermal Flap

The lipodermal flap addition to the M-plasty may be used as a “handle” of tissue, allowing the surgeon to pull the flap medially, while assessing the degree of flattening of the lateral contour of the chest wall. Once a satisfactory position for the flap is established (by the degree of desired flattening of the chest wall), the lipodermal flap is then secured to the pectoralis fascia with absorbable sutures, taking care not to place sutures into the pectoralis muscle to reduce the risk of bleeding. These sutures maintain the position of the medialized flap and serve to reduce the tension over the skin of the apex of the M-plasty.

Wound Closure

A drain is inserted depending on the size of the mastectomy. Deep dermal and subcuticular closure is completed with absorbable sutures such that the lipodermal flap is buried under the superior and inferior mastectomy flaps (Fig. 2). Dressings are applied.

DISCUSSION

Simple mastectomy is traditionally performed through a transverse elliptical incision, as described by Stewart in 1915.⁵ The mastectomy wound usually has a large lateral apical angle, and unequal opposite side lengths. As the wound is closed, the corners experience rotational and compression forces, resulting in outward and upward protrusion of tissue; this is colloquially termed the “dog-ear.”

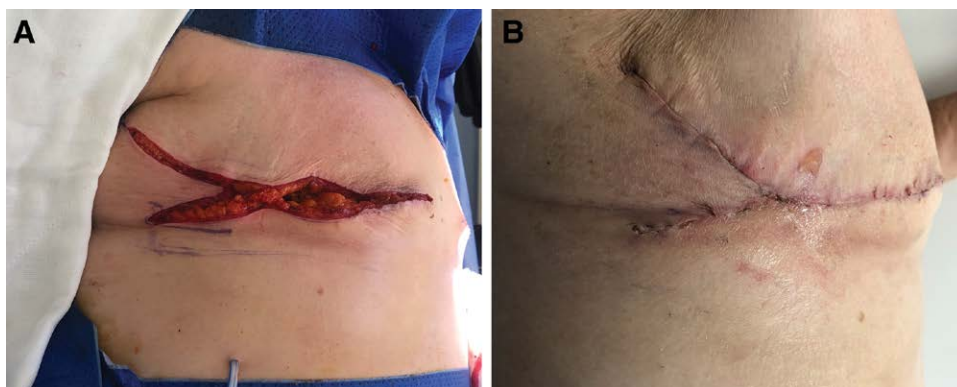


Fig. 2. The lipodermal flap component of the modified M-plasty is buried under the superior and inferior mastectomy flaps. A, Appearance after lipodermal flap has been medialized and secured to the pectoralis fascia, and deep dermal closure is completed. Note, there is minimal wound tension, and any dog-ear is eliminated. B, Postoperative appearance at 3 weeks.

Dog-ears are not uncommon after mastectomy, particularly in obese or large breasted patients.¹ Dog-ears normally lie at or above the bra line, leading to an ill-fitting bra; they are unsightly, and can cause pain or pressure injury.^{6,7} Furthermore, dog-ears can be a source of litigation by disappointed patients and will often require surgical correction.^{6,7}

The most common and simplest way to prevent dog-ears is a straight line wound extension, but the trade-off for the better contour is a longer scar, with potential for reduced shoulder mobility if the incision extends into the axilla or arm.^{1,7,12,14,15} Another common strategy employed is the “hockey stick” incision, which involves extending the shorter side of the wound at an approximately 120 degree angle from the original axis that necessarily causes a longer scar.⁷ Lastly, the “fish-tail” incision or “Y closure” and its variations (“tear-drop” incision, “L” scar technique) have been described.^{1,11} When the mastectomy wound is long, and the long lateral tip of the mastectomy is fixed medially in a “Y fashion” to correct the lateral dog-ear, we hypothesize that the risk of wound complication may increase due to increased tension and tenuous blood supply at the apex of the “Y” closure.²

M-plasty has been described to minimize dog-ears on the face.⁸ Traditionally the M-plasty involves incorporating a free drawn “M” to the end/s of an ellipse before excision or later in the wound repair.^{8,9} The modified M-plasty technique presented here is marked before any excision. The lipodermal flap addition to the M-plasty has a number of advantages in supporting wound healing as well as wound closure. Maintaining the lipodermal flap around the tip of the triangle of the modified M-plasty provides collateral perfusion support and reduces ischemia of the tip of the triangle.¹⁻⁴ Secondly, the lipodermal flap can also be manipulated like a “bucket-handle,” and this reduces tissue-handling-related trauma on the overlying skin. The lipodermal flap distributes the wound tension equally over a larger area. Hence, the lipodermal flap may function as an anchor upon which the overlying skin flaps can be approximated, possibly with reduced wound tension and protected perfusion.

A limitation of this approach is with respect to its utility in patients with lateral breast tumors that extend into the skin, particularly if an oncological safe plane cannot be developed between the lipodermal flap and tumor. In this setting, skin from the lateral chest may not be able to be used for the lipodermal flap component. Another consideration is with respect to detection of recurrence within the buried lipodermal flap. However, this consideration is similar to any mastectomy flap, which may contain a small amount of breast tissue that is buried in a deeper plane similar to the established Goldilocks technique.^{5,6,10} Lastly, there is potential for further standardization of the marking of the lipodermal flap component. This may be achieved by correlating the measurements for the lengths of the equilateral triangle with measurement proportions based on patient characteristics such as breast size and body mass index.

CONCLUSIONS

The modified M-plasty approach to mastectomy is presented here for consideration in patients who are at high risk for lateral dog-ear formation such as obese or overweight patients and patients with excessive tissue in the lateral chest wall who are not suitable candidates for immediate reconstruction or the Goldilocks mastectomy approach.^{4,5,9} It is an approach that has been used in our practice with success so far. With further accumulated experience, surgical outcomes and patient-reported outcomes will be evaluated in future studies, providing validation to this approach.

My Pham, MD, MS

Westmead Breast Cancer Institute
New South Wales, Australia
E-mail: my.b.pham@gmail.com

REFERENCES

1. Lim GH, Tan HF. Surgical techniques to avoid lateral dog ear of the mastectomy scar: a systematic review. *Int J Surg*. 2016;26:73–78.
2. Rao R, Saint-Cyr M, Ma AM, et al. Prediction of post-operative necrosis after mastectomy: a pilot study utilizing optical diffusion imaging spectroscopy. *World J Surg Oncol*. 2009;7:91.
3. Memarzadeh K, Sheikh R, Blohmé J, et al. Perfusion and oxygenation of random advancement skin flaps depend more on the length and thickness of the flap than on the width to length ratio. *Eplasty*. 2016;16:e12.
4. Jeevan R, Cromwell DA, Browne JP, et al. Findings of a national comparative audit of mastectomy and breast reconstruction surgery in England. *J Plast Reconstr Aesthet Surg*. 2014;67:1333–1344.
5. Robertson SA, Jeevaratnam JA, Agrawal A, et al. Mastectomy skin flap necrosis: challenges and solutions. *Breast Cancer (Dove Med Press)*. 2017;9:141–152.
6. Hussien M, Daltrey IR, Dutta S, et al. Fish-tail plasty: a safe technique to improve cosmesis at the lateral end of mastectomy scars. *Breast*. 2004;13:206–209.
7. Kang AS, Kang KS. A systematic review of cutaneous dog ear deformity: a management algorithm. *Plast Reconstr Surg Glob Open*. 2020;8:e3102.
8. Prohaska J, Sequeira Campos M, Crane JS. *M-plasty*. Treasure Island, Fla.: StatPearls Publishing; 2020.
9. Trakatelli M, Rossi E. Surgery. In: Katsambas AD, Lotti TM, Dessinioti C, D’Erme AM, eds. *European Handbook of Dermatological Treatments*. Berlin, Heidelberg: Springer; 2015:1325–1342.
10. Nickel KB, Fox IK, Margenthaler JA, et al. Effect of noninfectious wound complications after mastectomy on subsequent surgical procedures and early implant loss. *J Am Coll Surg*. 2016;222:844–852.e1.
11. Thomas R, Mouat C, King B. Mastectomy flap design: the ‘waisted teardrop’ and a method to reduce the lateral fold. *ANZ J Surg*. 2012;82:329–333. doi: 10.1111/j.1445-2197.2012.06046.x.
12. Clough KB, Massey EJ, Mahadev GK, et al. Oncoplastic technique for the elimination of the lateral “dog ear” during mastectomy. *Breast J*. 2012;18:588–590.
13. Bennett IC, Biggar MA. A triangular advancement technique to avoid the dog-ear deformity following mastectomy in large breasted women. *Ann R Coll Surg Engl*. 2011;93:554–555.
14. Hill EL, Ochoa D, Denham F, et al. The angel wings incision: a novel solution for mastectomy patients with increased lateral adiposity. *Breast J*. 2019;25:687–690.
15. Grassetti L, Lazzeri D, Torresetti M, et al. Aesthetic refinement of the dog ear correction: the 90° incision technique and review of the literature. *Arch Plast Surg*. 2013;40:268–269.