

MINI-FOCUS ISSUE: INTERVENTIONAL CARDIOLOGY

INTERMEDIATE

CASE REPORT: CLINICAL CASE

Functional Recovery of a Failed Radial Artery Graft After Progression of Native Coronary Stenosis



Ioannis Anastasiou, MD, Ioannis Konstantinou, MD, Stylianos Petousis, MD, Emmanouil Skalidis, Fragkiskos Parthenakis, Michalis Hamilos, PhD

ABSTRACT

Competitive flow from the native vessel can lead to coronary graft failure. However, restoration of graft patency can occasionally occur. We present the case of subtotal occlusion of a radial artery graft bypassing a lesion with moderate stenosis, with subsequent late functional recovery once the native vessel disease had progressed. (**Level of Difficulty: Intermediate.**) (J Am Coll Cardiol Case Rep 2020;2:1907-10) © 2020 The Authors. Published by Elsevier on behalf of the American College of Cardiology Foundation. This is an open access article under the CC BY-NC-ND license (<http://creativecommons.org/licenses/by-nc-nd/4.0/>).

PRESENTATION

A 47-year-old female patient, former smoker, presented to the emergency department of the authors' hospital due to an episode of syncope in the standing position, which was preceded by a brief episode of chest discomfort.

At presentation, the patient was asymptomatic and hemodynamically stable. Systolic and diastolic blood pressure values were 132/75 and 122/71 mm Hg in the supine position and on standing, respectively. Heart

rate was 72 beats/min. Physical examination was unremarkable.

Electrocardiography (ECG) revealed normal sinus rhythm without atrioventricular or intraventricular conduction delay or specific repolarization abnormalities, and initial cardiac biomarker and d-dimer levels proved to be normal.

MEDICAL HISTORY

The patient had a medical history of arterial hypertension and 3-vessel coronary artery disease treated with coronary artery bypass grafting (CABG) 1 year previously. Pre-CABG coronary angiography was indicated by limiting angina pectoris (Canadian Cardiovascular Society Class III) and had revealed extensive atherosclerosis of left anterior descending artery (LAD) with consecutive stenotic lesions 90% to 95%, borderline stenosis (50%) of the proximal left circumflex artery, 80% stenosis of the first obtuse marginal branch (OM1), and 50% stenosis of the mid right coronary artery (RCA) right dominance). The

LEARNING OBJECTIVES

- To emphasize the fact that restoration of patency of subtotally occluded radial arterial grafts can occur in the long-term, even after more than 5 years.
- To become familiar with the pathophysiology of coronary graft failure and key properties of radial arterial grafts.

From the Cardiology Department, University Hospital of Heraklion, Heraklion, Crete, Greece.

The authors attest they are in compliance with human studies committees and animal welfare regulations of the authors' institutions and Food and Drug Administration guidelines, including patient consent where appropriate. For more information, visit the *JACC: Case Reports* [author instructions page](#).

Manuscript received May 27, 2020; revised manuscript received August 24, 2020, accepted September 2, 2020.

ABBREVIATIONS AND ACRONYMS

CABG = coronary artery bypass grafting

ECG = electrocardiography

LAD = left anterior descending artery

LITA = left interior thoracic artery

OMI = first obtuse marginal branch

PDA = posterior descending artery

RCA = right coronary artery

SPECT = single-photon emission computed tomography

SVG = saphenous vein graft

LAD was grafted by the left interior thoracic artery (LITA), OM1 by a saphenous vein graft (SVG), and the posterior descending artery (PDA) by a left radial artery graft.

Long-term medical therapy included oral low-dose aspirin; metoprolol, 25 mg twice daily, atorvastatin, 40 mg daily, and ramipril, 5 mg daily.

DIFFERENTIAL DIAGNOSIS

Initial differential diagnosis included: 1) non-ST-segment elevation acute coronary syndrome; 2) an arrhythmic event; and 3) neurally mediated syncope precipitated by noncardiac chest discomfort or emotional stress.

INVESTIGATIONS

The patient was admitted to the cardiology clinic for further investigation and management. Serial testing of cardiac biomarkers and repeated ECGs did not yield results compatible with acute myocardial injury. Transthoracic echocardiography showed preserved left ventricular systolic function without any other remarkable findings. Twenty-four-hour ECG monitoring did not reveal any significant heart rhythm disturbances.

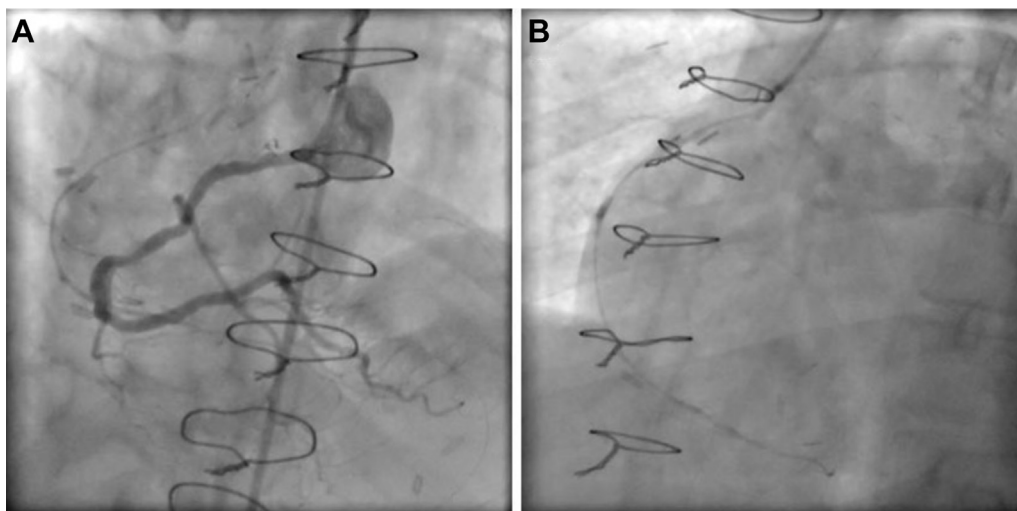
ECG exercise testing was positive for ischemia, and thus, exclusion of graft failure or progression of native vessel coronary artery disease was deemed mandatory.

Coronary angiography did not reveal significant progression of native vessel disease. LITA graft to LAD and SVG to OM were functioning well, whereas the RA graft to RCA was found diffusely narrowed and subtotally occluded (“string sign”) (Figure 1B, Video 1). As the bypassed stenotic lesion of the right coronary artery was of borderline severity (50% diameter) (Figure 1A, Video 2), the RA graft failure was presumed to be due to competitive flow from the native vessel. Subsequently, further noninvasive testing with single-photon emission computed tomography (SPECT) was performed, which did not reveal myocardial ischemia at any territory.

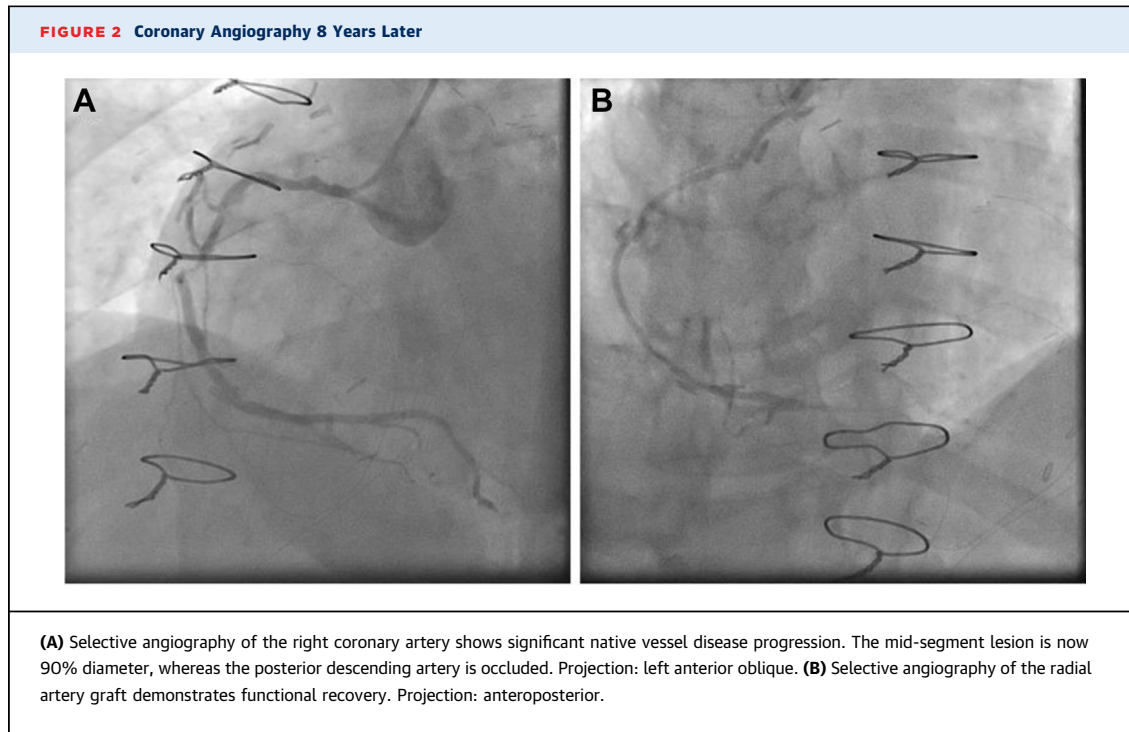
DISCUSSION

According to current guidelines (1), the decision to repeat revascularization in CABG patients with angiographic evidence of graft failure must be based on the presence of either a large area of inducible ischemia on noninvasive testing, usually defined as at least 10% of left ventricular myocardium, or severe symptoms despite optimal medical therapy. If revascularization is deemed appropriate, percutaneous

FIGURE 1 Coronary Angiography at Index Hospitalization (1 Year Post-Coronary Artery Bypass Graft)



(A) Selective angiography of the right coronary artery shows a stenotic lesion of approximately 50% diameter at the vessel's mid-segment. Projection: left anterior oblique. (B) Selective angiography of the radial artery graft to the posterior descending artery demonstrates diffuse narrowing and subtotal occlusion (“string sign”). Projection: left anterior oblique.



coronary intervention of the native vessel is the preferred approach in most cases.

In the present case, the constellation of symptoms, clinical picture, and laboratory and angiographic findings was not suggestive of an acute coronary syndrome, whereas the patient had not experienced typical angina post-CABG.

MANAGEMENT

Due to the lack of inducible ischemia on SPECT, conservative therapy was chosen. The patient remained asymptomatic throughout hospitalization and was discharged 4 days after admission. Neurally mediated syncope was considered the most probable cause of transient loss of consciousness. Medical therapy remained the same, and a follow-up visit was scheduled.

FOLLOW-UP

Eight years later, the patient once again underwent coronary angiography due to an atypical chest pain syndrome with concomitant nonspecific repolarization abnormalities on ECG. LITA graft to LAD and SVG to OM were shown to be patent and functioning well, whereas no clinically significant disease progression in native branches of the left coronary artery was noted. On the other hand, significant atherosclerosis

progression was now observed in mid-RCA (90%), and the PDA was totally occluded at its origin (Figure 2A, Video 3). Importantly, however, selective angiography of the radial artery graft, which demonstrated “string sign” on previous catheterization, was now shown to be fully patent and functional with satisfactory run-off to the PDA (Figure 2B, Video 4).

CONCLUSIONS

RA grafts have been shown to carry superior long-term patency rates compared to SVG and have been associated with a lower risk of mid-term major adverse events when used to supplement single or bilateral interior thoracic artery grafts (2). Currently, radial artery grafts comprise the preferred approach in grafting native vessels other than the LAD, in cases where right interior thoracic artery grafts cannot be used (1). However, the hemodynamic significance of native vessel lesions should be established prior to surgery by functional assessment because competitive flow from the native vessel is a leading cause of early and late graft failure. The radial artery, particularly, is characterized by a thicker wall and higher myocyte density in the media compared to the interior thoracic artery, which may account for the well-established predisposition of radial artery grafts for early postoperative spasm, leading sometimes to

graft failure (3). In addition, placement of a graft to bypass a lesion of moderate angiographic severity has been associated with significantly greater incidence of native vessel disease progression. Interestingly, the latter phenomenon occurs more frequently at the right coronary circulation (4).

There is evidence that late functional recovery and restoration of patency can occur in a large proportion of radial artery grafts that appear subtotally or totally occluded, with the presence of a native vessel stenosis of at least 90% constituting an independent predictive factor of graft recovery. This phenomenon has been observed 6 to 12 months post-CABG, but to the best of the authors' knowledge, the present case is the first very late (8 years) string sign reversal to be reported (5,6).

In this patient's original CABG procedure, the radial artery should have probably been used to graft the more severely stenosed OM1, although it is doubtful if grafting the RCA was indicated at all. Nevertheless, the configuration of grafts used, although inappropriate, provided a valuable insight into the physiology of radial artery grafts.

AUTHOR RELATIONSHIP WITH INDUSTRY

The authors have reported that they have no relationships relevant to the contents of this paper to disclose.

ADDRESS FOR CORRESPONDENCE: Dr. Michalis Hamilos, University Hospital of Heraklion, Greece, Stavrakia, Voutes, 71100, Heraklion, Crete 71100, Greece. E-mail: xammix@hotmail.com.

REFERENCES

1. Neumann F-J, Sousa-Uva M, Ahlsson A, et al., for the ESC Scientific Document Group. 2018 ESC/EACTS guidelines on myocardial revascularization. *Eur Heart J* 2019;40:87-165.
2. Gaudino M, Benedetto U, Fremes S, et al. Radial-artery or saphenous-vein grafts in coronary-artery bypass surgery. *N Engl J Med* 2018;378:2069-77.
3. Acar C, Jebara VA, Portoghese M, et al. Comparative anatomy and histology of the radial artery and the internal thoracic artery. Implication for coronary artery bypass. *Surg Radiol Anat* 1991; 13:283-8.
4. Hayward PA, Zhu YY, Nguyen TT, Hare DL, Buxton BF. Should all moderate coronary lesions be grafted during primary coronary bypass surgery? An analysis of progression of native vessel disease during a randomized trial of conduits. *J Thorac Cardiovasc Surg* 2013;145:140-8; discussion 148-9.
5. Kim JB, Kang JW, Song H, et al. Late improvement in graft patency after coronary artery bypass grafting: serial assessment with multidetector computed tomography in the early and late postoperative settings. *J Thorac Cardiovasc Surg* 2011;142:793-9.
6. Merlo M, Terzi A, Tespili M, Ferrazzi P. Reversal of radial artery 'string sign' at 6 months follow-up. *Eur J Cardiothorac Surg* 2003;23:432-4.

KEY WORDS CABG, coronary graft failure, radial arterial graft

APPENDIX For supplemental videos, please see the online version of this paper.