



ELSEVIER

Contents lists available at [ScienceDirect](https://www.sciencedirect.com)

Trauma Case Reports

journal homepage: www.elsevier.com/locate/tcr

Case Report

Splenic infarction complicated with abscess after pelvic trauma as the first presentation of patent foramen ovale - A case report

J. Demma^{*}, D. Weiss, A. Kedar, N. Shussman, G. Zamir, A. Pikarsky, M. Bala

General Surgery and Traumatology Department, Hadassah Hebrew University Medical Center, Jerusalem, Israel

ARTICLE INFO

Keywords:

Splenic abscess
 Trauma coagulopathy
 Diabetic hypercoagulation
 Patent foramen ovale

ABSTRACT

Hypercoagulability after trauma is a known entity. Following significant trauma, most guidelines advise anticoagulation treatment for venous thromboembolism (VTE) prophylaxis. VTE following minor trauma conveyed with arterial or systemic embolization dictate the need to search for uncommon source of thromboembolic complications. This is a report of an unusual case of pulmonary and systemic emboli complicated by splenic abscess following minor trauma in a patient with Diabetes Mellitus as the first presentation of patent foramen ovale (PFO).

Case presentation

A 35-year-old woman, with a history of bipolar disorder and type 2 diabetes mellitus (DM) who was known to have poor compliance presented at our Emergency department with diffuse peritonitis. About two weeks prior to her admission, she was hit by an electric bicycle and was admitted to another hospital. She sustained fractures of the Ramus pubis and transverse process (TP) of fifth lumbar vertebrae as well as a grade 1 tear of the spleen. Upon completion of the workup in emergency department (ED) she was discharged against medical advice claiming she felt well. A few days prior to her admission to our hospital, she noted worsening epigastric pain. Upon arrival to our ED, she was alert, but tachycardic (120 BPM) and tachypneic (40 RPM) with a blood pressure of 110/70 mmHg. Physical examination of the abdomen revealed diffuse peritonitis. Heart and lung examination were within normal limits and limb examination was negative for edema or signs of deep vein thrombosis (DVT). Blood tests were performed and showed metabolic acidosis (pH 7.20) with a base excess of -12, Glucose level of 320 mg/dL (17.7 mmol/l), white blood count of 18.7 K/ μ l, hemoglobin level of 12 g/dl and a platelet count of 433 K/ μ l. Conventional coagulation function tests were normal. Fluid resuscitation was initiated and broad spectrum intravenous antibiotics were administered. Radiographic images were obtained. The chest x-ray raised suspicion for free intraperitoneal air. The abdominal x-ray showed a gasless abdomen with a single dilated sentinel-loop and an unclear thin loculation of air in the left-upper quadrant. Patient underwent a computerized tomography (CT) with intravenous contrast in arterial and venous phases which demonstrated the same known fracture of the ramus pubis, splenic abscess and a small amount of free intraperitoneal air. Furthermore, multiple sites thrombosis were found: right external iliac artery, multiple pulmonary emboli (PE) (Fig. 1) and thrombi in the celiac trunk and the splenic artery (Fig. 2).

Due to the clinical and radiographic findings, the patient was transferred to the operating room (OR) for exploratory laparotomy. Upon entering the abdomen, 600 ml of pus was found in the abdominal cavity and the spleen was found to have necrotic parenchyma and ruptured abscess. There were no previous signs of bowel injury or other intestinal pathology. Splenectomy and vigorous abdominal washout were performed before abdominal closure. Drains were placed in the splenic bed. The patient was stable during surgery albeit

^{*} Corresponding author.

E-mail address: yonatand@hadassah.org.il (J. Demma).

<https://doi.org/10.1016/j.tcr.2021.100479>

Accepted 17 April 2021

Available online 21 April 2021

2352-6440/© 2021 The Authors. Published by Elsevier Ltd. This is an open access article under the CC BY-NC-ND license

(<http://creativecommons.org/licenses/by-nc-nd/4.0/>).

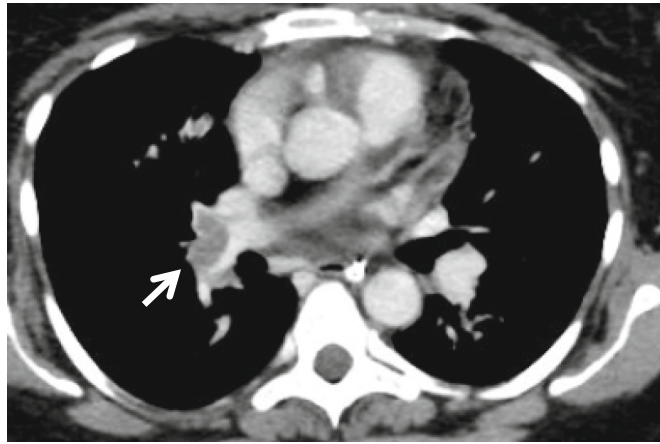


Fig. 1. Pulmonary embolism (arrow).

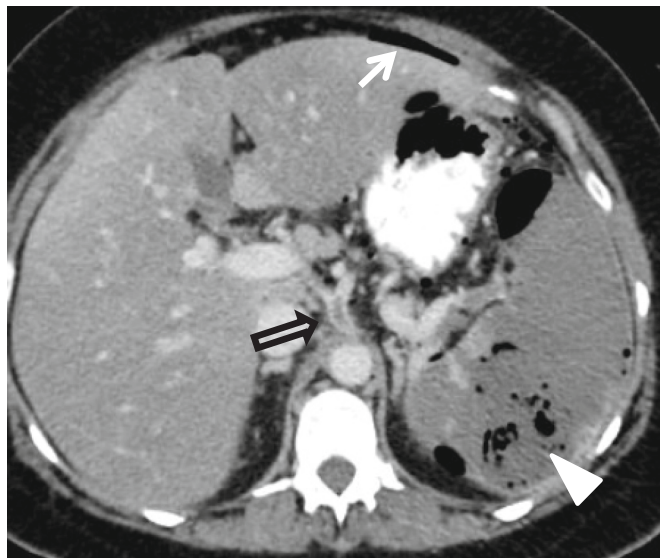


Fig. 2. Free air (white arrow), splenic abscess (white arrowhead), thrombus in the celiac trunk (black arrow).

an estimated blood loss of 400 ml. On post-operative day one, she self-extubated and slowly recovered uneventfully. Oral intake was gradually resumed. Drains' discharge remained clear and they were removed a few days later. Therapeutic dose of Enoxaparin was started the day after surgery and ANTI-XA levels were monitored until therapeutic levels were achieved. Microbial Culture from the spleen came back positive for *Finegoldia magna* and *Lactobacillus crispatus* for which a five-day regimen of IV antibiotics (ampicillin, cefuroxime and metronidazole) was completed. Proper immunization was administered.

Pathology specimen showed an organizing splenic infarct with superinfection and abscess formation and total occlusion of the splenic artery at the hilum of the spleen. The patient was questioned for possible gynecological or dental problems and found negative for both.

In order to understand the cause of these multiple thrombo-emboli, the following tests were obtained: Prothrombin time (PT), partial thromboplastin time (PTT), Fibrinogen level, Circulating Anti-Coagulant (CAC or lupus anticoagulant), Dilute Russell Viper Venom Test (DRV VT), Anticardio-IgM, Anticardio-IgG, Anti-B2-glyco IgG and Anti-B2-glyco IgM - all within normal limits. An echocardiogram including a saline bubble study was done and demonstrated an interatrial shunt, due to a patent foramen ovale (PFO). No vegetations were seen on the heart valves. Follow-up cardiology and hematology consults recommended pharmacological anti-coagulation alone, without cardiac intervention.

The patient was discharged in a good clinical condition under full anticoagulation treatment (Enoxaparin 1 mg per kg BID) on post-operative day 14.

Discussion

This is an unusual case of a splenic abscess accompanied by systemic and pulmonary circulation emboli following mild trauma. There are several factors worth discussing in order to better understand the clinical course.

Splenic abscess

Most splenic abscesses are small, multilocular, and clinically silent lesions found incidentally during autopsy and occurring as a complication of uncontrolled infection elsewhere. Clinically significant cases are uncommon and usually form in the following settings: (1) systemic bacteremia originating elsewhere, such as in endocarditis or intravenous drug injection, allowing for bacterial translocation; (2) superinfection of a damaged spleen (e.g. by trauma, ischemia, infarct or other diseases of the spleen). This is believed to develop via hematogenous spread. (3) Direct extension of an abscess involving an adjacent organ such as the pancreas or kidney; (4) various forms of immunodeficiency (e.g. cytotoxic or steroid use, AIDS, diabetes, etc.) allowing bacterial inoculation and propagation [1,2]. Our patient was diabetic and indeed presented 2 weeks after abdominopelvic blunt trauma with splenic involvement. The extent of injury, however, appeared to be minimal and may not be the direct cause of the splenic infarct and the secondary abscess.

Trauma induced coagulopathy

Trauma is a powerful promoter of coagulopathy. A trend towards bleeding is seen in the early stages with thrombosis developing later on. Traumatic coagulopathy is multifactorial with the early phase caused mainly by fibrinolysis. Severe tissue injury and a surge of pro-inflammatory cytokines activate the tissue-factor-dependent coagulation pathway thus causing massive generation and activation of thrombin. This trend is intensified by relatively insufficient levels of anticoagulant factors [3]. Hypercoagulability following trauma is not detected by routine coagulation assays. The thromboelastogram (TEG) is an alternative test of coagulation that may prove useful in identifying trauma patients who are at risk for developing complications related to a hypercoagulable state [4].

Diabetic hypercoagulation

Vascular complications are the leading cause of morbidity and mortality among patients with type 1 and type 2 diabetes mellitus. These develop due to chronic hyperglycemia, which causes increased oxidative stress and inflammatory responses. The resulting inflammation, endothelial dysfunction, and hypercoagulability all play an important role in the development of vascular complications in diabetic patients [5].

Patent foramen ovale

The foramen ovale is an important fetal structure allowing normal fetal circulation which closes after birth in most individuals. Patent foramen ovale (PFO) meaning non-closure of the foramen ovale has an incidence of 15 to 25% of the healthy population [6]. It involves bypass of the pulmonary circulation caused by shunting of right-sided venous blood into the left-sided arterial circulation. Although most patients with PFO are asymptomatic. Some patients will present with one of the following manifestations: Cryptogenic stroke, migraine and vascular headache, decompression sickness and air embolism, or as in our case the combination of venous and systemic thromboembolic event [7]. This paradoxical embolization is thought to be caused by venous thrombosis entering the systemic circulation via the PFO. However it seems that the situation is different if the cause of the embolism is a fat embolism due to a fracture of a long bone. In this case, it does not appear that PFO is a risk factor for a systemic fat embolism [8].

Coagulopathy workup showed no evidence of any coagulation abnormality in our patient. We suggest that the clinical scenario was caused by trauma, allowing the patient to develop thrombosis of pelvic veins following the fracture. The thrombosis then released multiple emboli into venous circulation, part of which were transferred to the systemic circulation by means of the PFO while others caused PE. The splenic infarction was secondary and became superinfected. The patient's uncontrolled hyperglycemia contributed by worsening the hypercoagulable state and by increasing the risk of secondary infection.

Conclusion

This is a report of an unusual case of pulmonary and systemic emboli complicated by splenic abscess following minor trauma in a patient with DM and a PFO. Patients who present with both pulmonary and systemic thromboembolic complications should be screened for PFO including in the setting of trauma patients.

Declaration of competing interest

None.

References

- [1] M.A. Alonso Cohen, M.J. Galera, M. Ruiz, et al., Splenic abscess, *World J. Surg.* 14 (4) (1990 Jul-Aug) 513–516 (discussion 516-7).

- [2] J.T. Liang, P.H. Lee, S.M. Wang, et al., Splenic abscess: a diagnostic pitfall in the ED, *Am. J. Emerg. Med.* 13 (3) (1995 May) 337–343.
- [3] S. Gando, A. Sawamura, M. Hayakawa, Trauma, shock, and disseminated intravascular coagulation: lessons from the classical literature, *Ann. Surg.* 254 (1) (2011 Jul) 10–19, <https://doi.org/10.1097/SLA.0b013e31821221b1>.
- [4] M. Maegele, P.C. Spinella, H. Schöchl, The acute coagulopathy of trauma: mechanisms and tools for risk stratification, *Shock.* 38 (5) (2012 Nov) 450–458, <https://doi.org/10.1097/SHK.0b013e31826dbd23>.
- [5] C.P. Domingueti, L.M. Dusse, M.D. Carvalho, et al., Diabetes mellitus: the linkage between oxidative stress, inflammation, hypercoagulability and vascular complications, *J. Diabetes Complicat.* 30 (4) (2016 May-Jun) 738–745, <https://doi.org/10.1016/j.jdiacomp.2015.12.018> (Epub 2015 Dec 18).
- [6] Y.P. Sun, S. Homma, Patent foramen ovale and stroke, *Circ. J.* 80 (8) (2016 Jul 25) 1665–1673, <https://doi.org/10.1253/circj.CJ-16-0534> (Epub 2016 Jun 22).
- [7] Lars Søndergaard, Scott E. Kasner, John F. Rhodes, et al., Patent foramen ovale closure or antiplatelet therapy for cryptogenic stroke, *N. Engl. J. Med.* 377 (2017) 1033–1042, <https://doi.org/10.1056/NEJMoa1707404>.
- [8] Slobodan Nikolic, Vladimir Zivkovic, Dragan Babic, et al., Systemic fat embolism and the patent foramen ovale—a prospective autopsy study, *Injury* (2010) 608–612, <https://doi.org/10.1016/j.injury.2010.08.027>.