

CASE REPORT

The birth and rise of a craniopharyngioma: the radiological evolution of an incidental craniopharyngioma detected on serial MRI during medical treatment of a macroprolactinoma

Stefano Mariotti¹, Marco Losa², Pietro Mortini² & Luca Saba³

¹Endocrinology, Department of Medical Sciences, University of Cagliari, Cagliari, Italy

²Department of Neurosurgery, San Raffaele Scientific Institute, Vita-Salute University, Milan, Italy

³Radiology, Department of Medical Sciences, University of Cagliari, Cagliari, Italy

Correspondence

Luca Saba, Radiology, Department of Medical Sciences, University of Cagliari, Cagliari, 09100 Italy. Tel:/Fax: 0706753193; E-mail: lucasaba@tiscali.it

Funding Information

No sources of funding were declared for this study.

Received: 11 October 2015; Revised: 21

March 2016; Accepted: 3 May 2016

Clinical Case Reports 2017; 5(1): 14–17

doi: 10.1002/ccr3.623

Key Clinical Message

This case demonstrates the rare coexistence of a prolactinoma with craniopharyngioma and documents its radiological growth. This case suggests that patients with pituitary neoplasms should be followed closely and although prolactinomas can often be managed medically, a coexistent other lesion may require surgery for histological assessment and to reduce mass effect.

Keywords

Chiasmatic cistern, craniopharyngioma, magnetic resonance, prolactinoma sellar cavity.

We would like to present the case of a 38-year-old female patient with amenorrhea, galactorrhea, and marked hyperprolactinemia discovered few months ago, with a giant macroprolactinoma and the unusual finding of an almost synchronous rise of a craniopharyngioma, during the progressive shrinking of the pituitary tumor on cabergoline therapy. Thus, in this patient, two uncommon conditions occurred: firstly, the sequence of the “birth” of a craniopharyngioma and secondly, the presence of two sellar lesions at the same time.

Five Magnetic Resonance Imaging (MRI) exams were performed and all the procedures were acquired on a Gyroscan 1.5-T superconducting magnet (Philips, Best, the Netherlands) with a head coil before and after the administration of 6 mL of contrast material (gadolinium, Gadovist, Bayer-Schering, Leverkusen, Germany).

The patient underwent the first MRI for amenorrhea (performed 6 months earlier, after interruption of combined estrogen-progestin pill), galactorrhea, and marked hyperprolactinemia (>318,000 mIU/L [>15,000 ng/mL],

normal values in our Laboratory: <424 mIU/L [<20 ng/mL] in women and <318 mIU/L [<15 ng/mL] in men). No other abnormalities of anterior and posterior pituitary hormone secretion were documented. The patient reported mild cephalalgia since several years (for which no specific investigation was performed), a computerized campimetry was normal and no other visual defects were present. A big (61 × 53 mm) mass with homogenous hyper-signal after the intravenous administration of contrast material was documented in the sellar area, including the caudal part of the infundibular stalk, without involvement of the optic chiasm (Fig. 1A). A complete encasement of the internal carotid artery was also present with cavernous sinus invasion. These MRI features, together with the clinical presentation and the prolactin levels, were indicative for macroprolactinoma and according to current guidelines, [1] the patient started cabergoline, 1.5 mg/week. In the second MRI exam performed after 2 months, serum PRL was 1490 mIU/L (70.3 ng/mL), galactorrhea disappeared and a reduction in the

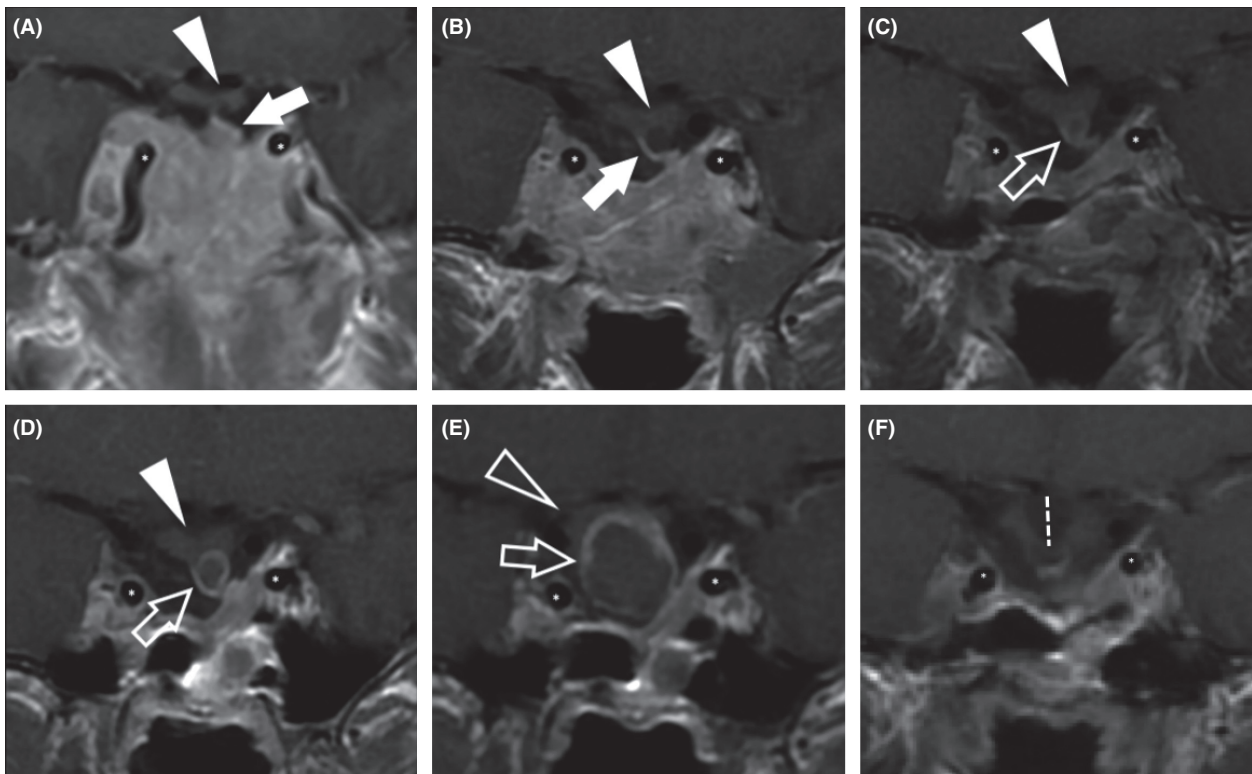


Figure 1. Magnetic Resonance (MRI) coronal image TSE - T1-weighted after administration of contrast material. In panel A, B, C, D, and E the images acquired in the first exam, after 2 months, after 7 months, after 14 months, and after 22 months, respectively, are given. The asterisks identify the carotid arteries in the supra-clinoid segment. In panel A, the caudal part of the infundibular stalk (white arrow) seems to be involved by the prolactinoma, whereas the optic chiasm does not show pathological signal (white arrowhead). There is also a complete encasement of the internal carotid artery. In the panel B, the infundibular stalk (white open arrow) does not show alteration, whereas in the panel C, a small (mm 3.2) hypointense mass with peripheral enhancement is observed; these are the typical features of a craniopharyngioma that become clearer in the panel D with a mass diameter of 5.7 mm and panel E with a mass diameter of 15.6 mm. In the panel E, the cranial dislocation of the optic chiasm is also visible (white open arrowhead). In the MRI check, acquired 2 months after the surgical procedure, there was no evidence of recurrence of pathology (panel F) but the herniation of the chiasmatic cistern into the sellar cavity is visible (white dashed line).

volume of the prolactinoma was clearly visible (Fig. 1B); two months after, normal menses reappeared. From the third exam (performed after 7 months), besides further progressive reduction in the prolactinoma (serum PRL 496.1 mIU/L [23.4 ng/mL]), MRI revealed, in the infundibular stalk, a small round lesion with a homogeneous hypointense signal on T1 sequences and enhanced peripherally after gadolinium; these are typical MRI features associated with a craniopharyngioma (Fig. 1C). During the two following MRI checks (14 months and 22 months), the stalk mass becomes larger reaching a diameter of 15.6 mm (from a value of 3.2 mm) with cranial dislocation of the optic chiasm (Fig. 1D and E). Indeed, the last MRI was performed 4 months in advance for the sudden appearance about 3 weeks before of an important visual field defect, which was confirmed by computerized campimetry. Further reduction in the prolactinoma size was observed, while serum PRL was 207.8 mIU/L (9.8 ng/mL). Moreover, the patient had

regular menses and no clinical/biochemical evidence of anterior or posterior pituitary failure. The patient underwent surgical procedure (by transphenoidal approach) that confirmed the diagnosis of craniopharyngioma (histological examination: papillary craniopharyngioma, Grade I WHO). The surgery was followed by anterior panhypopituitarism and central diabetes insipidus, requiring adequate substitution therapy with hydrocortisone, levothyroxine, estrogen-progestin pill, growth hormone, and desmopressin. Since no specific effort was made to remove the prolactinoma (very small and barely detectable at the time of transphenoidal surgery), the patient was kept on cabergoline therapy, with serum prolactin remaining <212 mIU/L (<10 ng/mL). Visual field improved, but the recovery was not complete. The MRI check performed 2 months after the surgical procedure (Fig. 1D and F) did not find any evidence of recurrence for both craniopharyngioma and prolactinoma, but showed a herniation of the chiasmatic cistern into the

sellar cavity, which could be responsible for the incomplete recovery of visual field.

Prolactinomas make up the majority of pituitary macroadenomas and are fortunately often responsive to medical management [2], as documented in the present case. In cases where the tumor is refractory to medical management, surgical resection is necessary [3]; since refractoriness to medical therapy is more frequent in giant prolactinomas (as the tumor of the present report) which may require multimodal therapy [4], we performed frequent MRIs to strictly follow the tumor morphology; however, the response to cabergoline therapy in terms of reduction in tumor mass, prolactin secretion, and clinical symptoms was excellent.

Magnetic resonance imaging is considered the imaging technique of choice in pituitary and para-sellar tumors because it accurately depicts the complex anatomy around the sellar well [5]. Several pathologic entities occur in this region, and most can be differentiated with MRI. These entities can be broadly divided on the basis of their involvement, as follows: intra-sellar, infundibular, supra-sellar, anterior part of the third ventricle and/or optic chiasm, and sphenoid and/or cavernous sinus.

In this case, the extremely uncommon finding was the opportunity to identify the birth and rise of a craniopharyngioma, during the follow-up of a macroprolactinoma responding to cabergoline therapy. Moreover, a second uncommon condition was documented: the presence of two different sellar lesions (prolactinoma and craniopharyngioma) at the same time. This extremely uncommon condition was probably responsible for the delayed recognition of the craniopharyngioma image, which was detectable several months before the onset of visual field loss (Fig. 1C and D) and whose detection could have allowed earlier surgical removal.

Finally, we considered the possibility that the appearance of the craniopharyngioma could be the consequence of cabergoline therapy, but we feel it very unlikely, because until now no association has been described between this drug and development of craniopharyngioma.

Craniopharyngiomas are a benign but aggressive neoplasms arising along the craniopharyngeal duct. MRI features suggest this pathological entity even if false-positive results may occur with cysts, metastases, infarctions, epidermoid cysts, and abscesses. All these lesions may appear as areas of low-signal intensity after the administration of gadolinium-based contrast agent, but the rim enhancement is more likely associated with the craniopharyngioma [6].

Some authors found that patients with craniopharyngioma occasionally also have prolactinomas and in 1986 *Wheatley et al.* described the case of a 61-year-old man

using the CT image [7]. In a recently published review paper, *Guaraldi et al.* reported that the association between craniopharyngioma (typically adamantinomatous type) and pituitary adenoma is very rare [8] but this condition can occur and therefore, it is important to strictly follow imaging techniques of patients with pituitary tumors in order to identify the occurrence of a second neoplasm. Aside from these sporadic reports, to the best of our knowledge, no condition has been identified so far with a clear association between prolactinomas and craniopharyngiomas. Given the relatively young age of the patient, the possibility of a still unrecognized genetic mutation in one of the transcription factors involved in the Rathke pouch's formation and in the early anterior pituitary development can be envisaged, although at the present time, this possibility remains fully speculative.

However, in this case also the location of craniopharyngioma is uncommon, because this tumor is frequently identified in the supra-sellar region only when its diameter is much bigger than one in our case. The observation of the pituitary stalk craniopharyngioma is unusual because it is uncommon that this tumor may be diagnosed at such an early stage that it only involves the pituitary stalk, before enlarging and extending to supra- or para-sellar region [9].

From the MRI point of view, in the differential diagnosis setting, the primary tumors that can involve the pituitary stalk include gliomas, metastases (usually from breast and lung cancers), leukemia (chronic myelogenous leukemia and acute myelogenous leukemia), lymphoma, and benign tumors like meningioma. However, when a patient develops a *new* pituitary stalk lesion, the physician should be aware that not infrequently these are malignant lesions and it is therefore often required to intervene surgically to obtain definitive histology [10].

The present case suggests that physicians should be alerted to incidental diagnoses and that there is the need for follow-up imaging and although prolactinomas can often be managed medically, a coexistent other lesion may require surgery for histological assessment and to reduce mass effect.

Conflict of Interest

None declared.

References

1. Melmed, S., F. F. Casanueva, A. R. Hoffman, D. L. Kleinberg, V. M. Montori, J. A. Schlechte, et al. 2011. Diagnosis and treatment of hyperprolactinemia: an Endocrine Society clinical practice guideline. *J. Clin. Endocrinol. Metab.* 96:273–288.

2. Schlechte, J. A. 2003. Clinical practice. Prolactinoma. *N. Engl. J. Med.* 349:2035–2041. Review. PubMed PMID: 14627789.
3. Bloomgarden, E., and M. E. Molitch. 2014. Surgical treatment of prolactinomas: cons. *Endocrine* 47:730–733.
4. Moraes, A. B., C. M. Silva, L. Vieira Neto, and M. R. Gadelha. 2013. Giant prolactinomas: the therapeutic approach. *Clin. Endocrinol. (Oxf)* 19:447–456.
5. Hess, C. P., and W. P. Dillon. 2012. Imaging the pituitary and parasellar region. *Neurosurg. Clin. N. Am.* 23:529–542.
6. Mollá, E., L. Martí-Bonmatí, A. Revert, E. Arana, F. Menor, R. Dosdá, et al. 2002. Craniopharyngiomas: identification of different semiological patterns with MRI. *Eur. Radiol.* 12:1829–1836.
7. Wheatley, T., J. D. Clark, and S. Stewart. 1986. Craniopharyngioma with hyperprolactinaemia due to a prolactinoma. *J. Neurol. Neurosurg. Psychiatry* 49:1305–1307.
8. Guaraldi, F., N. Prencipe, V. di Giacomo, M. Scanarini, V. Gasco, M. P. Gardiman, et al. 2013. Association of craniopharyngioma and pituitary adenoma. *Endocrine* 44:59–65.
9. Figueiredo, E. G., L. C. Welling, J. W. de Faria, and M. J. Teixeira. 2011. Pituitary stalk craniopharyngioma. *BMJ Case Rep.* 2011: pii: bcr0620103097.
10. Ariel, D., H. Sung, N. Coghlan, R. Dodd, I. C. Gibbs, and L. Katznelson. 2013. Clinical characteristics and pituitary dysfunction in patients with metastatic cancer to the sella. *Endocr. Pract.* 19:914–919.