

## A Large Refilling Cystic Lesion In A Gastric Bypass Patient

Virendra Tewari, MD<sup>1</sup>, Deepali Tewari, MD<sup>2</sup>, Daylem Antunez, MD<sup>1</sup>, Shahzad Iqbal, MD<sup>3</sup>, and Susan Williams, MD<sup>1</sup>

<sup>1</sup>New York Medical College, Metropolitan and Woodhull Hospitals, New York, NY

<sup>2</sup>New York Medical College, Maria Fareri Children's Hospital at Westchester Medical Center, New York, NY

<sup>3</sup>Kings County and SUNY Downstate University Hospitals, Brooklyn, NY

---

### Abstract

We describe a patient with a history of gastric bypass and chronic alcoholism suffering from a rare Peterson's hernia resulting from her surgery. There are a few case reports in which afferent loop obstruction was misdiagnosed as pancreatic pseudocyst after Billroth II gastrectomy. Ours is the first in which Peterson's hernia was initially misdiagnosed as a pancreatic pseudocyst in a gastric bypass patient.

---

### Introduction

Internal hernias have been reported in 0.2–9% of gastric bypass patients. Petersen's hernia is one of the rarest, and occurs through the potential gap between the jejunal mesentery and mesocolon behind the alimentary limb.<sup>1</sup> Prior case reports have described patients with acute abdominal pain, marked hyperamylasemia, and palpable abdominal masses due to afferent loop obstruction 5-15 years after Billroth II gastrectomy, but were initially diagnosed as pancreatic pseudocysts, obstructive jaundice, and pancreatitis.<sup>2-4</sup> With the growing number of bariatric surgeries, physicians should be aware of internal hernia complications to avoid misdiagnosis and delayed management.<sup>5</sup>

### Case Report

A 42-year-old woman with history of hypertension, bipolar disorder, chronic alcohol abuse, breast reduction 6 years ago, and gastric bypass 4 years ago was admitted with abdominal pain and an epigastric lump. Computed tomography (CT) showed a large multilobulated cystic collection extending to the pelvis (Figure 1), thought to be a pancreatic pseudocyst secondary to alcohol-induced pancreatitis. She was treated with bowel rest, total parenteral nutrition, and octreotide. When no regression in cyst size was observed after 3 weeks, CT-guided catheter drainage was performed. The drainage volume was approximately 1.5 L of clear fluid per day with fluid analysis showing amylase 15,320 U/L and lipase 3080 U/L. The collection resolved after a few days, but quickly recurred after inadvertent catheter dislodgment. The patient remained afebrile, but began noting abdominal discomfort.

At a facility with bariatric surgery experience, a fresh review of the prior CT identified the cystic lesion as a distended, excluded gastroduodenal limb with intestinal obstruction. An exploratory laparotomy showed that the biliopancreatic limb was chronically incarcerated through the Petersen's space. Resection and re-anastomosis was performed and a gastrostomy tube was placed. She had an unremarkable recovery and the gastrostomy tube was removed after 4 days (Figure 2).

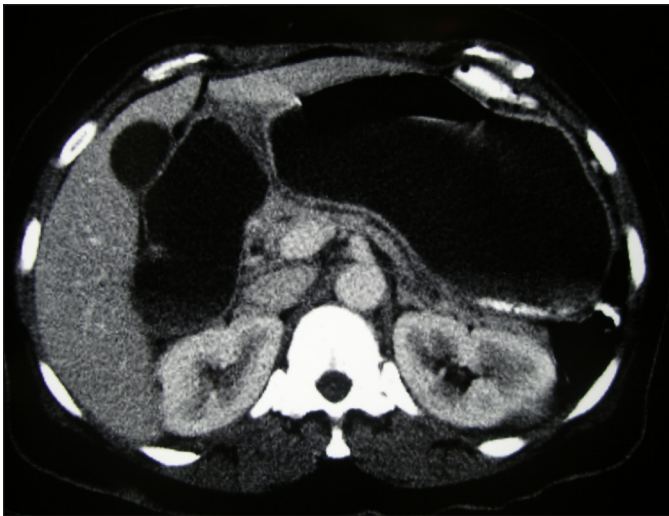
---

ACG Case Rep J 2015;2(4):252-254. doi:10.14309/crj.2015.76. Published online: July 9, 2015.

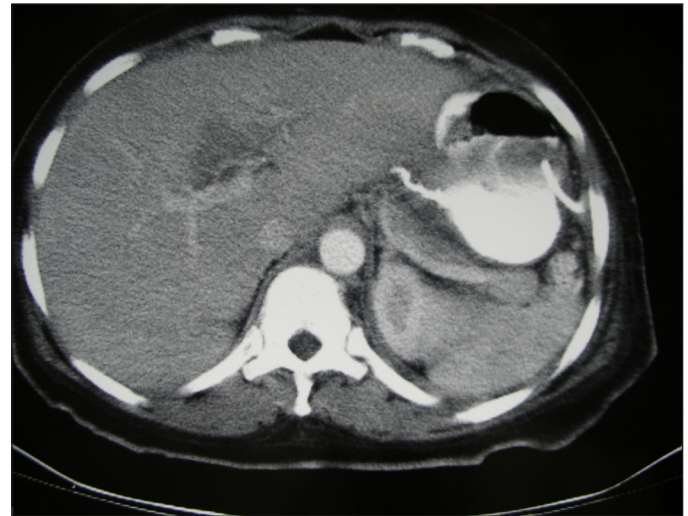
**Correspondence:** Virendra Tewari, Department of Gastroenterology, Metropolitan Hospital, 1901 1st Avenue, New York, NY 10029 (Virendra.Tewari@nychhc.org).



**Copyright:** © 2015 Tewari et al. This work is licensed under a Creative Commons Attribution-NonCommercial-NoDerivatives 4.0 International License. To view a copy of this license, visit <http://creativecommons.org/licenses/by-nc-nd/4.0>.



**Figure 1.** CT showing a large multilobulated cystic collection extending to the pelvis.

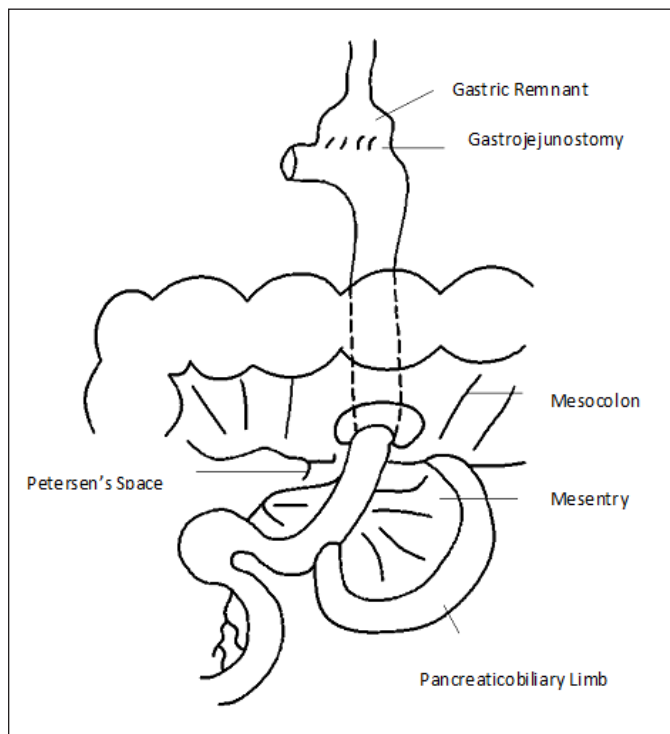


**Figure 2.** Temporary resolution of cyst collection with transcutaneous catheter drainage.

## Discussion

Bariatric surgery is an effective treatment modality for morbid obesity, which remains a significant health burden affecting 34.9% of U.S. adults.<sup>6,7</sup> Roux-en-Y gastric bypass surgery—first introduced in 1977 by Griffen et al—creates a small gastric pouch and reduces the functional length of jejunum.<sup>8</sup> It is effective for achieving significant weight reduction.<sup>9,10</sup> The laparoscopic approach is now the procedure of choice in North America.<sup>11</sup> Complications can occur in 9.5%

of patients who undergo this surgery.<sup>12</sup> Major complications include small bowel obstruction, leaks and abscesses, anastomotic strictures, and fistulae. Minor complications include contained leaks, marginal ulcers, pancreatitis, esophagitis, splenic abscess, and cholelithiasis.<sup>13</sup> Internal hernias may form as a result of iatrogenic mesenteric defects and have been reported in 0.2–9% of gastric bypass patients.<sup>14</sup> Although mesenteric defects are closed at surgery, rapid post-operative weight loss with decrease in abdominal fat loosens sutures and widens defects.<sup>15</sup> The laparoscopic approach is more prone to hernia formation than an open operation, possibly because of fewer adhesions to tether small bowel loops.<sup>16</sup>



**Figure 3.** Diagram of Roux-en-Y gastric bypass illustrating Petersen's space.

There are 3 potential sites for the herniation: at the defect in the transverse mesocolon through which the Roux loop passes, at the mesenteric defect at the enteroenterostomy, and behind the Roux limb mesentery.<sup>17</sup> This third type, developing behind Roux limb mesentery through the potential gap between the jejunal mesentery and mesocolon, is called Petersen's hernia. It is one of the rarest types and can be retrocolic Petersen or antecolic Petersen, based on where the Roux loop is placed (Figure 3).<sup>1</sup>

An internal hernia usually presents as a closed loop obstruction with abdominal pain, distension, nausea, and vomiting. Hernias may be reducible initially, so symptoms may begin intermittently, followed by recurrence with greater severity as incarceration or even strangulation occurs.<sup>12</sup> Our patient was fortunate not to develop strangulation and gangrenous complications despite the biliopancreatic limb being incarcerated for a prolonged period.

CT is the method of choice for diagnosis of internal hernia. CT findings include clustering of small bowel loops and distortion of mesenteric vasculature. Swirling of mesenteric vessels near the mesenteric root may be the most sensitive sign of an internal hernia in gastric bypass.<sup>17</sup> In our case, the large size of the fluid collection obscured these features, biliopancreatic limb obstruction produced high levels of pancreatic enzymes, and high daily drainage causing misdiagnosis as a pancreatic pseudocyst. The importance of bariatric surgery experience was underscored when imaging review by specialists established the correct diagnosis, which prompted urgent surgery.

## Disclosures

Author contributions: V. Tewari is the principal author and article guarantor. D. Tewari and D. Antunez performed the literature search and assisted in writing and revising the manuscript. S. Iqbal provided surgical and post-operative details of the case and assisted in editing and revising the manuscript. S. Williams edited and proofread the manuscript.

Financial disclosure: None to report.

Informed consent was obtained for this case report.

Received: February 18, 2015; Accepted: May 7, 2015.

## References

1. Ximenes MA, Baroni RH, Trindade RM, et al. Petersen's hernia as a complication of bariatric surgery: CT findings. *Abdom Imaging*. 2011;36(2):126–129.
2. Conter RL, Converse JO, McGarrity TJ, Koch KL. Afferent loop obstruction presenting as acute pancreatitis and pseudo-cyst: Case report and review of the literature. *Surgery*. 1990;108(1): 22–27.
3. Joo YE, Kim HS, Choi SK, et al. Internal hernia presenting as obstructive jaundice and acute pancreatitis. *Scand J Gastroenterol*. 2002;37(8):983–986
4. Kawakami M, Mukaiya M, Kimura Y, et al. Obstructive jaundice due to internal herniation: A case report and review of the literature. *Hepato-gastroenterology*. 2002;49(46):1030–1032.
5. Renault K, Gyrtrup H, Damgaard K, et al. Pregnant woman with fatal complication after laparoscopic Roux-en-Y gastric bypass. *ACTA Obstet Gynecol Scand*. 2012;91(7):873–875.
6. Ogden CL, Carroll MD, Kit BK, Flegal KM. Prevalence of childhood and adult obesity in the United States, 2011–2012. *JAMA*. 2014;311(8):806–814.
7. National Institutes of Health. Clinical guidelines on the identification, evaluation, and treatment of overweight and obesity in adults: The evidence report. *Obes Res*. 1998;6(suppl 2):51S–209S.
8. Griffen WO, Young VL, Stevenson CC. A prospective comparison of gastric and jejunioileal bypass procedures for morbid obesity. *Ann Surg*. 1977;186(4):500–509.
9. Sugerma HJ, Starkey JV, Birkenhauer R. A randomized prospective trial of gastric bypass versus vertical banded gastroplasty for morbid obesity and their effects on sweets versus nonsweet eaters. *Ann Surg*. 1987;205(6):613–624.
10. Capella JF, Capella RF. The weight reduction operation of choice: Vertical banded gastroplasty or gastric bypass. *Am J Surg*. 1996;171(1):74–79.
11. Wittgrove AC, Clark GW, Schubert KR. Laparoscopic gastric bypass, Roux-en-Y: Preliminary report of five cases. *Obes Surg*. 1995;4(4):353–357.
12. Blachar A, Federle MP, Pealer KM, et al. Gastrointestinal complications of laparoscopic Roux-en-Y gastric bypass surgery: Clinical and imaging findings. *Radiology*. 2002;223(3):625–32.
13. Mhuircheartaigh J, Abedin S, Bennett AE, Tyagi G. Imaging features of bariatric surgery and its complications. *Semin Ultrasound CT MR*. 2013;34(4):311–324.
14. Filip JE, Mattar SG, Bowers SP, Smith CD. Internal hernia formation after laparoscopic Roux-en-Y gastric bypass for morbid obesity. *Am Surg*. 2002;68(7):640–643.
15. Iannelli A, Facchiano E, Gugenheim J. Internal hernia after laparoscopic Roux-en-Y gastric bypass for morbid obesity. *Obes Surg*. 2006;16(10):1265–1271.
16. Higa KD, Ho T, Boone KB. Internal hernias after laparoscopic Roux-en-Y gastric bypass: Incidence, treatment and prevention. *Obes Surg*. 2003;13(3):350–4.
17. Lockhart ME, Tessler FN, Canon CL, et al. Internal hernia after gastric bypass: Sensitivity and specificity of seven CT signs with surgical correlation and controls. *AJR Am J Roentgenol*. 2007;188(3):745–750.

## Publish your work in ACG Case Reports Journal

ACG Case Reports Journal is a peer-reviewed, open-access publication that provides GI fellows, private practice clinicians, and other members of the health care team an opportunity to share interesting case reports with their peers and with leaders in the field. Visit <http://acgcasereports.gi.org> for submission guidelines. Submit your manuscript online at <http://mc.manuscriptcentral.com/acgcr>.