

CASE REPORT

The Single-access for Hi-risk PCI (SHiP) technique

Jason Wollmuth MD¹ | Ethan Korngold MD¹ | Kevin Croce MD, PhD² |
 Duane S. Pinto MD, MPH³ 

¹Providence Heart and Vascular Institute, Providence, Oregon

²Brigham and Women's Hospital, Boston, Massachusetts

³Division of Cardiology, Beth Israel Deaconess Medical Center, Boston, Massachusetts

Correspondence

Duane S. Pinto, Division of Cardiology, Beth Israel Deaconess Medical Center, 1 Deaconess Road, Boston, MA 02115.

Email: dpinto@bidmc.harvard.edu

Abstract

Currently, the Impella CP (Abiomed, Danvers, Massachusetts) percutaneous ventricular assist catheter requires implantation through a 14 French sheath. Additional arterial access is commonly obtained to perform therapeutic or diagnostic procedures. Multiple arterial access requires time and results in increased risk for vascular complications. Some patients may have limited arterial access. We describe the Single-access for Hi-risk PCI (SHiP) technique to allow for rapid and safer single access utilizing only the Impella access site. After the Impella catheter is placed in the standard fashion, a micropuncture needle is used to pierce the hemostasis valve of the Impella insertion sheath. After dilating the hemostasis valve and exchanging for a 0.035" wire, up to a 7 French sheath can be inserted for PCI within the 14 French access sheath and alongside the 9 French portion of the Impella catheter. After PCI, the sheath is removed. We report on a case series of 17 patients using this technique. There were no instances of bleeding during the procedure or after removal of the PCI sheath, and no evidence of disruption of the Impella sheath.

1 | INTRODUCTION

The size of the sheath required for Impella placement is dependent on the largest portion of the device. For the Impella CP catheter, the blood inlet area requires a 14 French sheath. After the blood inlet portion of the catheter is delivered through the sheath into the left ventricle, the shaft of the catheter is what remains. The diameter of this portion of the device is only 9 French. As such, there is another safer option to place an additional sheath for coronary access by utilizing this additional space thereby avoiding the perils of additional access site cannulation.^{1,2}

2 | TECHNIQUE DESCRIPTION

The 14 French Impella sheath (Figure 1) is placed in the standard fashion over an 0.035" wire. Subsequently, a micropuncture access needle is used to pierce the hemostasis valve in the superior portion of the sheath with care to avoid piercing the Impella catheter (Figure 2). After

exchanging for an 0.035" wire, an 8 French dilator is used to dilate the hemostasis valve and the sheath for PCI is placed (Figure 3). After PCI, the sheath can simply be removed since the defect closes upon itself. If the Impella catheter is to be removed, the arteriotomy is closed in the standard fashion. If the Impella catheter is left in place, the sheath can be removed and the reaccess sheath inserted in the standard fashion.

3 | CASE SERIES

Table 1 summarizes the characteristics of the patients and procedures in this series. Nearly all patients underwent left main coronary artery intervention in the setting of active congestive heart failure and significantly reduced left ventricular contractile function. Two patients had severe aortic stenosis and underwent concomitant balloon aortic valvuloplasty using the same single access. In one of these, the Impella 2.5 catheter was used with the 14 French sheath because the Impella CP catheter would not cross the stenotic aortic valve. The Impella CP catheter was used in all other cases. Multivessel intervention (94%)

This is an open access article under the terms of the Creative Commons Attribution-NonCommercial License, which permits use, distribution and reproduction in any medium, provided the original work is properly cited and is not used for commercial purposes.

© 2019 The Authors. *Catheterization and Cardiovascular Interventions* published by Wiley Periodicals, Inc.



FIGURE 1 Impella insertion sheath

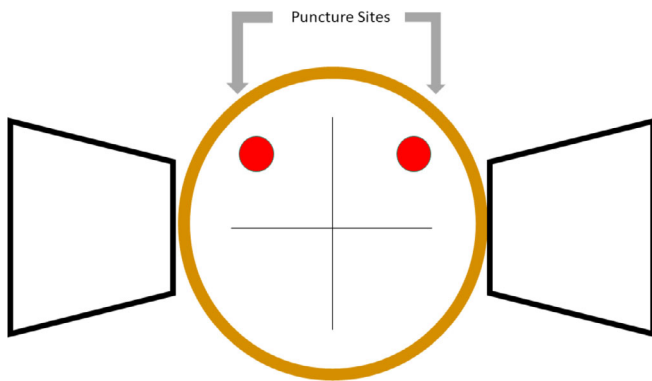


FIGURE 2 Illustration depicting suggested entry points for puncture using the SHiP technique

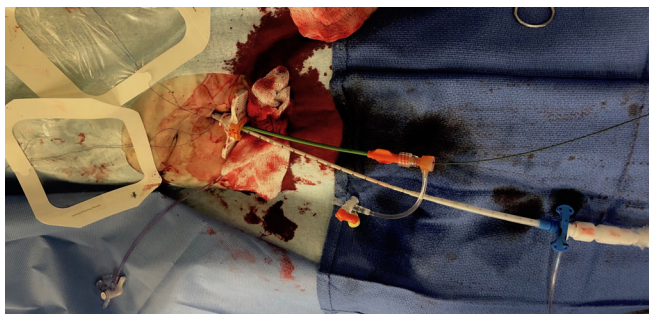


FIGURE 3 Example of Impella catheter and PCI sheath placed within the Impella insertion sheath

and atherectomy (88%) were employed in nearly all cases. The Impella catheter was removed in the catheterization laboratory in all but 3 cases, and the insertion sheath was removed in all cases. It is not the practice of the operators to leave the insertion sheath in place outside the catheterization laboratory, given risk for limb ischemia. As such, other sheaths besides the sheath supplied with the Impella catheter were not utilized in this series.

Many of the procedures were lengthy, and in 35% ($n = 6$), PCI for chronic total occlusions were performed. Despite the length of time

TABLE 1 Characteristics of the patients and procedures

Age (y)	Sex	Presentation	LVEF (%)	NYHA	Severe AS	LMCA	Multivessel	Atherectomy	Hemostasis valve bleeding	Impella removed in catheterization laboratory	Access complication
53	M	NSTEMI	15	IV	N	N	Y	N	N	N	N
83	F	NSTEMI	35	IV	N	Y	Y	Y	N	N	Y
90	M	NSTEMI	30	IV	Y	N	Y	Y	N	Y	N
65	F	NSTEMI	60	IV	N	Y	Y	Y	N	Y	N
82	M	NSTEMI	15	IV	N	Y	Y	Y	N	Y	N
69	M	NSTEMI	20	IV	N	Y	Y	Y	N	Y	N
75	F	NSTEMI	25	IV	N	Y	Y	Y	N	Y	N
88	M	NSTEMI	45	IV	Y	Y	Y	Y	N	Y	N
79	F	NSTEMI	30	IV	N	Y	Y	Y	N	N	N
53	F	UA	20	IV	N	Y	Y	Y	N	Y	N
70	M	NSTEMI	40	IV	N	Y	Y	Y	N	Y	N
74	F	ELECTIVE	50	IV	N	Y	Y	Y	N	Y	N
75	F	NSTEMI	30	IV	N	Y	Y	N	N	Y	N
62	M	ELECTIVE	55	II	Y	Y	Y	Y	N	Y	N
66	M	NSTEMI	20	IV	N	Y	Y	Y	N	Y	N
78	M	ELECTIVE	30	III	N	Y	Y	Y	N	Y	N
83	M	NSTEMI	30	IV	N	N	N	Y	N	Y	N

Abbreviations: AS, aortic stenosis; LMCA, left main coronary artery; LVEF, left ventricular ejection fraction; NSTEMI, non-ST segment myocardial infarction; NYHA, New York Heart Association Classification.

that the sheaths were indwelling, there was no evidence of bleeding through the hemostasis valve during the cases or after removal of the PCI sheath. Furthermore, there was no thrombus formation after removal of the Impella sheath and catheters in all but one patient. This patient was noted to have iliac thrombus on angiography during Impella catheter removal several days after the PCI procedure.

4 | DISCUSSION

We report a technique to rapidly and safely perform complex PCI using only the arterial access obtained for Impella placement. This technique obviates the need for unnecessary additional arterial access and avoids delays and the risk of multiple access site complications which can be of significant importance among those who are urgently ill or with limited access site options due to peripheral arterial disease. There was one patient with a vascular complication in this series. It is uncertain whether this was related to either the Impella, PCI sheath placement, use of the SHiP technique, or simply the indwelling catheter in the artery.

It is important to puncture the sheath diaphragm away from the central portion to maintain hemostasis and then the sheath inserted over a wire. If the sheath is simply advanced into the insertion sheath, there will be bleeding as the valve cannot form a tight seal around both the Impella catheter and PCI sheath.

While a 6 French × 10 cm sheath can be used and was in 4 cases, we recommend the use of a 7 French × 45 cm sheath with a 35-cm hydrophilic coating to improve the ease of insertion and to afford greater ability to torque up to a 7 French PCI guiding catheter. An attempt was made to use an 8 French sheathless guide in one case but was unsuccessful. We emphasize that care should also be taken when advancing the sheath so as not to disrupt the integrity of the peel-away introducer sheath.

5 | CONCLUSION

The SHiP technique is a simple, safe, and reproducible way to perform coronary revascularization procedures and mechanical circulatory support using single arterial access. This strategy affords the opportunity to avoid unnecessary vascular complications and the ability to treat individuals with limited vascular access as in this case.

ORCID

Duane S. Pinto  <https://orcid.org/0000-0002-2309-8480>

REFERENCES

1. Kinnaird T, Anderson R, Ossei-Gerning N, Gallagher S, Large A, Strange J, Ludman P, de Belder M, Nolan J, Hildick-Smith D and others. Vascular access site and outcomes among 26,807 chronic total coronary occlusion angioplasty cases from the British cardiovascular interventions society National Database. *JACC Cardiovasc Interv* 2017;10(7):635–644.
2. Ortiz D, Jahangir A, Singh M, Allaqaband S, Bajwa TK, Mewissen MW. Access site complications after peripheral vascular interventions: incidence, predictors, and outcomes. *Circ Cardiovasc Interv*. 2014;7(6):821–828.

SUPPORTING INFORMATION

Additional supporting information may be found online in the Supporting Information section at the end of this article.

How to cite this article: Wollmuth J, Korngold E, Croce K, Pinto DS. The Single-access for Hi-risk PCI (SHiP) technique. *Catheter Cardiovasc Interv*. 2020;96:114–116. <https://doi.org/10.1002/ccd.28556>