

Acute kidney injury in a patient with metabolic syndrome

Gioacchino Li Cavoli^{1*}, Rita Passantino², Angelo Ferrantelli¹, Angelo Tralongo¹, Franca Servillo¹, Tancredi Vincenzo Li Cavoli¹, Pietro Tralongo¹, Mattia Palmeri¹, Giacomo Ferrantelli¹, Rotolo Ugo¹

¹Nephrology-Dialysis, Civico and Di Cristina Hospital, Palermo, Italy

²Pathologic Anatomy, Civico and Di Cristina Hospital, Palermo, Italy

Article Info



Article Type:
Case Report

Article History:

Received: 14 Feb. 2015
 Revised: 26 Mar. 2015
 Accepted: 26 Mar. 2015
 ePublished: 27 May 2015

Keywords:

Acute kidney injury
 Metabolic syndrome
 Obesity

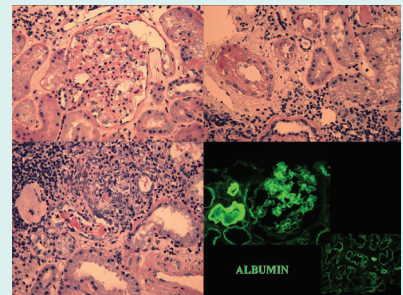
Abstract

Introduction: The metabolic syndrome (MS) encompasses many metabolic abnormalities and the insulin resistance is considered as one of the most significant denominators. The chronic kidney disease (CKD) is an emerging health problem but only few patients would reach the end stage renal disease. There exists an increasing strong association between MS and CKD, but up until now the link between MS and CKD is unclear and there are few studies regarding the renal histology in MS.

Methods: We describe an acute tubulointerstitial nephritis case, due to both infective and pharmacological aetiology, overlapping relevant histological changes (focal segmental glomerulosclerosis [FSG], hyaline arteriosclerosis) in a patient with MS and previously normal renal function. Despite the severe vascular finding (elevated renal arterial resistive index), the patient recovered a normal renal function.

Results: We reviewed the kidney pathological studies in MS and analyzed the principal renal histological images of glomerulomegaly, segmental glomerulosclerosis, and obesity-related glomerulopathy.

Conclusion: Despite the strong association, the renal involvement in MS has not been proven. A greater knowledge of the combination of histological renal changes in MS can help to understand the pathophysiological mechanism(s) of MS.



Introduction

In the United State of America, the two-thirds of adult population are suffering from overweight and one-third are obese.¹

According to the epidemiologic studies in other parts of the world, the obesity is a public health problem. The metabolic syndrome (MS) encompasses many metabolic abnormalities. Triglyceride and high-density lipoprotein cholesterol high levels, fasting hyperglycemia, abdominal obesity, and high blood pressure are the leading criteria while the insulin resistance is the most significant denominator of MS.² The chronic kidney disease (CKD) is an emerging health problem. Arterial Hypertension and Diabetes Mellitus are the most predictive factors of CKD but only few patients would reach the end stage renal disease.^{3,4} Up to now, there exists an increasing strong association between MS and CKD, however the pathogenetic mechanisms inducing the renal involvement

in MS are for the most part unknown. Although there are a large number of investigations regarding the link between MS and renal cell carcinoma, few studies tackle the renal histology in MS. In the current study, we describe a case of acute tubulointerstitial nephropathy overlapping early diabetic nephropathy in a patient with MS and review the kidney pathological features.

Case description

A 69-year-old Caucasian male, with previous normal renal function, suffering from diabetes mellitus, obesity (BMI= 38 kg/m²), hypercholesterolemia, hypertension and coronary artery disease started haemodialysis because of severe acute renal failure (oliguria, dyspnoea, creatinine 10.3 mg/dL). His recent medical history revealed toothache, fever, myalgia, and intake of nonsteroidal anti-inflammatory drugs. Renal ultrasonography showed no hydronephrosis, normal size, and echogenicity but



*Corresponding author: Gioacchino Li Cavoli, Email: gioacchinolicavoli@libero.it



© 2015 The Author(s). This work is published by BioImpacts as an open access article distributed under the terms of the Creative Commons Attribution License (<http://creativecommons.org/licenses/by-nc/4.0/>). Non-commercial uses of the work are permitted, provided the original work is properly cited.

elevated renal arterial resistive index (RI=1). Instrumental and laboratory examinations detected pneumonia with bacteraemia from *Staphylococcus aureus*. Immunological tests and other microbiological investigations were negative. Proteinuria was 1.2 g/24 h. Treatment included volume repletion, antibiotics and a 3-day course of corticosteroid therapy, with significant improvement in his symptoms. Based on renal biopsy: among 22 glomeruli, we detected focal segmental glomerulosclerosis (FSG) and glomerulomegaly (Fig. 1), arteriolar hyalinosis and severe interstitial inflammation (Figs. 2-3) without evidence for other causes of acute kidney injury. The immunofluorescence microscopy highlighted linear staining for albumin and IgG along the glomerular basement membranes (Fig. 4). We diagnosed an acute tubulointerstitial nephropathy overlapping early diabetic nephropathy. The patient underwent to haemodialysis for two months up to recovery of the renal function (creatinine: 1,2 mg/dL, proteinuria 0.6 g/24 h).

Discussion

The link between kidney disease and MS is investigated

by experimental and clinical histopathology. The study of Nagase et al indicated the podocyte injury as early key manifestation in a rat model of MS and nephropathy.⁶ Experimental studies revealed an increase of glomerular size, a podocyte injury, expansion, and sclerosis of the mesangium in genetically obese rats.⁷ Longitudinal clinical studies in humans highlighted that glomerulomegaly is the histological characteristic change in glomerular hyperfiltration and the increase of albuminuria is the first clinical manifestation. In human pathology, the obesity is associated with CKD, and glomerulomegaly, proteinuria, and FSG define the obesity-related glomerulopathy (ORG). However, the pathophysiology of ORG and glomerulosclerosis is not fully understood.^{8,9} Since 1974, the glomerulomegaly and the FSG have been known to associate with severe obesity.¹⁰ Later on, it became evident that ORG encompasses a continuum from glomerulomegaly to glomerulosclerosis.¹¹ On kidney biopsy, the patients with massive obesity develop glomerulomegaly. In 95 obese patients with a mean BMI of 52 kg/m², the kidney biopsies reported a greater prevalence of glomerulomegaly, podocyte hypertrophy, mesangial

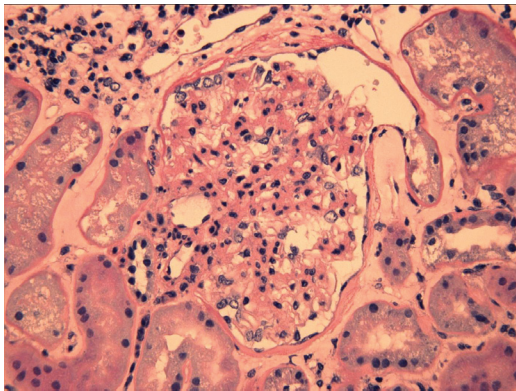


Fig. 1. Renal biopsy micrographs of chronic kidney disease. Light microscopic: glomerulomegaly with arteriolar hyalinosis and a perihilar segmental sclerosis with synechiae formation and diffuse thickening of capillary basement membranes (H&E stain, x 40).

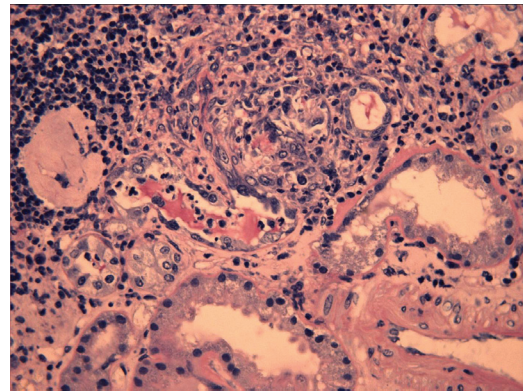


Fig. 3. Renal biopsy micrographs of chronic kidney disease. Light microscopic: interstitial patchy granulomas (epithelioid histiocytes) with tubulitis (intramural and intraluminal neutrophils) (H&E stain, x 40).

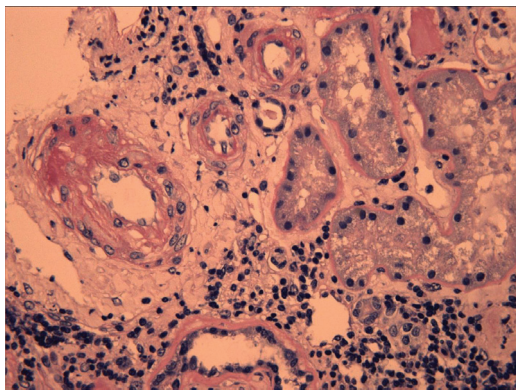


Fig 2. Renal biopsy micrographs of chronic kidney disease. Light microscopic: hyalinosis and marked thickening of medium and small arteries wall, due to intimal fibrosis with narrowing of the lumen, and inflammatory interstitial infiltrates with evidence of tubulitis (H&E stain, x 40).

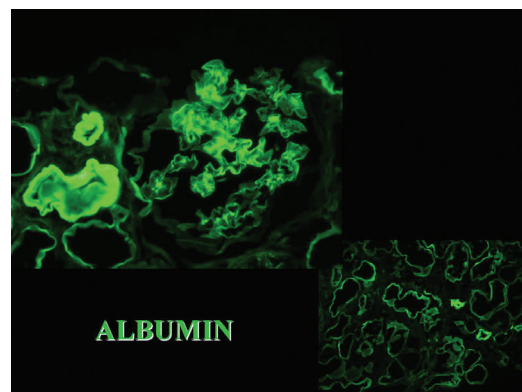


Fig 4. Renal biopsy micrographs of chronic kidney disease. Immunofluorescence: IgG and albumin in glomerular basement membranes.

cell proliferation, and an increase of mesangial matrix.¹² In 49 obese renal donors, compared to 41 nonobese controls, Rea et al reported a larger glomerular planar surface area; the urinary microalbumin excretion and the patient weight correlated with this finding but the obese renal donors did not show evidence of glomerulosclerosis.¹³ Alexander et al examined 146 patients undergone to elective nephrectomy for renal cell carcinoma. Twelve of whom had also MS. The tubular atrophy, the interstitial fibrosis, the arterial sclerosis, the global glomerulosclerosis, and the segmental glomerulosclerosis had a higher prevalence in these patients with MS as compared to healthy subjects, suggesting evidence of vascular damage, but the glomerular volume was not different between MS-patients and controls.¹⁴ Kambham et al compared 71 patients with ORG and 50 patients with idiopathic-FSG without ORG. The Author detected FSG with glomerulomegaly in 57 and glomerulomegaly alone in 14 of ORG-patients and highlighted the significant overlap in clinical and pathologic features between ORG and idiopathic-FSG.¹⁵ In the present case, we detected an acute tubulointerstitial nephritis, due to both infective and pharmacological aetiology, overlapping relevant histological changes (FSG, hyaline arteriosclerosis) in a patient with MS having previously normal renal function. Despite a severe vascular damage (elevated renal arterial resistive index), the patient recovered a normal renal function.

Conclusion

The relationship between MS and nephropathy is complex. Despite the strong epidemiologic association, the renal involvement in MS has not been proven. A greater knowledge of the combination of FSG and glomerulomegaly in MS can help in the understanding of pathophysiological mechanisms of this new emergency.

Acknowledgments

There is none to be declared.

Ethical issues

There is none to be declared

Competing interests

The authors declare no conflict of interests.

References

1. Yanovski SZ, Yanovski JA. Obesity prevalence in the United States--up, down, or sideways? *N Engl J Med* **2011**;364:987-9. doi: 10.1056/NEJMp1009229
2. Grundy SM, Cleeman JJ, Daniels SR, Donato KA, Eckel RH, Franklin BA, et al. American Heart Association; National Heart, Lung, and Blood Institute. Diagnosis and management of the metabolic syndrome: an American Heart Association/National

Case Highlights

What is current knowledge?

- ✓ The MS is an increasing public health problem.
- ✓ The CKD is an emerging pathology but only few patients will reach the end stage renal disease.
- ✓ There exists a growing strong association between MS and CKD but up to now the pathogenetic mechanisms inducing the renal involvement in MS are for the most part unknown.

What is new here?

- ✓ Analysing the reported pathologic studies, despite the strong epidemiologic association, the involvement in MS has not been proven.
- ✓ A greater knowledge of the combination of histological renal changes in MS can help in the understanding of pathophysiological mechanisms of MS.

- Heart, Lung, and Blood Institute Scientific Statement. *Circulation* **2005**;5;112:2735-52.
3. Meguid El Nahas A, Bello AK. Chronic kidney disease: the global challenge. *Lancet* **2005**;365:331-40.
 4. Lameire N, Jager K, Van Biesen W, de Bacquer D, Vanholder R. Chronic kidney disease: a European perspective. *Kidney Int Suppl* **2005**;99:S30-8.
 5. Zhang GM, Zhu Y, Ye DW. Metabolic syndrome and renal cell carcinoma. *World J Surg Oncol* **2014**; 29;12:236. doi: 10.1186/1477-7819-12-236
 6. Nagase M, Yoshida S, Shibata S, Nagase T, Gotoda T, Ando K, et al. Enhanced aldosterone signaling in the early nephropathy of rats with metabolic syndrome: possible contribution of fat-derived factors. *J Am Soc Nephrol* **2006**;17:3438-46.
 7. O'Donnell MP, Kasiske BL, Cleary MP, Keane WF. Effects of genetic obesity on renal structure and function in the Zucker rat. II. Micropuncture studies. *J Lab Clin Med* **1985**; 106:605-10.
 8. Hollenberg NK. Obesity and the kidney: why is the kidney at risk? *Kidney Int* **2007**; 71:187-8.
 9. Hall JE, Kuo JJ, da Silva AA, de Paula RB, Liu J, Tallam L. Obesity-associated hypertension and kidney disease. *Curr Opin Nephrol Hypertens* **2003**; 12:195-200.
 10. Weisinger JR, Kempson RL, Eldridge FL, Swenson RS. The nephrotic syndrome: a complication of massive obesity. *Ann Intern Med* **1974**;81:440-7.
 11. Eknayan G. Obesity and chronic kidney disease. *Nefrologia* **2011**;31:397-403. doi: 10.3265/Nefrologia.pre2011.May.10963
 12. Serra A, Romero R, Lopez D, Navarro M, Esteve A, Perez N, et al. Renal injury in the extremely obese patients with normal renal function. *Kidney Int* **2008**;73:947-55. doi: 10.1038/sj.ki.5002796.
 13. Rea DJ, Heimbach JK, Grande JP, Textor SC, Taler SJ, Prieto M, et al. Glomerular volume and renal histology in obese and non-obese living kidney donors. *Kidney Int* **2006**; 70:1636-41.
 14. Alexander MP, Patel TV, Farag YM, Florez A, Rennke HG, Singh AK. Kidney pathological changes in metabolic syndrome: a cross-sectional study. *Am J Kidney Dis* **2009**;53:751-9. doi: 10.1053/j.ajkd.2009.01.255
 15. Kambham N, Markowitz GS, Valeri AM, Lin J, D'Agati VD. Obesity-related glomerulopathy: an emerging epidemic. *Kidney Int* **2001**;59:1498-509.